TUMORS of the CENTRAL NERVOUS SYSTEM

by

LUCIEN J. RUBINSTEIN, M.D.

AFIP

TUMORS of the CENTRAL NERVOUS SYSTEM

ATLAS OF TUMOR PATHOLOGY

Second Series

Fascicle 6

TUMORS OF THE CENTRAL NERVOUS SYSTEM

by

LUCIEN J. RUBINSTEIN, M.D.

Professor of Pathology (Neuropathology)
Stanford University School of Medicine
Stanford, California

Published by the
ARMED FORCES INSTITUTE OF PATHOLOGY
Washington, D. C.

Under the Auspices of
UNIVERSITIES ASSOCIATED FOR RESEARCH AND EDUCATION IN PATHOLOGY, INC.
Bethesda, Maryland
1972

Accepted for Publication
1970

For sale by the American Registry of Pathology
Armed Forces Institute of Pathology
Washington, D. C. 20305

ATLAS OF TUMOR PATHOLOGY

Sponsored and Supported by

AMERICAN CANCER SOCIETY
NATIONAL CANCER INSTITUTE, NATIONAL INSTITUTES OF HEALTH
U. S. PUBLIC HEALTH SERVICE
and
ARMED FORCES INSTITUTE OF PATHOLOGY

EDITOR
HARLAN I. FIRMINGER, M.D.
Professor, Department of Pathology
University of Maryland School of Medicine
Baltimore, Maryland 21201
and
Scientist Associate, Universities Associated for
Research and Education in Pathology, Inc.
9650 Rockville Pike
Bethesda, Maryland 20014

EDITORIAL ADVISORY COMMITTEE

Lauren V. Ackerman, M.D.	Washington University School of Medicine St. Louis, Missouri
David G. Freiman, M.D.	Harvard Medical School Boston, Massachusetts
John K. Frost, M.D.	The Johns Hopkins School of Medicine Baltimore, Maryland
James C. Harkin, M.D.	Tulane University School of Medicine New Orleans, Louisiana
Dante G. Scarpelli, M.D.	University of Kansas Medical Center Kansas City, Kansas
Robert E. Scully, M.D.	The Massachusetts General Hospital Boston, Massachusetts
Philippe Shubik, M.D.	University of Nebraska College of Medicine Omaha, Nebraska
Harlan J. Spjut, M.D.	Baylor University College of Medicine Houston, Texas

EDITOR'S NOTE

The Atlas of Tumor Pathology was originated by the Committee on Pathology of the National Academy of Sciences–National Research Council in 1947. The form of the Atlas became the brainchild of the Subcommittee on Oncology and was shepherded by a succession of editors. It was supported by a long list of agencies; many of the illustrations were made by the Medical Illustration Service of the Armed Forces Institute of Pathology; the type was set by the Government Printing Office; and the final printing was made by the press at the Armed Forces Institute of Pathology. The American Registry of Pathology purchased the fascicles from the Government Printing Office and sold them at cost, plus a small handling and shipping charge. Over a period of 20 years, 15,000 copies each of 40 fascicles were produced. They provided a system of nomenclature and set standards for histologic diagnosis which received worldwide acclaim. Private contributions by almost 600 pathologists helped to finance the compilation of an index by The Williams & Wilkins Company to complete the original Atlas.

Following the preparation of the final fascicle of the first Atlas, the National Academy of Sciences–National Research Council handed over the task of further pursuit of the project to Universities Associated for Research and Education in Pathology, Inc. Grant support for a second series was generously made available by both the National Cancer Institute and the American Cancer Society. The Armed Forces Institute of Pathology has expanded and improved its press facilities to provide for a more rapid and efficient production of the new series. A new Editor and Editorial Advisory Committee were appointed, and the solicitation and preparation of manuscripts continues.

This second series of the Atlas of Tumor Pathology is not intended as a second edition of the first Atlas and, in general, there will be variation in authorship. The basic purpose remains unchanged in providing an Atlas setting standards of diagnosis and terminology. Throughout this new series, the term chosen by the Committee on Tumor Nomenclature of the International Union Against Cancer is shown by an asterisk if it corresponds to the author's heading, or as the first synonym in bold if it differs from the author's first choice.* Hematoxylin and eosin stained sections still represent the keystone of histologic diagnosis; therefore, most of the photomicrographs will be of sections stained by this technic, and only sections prepared by other technics will be specifically designated in the legends. It is hoped that in many of the new series a broader perspective of tumors may be offered by the inclusion of special stains, histochemical illustrations, electron micrographs, data on the biologic behavior, and other pertinent information for better understanding of the disease.

The format of the new series is changed in order to allow better correlation of the illustrations with the text, and a more substantial cover is provided. An index will be included in each fascicle.

It is the hope of the Editor, the Editorial Advisory Committee, and the Sponsors that these changes will be welcomed by the readers. Constructive criticisms and suggestions will be appreciated.

Harlan I. Firminger, M.D.

---

* The author feels that the present International Nomenclature for tumors of the central nervous system is unsatisfactory. The International Union Against Cancer has decided not to reappoint the Committee on Tumor Nomenclature, and the responsibility for drafting an international classification of neoplasms is now in the hands of the World Health Organization. We understand that an effort to develop a more widely acceptable classification for CNS tumors is proceeding at this time. Consequently the Editor chose in this Fascicle to depart from the past practice of highlighting the present IUCC Nomenclature. Hopefully a new, more comprehensive international classification for CNS tumors will be forthcoming in the near future.

FOREWORD

This fascicle of the second series of the Atlas of Tumor Pathology could well be considered a textbook on tumors of the central nervous system.

As in the entire series of fascicles, the illustrations in this one are numerous and excellent; there are more than 400, including 15 color plates. The nomenclature is elaborate, incorporating many of the subtypes of rare neoplasms that have been described. In the almost 30 years since we produced the earlier fascicle on this subject, there have been advances in techniques and methods of study that have helped clarify some of the problems in this field. Some of them have been of aid to the neurosurgeons and irradiation therapists, but still more help is needed for patients harboring many of the gliomas—especially the highly malignant ones.

It has been a pleasure to write the Foreword for this fascicle by L. J. Rubinstein, whose qualifications in the field of neuro-oncology are well known.

James W. Kernohan, M.D.
George P. Sayre, M.D.

Mayo Clinic and Mayo Foundation
Rochester, Minnesota

PREFACE AND ACKNOWLEDGMENTS

The invitation by the Editor and the Editorial Advisory Committee of the Atlas of Tumor Pathology to undertake the Second Series of the fascicle on Tumors of the Central Nervous System presented the writer with a challenging task. The previous fascicle by Dr. J. W. Kernohan and Dr. G. P. Sayre had long established for itself a position of authority in neuro-oncology. Aside from its intrinsic excellence, it embodied the unrivaled experience of the Mayo Clinic workers and represented a school of thought that had gained a considerable measure of acceptance both in this Country and abroad. It would have been presumptuous on the part of the writer to attempt to improve or modify the fascicle of the first series, and he therefore decided to plan the present fascicle as a new work that, in concept and execution, is not designed to supplant the monograph by Dr. Kernohan and Dr. Sayre. The views expressed in this fascicle differ in a number of minor points from those in the previous work, but these differences of opinion are probably more a matter of terminology than concept.

The classification and nomenclature used in this text are those widely adhered to in English-speaking countries. In an attempt to provide some continuity with the previous fascicle, attention has been paid where relevant to the system of grading advocated by the Mayo Clinic workers; this aspect is further discussed in the introduction. This is not to deny that a number of conceptual differences do exist between neuro-oncologists in English-speaking countries and those on the European Continent; attempts to reconcile these divergences by the adoption of various terminologic compromises are premature at this stage, and little seems to be gained by them.

The diagnostic recognition of tumor entities being the primary purpose of this Atlas, a relatively minor role has been assigned to modern tools of investigative oncology, such as electron microscopy, tissue culture, and enzyme histochemistry. Nevertheless, recent advances in the field have made it desirable to outline in the introduction some of the general principles that determine the biologic character of tumors of the central nervous system in man and some of the results of their experimental production as a pointer toward further research. The fascicle is primarily addressed to the resident in pathology, neurology, and neurosurgery, and to the general pathologist who may be confronted by the practical diagnostic problems that are frequently raised by these neoplasms. In this spirit it was thought desirable to include a chapter on the effects of radiation on cerebral tumors and the adjacent brain, and a brief account of the special staining and impregnation technics the writer has found useful in the diagnosis of cerebral tumors; a note on rapid diagnostic methods has also been appended, including an assessment of the brain smear technic. Although this method is sometimes regarded as less reliable than other rapid diagnostic technics, this has not been the experience of the writer, and since it is still employed in a number of neurosurgical centers it cannot be considered obsolete.

The writer is indebted to many colleagues for their guidance. To his teacher, Professor Dorothy S. Russell, he owes most of all.

For their counsels in the planning of this fascicle, he would like to thank the members of the Editorial Advisory Committee, especially Dr. Harlan I. Firminger, and, for their suggestions, Dr. Amico Bignami, Dr. Kenneth M. Earle, Dr. Mary M. Herman, Dr. John J. Kepes, and Dr. William C. Schoene.

The writer acknowledges with gratitude assistance from the following: Dr. David M. Robertson, Kingston, Ontario; Dr. F. S. Vogel, Durham, N. C.; Dr. Milton W. Brightman, Bethesda, Md.; Dr. Edwin R. Fisher, Pittsburgh, Pa.; Dr. Mary M. Herman, Stanford, Calif.; and Dr. L. M. Napolitano, Albuquerque, N. Mex., for electron micrographs; Dr. Leslie M. Zatz, Stanford, Calif.; and Col. Ludwig G. Kempe, Walter Reed Army Medical Center, for x-ray photographs; Professor David S. Maxwell, Los Angeles, Calif., for the drawing illustrated in figure 182; and Dr. Ranice W. Crosby and the Walter E. Dandy Collection, Johns Hopkins School of Medicine, for the drawing on the frontispiece; Dr. Igor Klatzo, Bethesda, Md., for the photographs illustrated in color plate XII; Professor William B. Blackwood, London, England; Dr. Richard L. Davis, Los Angeles, Calif.; Dr. Kenneth M. Earle, Washington, D. C.; Dr. Lysia S. Forno, Stanford, Calif.; Dr. John W. Hanbery, Stanford, Calif.; Dr. Juan E. Olvera-Rabiela, Mexico City, Mexico; Dr. Lucy B. Rorke, Philadelphia, Pa.; and Professor Dorothy S. Russell, London, England, for a number of gross photographs and photomicrographs. Permission was kindly given by Dr. J. W. Kernohan and Dr. G. P. Sayre to reproduce some of the gross photographs from the previous fascicle. Unless especially acknowledged in the captions, all the photographs are the author's own.

Most of the material used to illustrate this fascicle was studied by the writer at the London Hospital, England, the Montefiore Hospital and Medical Center, New York, and the Stanford University School of Medicine. He wishes to record his thanks to Dr. Harry M. Zimmerman for the use of the Montefiore Hospital material. Dr. John K. Frost of The Johns Hopkins Hospital has generously provided the material and illustrations on spinal fluid cytology. He is also much indebted to Dr. Kenneth M. Earle, Chief, Neuropathology Branch, Armed Forces Institute of Pathology for liberal access to gross and microscopic neuropathologic material from the Armed Forces Institute of Pathology, as well as for the kind hospitality bestowed by him and his department during the completion of this work.

The writer is grateful to the many colleagues who have submitted cases to him for consultation or interest in the past decade. It is impossible for him to name them all, but he would like to record his appreciation of his colleagues at Stanford University for the use in this fascicle of material studied, and in several instances published, by them; they include Dr. Jan Belza, Dr. Adam Borit, Dr. Michael M. Brand, Dr. John H. N. Deck, Dr. Lysia S. Forno, Dr. Jack Griffin, Dr. Mary M. Herman, Dr. Marshall E. Kadin, Dr. William J. Logan, and Dr. William C. Schoene. He would like to thank his neurosurgical colleagues for their cooperation and for making available to him the clinical data on the material he has examined: they include Mr. D. W. C. Northfield, London, England; Dr. Leo M. Davidoff and Dr. Emanuel H. Feiring, New York, N. Y.; and Dr. John W. Hanbery, Dr. James B. Golden, Dr. Daniel Meub, and Dr. Lawrence Arnstein, from Stanford. Outside cases referred for consultation, of which use has been made in this fascicle, were sent to the author by Dr. S. Ry Andersen, Copenhagen, Denmark; Dr. M. Sidney Anderson, Houston, Tex.; Dr. P. V. Best, Aberdeen, Scotland; Dr. Richard L. Davis, Los Angeles, Calif.; Dr. Clarissa L. Dolman, Vancouver, British Columbia; Dr. S. M.

Grant, Los Angeles, Calif.; Lt. Col. John M. Hardman, Washington, D. C.; Dr. Webb Haymaker, Moffett Field, Calif.; Dr. Ivan Herzog, New York, N. Y.; Capt. V. J. Hyams, Washington, D. C.; Dr. John J. Kepes, Kansas City, Kan.; Dr. Martin R. Krigman, Chapel Hill, N. C.; Dr. Gordon Mathieson, Montreal, Canada; Dr. A. A. Miller, Preston, England; Dr. James S. Nelson, St. Louis, Mo.; Dr. H. Okazaki, Rochester, Minn.; Dr. Juan E. Olvera-Rabiela, Mexico City, Mexico; Dr. David R. Oppenheimer, Oxford, England; Dr. Kenneth A. Osterberg, Minneapolis, Minn.; Dr. Robert S. Porro, New York, N. Y.; the late Dr. Helena E. Riggs, Philadelphia, Pa.; Dr. Lucy B. Rorke, Philadelphia, Pa.; Dr. J. H. Sung, Minneapolis, Minn.; Dr. Robert D. Terry, New York, N. Y.; Dr. Mary I. Tom, Toronto, Canada; Dr. Richard M. Torack, St. Louis, Mo.; Dr. Cecil S. Treip, Cambridge, England; Professor Henry Urich, London, England; Dr. C. J. Wegner, Stockton, Calif.; Dr. James A. Wilkerson, Salt Lake City, Utah; Dr. Harold W. Williams, Providence, R. I.; Dr. Wolfgang Zeman, Indianapolis, Ind.; and Dr. Gabriele M. Zu Rhein, Madison, Wis.

The writer is much indebted to the skilled technical support he has received from Mr. Harry J. Oliver in London, and from Messrs. Peter V. Sharp and Robert Kitchen at Stanford. Special thanks are due for their skill in photographic and photomicrographic work to Mr. A. John King and Mr. R. L. Gallup, from the London Hospital; to Mr. Antol Herskovitz, from the Montefiore Hospital, New York; to Mr. Ralph Isenburg, from the Armed Forces Institute of Pathology, Washington, D. C.; and to Miss Janet Robbins, at the Stanford Medical Center.

Finally, the writer would like to express his deep appreciation for the unfailing help and cooperation he has received from Miss Gertrude Fehrlin, Mrs. Audrey Cyr, and Mrs. Margaret Mumford of the editorial staff of the Atlas of Tumor Pathology, and from the technical personnel of the Armed Forces Institute of Pathology.

Permission to reproduce copyrighted material has been obtained from the following journals and monographs:

American Academy of Neurology:

Neurology 20:341–346, 1970. For our figures 251, 252

American Association of Neurological Surgeons:

J. Neurosurg.

25:199–204, 1966. For our Plate X–F

26:542–547, 1967. For our figures 6, 74, 75, 77, 78

29:451–463, 1968. For our figure 182

33:587–590, 1970. For our figure 264

American Cancer Society, Inc.:

Cancer 17:233–241, 1963. For our figure 200

American Medical Association:

Arch. Path.

88:298–304, 1969. For our figure 315

90:35–45, 1970. For our figures 125–129

British Medical Association:

J. Neurol. Neurosurg. Psychiat. 33:763–770, 1970. For our figure 131

Edward Arnold (Publishers) Ltd.:

Pathology of Tumours of the Nervous System, 3d ed., 1970. For our figures 70, 71, 313

Fellowship of Postgraduate Medicine:

Postgrad. Med. J. 26:109–125, 1950. For our figure 132

J. F. Bergmann-Verlagsbuchhandlung:

Acta Neuropath. 14:77–97, 1969. For our figures 238, 239

Johns Hopkins School of Medicine:

Department of Art as Applied to Medicine. For our frontispiece

Journal of Neuropathology and Experimental Neurology:

J. Neuropath. Exp. Neurol.

7:349–367, 1948. For our figure 262

21:116–136, 1962. For our figures 342, 343

21:185–193, 1962. For our figures 37, 173–176

28:442–454, 1969. For our figures 113, 134, and Plate V–A

29:583–600, 1970. For our figures 135, 136

Macmillan (Journals) Ltd.:

Brain 87:379–412, 1964. For our figures 138, 147, 152, 158, 159

McGraw-Hill Book Company:

Pathology of the Nervous System, Vol. 2, 1971. For our figures 68, 206–208, 212, 214–216

Oliver & Boyd, Ltd.:

J. Path.

71:441–459, 1956. For our figure 66

73:25–31, 1957. For our figure 256

78:187–195, 1959. For our figures 162, 164, 165

97:165–168, 1969. For our figures 275, 276

Rockefeller University Press:

J. Cell Biol.

15:313–334, 1962. For our figure 94

19:415–439, 1963. For our figure 107

Seminario de Neuropatologia, Mérida, Yucatán:

Bol. Asoc. Mex. Patol., A. C. 7:13–59, 1969. For our figures 5, 11, 16, 30, 82, 115, 219, 228, 230, 231, 265, 266, 278, 314, 321, 322, and Plates I–C, IV–A, X–C

S.P.E.I. Editeurs:

Les Phakomatoses Cérébrales, 1963. For our figures 308–310

Springer-Verlag:

Acta Neurochir.

Supp. X:141–158, 1964. For our figures 65, 70, 71, 211

Supp. X:201–212, 1964. For our figures 227, 232–234

The atlas numbers are for identification of negatives at the Armed Forces Institute of Pathology.

Lucien J. Rubinstein, M.D.

TUMORS OF THE CENTRAL NERVOUS SYSTEM

CONTENTS

Page No.

INTRODUCTION 1
Incidence and Statistical Data 1
Tables I, II, III, IV, p. 2
Table V, p. 3
Pathogenesis 3
Experimental Tumor Production in Animals 5
TUMORS OF CENTRAL NEUROGENIC ORIGIN 7
Classification and Grading 7
General Biologic Characteristics 9
TUMORS OF NEUROGLIAL CELLS 19
Astrocytomas 19
Diffuse Cerebral Astrocytoma 21
Cerebellar Astrocytoma 32
Pilocytic Astrocytoma of Juvenile Type 34
Pontine and Medullary Astrocytomas 37
Spinal Astrocytoma 38
Protoplasmic Astrocytoma 39
Pilocytic Astrocytoma of Adult Type 39
Gemistocytic Astrocytoma 40
Subependymal Giant Cell Astrocytoma 40
Gliomatosis Cerebri 42
Malignant Astrocytoma 42
Astroblastoma 50
Plates I and II, pp. 25, 31
Polar Spongioblastoma 53
Glioblastoma Multiforme 55
Giant Cell Glioblastoma 72
Mixed Glioblastoma and Fibrosarcoma 74
Plate III, p. 59
Oligodendrogliomas 85
Ependymomas 104
Subependymoma 116
Myxopapillary Ependymoma of Filum Terminale 118
Malignant Ependymomas. Ependymoblastoma 119
Plate IV, p. 103

Page No.

TUMORS OF NEURONAL CELLS AND PRIMITIVE BIPOTENTIAL PRECURSORS 127
Medulloepithelioma 127
Medulloblastomas 130
Pigmented Papillary Medulloblastoma 141
Medullomyoblastoma 142
Neuroblastoma 154
Ganglioneuroma and Ganglioglioma 158
Dysplastic Gangliocytoma of the Cerebellum 164
Dysplastic Gangliocytoma of the Cerebrum 166
Plate V, p. 135
TUMORS OF MESODERMAL TISSUES 169
Tumors of the Meninges and Their Derivatives 169
Meningiomas 169
Meningotheliomatous Meningioma 175
Transitional or Mixed Meningioma 176
Psammomatous Meningioma 176
Fibroblastic Meningioma 177
Angioblastic Meningioma 180
Malignant Meningioma 186
Plate VI, p. 179
Sarcomas 190
Fibrosarcoma 192
Spindle Cell Sarcoma 193
Polymorphic Cell Sarcoma 194
Meningeal Meningiomatosis (Primary Sarcomatosis) 200
Myxosarcomas and Chondrosarcomas 200
Mesenchymal Chondrosarcoma 200
Embryonal Sarcoma 201
Plate VII, p. 197

TUMORS OF THE CRANIAL AND SPINAL NERVE ROOTS 205
Schwannomas 206
Neurofibromas 213

TUMORS OF THE LYMPHORETICULAR SYSTEM 215
Primary Tumors of the Lymphoreticular System 215
Reticulum Cell Sarcoma-Microglioma 215
"Hodgkin's Disease" 225
Hypothalamic Granuloma or Cerebral Form of Histiocytosis X 225
Primary Meningeal Lymphosarcoma 227
Plasmacytoma 227

Page No.

Secondary Lymphomatous Proliferations 227
Lymphosarcoma and Reticulum Cell Sarcoma 228
Hodgkin's Disease 232
Plasmacytoma 232
Leukemias 232
TUMORS AND MALFORMATIONS OF THE BLOOD VESSELS 235
Neoplasms 235
Capillary Hemangioblastoma 235
Malformations 241
Capillary Telangiectases 241
Cavernous Angioma 245
Arteriovenous Malformations 246
Mesencephalo-Oculo-Facial Angiomatosis 250
Aneurysm of the Vein of Galen 250
Venous Malformations 254
"Angiodysgenetic Myelomalacia" 255
Sturge-Weber Disease 255
Plates VIII and IX, pp. 243, 253
TUMORS OF THE CHOROID PLEXUS AND RELATED STRUCTURES 257
Choroid Plexus Papillomas 257
Papillary and Acinar Mucus-Secreting Adenomas 259
Xanthogranuloma of the Choroid Plexus 262
Choroid Plexus Meningioma 263
Colloid Cysts of the Third Ventricle 263
Plate X, p. 267
TUMORS OF THE PINEAL REGION 269
Tumors of Germ Cell Origin (Including Those Arising in the Suprasellar Region) 269
Germinoma 269
Teratomas 275
Choriocarcinoma 276
Embryonal Carcinoma 276
Tumors of the Pineal Parenchyma 277
Pineocytoma 279
Pineoblastoma 281
Ganglioneuroma and Ganglioglioma 282
Chemodectoma 283
Gliomas 283
Other Neoplasms of the Pineal Region 283
Meningioma 283
Pineal Cysts 283
Epidermoid and Dermoid Cysts 283
Glial Cysts 283
Plate X, p. 267

Page No.

TUMORS AND TUMOR-LIKE LESIONS OF MALDEVELOPMENTAL ORIGIN 285
Nonneurogenic Neoplasms 285
Teratomas 285
Teratomas and Teratoid Tumors of the Fourth Ventricle 286
Germinoma (or Atypical Teratoma) 287
Spinal Enterogenous Cyst 287
Dermoid and Epidermoid Cysts 288
Craniopharyngioma 292
Intrasellar Rathke Cleft Cysts 294
Lipomas 294
Neuroepithelial Ectopic Tumors and Hamartomas 296
Ectopic Gliomas 296
Melanotic Neuroectodermal Tumor of Infancy 297
Hypothalamic Ganglionic Hamartoma 298
Choristoma of the Neurohypophysis 299
Dysgenetic Syndromes (Phacomatoses) Associated with Tumors or Tumor-like Malformations of the Nervous System 300
Tuberous Sclerosis 301
Von Recklinghausen's Neurofibromatosis 302
Tumors in Central Neurofibromatosis 303
Hamartomas in Central Neurofibromatosis 303
Von Hippel-Lindau Disease 309
Sturge-Weber Disease (Encephalotrigeminal Angiomatosis) 309
Neurocutaneous Melanosis and Primary Meningeal Melanoma 309
SECONDARY TUMORS OF THE CENTRAL NERVOUS SYSTEM 313
Direct Extension of Local Tumors 313
Pituitary Adenomas 313
Chemodectoma of the Glomus Jugulare 314
Chordoma 315
Other Tumors 318
Hematogenous Spread 319
Metastatic Carcinoma 319
Meningeal Carcinomatosis 325
Metastatic Melanoma 328
Other Metastatic Tumors 332
Plate XI, p. 323
CHANGES IN THE BRAIN, SPINAL CORD, AND OTHER NEIGHBORING STRUCTURES PRODUCED BY LOCAL NEOPLASMS 333
Cerebral Edema 333
Hydrocephalus 342
Internal Herniations and Their Secondary Vascular Effects 343
Brainstem Hemorrhages 344

Page No.

Calcarine Infarction 346
Cerebellar Herniations 346
Pressure Effects on the Pituitary Gland 347
Pressure Effects on the Dura and Skull 348
Effects of Intraspinal Neoplasms on the Spinal Cord 348
Plate XII, p. 337
RADIATION CHANGES IN INTRACRANIAL NEOPLASMS AND THE ADJACENT BRAIN 349
Effects of Radiation on Intracranial Tumors 349
Effects of Radiation on the Normal Brain and on the Brain Adjacent to Intracranial Tumors (Radionecrosis) 350
Plate XIII, p. 357
DIAGNOSTIC AIDS FOR THE HISTOLOGIC AND CYTOLOGIC EXAMINATION OF TUMORS OF THE CENTRAL NERVOUS SYSTEM 361
Special Stains 361
Connective Tissue Stains 362
Silver Impregnations for Reticulin Fibers 362
Methods for Neuroglia 362
Stains for Nerve Cells and Neurites 362
Special Metallic Impregnations 363
Enzyme Histochemical Technics 366
Rapid Diagnostic Methods 366
Smear or Wet Film Technic 366
Frozen Sections 367
Cryostat-cut Unfixed Sections 367
Spinal Fluid Cytology 370
Plates XIV and XV, pp. 365, 369
INDEX 379

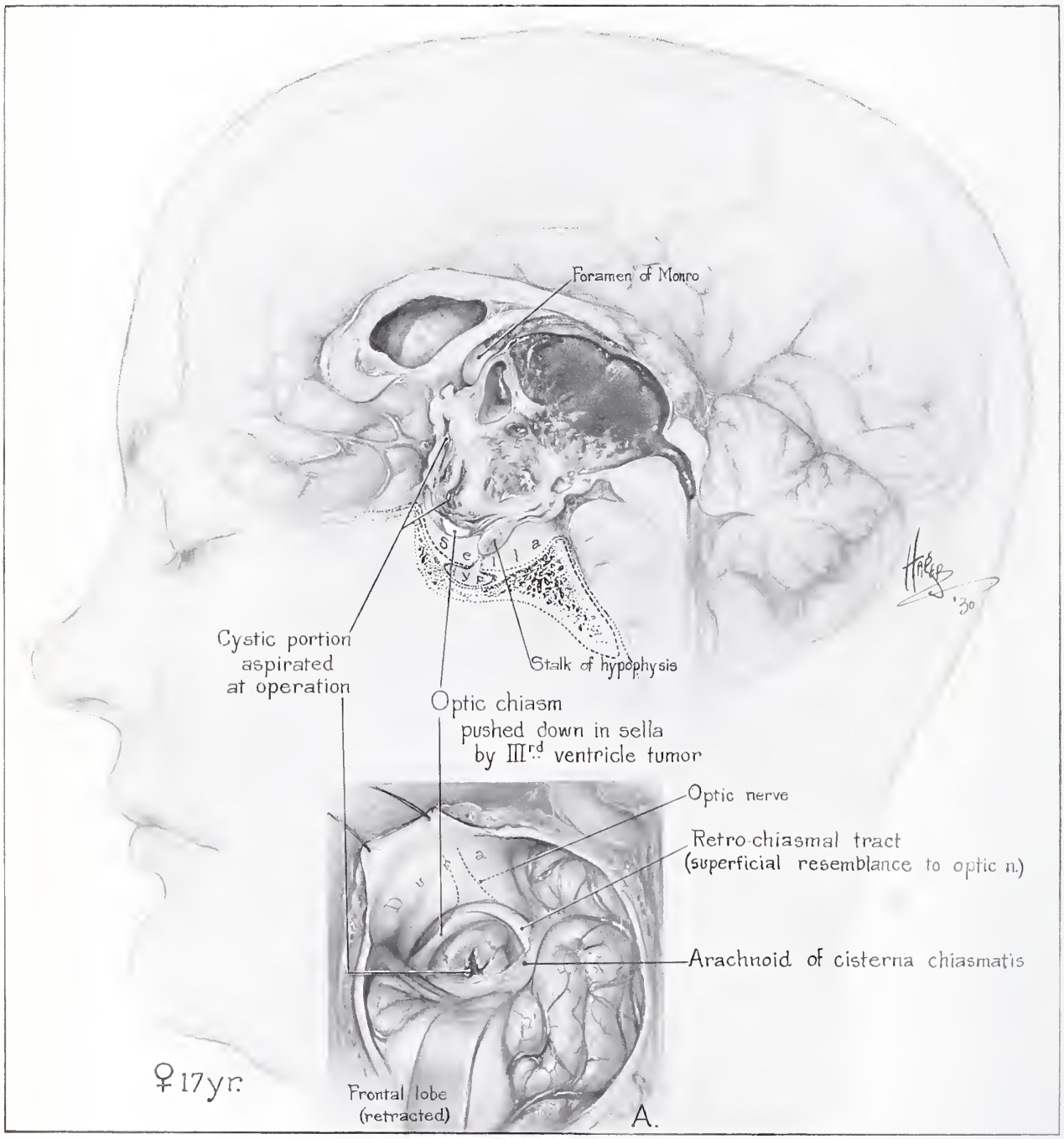

ASTROCYTOMA OF THE THIRD VENTRICLE

This astrocytoma arose in the third ventricle of a 17-year-old girl and caused obesity and obstructive hydrocephalus.

Drawing by Dorcas H. Padget
Property of: Walter E. Dandy Collection
Department of Art as Applied to Medicine
The Johns Hopkins School of Medicine

TUMORS OF THE CENTRAL NERVOUS SYSTEM

INTRODUCTION

INCIDENCE AND STATISTICAL DATA

Primary tumors of the central nervous system and its coverings account for about 1.2 percent of all autopsied deaths and for approximately 9 percent of all primary neoplasms. Eighty-five percent of them are found within the cranial cavity.

Among the **intracranial** tumors, those of central neurogenic origin claim priority in number and complexity. These are the tumors derived from the intrinsic, or parenchymatous elements of the central nervous system, excluding the microglia; they are widely credited to account for 40 to 50 percent of all intracranial tumors both primary and metastatic encountered at all ages of life. Following Bailey and Cushing, they have been generally termed tumors of the **glioma** group; in fact, they encompass not only those which are derived from neuroglial elements but also those from neuronal cells and their primitive bipotential precursors.

Second to the gliomas in neurosurgical importance in the adult are the meningiomas (13 to 18 percent), followed by the acoustic nerve schwannomas (8 percent). Pituitary adenomas account for 3.4 to 17.8 percent of intracranial tumors, depending on the neurosurgical centers which attract them. Also the incidence of metastatic carcinomas differs widely: it may be as high as 37 percent in some series and as low as 4.2 percent in others, according to whether the figures emanate from general autopsy material or from neurologic and neurosurgical sources. The high estimate of 32 percent has been computed by Kurland for the resident population of Rochester, Minnesota. In pathologic practice a figure of 15 to 25 percent is probably realistic (Courville).

The central nervous system is the second most common site of primary tumor formation in **children**, who show in this regard a much higher relative incidence than **adults**. This is because neoplasms in adults most often involve the respiratory, mammary, gastrointestinal, and genital tracts, whereas up to 75 percent of the neoplasms in children arise from the hematopoietic, urinary, and nervous (central and peripheral) systems. Primary neurogenic neoplasms comprise from 80 to almost 90 percent of all intracranial tumors below the age of 15 years. On the other hand, those that originate from the sheath elements covering the brain and nerves—meningiomas and schwannomas—with very rare exceptions are tumors of adults.

Another important incidental difference between adults and children lies in the localization of these neoplasms within the cranial cavity. In children 70 percent of all intracranial tumors are **infratentorial;** in adults 70 percent are **supratentorial.**

Irrespective of age the incidence of various types of intracranial gliomas, based on necropsy findings of 496 cases observed over a 22-year period is shown in Table I.

Table I
INCIDENCE OF INTRACRANIAL GLIOMAS (ALL AGES)*

Glioblastomas	55.0%
Astrocytomas	20.5%
Ependymomas	6.0%
Medulloblastomas	6.0%
Oligodendrogliomas	5.0%
Choroid plexus papillomas	2.0%
Colloid cysts	2.0%

*Russell, D. S., and Rubinstein, L. J. Pathology of Tumours of the Nervous System, 3d ed. London: Edward Arnold, 1971.

The incidence of the different forms of intracranial gliomas in children is shown in Table II.

Table II
INCIDENCE OF INTRACRANIAL GLIOMAS IN CHILDREN *

Astrocytomas (all sites)	48.0%
Medulloblastomas	44.0%
Ependymomas	8.0%

*Bodian, M., and Lawson, D. The intracranial neoplastic diseases of childhood. A description of their natural history based on a clinico-pathological study of 129 cases. Brit. J. Surg. 40:368-392, 1953.

Primary tumors that originate in the posterior fossa present special diagnostic and neurosurgical problems. The following figures in Table III show the incidence of cerebellar and fourth ventricle neoplasms, irrespective of age but excluding the cerebellopontine angle and brainstem tumors. The incidence of metastatic tumors is certainly unduly low in this series.

Table III
INCIDENCE OF CEREBELLAR AND FOURTH VENTRICLE TUMORS *

Astrocytomas	29.0%
Medulloblastomas	24.8%
Ependymomas	11.1%
Hemangioblastomas	11.6%
Meningiomas	5.3%
Choroid plexus papillomas	2.0%
Metastatic neoplasms	2.5%

* Zülch, K. J. Brain Tumors. Their Biology and Pathology, 2d American ed., p. 78. New York: Springer Publishing Co., 1965.

Intraspinal neoplasms account for 15 percent of all primary tumors of the central nervous system and its sheath elements (meninges and Schwann cells). The incidence of the various tumor types differs markedly from those harbored by the cranial cavity as shown in Table IV.

Table IV
INCIDENCE OF PRIMARY INTRASPINAL TUMORS IN A SERIES OF 1322 CASES AT MAYO CLINIC *

Schwannomas	29.0%
Meningiomas	25.5%
Gliomas, including extramedullary	22.0%
Sarcomas	11.9%
Vascular tumors	6.2%
Chordomas	4.0%
Epidermoid and other tumors	1.4%

* Slooff, J. L., Kernohan, J. W., and MacCarty, C. S. Primary Intramedullary Tumors of the Spinal Cord and Filum Terminale. Philadelphia: W. B. Saunders Company, 1964.

Among the intraspinal gliomas, which predominantly occur in adults, the ependymomas form the largest group. This is partly

due to their high incidence in the filum terminale, where almost 60 percent of the spinal ependymomas originate. Figures on the incidence of the different types of intraspinal intramedullary gliomas are shown in Table V.

Table V

INCIDENCE OF PRIMARY INTRASPINAL INTRAMEDULLARY GLIOMAS *

Ependymomas	63.0%
Astrocytomas (grades 1 and 2)	24.5%
Glioblastomas (astrocytomas grades 3 and 4)	7.5%
Oligodendrogliomas	3.0%
Other tumors	2.0%

* Based on data published by Slooff, J. L., Kernohan, J. W., and MacCarty, C. S. Primary Intramedullary Tumors of the Spinal Cord and Filum Terminale. Philadelphia: W. B. Saunders Company, 1964.

The sex distribution of intracranial gliomas indicates a preponderance of 2 to 1 in the male, both in the malignant supratentorial gliomas of adult life and middle age, and in the cerebellar astrocytomas and medulloblastomas of children. A somewhat lesser preponderance of males is also found for the intraspinal gliomas. By contrast, intracranial schwannomas are relatively more common in females. Females are also twice as liable to be afflicted by intracranial meningiomas as males. In spinal meningiomas this preponderance is even greater: the incidence in females is four times larger than in males (Slooff et al.).

Figures on the incidence of spontaneous neoplasms of the central nervous system in animals are difficult to obtain. The most reliable are those provided by McGrath for the dog. They show that the relative incidence of spontaneous gliomas compares closely to that in man (46.5 percent); meningiomas are less common (6 percent), and metastatic neoplasms account for 32 percent. In Lüginbühl's series of 400 nervous system tumors in various animal species, 30.5 were classified as neuroectodermal, 17 percent as metastatic, and 39.2 percent as mesodermal. The last figure is due to the remarkable incidence of meningiomas in aged cats and dogs, and to the relative frequency of malignant primary neoplasms of the lymphoreticular system in dogs, horses, and cattle. Most of the gliomas were found in dogs: the majority were oligodendrogliomas, which made up 48 percent of the entire animal series. No differences in sex distribution were observed. Further details on the pathologic study of these animal tumors have been published by Lüginbühl and associates.

PATHOGENESIS

Very little is known of the pathogenic factors that induce tumor formation in the central nervous system in man. Aside from the well known familial incidence of retinoblastomas and the occasional occurrence of cerebellar medulloblastomas in twins, no genetic disposition has been found to influence the incidence of primary intracranial tumors as a whole, except for a few rare reported examples of familial astrocytomas. The dysgenetic syndromes, or phacomatoses, associated with tumors or tumor-like formations in the nervous system are a special case; as will be mentioned later (p. 302), intracranial and intraspinal tumors, often hereditary, are a frequent accompaniment of the central form of von Recklinghausen's

neurofibromatosis, of von Hippel-Lindau's disease, and of tuberous sclerosis. Moreover, multiplicity of tumors is characteristic of the first two of these conditions, and there is a suggestion that, in neurofibromatosis and tuberous sclerosis, neoplastic gliogenous transformation may take place on the basis of focal glial cell abnormalities of embryonal origin, which are sometimes widespread.

The majority of tumors of the central nervous system are generally believed to arise from the neoplastic transformation of adult elements. The more primitive and malignant tumors of infancy and early childhood, however, such as the medulloblastomas, neuroblastomas, and medulloepitheliomas, probably originate from primitive neuronal or bipotential cell precursors. Evidence will be presented (p. 130) in support of the theory that some medulloblastomas may be derived from the fetal external granular layer of the cerebellum; others may arise from persistent embryonal cell rests in the posterior medullary velum (Raaf and Kernohan). A few medulloblastomas are **congenital** in origin and present clinically a few weeks after birth (Kadin et al.). Other congenital gliomas have been reported (Sandbank), as well as congenital teratomas, meningeal tumors, choroid plexus tumors, and intracerebral vascular neoplasms (Solitare and Krigman).

Careful microscopic examination of the temporal lobes surgically excised from children and young subjects with a prolonged history of epilepsy has suggested, in a few cases, that **ectopic** or **hamartomatous neuroglial cell foci** in this region may constitute a potential source for subsequent glioma formation (Cavanagh). In one such case examined by me an extensively calcified, partly cystic oligodendroglioma was found in the right fusiform and hippocampal gyri in a 15-year-old boy who was mentally retarded since early childhood and had suffered from poorly controlled epileptic seizures for 13 years. Neuronal ectopias and glial dysplastic foci were present in the inferior temporal cortex and in the inferior and middle temporal white matter.

Tumors of **vestigial** tissues, such as teratomas and teratoid neoplasms, dermoid and epidermoid cysts, craniopharyngiomas, and probably chordomas, as well as neurogenic intra-axial and ectopic hamartomas, are clearly of malformative origin. This is supported in the case of the dermoid and epidermoid cysts by their association with other malformations such as spina bifida and cranial defects. In addition to the previously mentioned association of cerebral and spinal tumors with the phacomatoses, a definite correlation between the incidence of intramedullary spinal cord tumors and syringomyelia appears to have been established (Poser; Ferry et al.).

In the context of current concepts on malignant cell transformation which implicate the possible alteration of the cell genome by oncogenic viruses, no causative factors have been found in man which link tumor formation in the central nervous system with any of the known bacterial, parasitic, or viral infections of the nervous system. From the cytologic point of view, much interest is focused at this time on the morphologic features of the bizarre astrocytes found in progressive multifocal leucoencephalopathy, an ingravescent degenerative disease of the central nervous system that, on electron microscopic evidence, is regarded as being caused by the replication in glial cells of virions belonging to the papova group of viruses (Zu Rhein). These astrocytes have all the cytologic features of malignant cells, but actual tumor formation has not been observed.

In relation to the **degenerative** diseases of the nervous system, the exceptional association of malignant gliomas with multiple sclerosis has been reported (Brihaye et al.). Subsequently to the two cases described elsewhere (Russell and Rubinstein), I have studied a third example in a middle-aged man, in whom a gemistocytic astrocytoma of the left temporal lobe was adjacent to the typical plaques of long-standing multiple sclerosis. The association is intriguing, but probably fortuitous.

Despite a few suggestive case reports, there is no evidence that **head injury** and **glial scars** play a statistically significant role in the subsequent development of intracranial gliomas. Trauma has, however, been invoked in the pathogenesis of meningiomas (p. 172), and the relationship between the occurrence of lumbar dermoid and epidermoid cysts and previous repeated lumbar punctures is now well established on both clinical and experimental grounds (Van Gilder and Schwartz).

I am not aware of any authentic case of glioma in man which might possibly have been induced by previous therapeutic **radiation** to the head. On the other hand a few intracranial sarcomas have been described in which the circumstantial evidence is strong enough to point to radiation as the probable inciting factor. This rare complication is described on page 191.

EXPERIMENTAL TUMOR PRODUCTION IN ANIMALS

The experimental production of intracranial tumors has so far borne no relevance to the pathogenesis of brain tumors in man. They constitute, however, useful tools for the study of their morphology, biologic behavior, growth and spread, and therapeutic control. Until recently experimental intracranial tumors have been primarily induced by three methods: radiation, the intracranial implantation of carcinogenic chemicals, and the local injection of oncogenic viruses (Grove et al.).

Gamma rays, neutrons, I^{131}, Na^{24}, and x-rays have produced pituitary tumors in mice, and **x-rays** have induced gliomas in monkeys.

Carcinogenic chemicals have been widely used to induce intracranial tumors. The **oral** administration of acetylaminofluorene in the rat has resulted in gliomas, meningiomas, and neurilemomas, as well as tumors in other organs (Snell et al.). Ganglion cell tumors of the frontal lobes have also been produced in mice on diets supplemented by cholesterol or lecithin (Szepsenwol). The local **intracerebral implantation** in mice of a variety of carcinogenic **hydrocarbons** has been extensively performed by Zimmerman and his associates, and by others. The incidence of tumors varies according to the strain of mice used. The latent period is relatively long: the average time needed for the development of intracranial tumors in rodents has been 250 days for gliomas and 220 days for sarcomas. Tumors of mixed cell type are often produced, and subsequent transplantation experiments have suggested that the environment or host play an important role in determining the cytologic appearance of the tumor cells (Zimmerman).

Of particular interest is the observation by Ikuta and Zimmerman of cylindrical and filamentous virus-like particles in the cytoplasm of reactive cells during the precancerous stages of the lesion following the intracerebral implantation of dibenzanthracene. The majority of the cells were subsequently

identified as macrophages; they all contained crystals of phagocytosed carcinogen (Popoff et al.). The interpretation of these findings is further complicated by the subsequent disclosure in the same laboratory of spherical virus-like particles, of a different morphologic structure, in the cytoplasm of a methylcholanthrene-induced mouse ependymoblastoma (Rubin et al.). The significance of this virus, identified as possibly a member of the murine Thylaxoviridae viruses, and its relation to the oncogenic effects of the implanted hydrocarbon have yet to be elucidated.

Two further approaches have recently been used for the production of chemically induced intracranial tumors. Hosobuchi and Ishii have described the successful production, within a few weeks, of gliomas and gangliogliomas in newborn and young hamsters following intracerebral implantation of brains of homologous embryo animals whose mothers were injected intravenously with a single dose of dimethylbenzanthracene. In recent years a group of extremely powerful carcinogenic compounds, the **nitrosamines**, have been introduced by Druckrey and his colleagues for the production of a wide variety of tumors of the central and peripheral nervous system. Both methylnitrosourea and dimethylnitrosourea induce these tumors in a high percentage of rats when administered intravenously or by ingestion (Stroobandt and Brucher). The average latent period following the gastric route is 200 days. A single intravenous injection of ethylnitrosourea in pregnant rats on the fifteenth day of gestation has induced a wide variety of malignant tumors of the brain, spinal cord, cranial, and peripheral nerves in almost all offspring (Ivankovic and Druckrey). The yield was highest when the compound was administered during the last week of gestation.

The third method for the production of experimental intracranial tumors has been the local injection of **oncogenic viruses.** This method provides a high percentage of positive yields: 70 percent in hamsters inoculated with polyoma virus, and 75 to 85 percent in dogs inoculated with the Rous sarcoma virus. The induction time required for the development of the neoplasms is considerably shorter than with chemical carcinogens; the polyoma virus often produces tumors in less than 30 days. Some of the tumors arising from the ependyma following the direct implantation in hamsters of the simian vacuolating virus are choroid plexus papillomas or carcinomas rather than true gliomas (Duffell et al.), but the intracerebral implantation of the Schmidt-Ruppin strain of the Rous sarcoma virus will induce both sarcomas (Grove et al.) and gliomas (Bigner et al.) in dogs, and gliomas in hamsters (Bucciarelli et al.). The virions of the original infective agent are seldom recovered in these tumors.

An ingenious new technic for the speedy and reliable production of neuroglial tumors has been devised by Shein. Following the neoplastic transformation of tissue-cultured fetal or newborn hamster glial cells by the polyoma virus or the simian virus 40, subcutaneous or intracerebral inoculation of the transformed cells produces astrocytomas and glioblastomas in newborn or adult hamsters. This promising model lends itself to numerous experimental situations and may open a new avenue in glioma research. Of particular interest in this context is the production of glioblastoma multiforme by the progeny of a single cloned astrocytoma cell.

TUMORS OF CENTRAL NEUROGENIC ORIGIN

CLASSIFICATION AND GRADING

CYTOGENESIS. The experimental work previously referred to has reinforced the current belief that gliogenous tumors, like neoplasms elsewhere in the body, are generally the result of the malignant proliferation of well differentiated **adult** elements, due to either a mutation in the genetic apparatus of the cell or the transformation of its genome by the introduction of extraneous oncogenic nucleic acid material. Historically, however, the morphologic complexity and diversity of these neoplasms led to the concept of their **embryogenetic** derivation, a view which Bailey and Cushing did not endorse but nevertheless embodied in their widely accepted classification. In this scheme the tumor types were aligned with the various stages of cell ontogenesis in the central nervous system. Support was gained for these conclusions by the use of metal impregnations, which emphasized the cytoplasmic features of tumor cell structure. Although Bailey and Cushing were obviously aware of the range of morphologic variation that may normally be expected in malignant neoplasms in general, and of the phenomenon of dedifferentiation that may accompany rapid increases in tumor growth, these important aspects were somewhat overshadowed by the weight and wealth of their cytologic observations. Despite some criticism their scheme has, with minor modification, remained the basis of most modern classifications of tumors of central neurogenic origin.

In the last three decades emphasis has shifted to the frequency with which **anaplasia** and **dedifferentiation** play a role in the morphologic character of tumor cell populations. Present concepts therefore stress the derivation of most gliogenous tumors from the three types of adult neuroglial cells normally found in the central nervous system: the astrocyte, oligodendrocyte, and ependymal cell. The medulloblastoma, a common tumor, is a truly primitive embryonal neoplasm capable, like the cells from which it probably originates, of differentiating along more than one cell line. The glioblastoma presents a special problem: it too is almost certainly derived from the anaplastic transformation of mature glial cells, most often astrocytes. The name, however, has been sanctioned by usage, and since the derivation of the glioblastoma from more differentiated astrocytes cannot clearly be demonstrated in all cases, it deserves to be retained. Finally there remain a number of rare primitive tumors of the central nervous system, such as the medulloepithelioma, neuroblastoma, and polar spongioblastoma, that possess distinct and characteristic morphologic features and therefore merit retention in the scheme.

In the previous series of this fascicle Kernohan and Sayre rejected the inclusion of these rare tumors as well as the term glioblastoma. By a logical application of the concepts of anaplasia and dedifferentiation, they replaced the existing classification of Bailey and Cushing by a system of **grading**

from 1 to 4 in an ascending order of malignancy. This system was applied to the astrocytomas, oligodendrogliomas, and ependymomas. It has often been welcomed by general pathologists. Attractive though such an apparent simplification may be, and supported as it was in many cases by the theoretical considerations alluded to above, there are a number of inherent difficulties which militate against too uncritical an adoption of this view.

The most important difficulty is related to the problem of sampling, which in biopsy material may not be representative of the tumor as a whole. Moreover, the progressive evolution over a period of months or years of an originally benign neoplasm to a more malignant phase is not an uncommon phenomenon in gliomas of astrocytic lineage, and must clearly detract from the prognostic value of the grading system. Even if these two variables—the sampling factors and the possibility of subsequent anaplastic change—are discounted, the practical problem remains of correlating the histologic picture with the predicted clinical behavior. In practice, grading can in this sense perhaps least uncomfortably be applied to the astrocytomas, but in regard to the oligodendrogliomas it has been repeatedly observed that the cytologic appearances may bear little relationship to their subsequent clinical evolution. As for the ependymomas, high grades of malignancy are so rare that their grading may have little practical significance. Even with astrocytomas, difficulties in applying strictly and consistently the cytologic and histologic criteria clearly laid down by Kernohan and Sayre often arise in practice because the differences between a grade 2 and a grade 3 astrocytoma are of much greater import than any between grades 1 and 2 or between grades 3 and 4. In fact the latter behave for practical purposes like glioblastomas and are often classified as such. From the statistical point of view, grading alone fails to take into account the topography of the tumor, a factor which not only is of obvious importance in regard to its surgical accessibility and its chances of complete extirpation, but also has long been known to be consistently associated with a particular biologic behavior. Thus it is to be expected that most grade 1 astrocytomas would be localized in the cerebellar hemispheres or the hypothalamic region of children and young subjects, and most grades 3 and 4 astrocytomas in the cerebral hemispheres of adults. In summary therefore and with the foregoing reservations in mind, any worthwhile attempt at grading must necessarily be restricted to tissue examined at autopsy or to widely sampled biopsy material.

The classification adopted in this fascicle is therefore a modification of the original scheme of Bailey and Cushing and, with one relatively minor change, the same as the one proposed elsewhere (Russell and Rubinstein). The only change is a crisper separation of the choroid plexus tumors from those arising from the ependyma. The reasons for this will be mentioned on page 257. Because of the widespread use of the Mayo Clinic system of grading, the appropriate grading will be mentioned where relevant in the list of synonyms that identifies each tumor entity.

MIXED TUMOR CELL POPULATIONS. Our scheme of classification, like that of neoplasms elsewhere in the body, is based on the morphologic characteristics of the prevalent cell components. In the tumors of the glioma group, however, the presence of mixed tumor cell populations often presents difficulties that may defy attempts at classi-

fication and prognosis. Aside from the problems of dedifferentiation and anaplasia already mentioned, it is found that in practice three forms of cell mixtures may be encountered. In one group of tumors it involves solely the gliogenous elements: these are the mixed gliomas. In a second group both neuronal and glial cell forms appear to participate in the neoplastic process: these are the gangliogliomas. In a third group both gliomatous and sarcomatous cells are found in contiguity or closely intermingled: these are the mixed gliomas and sarcomas. The morphologic problems presented by brain tumors with these cell populations have been discussed in detail elsewhere (Russell and Rubinstein; Rubinstein, 1964) and will be illustrated in the appropriate sections of this fascicle.

The existence of cerebral tumors in man composed of mixtures of adult cells distinct from the phenomenon of anaplasia is, not surprisingly, supported by experiments on the topical application of carcinogenic agents for the artificial production of gliomas and sarcomas. Observations on neoplastic cells in **tissue culture** are also relevant to problems of tumor classification and behavior. The technics, findings, and scope of the tissue culture approach to tumors of the central nervous system are described in detail in other publications (Lumsden; Kersting), but a short reference to the significance of its contributions is warranted in this introduction.

Tissue culture emphasizes the more dynamic aspects of cell growth and differentiation, and brings to light the modulations and reversible changes of form that characterize the response of the living cell to environmental influences. Many of the distinguishing characteristics of nervous tissue cells, such as their cytoplasmic processes, are intensified in tissue culture. It is in the context of the cytologic mechanisms which influence the development of morphologic characters that tissue culture has, not unexpectedly, proved to be most useful. In some cases it has cast a light on histogenetic issues that remained controversial or unsolved by conventional technics. Thus it convincingly established the distinction between Schwann cells and fibroblasts well before the advent of the electron microscope. Interpretative differences exist, however, among tissue culturists on the significance of their observations that have a bearing on many other cytogenetic problems in need of resolution. Thus, according to Kersting, tissue culture has confirmed the validity of the cytogenetic classification of Bailey and Cushing, upheld the separate identity of the glioblastoma multiforme, and endorsed the existence of mixed or composite gliomas, and of mixed gliomas and sarcomas. Lumsden, on the other hand, while accepting that tissue culture observations corroborate a cyto-descriptive approach to the morphologic structure of brain tumors, feels that the considerable plasticity of cell forms is in support of a system of grading in ascending degrees of malignancy. Disagreement exists also on the cytogenesis of the pilocytic astrocytomas of the cerebellum, the so-called polar spongioblastomas, and the medulloblastomas. Interestingly it seems that in contrast to its occurrence *in vivo*, true cellular dedifferentiation—as opposed to "disorganization" or "simplification"—does not play an important role in the evolution of human gliomas that have been sampled for culture.

GENERAL BIOLOGIC CHARACTERISTICS

The distinction between **benign** and **malignant** neoplasms is considerably less trenchant in tumors of central neurogenic

origin than in those that arise in other systems. Aside from the fact that its intracranial or intraspinal location converts any expanding space-occupying mass into a clinically malignant lesion, the criteria usually set for the definition of malignancy often break down when applied to the gliomas. Even the well demarcated and histologically differentiated neoplasms, such as most ependymomas and the choroid plexus papillomas, lack a capsule. Many infiltrating tumors, such as the diffuse cerebral astrocytomas and the oligodendrogliomas, may be slowly growing and relatively benign histologically. The most malignant, the glioblastoma multiforme, is often grossly circumscribed; yet microscopic examination usually discloses a more extensive infiltration than was at first suspected, and fatal recurrence within a matter of months is virtually invariable. Even the relatively benign cerebellar astrocytoma often shows a narrow zone of infiltration into the adjacent brain, and the slowly growing juvenile astrocytoma of the third ventricle is to be regarded as clinically malignant because of its inaccessible location despite its usually differentiated histologic picture. Finally, although metastasis through the cerebrospinal fluid pathways is a frequent complication in the less differentiated gliomas, distant dissemination outside the central neuraxis is a rare event, virtually always subsequent to previous operative procedure.

It is therefore to be expected that the clinical behavior of these tumors cannot always be foretold from their morphologic character. Nevertheless it is safe to assume that any glioma which combines in its histologic picture the features of dense cellularity, cytologic pleomorphism, primitive appearance, abundant mitotic figures, and spontaneous necrosis will behave clinically with a corresponding degree of malignancy.

If a predominantly **expansive** type of growth, only compressing but not infiltrating the contiguous brain, is an important criterion for the diagnosis of a benign tumor, then only the ependymomas and the choroid plexus papillomas, if they are included among the gliomas, are truly benign. The great majority of gliomas, including astrocytomas, glioblastomas, oligodendrogliomas, and medulloblastomas, show some evidence of **diffuse** infiltration of the adjacent tissues, often extensive. They grow therefore by a combination of expansion and infiltration. The most extreme example of diffuse growth is the condition of gliomatosis cerebri, in which a neoplastic change appears to have occurred in the neuroglial elements throughout widespread areas, including not only the cerebrum but in some cases the cerebellum and brainstem as well.

These tumors often possess features that seem to corroborate the view held by Willis and many others that neoplastic transformation may take place concurrently or consecutively over a definite "field." In such a predisposed field, multifocal neoplastic change is then subsequently overtaken by an accelerated and more aggressive phase of growth. Support for this concept is gained from the occasional occurrence of **multicentricity** in malignant gliomas. This is most often demonstrated in anaplastic astrocytomas and glioblastomas (figs. 35, 57). In most cases multifocality manifests itself by the presence of one or more small foci of satellite growth a few centimeters away from the margin of the main tumor mass. In a few, two or more sizable distinct gliomas are found occupying different lobes or hemispheres. In our experience multifocality can be demonstrated microscopically in 6 percent of gliomas of the astrocytic series, and widely separated multiple gliomas in 2.5 percent. This figure closely

agrees with those of Willis and of Batzdorf and Malamud. In the Mayo Clinic series the incidence of multiple gliomas was 4.9 percent (Moertel).

The concept of multicentricity may be extended to account for the presence within a diffusely infiltrating glioma of multiple discontinuous foci of increased cellularity and anaplasia. Here the process has progressed one step further and presumably heralds the next phase, in which growth becomes frankly invasive and destructive of tissues. This progress has been well illustrated by Bodian and Lawson in connection with the diffuse astrocytoma of the pons in children and follows logically from the ideas of Scherer.

The contributions of Scherer on the **patterns of growth and spread** of gliomas, particularly the cerebral astrocytomas, are of crucial importance for the understanding of the process of expansion and infiltration in these neoplasms, and have shed considerable light on the relationship that exists between the morphologic features of the diffuse tumors and the environmental influences determined by the host. His conclusions appear applicable to many glioblastomas, anaplastic cerebral astrocytomas, oligodendrogliomas, and medulloblastomas.

In describing the various patterns of growth that may be adopted by different glioma types, Scherer introduced the terms "primary," "secondary," and "tertiary" structures. The term **primary** or **proper** structures designates those patterns of growth that occur in gliomas irrespective of their situation and are therefore not subject to environmental modifications by the host. They consist for example in the rosettes of ependymomas, the palisading arrangements of the rare polar spongioblastoma, the pseudopalisades of glioblastomas, and the perivascular pseudorosettes of astroblastomas. These formations are therefore intrinsic to the glioma, and have been found in the artificial conditions of tissue culture. They do not by themselves imply any biologic significance beyond that which their recognition will confer.

Of greater biologic importance are the **secondary** structures, defined and extensively described by Scherer as dependent on the preexisting nerve tissue elements. An important group consists of increased concentrations of tumor cell aggregates along the interfaces of the brain parenchyma and around the neurons. These subpial, subependymal, perivascular, and perineuronal structures may be detected well beyond the confines of the main tumor mass and often seem to herald the growing margins of the neoplasm. Another type of secondary structure is produced by the alterations imposed on the growing tumor by the presence of preexisting nerve fibers (perifascicular, intrafascicular, and interfibrillary structures). These determine the fusiform, or polar, shape of the neoplastic cells when they infiltrate the long fiber tracts as in the corpus callosum, internal capsules, and ventral portion of the brainstem.

These different secondary structures and forms of spread are illustrated in the appropriate sections of this fascicle. Their importance is fourfold: First, they are invariably associated with tumors originating from the intrinsic elements of the central nervous system—which in this context include the microglia as well as the neuroglia. The secondary structures that particularly result from the cell aggregates at the interfaces of the brain parenchyma represent indeed a mode of spread which is morphologically quite distinct from the characteristi-

cally irregular invasion of the neuraxis by other neoplasms. Carcinoma or sarcoma may of course extensively encroach upon the superficial layers of the cortex, but infiltration is then essentially secondary to tumor permeation of the overlying leptomeninges, and its jagged pattern is evidently the result of the penetration, at various points of the pia-glial membrane, by neoplastic cells growing in the subarachnoid or perivascular spaces. Second, the secondary structures are always indicative of a generalized or partly diffuse infiltrative form of growth and are never encountered in benign ependymomas or cerebellar astrocytomas. Third, they may be of considerable diagnostic importance in the surgical biopsy of deeply situated gliomas, since their demonstration in the superficial cortex is sufficient to permit an affirmative diagnosis of underlying neoplasm. Fourth, they are of obvious theoretical interest in suggesting the possibility of neoplastic transformation of preexisting glial cells in preferential sites within the neural parenchyma.

The **tertiary** structures of Scherer comprise the changes occurring in malignant gliomas subsequent to extensive necrosis and hemorrhage, in particular the conspicuous mesenchymal reaction and cicatrization that may follow. Increased vascularization and proliferative fibrosis in the center of a necrotic glioma may lead to considerable alterations of cell structure and to a mixture of cell populations that may cause diagnostic difficulty. In the tertiary structures may be included the altered cell forms imposed on malignant gliomas when they begin to infiltrate the dura, and the secondary fibrosarcomatous changes that occasionally take place in glioblastomas.

Contrary to general belief, **focal invasion** of the **Virchow-Robin spaces** within the tumor and of the **leptomeninges** overlying it is a frequent feature of all gliomas, except the ependymomas. Again contrary to general belief, this bears no obvious relationship to the intrinsic malignancy of the neoplasm. Although characteristic of many if not most medulloblastomas, it is seen very frequently in benign astrocytomas originating in the cerebellum or from the walls of the third ventricle in children, and in optic nerve gliomas. It is often a local phenomenon and does not appear to be related to any propensity for metastasis through the cerebrospinal fluid pathways. It may be accompanied by a vigorous proliferative connective tissue reaction on the part of the meningeal fibroblasts, which will be illustrated under various tumor entities to be described. On the other hand, invasion of the ventricular ependyma by a locally infiltrating glioma appears to be of much greater importance for the production of remote metastases within the central nervous system.

Invasion of a **vascular lumen** by glioma cells is an exceptional event. When it occurs it virtually always does so as a result of dural invasion. Even then permeation of a dural vein or sinus is very rare. Once it has transgressed the dura and invaded the bone and soft tissues, as it may at the local site of recurrence following previous surgery, tumor may invade the extracerebral blood vessels. Since this has been reported in a significant number of patients who developed extraneural metastases, it would seem that venous permeation should be regarded as a harbinger of distant dissemination when demonstrated at the primary site (Rubinstein, 1967).

Metastasis throughout the central nervous system by way of the **cerebrospinal fluid pathways** is a common event. Although

characteristic of medulloblastomas it has been repeatedly observed in other malignant gliomas, in particular oligodendrogliomas (Best) and glioblastomas. With the exception of extracranial optic nerve gliomas, no glial neoplasm is exempt from this possible complication. Thus it may occasionally be encountered in benign cerebellar or third ventricle astrocytomas. Although ventricular invasion by the tumor appears essential, its friable and soft texture plays an important role in the development of this form of spread, since the most common variety of primary intraventricular glioma, the ependymoma, metastasizes only rarely in the cerebrospinal fluid pathways.

In the light of experience of the last four decades the original thesis of Bailey and Cushing that tumors of the glioma group never produce **extraneural metastases** can no longer be maintained. Many well documented examples reviewed up to 1961 by Glasauer and Yuan are now on record.

It is widely agreed on clinical and experimental grounds that the determining factor in this development is access of the tumor cells to the lymphatics or veins outside the central nervous system. Almost without exception distant dissemination has been preceded by operative procedures, often repeated. Craniotomy presumably plays a decisive role in providing this access. Many reports point to the massive extracranial encroachment of the growth through the operative defect at the time when extraneural deposits become apparent. An exceptional, example of distant dissemination that developed in the absence of surgical procedure was recorded in which the tumor, a radiated malignant astrocytoma, spontaneously transgressed the dura and was found to invade the superior longitudinal sinus (Rubinstein, 1967). As in several other reported examples with extraneural metastases, venous permeation by glioma cells was demonstrated microscopically in this case, not only at the primary site but also in the distant deposits.

Another man-made pathway of distant dissemination is provided by the increasingly frequent procedure of bypass operations for the temporary relief of obstructive hydrocephalus. Several cases are now on record in which the pleura, the peritoneal cavity, and other sites have developed metastases following the implantation of ventriculopleural, ventriculoperitoneal, and ventriculocaval shunts (Brust et al.).

Many of the well documented earlier reports of extraneural metastasis were concerned with ependymomas, in which slow growth, repeated recurrences, prolonged survival, and multiple operations were regarded as important factors in the development of this complication (Russell and Rubinstein). It is now clear that all types of glioma are liable to metastasize outside the central neuraxis following operative decompression; in fact the glioblastomas are now the most frequently recorded. In the large series of 35 cases reviewed at the Armed Forces Institute of Pathology, Smith and associates listed 23 glioblastomas and 8 medulloblastomas. All these patients had had one or more previous operations. Metastases occurred most frequently in the lungs and regional lymph nodes in glioblastomas, and in the bones and lymph nodes in medulloblastomas.

Although mechanical access to the regional lymph nodes or to the blood vessels must play a crucial role in determining the occurrence of extraneural metastasis, its relative infrequence—considering the frequency with which access to the blood vessels must be gained in the course of

craniotomy—and the fact that when it does occur secondary foci tend to be few and their distribution relatively restricted in other organ systems suggest that additional factors must militate against the successful growth of central neurogenic deposits in remote sites. The curious resistance of the lungs to the development of metastases from cerebellar medulloblastomas (Drachman et al.) and the tendency of the deposits to seed most often in the bone marrow require an explanation other than mechanical. Claims have been made that tumor cells can often be demonstrated in the bloodstream at the time of and immediately after craniotomy for intracranial gliomas (Morley), but so far these claims have not been confirmed. It is certainly intriguing that microscopic vascular permeation, when demonstrated at all, can be seen only in the extracerebral blood vessels and never within the central nervous system parenchyma. Animal experimentation also suggests that the development of gliomatous tumors outside the nervous system following the intravenous injection of tumor cells is by no means the almost invariable sequel. Even the injection of cell suspensions prepared from highly metastasizing tumors such as the rabbit Brown-Pearce and V2 carcinomas reveals a limited number of successful colonies or "metastases" compared to the number of cells injected.

Collectively, therefore, these considerations strongly suggest that factors which affect host tissue, tumor cell relationships must also play an important role in the successful development of gliomatous deposits in extraneural sites. One such factor may be time. The experiments of Shivas, who failed after 32 days to produce extraneural metastases following the intracerebral implantation of the Brown-Pearce carcinoma in rabbits, have been refuted by Greene and Harvey (1964a). These workers transplanted visceral tissues from animals bearing transplanted tumor in the brain into homologous normal animals and subsequently obtained tumor growth in the tissue transplants in all instances.

Further light on this problem may possibly be shed by the transplantation experiments being performed with both human and animal cerebral tumors. Greene has suggested that one of the reasons glioblastomas so often fail to metastasize is that, like their parent tissues, they are exceptionally poor stroma-inducers. More recently he has stressed another prerequisite as essential for the stromatization of tumors by interstitial tissue and the subsequent development of metastasis, namely the capacity of the neoplastic cell to permeate the endothelial lining (Greene and Harvey, 1964b). This endothelial binding capacity resembles the capacity of leukocytes to adhere to vascular endothelium near an inflammatory focus. According to Greene the strength of the adhesive bond varies with different tumors and with the vascular endothelium in different organs. Thus variations in the receptivity of the endothelium to tumor cells may occur in response to constitutional changes in the host, accounting for the considerable variation and lack of predictability in the formation of distant metastases in general.

Another factor may be the quality of the immune response evoked by the tumor on the part of the host. Transplantation experiments in animals have so far concentrated on two main aspects: the provision of suitable models for the *in vivo* study of human gliomas heterologously transplanted in appropriate sites, usually the brain, or the anterior chamber of the eye in guinea pigs

and rabbits (Manuelidis, 1966); and the study of local host-rejection to transplantation of animal gliomas in homologous and isologous systems.

The first group of studies has yielded mostly morphologic information. Of particular interest is the observation that tissue culture cell lines from typical human glioblastomas may occasionally, on successful transplantation into the subcutaneous tissues of cortisone-treated hamsters, acquire an epithelial appearance indistinguishable from carcinoma. This transformation was maintained when the transplants were subsequently transferred to the brains and anterior chambers of the eye of unconditioned guinea pigs (Manuelidis, 1961). The fine structure of human glioblastoma-derived tumors heterologously and serially transplanted to the guinea pig eye and brain retains its conformity to that of human neoplastic astrocytes (Herman et al.).

The second group of studies, whose ultimate objective is to develop a successful technic of **brain tumor immunization**, has led to the conclusion that, contrary to common belief, the brain does not behave as a completely immunologically privileged site in respect to homotransplantation (Scheinberg et al., 1964). In an isologous system, prior intradermal immunization with a glioma-adjuvant mixture has resulted in a marked subsequent inhibition or rejection of an intracerebrally implanted mouse glioma (Scheinberg et al., 1963).

A few experiments have also been made on human patients in whom autologous transplantation of glioma fragments was carried out in the subcutaneous tissues. So far they have yielded inconclusive results (Grace et al.). The success or failure on the part of glioma autografts to take in the subcutaneous tissues has not been correlated with the development of extracranial metastases. Certainly attempts at immunization in man by this procedure have so far been discouraging (Scheinberg and Taylor).

References

Bailey, P., and Cushing, H. A Classification of the Tumors of the Glioma Group on a Histogenetic Basis with a Correlated Study of Prognosis. Philadelphia: J. B. Lippincott Company, 1926.

Batzdorf, U., and Malamud, N. The problem of multicentric gliomas. J. Neurosurg. 20:122–136, 1963.

Best, P. V. Intracranial oligodendrogliomatosis. J. Neurol. Neurosurg. Psychiat. 26:249–256, 1963.

Bigner, D. D., Odom, G. L., Mahaley, M. S., Jr., and Day, E. D. Brain tumors induced in dogs by the Schmidt-Ruppin strain of Rous sarcoma virus. Neuropathological and immunological observations. J. Neuropath. Exp. Neurol. 28:648–680, 1969.

Bodian, M., and Lawson, D. The intracranial neoplastic diseases of childhood. A description of their natural history based on a clinico-pathological study of 129 cases. Brit. J. Surg. 40:368–392, 1953.

Brihaye, J., Périer, O., and Sténuit, J. Multiple sclerosis associated with a cerebral glioma. J. Neuropath. Exp. Neurol. 22:128–137, 1963.

Brust, J. C. M., Moiel, R. H., and Rosenberg, R. N. Glial tumor metastases through a ventriculo-pleural shunt. Resultant massive pleural effusion. Arch. Neurol. 18: 649–653, 1968.

Bucciarelli, E., Rabotti, G. F., and Dalton, A. J. Ultrastructure of gliomas induced in hamsters with Rous sarcoma virus. J. Nat. Cancer Inst. 38:865–889, 1967.

Cavanagh, J. B. On certain small tumours encountered in the temporal lobe. Brain 81:389–405, 1958.

Courville, C. B. Intracranial tumors. An appendix to the "Supplement." Bull. Los Angeles Neurol. Soc. 33:26–30, 1968.

Drachman, D. A., Winter, T. S., III, and Karon, M. Medulloblastoma with extracranial metastases. Arch. Neurol. 9:518–530, 1963.

Druckrey, H., Ivankovic, S., and Preussmann, R. Selektive Erzeugung maligner Tumoren in Gehirn und Rückenmark von Ratten durch N-Methyl-N-nitrosoharnstoff. Z. Krebsforsch. 66:389–408, 1965.

Duffell, D., Hinz, R., and Nelson, E. Neoplasms in hamsters induced by simian virus 40. Light and electron microscopic observations. Amer. J. Path. 45: 59–73, 1964.

Ferry, D. J., Hardman, J. M., and Earle, K. M. Syringomyelia and intramedullary neoplasms. Med. Ann. D. C. 38:363–365, 1969.

Glasauer, F. E., and Yuan, R. H. P. Intracranial tumors with extracranial metastases. J. Neurosurg. 20: 474–493, 1963.

Grace, J. T., Jr., Perese, D. M., Metzgar, R. S., Sasabe, T., and Holdridge, B. Tumor autograft responses in patients with glioblastoma multiforme. J. Neurosurg. 18:159–167, 1961.

Greene, H. S. N. Transplantation of human brain tumors to brains of laboratory animals. Cancer Res. 13:422–426, 1953.

———, and Harvey, E. K. Metastasis from the brain. Cancer Res. 24:1021–1027, 1964a.

———, and Harvey, E. K. Metastasis of heterologously transplanted tumors. Cancer Res. 24:1678–1687, 1964b.

Grove, A. S., Jr., Di Chiro, G., and Rabotti, G. F. Experimental brain tumors, with a report of those induced in dogs by Rous sarcoma virus. J. Neurosurg. 26:465–477, 1967.

Herman, M. M., Adams, W. R., and Manuelidis, E. E. The ultrastructure of a human glioblastoma multiforme-derived tumor heterologously transplanted to guinea pig eye and brain. Acta Neuropath. 8:321–330, 1967.

Hosobuchi, Y., and Ishii, S. A new approach to hydrocarbon-induced brain tumors. Arch. Neurol. 16:664–675, 1967.

Ikuta, F., and Zimmerman, H. M. Virus particles in reactive cells induced by intracerebral implantation of dibenzanthracene. J. Neuropath. Exp. Neurol. 24:225–243, 1965.

Ivankovic, S., and Druckrey, H. Transplacentäre Erzeugung maligner Tumoren des Nervensystems. I. Äthyl-nitroso-harnstoff (ÄNH) an BD IX-Ratten. Z. Krebsforsch. 71:320–360, 1968.

Kadin, M. E., Rubinstein, L. J., and Nelson, J. S. Neonatal cerebellar medulloblastoma originating from the fetal external granular layer. J. Neuropath. Exp. Neurol. 29:583-600, 1970.

Kernohan, J. W., and Sayre, G. P. Tumors of the Central Nervous System. Fascicle 35, Atlas of Tumor Pathology. Washington: Armed Forces Institute of Pathology, 1952.

Kersting, G. Tissue Culture of Human Gliomas, pp. 165–202. In: Progress in Neurological Surgery, Vol. 2. (Eds.) Krayenbühl, H., Maspes, P. E., and Sweet, W. H. Chicago: Year Book Medical Publishers, Inc., 1968.

Kurland, L. T. The frequency of intracranial and intraspinal neoplasms in the resident population of Rochester, Minnesota. J. Neurosurg. 15:627–641, 1958.

Lüginbühl, H. Comparative aspects of tumors of the nervous system. Ann. N. Y. Acad. Sci. 103, Art. 3:702–721, 1963.

———, Fankhauser, R., and McGrath, J. T. Spontaneous Neoplasms of the Nervous System in Animals, pp. 85–164. In: Progress in Neurological Surgery, Vol. 2. (Eds.) Krayenbühl, H., Maspes, P. E., and Sweet, W. H. Chicago: Year Book Medical Publishers, Inc., 1968.

Lumsden, C. E. The Study by Tissue Culture of Tumours of the Nervous System, Chap. 14, pp. 334–420. In: Russell, D. S., and Rubinstein, L. J. Pathology of Tumours of the Nervous System, 3d ed. London: Edward Arnold, 1971.

Manuelidis, E. E. Heterologous transplantation of two tissue culture lines of glioblastoma multiforme (TC 178 and TC 224). Proc. Soc. Exp. Biol. Med. 107: 636–639, 1961.

———. The fate of serial heterologously transplanted glioblastoma multiforme in the eye of the guinea pig. Amer. J. Path. 48:65–89, 1966.

McGrath, J. T. Intracranial pathology of the dog. Acta Neuropath., Supp. 1:3–4, 1962.

Moertel, C. G. Multiple Primary Malignant Neoplasms. Their Incidence and Significance, pp. 103–104. New York: Springer-Verlag, 1966.

Popoff, N., Sutton, C. H., and Zimmerman, H. M. Virus-like particles in reactive cells associated with crystals of implanted carcinogen. Acta Neuropath. 10:308–323, 1968.

Poser, C. M. The Relationship Between Syringomyelia and Neoplasm. Springfield, Ill.: Charles C Thomas, 1956.

Raaf, J., and Kernohan, J. W. Relation of abnormal collections of cells in posterior medullary velum of the cerebellum to origin of medulloblastoma. Arch. Neurol. & Psychiat. 52:163–169, 1944.

Rubin, R., Ames, R. P., Sutton, C. H., and Zimmerman, H. M. Virus-like particles in murine ependymoblastoma. J. Neuropath. Exp. Neurol. 28:371–386, 1969.

Rubinstein, L. J. Morphological problems of brain tumors with mixed cell population. Acta Neurochir., Supp. X:141–158, 1964.

———. Development of extracranial metastases from a malignant astrocytoma in the absence of previous craniotomy. J. Neurosurg. 26:542–547, 1967.

Russell, D. S., and Rubinstein, L. J. Pathology of Tumours of the Nervous System, 3d ed. London: Edward Arnold, 1971.

Sandbank, U. Congenital astrocytoma. J. Path. Bact. 84:226–228, 1962.

Scheinberg, L. C., Edelman, F. L., Levy, W. A., and Kotsilimbas, D. G. Is the brain 'An immunologically privileged site'? I. Studies based on intracerebral tumor homotransplantation and isotransplantation to sensitized hosts. Arch. Neurol. 11:248–264, 1964.

_____, Suzuki, K., Edelman, F., and Davidoff, L. M. Studies in immunization against a transplantable cerebral mouse glioma. J. Neurosurg. 20:312–317, 1963.

_____, and Taylor, J. M. Immunological Aspects of Brain Tumors, pp. 267–291. In: Progress in Neurological Surgery, Vol. 2. (Eds.) Krayenbühl, H., Maspes, P. E., and Sweet, W. H. Chicago: Year Book Medical Publishers, Inc., 1968.

Scherer, H. J. Structural development in gliomas. Amer. J. Cancer 34:333–351, 1938.

Shein, H. M. Neoplastic transformation of hamster astrocytes and choroid plexus cells in culture by polyoma virus. J. Neuropath. Exp. Neurol. 29:70-88, 1970.

Shivas, A. A. The behaviour of Brown-Pearce carcinoma implanted in rabbit brain. J. Path. Bact. 78:81–85, 1959.

Slooff, J. L., Kernohan, J. W., and MacCarty, C. S. Primary Intramedullary Tumors of the Spinal Cord and Filum Terminale, pp. 29–115. Philadelphia: W. B. Saunders Company, 1964.

Smith, D. R., Hardman, J. M., and Earle, K. M. Metastasizing neuroectodermal tumors of the central nervous system. J. Neurosurg. 31:50–58, 1969.

Snell, K. C., Stewart, H. L., Morris, H. P., Wagner, B. P., and Ray, F. E. Intracranial neurilemmoma and medulloblastoma induced in rats by the dietary administration of N,N'–2, 7–Fluorenylenebisacetamide. Nat. Cancer Inst. Monogr. 5:85–103, 1961.

Solitare, G. B., and Krigman, M. R. Congenital intracranial neoplasm. A case report and review of the literature. J. Neuropath. Exp. Neurol. 23:280–292, 1964.

Stroobandt, G., and Brucher, J. M. Étude de tumeurs nerveuses obtenues par l'administration de méthylnitrosourée au rat. Neurochirurgie 14:515–535, 1968.

Szepsenwol, J. Brain nerve cell tumors in mice on diets supplemented with various lipids. Path. Microbiol. 34:1–9, 1969.

Van Gilder, J. C., and Schwartz, H. G. Growth of dermoids from skin implants to the nervous system and surrounding spaces of the newborn rat. J. Neurosurg. 26:14–20, 1967.

Willis, R. A. Pathology of Tumours, 3d ed. London: Butterworth & Co., Ltd., 1960.

Zimmerman, H. M. The natural history of intracranial neoplasms, with special reference to the gliomas. Amer. J. Surg. 93:913–924, 1957.

Zülch, K. J. Brain Tumors. Their Biology and Pathology, 2d American ed., p. 78. New York: Springer Publishing Co., 1965.

Zu Rhein, G. M. Association of papova-virions with a human demyelinating disease (progressive multifocal leukoencephalopathy). Progr. Med. Virol. 11:185–247, 1969.

TUMORS OF NEUROGLIAL CELLS

ASTROCYTOMAS

SYNONYMS AND RELATED TERMS: Astrocytomas, grades 1 and 2. The terms 'spongioblastoma' and 'polar spongioblastoma' are sometimes applied to the supratentorial pilocytic astrocytomas of juvenile type, the diffuse pontine astrocytomas, and the cerebellar and spinal astrocytomas.

DEFINITION AND CYTOGENESIS. Astrocytomas are neoplasms derived from and composed of astrocytes showing various degrees of maturity. They differ a great deal in their gross features, microscopic appearances, and biologic behavior. The morphologic variation is not surprising if we recall the different structural forms which may be adopted by the normal and reactive astrocytes.

In the normal brain, astrocytes in the middle layers of the cortex and in the basal ganglia are protoplasmic; that is, their processes form delicate frondlike arborizations, and by light microscopy they do not possess intracytoplasmic neuroglial fibrils. In the superficial and deep cortical layers and in the white matter, the astrocytes are fibrillary; that is, their processes are straighter and they contain fibrils. Although most electron microscopists accept the distinction between protoplasmic and fibrillary astrocytes, the presence of intracytoplasmic glial filaments measuring from 80 to 90 angstroms in diameter is characteristic of both forms, and indeed constitutes one of the criteria for the recognition of astrocytes at the fine structural level (Peters et al.). Most astrocytes are stellate, or star-shaped, but those attached to the pia or situated beneath the ependyma and in the Purkinje cell layer of the cerebellum—the Bergmann glia—are fusiform, or polar. In nonneoplastic processes, protoplasmic astrocytes rapidly become fibrillated. In addition fibrillary gliosis in the nervous system often causes the laying down of long parallel fibers along the nerve fiber tracts. As a result reactive astrocytes may become thinned, elongated, and bipolar; hence the term piloid, or pilocytic, which means hairlike.

Many reactive astrocytes also become enlarged, and the prominent cytoplasmic volume resulting thereby appears intensely eosinophilic in hematoxylin and eosin sections. Because the cells appear distended, the term "gemistocytic" (from the Greek, to fill) is often applied. They are sometimes erroneously referred to as protoplasmatic: in fact they always contain conspicuous neuroglial fibrils, but the latter tend to be situated at the periphery of the cell and in its processes. They are also sometimes thought to be degenerating forms; in reality they show considerable metabolic activity, as is readily demonstrated by their intense reductase activity with histochemical tetrazolium technics. With the electron microscope the eosinophilic cytoplasm is packed mostly with clusters of ribosomes, many mitochondria, and a few osmiophilic membrane-bound bodies; glial filaments are readily demonstrated at the periphery of the perikaryon and in the cell processes.

CLASSIFICATIONS. Various classifications are used to separate the astrocytomas. Some of these are entirely cytologic and reflect the morphologic variations of the normal and nonneoplastic astrocytes previously described. Thus astrocytomas have been listed as **protoplasmic, fibrillary, piloid** or **pilocytic,** and **gemistocytic.** However, these different cell forms are often intermingled or contiguous with one another within the same neoplasm. Thus benign cerebellar astrocytomas are almost invariably composed of both fibrillary and protoplasmic astrocytes, and these can be either pilocytic or stellate. Foci of gemistocytic astrocytoma are not uncommonly found among the widely infiltrating zones of a diffuse anaplastic astrocytoma.

Astrocytomas show various degrees of cytologic malignancy, which is explained by the progressive anaplasia, or dedifferentiation, of the mature astrocytic cell in the course of neoplastic transformation. Since it is possible to find every stage of anaplasia, which in extreme cases may become indistinguishable from the picture of glioblastoma multiforme, astrocytomas have been classified by Kernohan and Sayre in ascending grades of malignancy from 1 to 4. In this section, however, aside from the malignant variant of astrocytoma to be described below, we are solely concerned with the grades 1 and 2 of the Mayo Clinic classification. The astrocytomas grades 3 and 4 are equated with the malignant astrocytoma and the glioblastoma.

Finally it is possible to separate the astrocytomas into fairly well defined clinicopathologic entities, in which a particular localization in the brain is generally associated with a prevalent age incidence, a readily recognizable microscopic picture, and a fairly predictable biologic behavior. Thus we can classify them into the diffuse cerebral astrocytoma of adults, the solid and cystic cerebellar astrocytomas of children, the juvenile pilocytic astrocytomas of the third ventricle, hypothalamus and chiasm of children and young subjects, the diffuse pontine astrocytomas of children, and the astrocytomas of the spinal cord. In the present fascicle it is proposed to adopt this general classification, with an indication of the most frequent cytologic grading to be attached to the various localizations, and with a separate consideration of the malignant or dedifferentiating astrocytoma. We shall also describe a few separate cytologic variants that deserve special recognition because of their characteristic morphologic features.

INCIDENCE. In clinical series, astrocytomas constitute about 25 to 30 percent of all cerebral gliomas. Cerebellar astrocytomas form about 8 percent of all gliomas, but constitute about 30 percent of gliomas in children.

Astrocytomas may arise at any age. However, a characteristic age incidence frequently attaches to them in specific sites in the brain. Thus in the cerebral hemisphere they most frequently give rise to symptoms in adults in the third and fourth decades. Those in the hypothalamic region, cerebellum, and pons are most often harbored in children and adolescents. Exceptions to these rules exist, however. For example, in the cerebellum the juvenile type accounts for more than 80 percent of the astrocytomas and arises in early life; the mean age in this group is nine years. But the diffuse type in the same situation tends to occur in adults and the mean age is 24. Men are affected more than women.

CLINICAL DATA AND NATURAL HISTORY. The astrocytomas are usually slowly growing tumors. Some in the cerebral hemispheres may begin with the insidious onset of focal epilepsy, which may be controlled with anticonvulsants for many years. Symptoms are often present two years before the diagnosis is established. A more recent aggravation of the clinical symptoms, with a more rapid impairment of motor or sensory modalities and evidence of increased intracranial pressure are often an indication of an accelerated rate of growth accompanied by the appearance of cytologic malignancy. Although cerebral astrocytomas in adults may remain histologically benign, many undergo dedifferentiation in the course of months or years, with the terminal histologic picture of glioblastoma multiforme.

In the cerebellum the signs and symptoms are those of a posterior fossa tumor; the rapid expansion and filling of a large cyst may cause a swift acceleration of symptoms referable to that region. Although they may recur, most of these astrocytomas remain histologically benign. Occasionally, especially in the older age groups, they may display the same tendency toward dedifferentiation as the supratentorial examples.

In the third ventricle astrocytomas of juvenile type, there may be a long clinical history of hypothalamic symptoms, including diabetes insipidus, obesity, bulimia, or extreme emaciation. These tumors usually grow very slowly and remain histologically benign.

In the pontine gliomas the most prominent early symptoms are due to involvement of the cranial nerve nuclei and the long nerve fiber tracts. Signs of increased intracranial pressure are usually late, and may result from focal anaplastic changes in the tumor, which are frequent. The clinical picture at first often mimics that of a subacute brainstem encephalitis.

ASSOCIATED CONDITIONS AND MULTIPLICITY. The pilocytic astrocytoma of the hypothalamic or chiasmatic regions is sometimes associated with the central form of von Recklinghausen's neurofibromatosis. The latter condition often accompanies astrocytomas of the optic nerve (these are treated separately in detail in the fascicle, "Tumors of the Eye and Adnexa"). Very rarely the central form of neurofibromatosis is associated with a diffuse type of cerebellar astrocytoma that shows a marked propensity to infiltrate the leptomeninges. The subependymal giant cell astrocytoma is characteristically associated with tuberous sclerosis (pp. 40, 301). In a significant proportion of cases, astrocytomas of the spinal cord have been associated with syringomyelia (Poser).

Astrocytomas are usually single, but the concurrent or consecutive development of multiple tumors has occasionally been reported, sometimes involving both the cerebral and cerebellar hemispheres (Solomon et al.).

GROSS. **Diffuse cerebral astrocytomas**, as their name implies, involve the cerebral hemispheres and are diffuse and ill-defined, pinkish gray when fresh, and whitish or pale gray when fixed. They widely infiltrate the central white matter, cortex, or basal ganglia. There is no obvious demarcation between tumor and the adjacent brain (fig. 1). When the cortex is invaded, the boundary between gray and white matter is lost, and the cortex may appear either thinned or occasionally abnormally wide. When a basal ganglion is infiltrated it may seem enlarged, and the normal anatomic markings are indistinct or absent

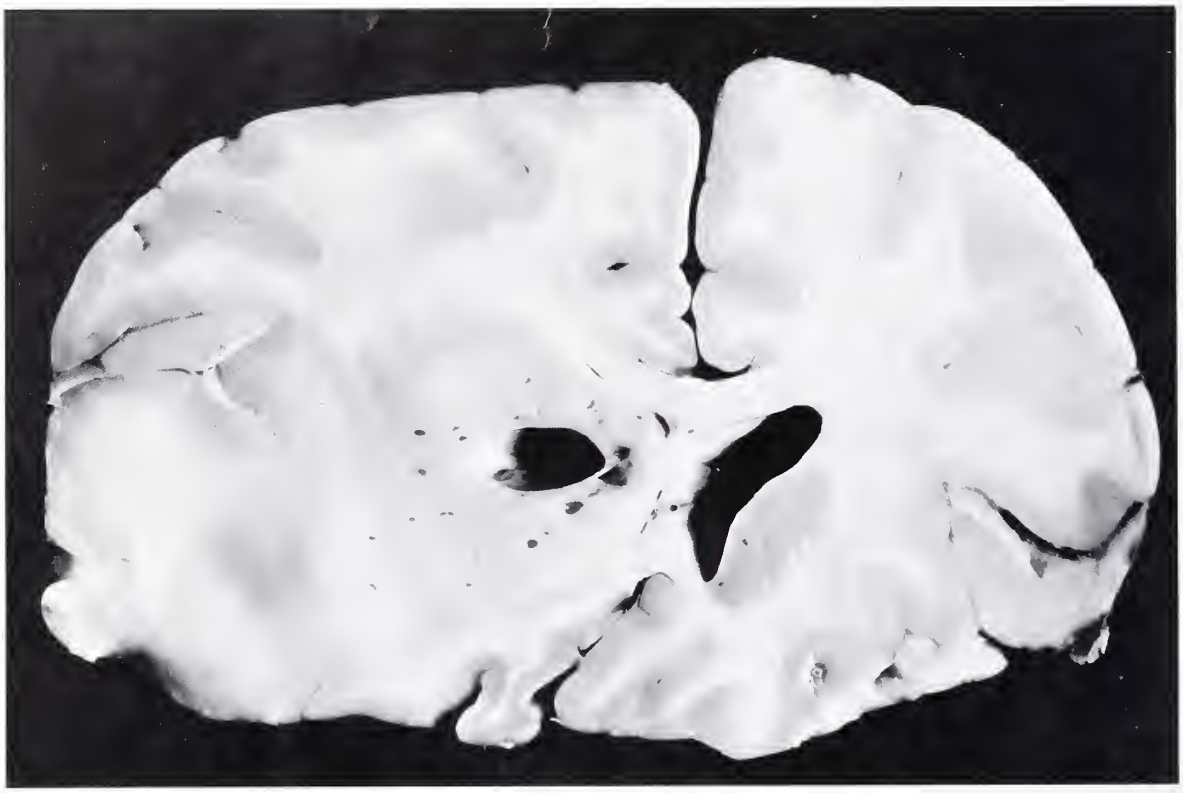

DIFFUSE CEREBRAL ASTROCYTOMA

Figure 1. This diffusely infiltrating left frontal astrocytoma shows focal cyst formation. Note absence of boundary from normal brain and infiltration of inferior frontal and lateral orbital cortex, with loss of demarcation between gray and white matter. (Courtesy of the Armed Forces Institute of Pathology).

(fig. 28). The texture of the tumor is usually abnormally firm, since most of them are fibrillary. Protoplasmic and gemistocytic astrocytomas have a softer, almost gelatinous or slightly granular consistency, with grayish homogeneous cut surfaces, and they are usually somewhat better circumscribed. Small cysts are often found in diffuse cerebral astrocytomas (fig. 1). Large cysts rarely develop.

Some of the cerebral astrocytomas are much better defined and may resemble in gross appearance as well as histologically the cerebellar astrocytomas of children and young subjects. The cut surfaces are dark gray when fixed and homogeneous. The tumor may appear intensely vascular, even hemorrhagic. It may be solid or cystic; the cysts may be large. One variety, the **piloid astrocytoma of juvenile type**, characteristically arises in the floor or walls of the third ventricle, and may present as a large suprasellar mass that displaces and compresses the optic chiasm and nerves (frontispiece; fig. 2). The cut surfaces are usually dark gray when fixed, often with focal hemorrhages (fig. 3). Cysts of various sizes may be present. These tumors appear circumscribed in most places, but usually infiltrate the hypothalamic and chiasmatic regions.

JUVENILE ASTROCYTOMA ARISING IN THE HYPOTHALAMIC REGION

(Figures 2, 3, and 16 from same case)

Figure 2. This massive tumor occupies the floor of the third ventricle in a 9-year-old boy with a clinical history referable to hypothalamic symptoms for six years. Note the marked compression of the optic chiasm.

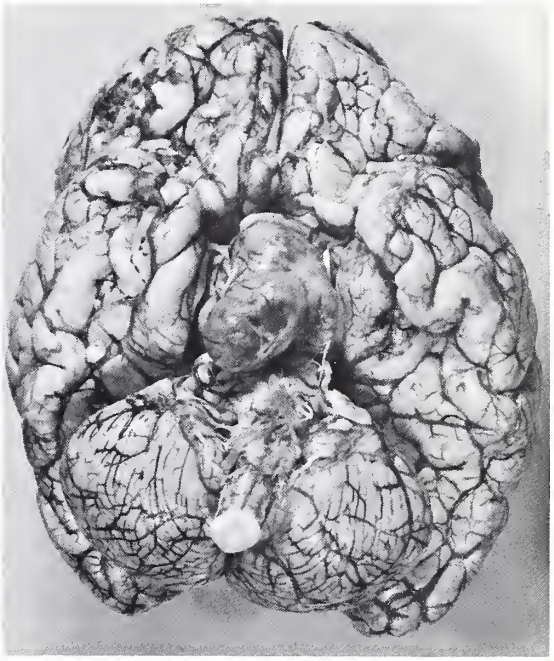

Fig. 2

JUVENILE ASTROCYTOMA ARISING IN THE HYPOTHALAMIC REGION

(Figures 2, 3, and 16 from same case)

Figure 3. This midsagittal section of the tumor demonstrates a large mass anterior to the pons. It is well circumscribed in most places except for infiltration of the hypothalamus. It is mostly solid, focally hemorrhagic, and cystic in its most dependent portion. There is slight dilatation of the ventricular system.

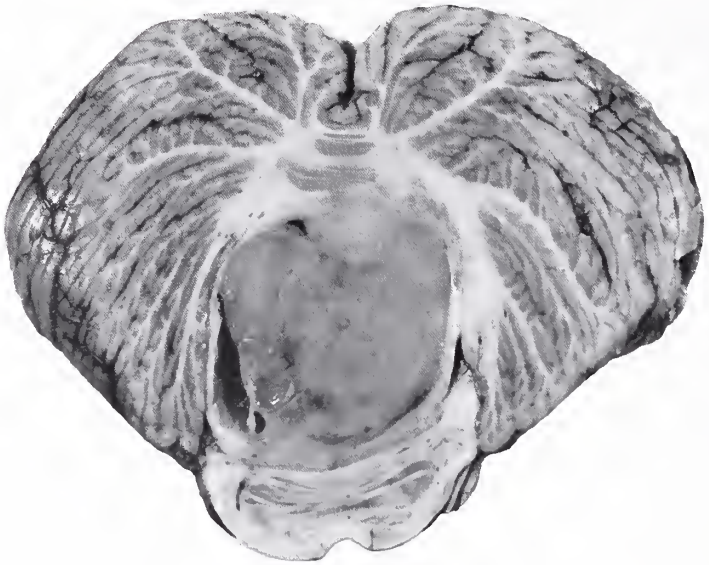

SOLID CEREBELLAR ASTROCYTOMA

Figure 4. This largely solid midline astrocytoma arises from the lingula and virtually completely fills the fourth ventricle in an 11-year-old boy. Note a small cyst in the lower left part of the tumor adjacent to the ventricle. The cut surface is gray and homogeneous.

In the **cerebellum** astrocytomas arise either in the lateral lobes or in the vermis; many examples involve both. Occasionally the tumor is largely intraventricular (fig. 4). It may either be largely solid, with a homogeneous fleshy gray cut surface when fixed (fig. 4) that reveals small cysts and a few hemorrhagic zones, or it may essentially be a large cyst that contains a small mural tumor nodule. The nodule may appear intensely hemorrhagic (pl. I-C). The wall of the cyst may consist of poorly cellular, often degenerated tumor, or include a layer of reactive nonneoplastic cerebellar tissue or part of the ependymal ventricular lining. Both solid and cystic forms tend to be well circumscribed. A minority, usually in the older age groups, are more diffuse and resemble the infiltrating cerebral astrocytomas of adults.

The **pontine astrocytomas** of children characteristically present as a gross, usually symmetrical, nodular enlargement of the pons and medulla with increased grooving of the ventral pontine surface produced by pressure from the basilar artery and its branches (pl. I-A). On midsagittal section the pons and frequently the midbrain and medulla are extensively replaced by a diffuse whitish or pale gray tumor that causes marked elongation of the aqueduct and floor of the fourth ventricle, and bulges smoothly into the latter. Occasionally the neoplasm extends laterally and invades the cerebellar white matter diffusely from the middle cerebellar peduncle. Much of the texture of the tumor is uniform and tough, but dark gray zones of granular or almost gelatinous consistency with hemorrhagic foci are often found in the central portion (pl. I-B). A tongue of tumor may extend ventrally into the subarachnoid space, surrounding and obscuring the basilar artery.

PONTINE ASTROCYTOMA

(Plate I-A and B from same case)

A. This ventral view of a brainstem astrocytoma in a 10-year-old boy shows diffuse nodular enlargement of the pons and medulla with increased markings of the ventral surfaces by the basilar artery and its branches.

PONTINE ASTROCYTOMA

(Plate I-A and B from same case)

B. This midsagittal section reveals an extensive dark gray and hemorrhagic dedifferentiated area that microscopically showed the picture of glioblastoma multiforme. The tumor bulges smoothly into the floor of the fourth ventricle and the latter is obliterated.

CYSTIC CEREBELLAR ASTROCYTOMA

(Plate I-C and Figures 11 and 24 from same case)

C. Note the intensely hemorrhagic mural nodule in a largely cystic cerebellar astrocytoma in a 17-year-old boy. The displaced fourth ventricle is compressed by the cyst into a narrow slit. The inferomedial portion of the cyst wall consists therefore partly of ependyma. (Courtesy of Dr. J. E. Olvera-Rabiela, Mexico City, Mexico; also fig. 1 from Rubinstein, L. J. Seminario de Neuropatologia, Mérida, Yucatán, Bol. Asoc. Mex. Patol., A. C. 7:13–59, 1969)

ASTROBLASTOMA

D. This well defined homogeneous frontal lobe tumor occurred in a 12-year-old boy and is separate from the lateral ventricle. (Courtesy of Dr. A. A. Miller, Preston, England)

PLATE I

The astrocytomas of the **spinal cord** consist in fairly circumscribed fusiform swellings of the cord that occur most frequently in the thoracic and cervical segments. Their extreme elongation has occasionally caused them to be called "pencil gliomas." The cut surfaces are usually firm, homogeneous, and grayish white.

MICROSCOPIC. The **diffuse cerebral astrocytomas** are characterized by an infiltration of the gray or white matter, or both, by widely dispersed small astrocytic cells. The cellular density may only slightly exceed that of the normal brain (fig. 5). The nuclei are usually slightly larger and more irregular than normal and may show mild hyperchromatism. Mitotic figures are usually scant. The capillary blood vessels may be a little more prominent than normal (fig. 5), but do not show endothelial proliferation unless the tumor begins to undergo anaplastic changes. Fibrillated cell processes and neuroglial fibrils can be demonstrated with the appropriate stains (fig. 6; pl. II-A). Silver carbonate preparations for astrocytes (fig. 7) display these processes in a dramatic manner: the cell outlines are shown by this method to be larger and to possess more processes than normal astrocytes.

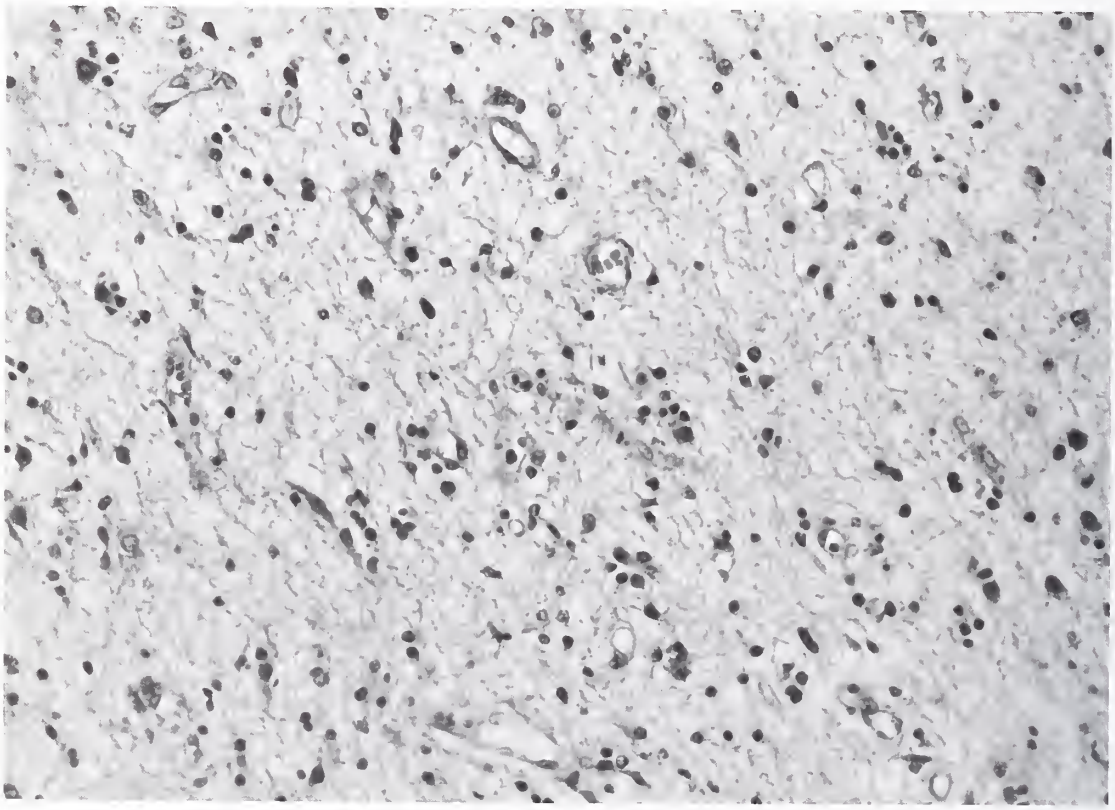

DIFFUSE FIBRILLARY CEREBRAL ASTROCYTOMA

Figure 5. This photomicrograph is from an ill-defined invasive right frontal lobe tumor in a 25-year-old woman and illustrates diffuse infiltration of the white matter by small astrocytic cells. Note the frequent capillary blood vessels. × 230. (Fig. 23 from Rubinstein, L. J. Seminario de Neuropatologia, Mérida, Yucatán, Bol. Asoc. Mex. Patol., A. C. 7:13–59, 1969).

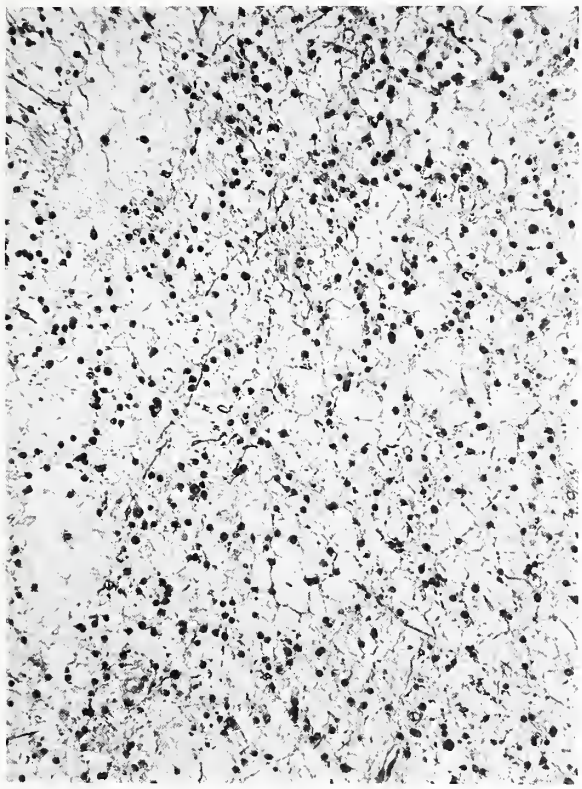

Fig. 6

FIBRILLARY ASTROCYTOMA WITH MICROCYST FORMATION

(Figures 6, 29, 74–78, and Plate XIII-D from same case)

Figure 6. Small stellate glial cells form microcysts with delicately stained neuroglial fibers in a left fronto-parietal tumor in a 37-year-old man. The tumor showed marked anaplastic changes in other areas. PTAH. × 150. (Fig. 4 from Rubinstein, L. J. Development of extracranial metastases from a malignant astrocytoma in the absence of previous craniotomy. J. Neurosurg. 26:542–547, 1967).

DIFFUSE FIBRILLARY ASTROCYTOMA

Figure 7. This silver impregnation reveals neoplastic astrocytes in a diffuse fibrillary astrocytoma infiltrating the cortex and underlying white matter. Scharenberg's modification of Hortega's triple silver carbonate method for astrocytes. × 270.

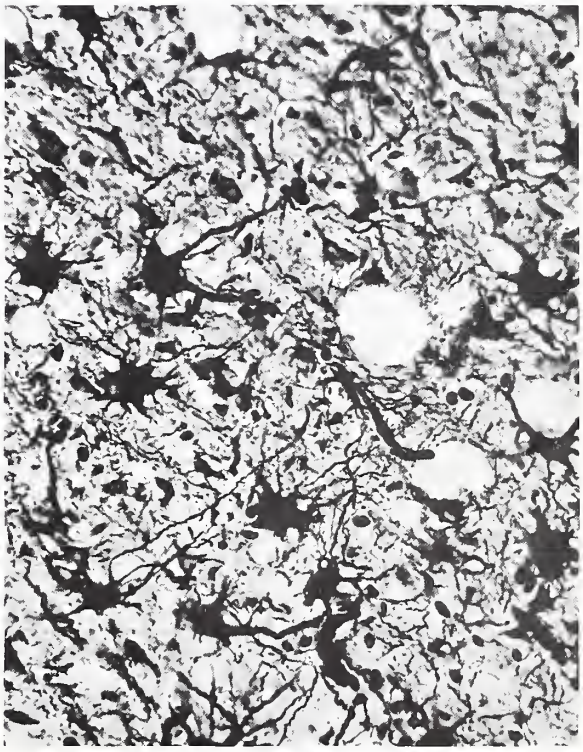

Fig. 7

However, it is difficult with silver preparations alone to distinguish reactive from neoplastic astrocytes. Fibrillary astrocytomas also tend to form small microcysts (fig. 6) that in some cases become confluent and may enlarge to produce the cysts found on gross examination. When tumor infiltrates the cortex and basal ganglia the neurons are often preserved and widely separated.

Microscopic examination of areas further afield discloses the infiltrative character of these neoplasms. In particular they are apt to demonstrate the secondary structures described by Scherer (1938, 1940) and previously referred to in the Introduction (p. 11). These formations consist of subpial aggregates of tumor cells beneath the superficial part of the molecular layer in the cerebral or cerebellar hemisphere (fig. 8) and beneath the ependyma. The aggregates may be either diffuse or nodular (fig. 9). They should not be confused with subarachnoid deposits or with foci of reinvasion that may follow leptomeningeal spread. Other secondary structures consist of perivascular accumulations of tumor cells in the neural parenchyma outside the Virchow-Robin spaces (fig. 10) or about the neurons: the latter are more commonly seen in oligodendrogliomas. Other secondary structures stem from the infiltration of major nerve fiber tracts, such as those in the corpus callosum, the internal capsule, and the brainstem. As a result the tumor cells become elongated and polar.

The grading of these diffuse astrocytomas is usually 1 or 2. There is, however, a frequent tendency toward anaplastic change with the result that some eventually fall into the grades 3 or even 4 of the Mayo Clinic classification (glioblastoma multiforme, p. 55).

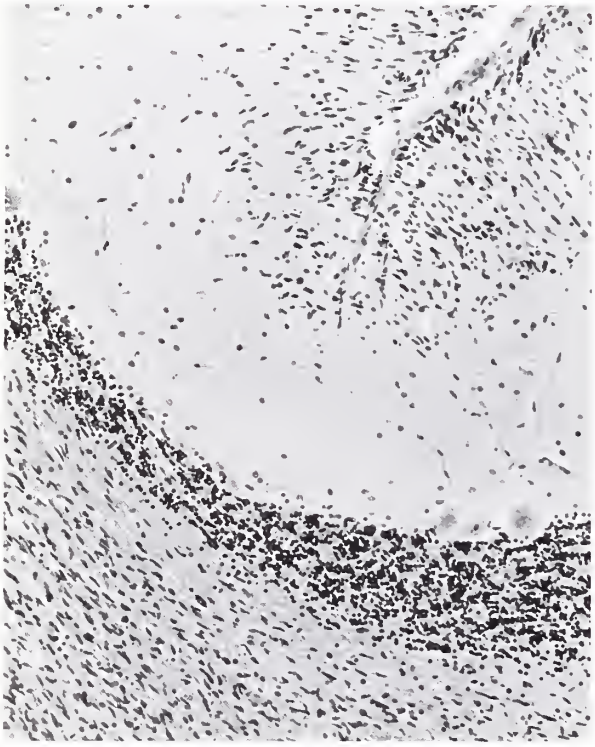

Fig. 8

SECONDARY STRUCTURES IN DIFFUSELY INFILTRATING ASTROCYTOMAS

Figure 8. Subpial aggregates of small darkly staining tumor cells infiltrate the superficial part of the molecular layer of the cerebellum. This 17-year-old boy had gliomatosis cerebri involving the cerebral hemispheres, cerebellum, and brainstem. Note the diffuse infiltration of the subcortical white matter by similar darkly staining elongated tumor cells. × 125.

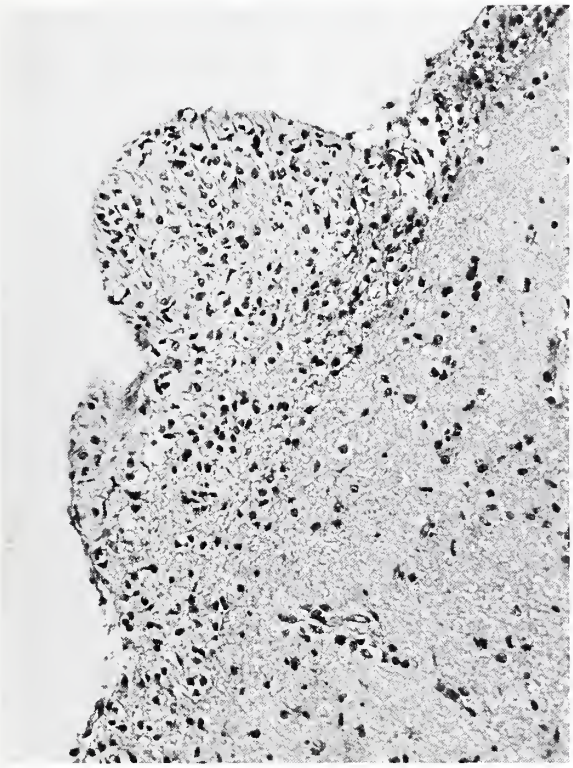

Fig. 9

SUBPIAL AND PERIVASCULAR STRUCTURES IN DIFFUSELY INFILTRATING ASTROCYTOMA

(Figures 9 and 10 from same case)

Figure 9. Nodular subpial secondary structures overlie an infiltrating parietal astrocytoma in a 12-year-old boy. × 165.

SUBPIAL AND PERIVASCULAR STRUCTURES IN DIFFUSELY INFILTRATING ASTROCYTOMA

Figure 10. This photomicrograph illustrates a perivascular accumulation of darkly staining tumor cells outside the Virchow-Robin space. × 165.

Fig. 10

PLATE II

DIFFUSE FIBRILLARY ASTROCYTOMA

(Plate II-A and C from same case)

A. This poorly cellular fibrillary astrocytoma occupied the tegmental portion of the upper midbrain in a 15-year-old boy. Numerous strongly staining neuroglial fibrils and cytoplasmic processes are present. PTAH. × 265. No. 67–5–353.

GEMISTOCYTIC ASTROCYTOMA

(Plate II-B and Figure 21 from same case)

B. This is the typical appearance of gemistocytic astrocytes. They show well stained fibrillary cytoplasmic processes. PTAH. × 350. No. 67–5–354.

INVASION OF LEPTOMENINGES BY DIFFUSE FIBRILLARY ASTROCYTOMA

C. The irregular fasciculated pattern is produced by invasion of the leptomeninges by highly fibrillated strands of glial tumor (stained blue). The lighter colored tan areas result from the proliferation of fibrous connective tissue in the leptomeninges. The poorly cellular, diffusely infiltrated midbrain is on the lower left of the photomicrograph. PTAH. × 165. No. 67–5–355.

SMEAR FROM FIBRILLARY ASTROCYTOMA

D. This smear is from an abundantly fibrillary cerebellar astrocytoma. Morris. × 400. No. 67–5–356.

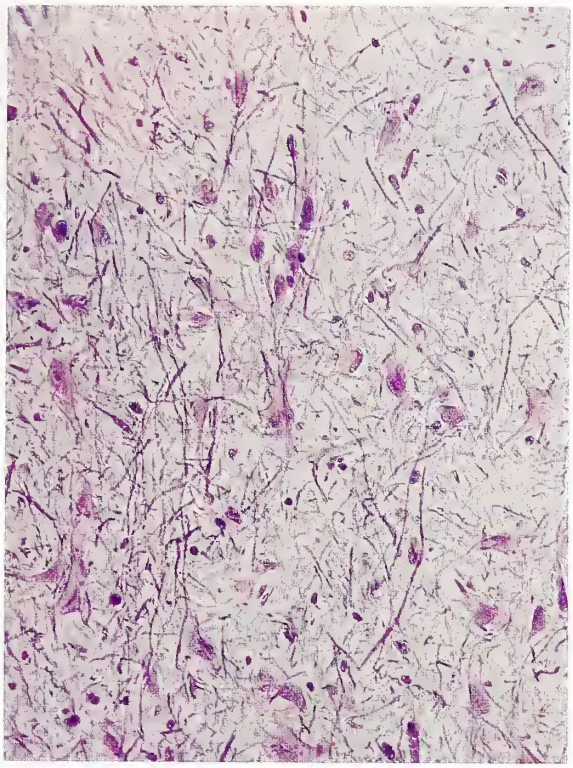

A

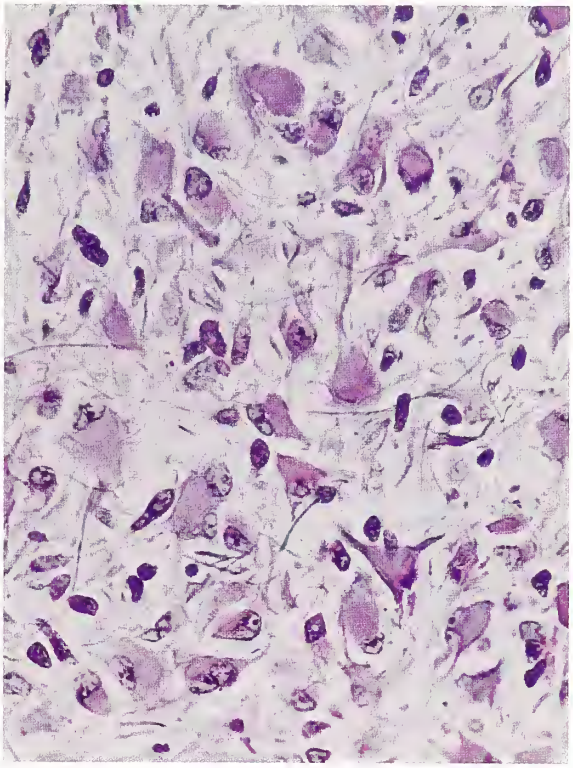

B

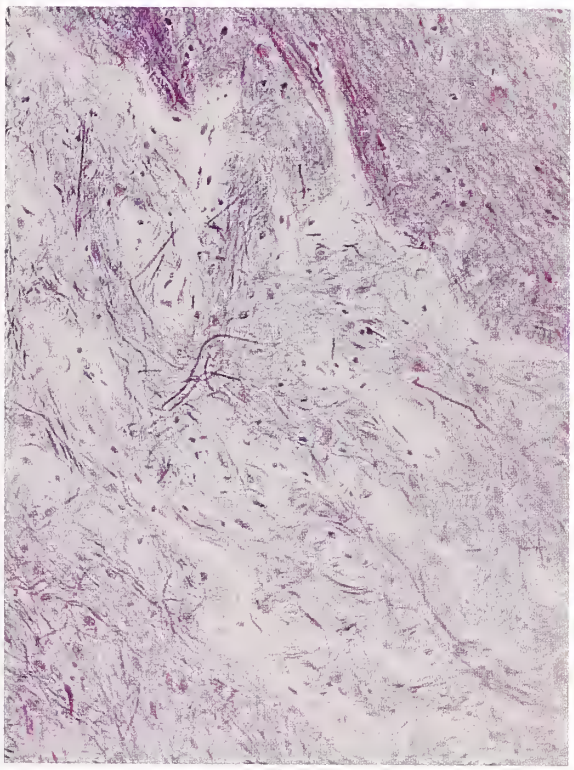

C

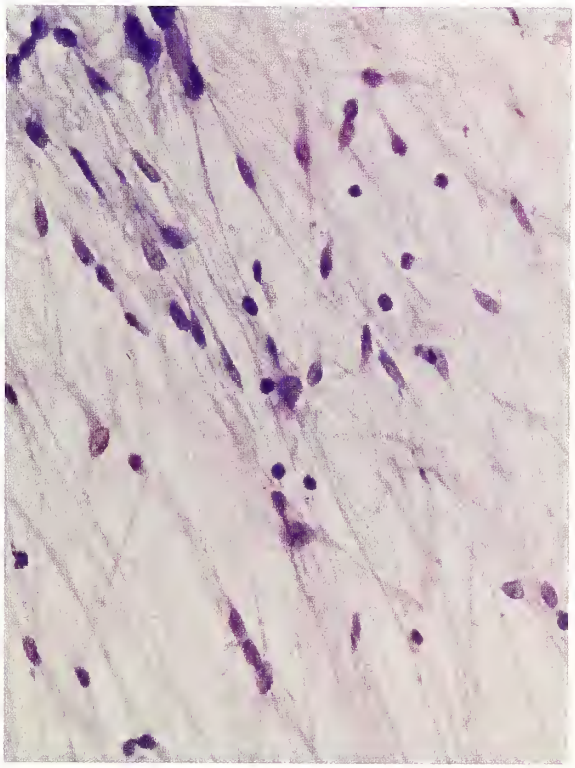

D

PLATE II

The characteristic histologic feature of the diffuse cerebral astrocytomas is their uniform appearance under the microscope. By contrast the microscopic appearances of most **cerebellar astrocytomas** under the low power vary from field to field (fig. 11). This results from the contiguity of compact areas composed of strongly fibrillated cells that are often fusiform or polar, and looser microcystic areas composed mostly of nonfibrillated stellate astrocytes that are often arranged around small cavities. The cysts contain protein-rich eosinophilic fluid (fig. 12). The fibrillated structure of the compact areas is well demonstrated in brain smears obtained in neurosurgical biopsy procedures (pl. II-D). The astrocytic nuclei are larger than normal, but usually quite regular and orthochromatic. Occasionally uninucleate or small multinucleate giant cells are seen, and some nuclei may be hyperchromatic. However, this does not connote malignancy in the absence of other evidence of anaplastic change such as increases of cellular density, necrosis, and mitotic figures. Similarly, vascular endothelial proliferation, relatively common in these astrocytomas, does not have the sinister implication that it does in the diffuse cerebral type. Mitotic figures are virtually absent. When present in any significant number they should arouse the suspicion of malignancy.

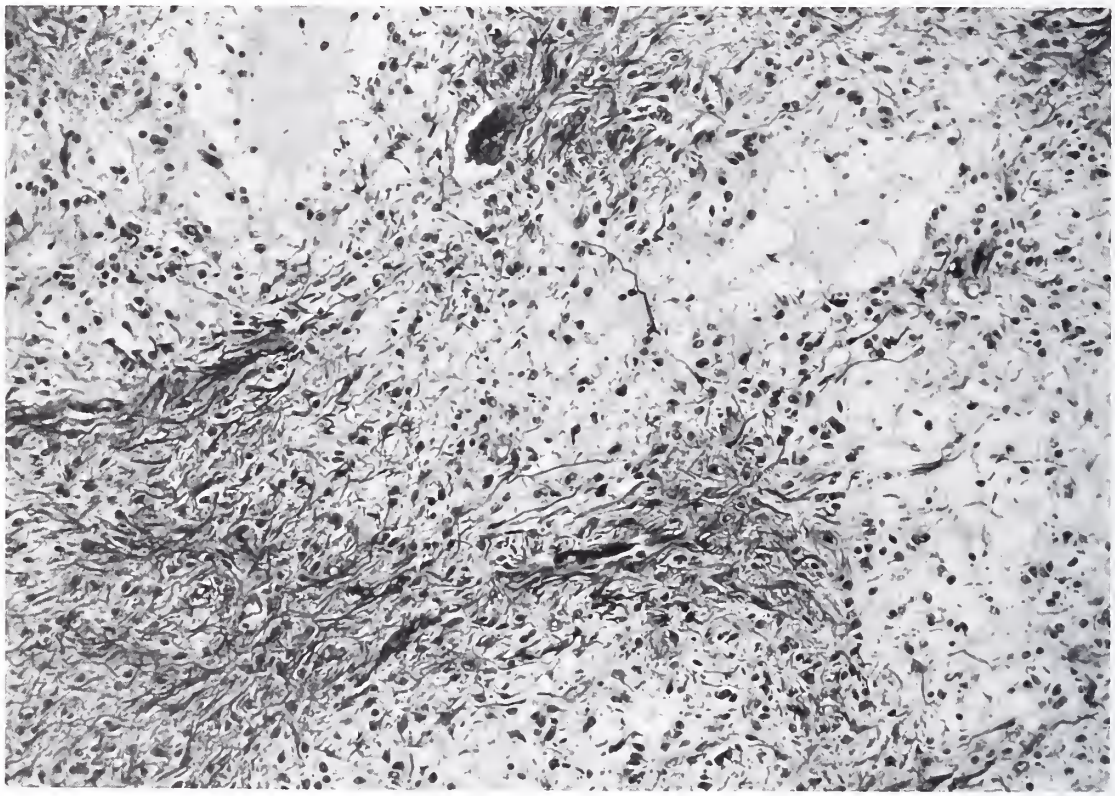

CEREBELLAR ASTROCYTOMA

(Figures 11, 24, and Plate I-C from same case)

Figure 11. Unlike the diffuse cerebral astrocytoma of adults, the histologic picture varies from field to field. Compact areas of fibrillated astrocytoma lie adjacent to looser microcystic areas. PTAH. × 180. (Fig. 2 from Rubinstein, L. J. Seminario de Neuropatologia, Mérida, Yucatán, Bol. Asoc. Mex. Patol., A. C. 7:13–59, 1969).

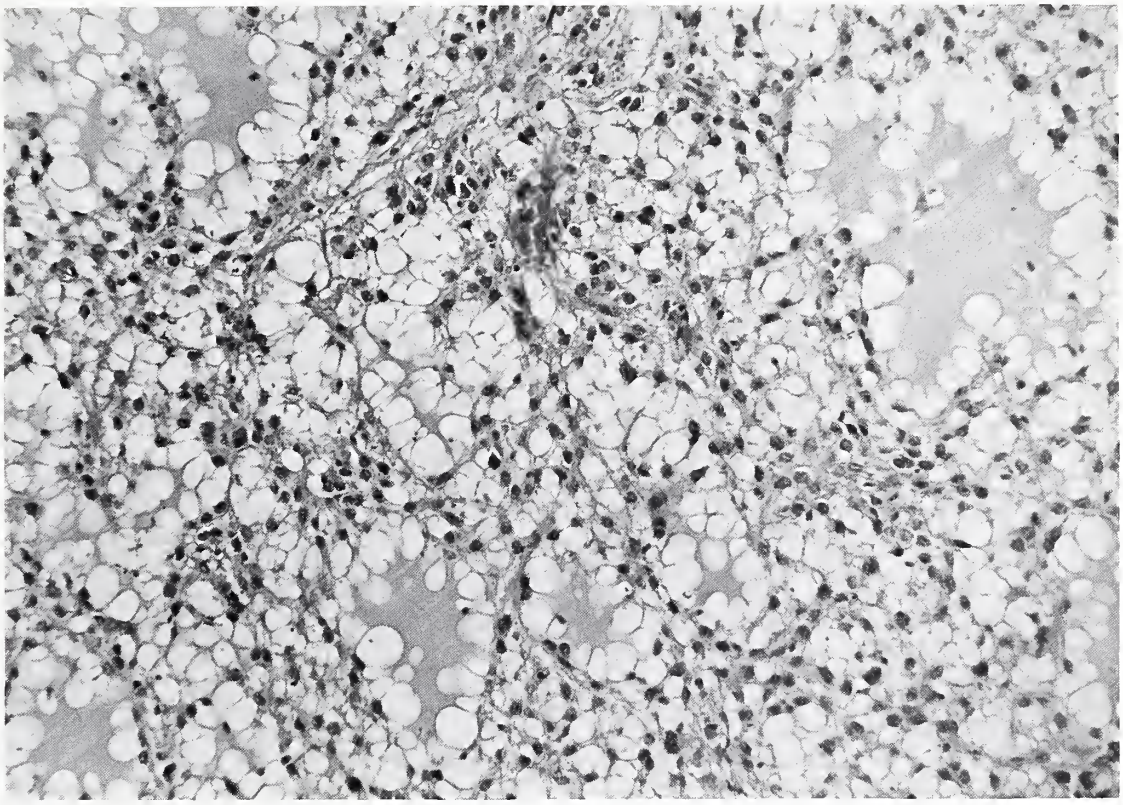

CEREBELLAR ASTROCYTOMA

Figure 12. This cerebellar astrocytoma is composed mostly of stellate protoplasmic astrocytes and includes microcystic areas. The cysts contain pale eosinophilic protein-rich fluid. × 190.

Electron microscopic studies on fibrillary astrocytomas (figs. 17, 18) stress the variations in cell outlines and agree on the characteristic presence of conspicuous bundles of glial filaments measuring 50 to 100 angstroms in diameter that occupy the perikaryon and cell processes (Luse; Duffell et al.; Raimondi).

Degenerative changes are frequent in cerebellar astrocytomas. Cells in the solid, compact, highly fibrillated areas often show an irregular swelling of their cytoplasm, with the formation of intensely eosinophilic elongated, cigar-shaped, or beaded bodies known as Rosenthal fibers (fig. 16). These are also frequently found in the pilocytic astrocytomas of the third ventricle (p. 36) as well as in the optic nerve gliomas. Another change related to the formation of Rosenthal fibers, and apparently an early form of them, is the development of small intracellular spherical droplets that become confluent to form larger granular bodies replacing the tumor cells. In addition, homogeneous and intensely eosinophilic spherical bodies measuring 20 to 40 microns, arranged singly or in clusters, may be found extracellularly; they resemble tinctorially the proteinaceous eosinophilic fluid found in the cysts. An example of this phenomenon occurring in a 41-year-old man is illustrated in figure 13. Secondary struc-

tures such as are described on pages 11 and 28 are not found in the large majority of solid or cystic cerebellar astrocytomas of childhood. When such secondary structures are present the tumor is of the diffuse infiltrative type and often shows cytologic evidence of malignancy (p. 42).

Most cerebellar astrocytomas should therefore be graded as grade 1 astrocytomas. Relatively insignificant cytologic features may place some of them into the grade 2 category, but the biologic differences between the two are difficult to assess. In a minority of cases, especially in the older age groups, the cerebellar astrocytomas show the same diffuse infiltrative histologic picture as most cerebral astrocytomas. This may be accompanied by cytologic evidence of malignancy such as increased cellularity, the appearance of mitoses, and of secondary structures. Here then the grading rises to 2 or 3, with a consequent more sinister prognosis.

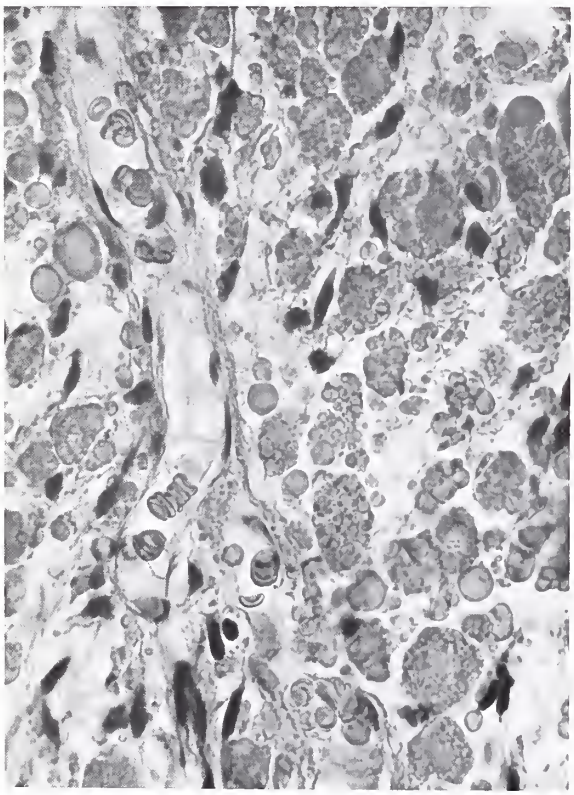

PROTEIN DROPLETS AND GRANULAR BODIES IN CYSTIC ASTROCYTOMA

Figure 13. Protein droplets form isolated or grouped granular bodies in a cystic cerebral astrocytoma. These bodies are intensely eosinophilic with H & E and strongly positive with PTAH. × 545.

Finally we note that just as cerebellar astrocytomas may sometimes be of the diffuse type and resemble the cerebral astrocytomas of adults, so also the "cerebellar type" of astrocytoma, either solid or more often cystic, is very occasionally encountered in the cerebral hemispheres, especially in children. Their gross appearances, microscopic features, and biologic behavior are then identical with those in the cerebellum.

The **pilocytic astrocytomas of juvenile type** in the region of the third ventricle and elsewhere have a characteristic microscopic appearance that is usually recognizable at a glance. In many ways the picture resembles that of the cerebellar astrocytoma, in that it shows the same variations from field to field, again contrasting with the uniform histologic appearance of the diffuse cerebral forms. Many of the cells are elongated and unipolar or bipolar, hence the name 'polar spongioblastoma' originally introduced by Bailey and Eisenhardt to designate them. This term is still often used in the literature (Zülch), but many workers regard these cells as pilocytic forms of mature astrocytes. They show strong affinity of their fibrillated cell processes for neuroglial stains (fig. 14). Moreover, other areas exhibit a looser pattern consisting of cystic zones in which the cells are feebly stellate and usually protoplasmic. Tissue culture of such a tumor by Russell and Bland convincingly

demonstrated its astrocytic nature and therefore seems to have justified the term piloid or pilocytic astrocytoma. This view has more recently been supported by Lumsden, but opposed by Kersting who, while aligning these tumors with the cerebellar astrocytomas, believes that both may represent a special cytologic type of astrocytoma. Electron microscopic studies of these tumors have confirmed the presence of compact bundles of glial filaments in the cell processes (Hossmann and Wechsler). In glutaraldehyde fixed material, tubules measuring 250 angstroms in diameter have also been seen near these filaments. The cytologic characteristics of these tumors are almost always benign. The nuclei are regular and orthochromatic. Giant cell formation and hyperchromatism are extremely rare; when present, they do not usually by themselves denote malignancy. The tumors are often highly vascular (fig. 15) and often hemorrhagic. As in the cerebellar astrocytomas, vascular endothelial proliferation may be encountered, but this in itself does not appear to herald malignant change.

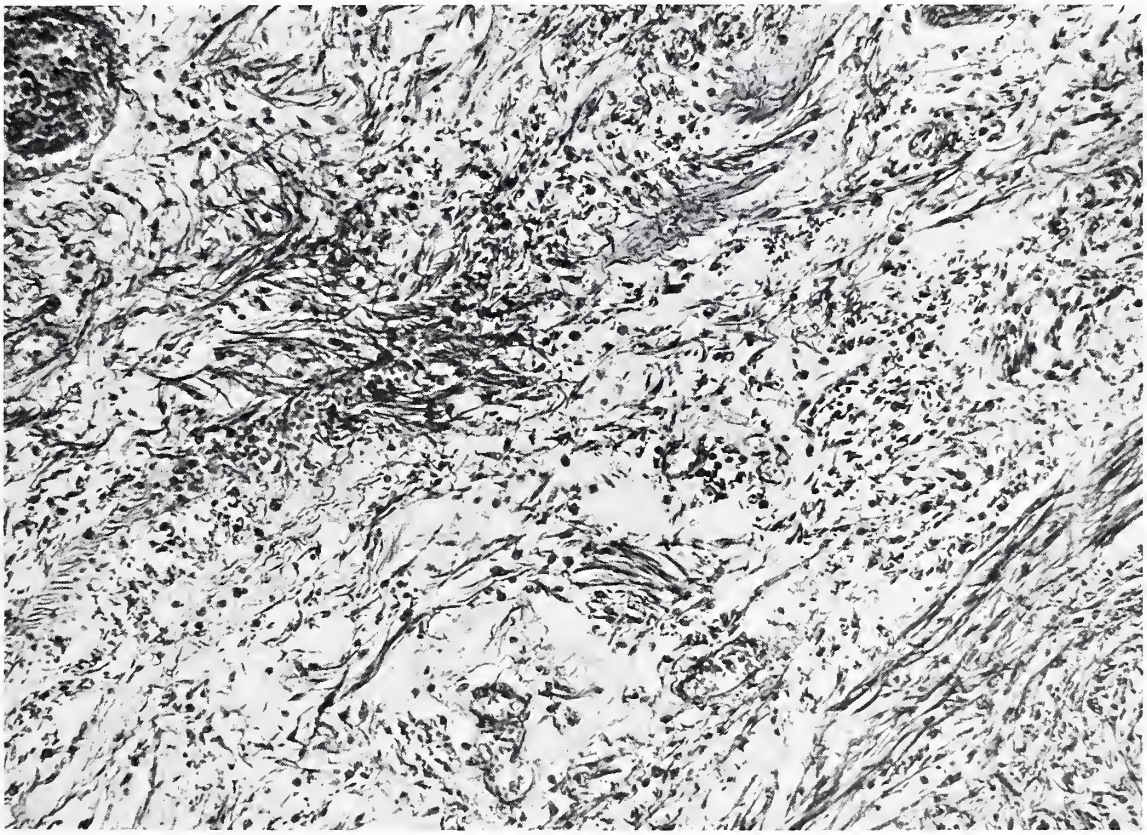

PILOCYTIC ASTROCYTOMA OF JUVENILE TYPE

(Figures 14 and 15 from same case)

Figure 14. The variation in this histologic picture of a ventricular tumor in a 9-year-old girl recalls that seen in the cerebellar type of astrocytoma. Compact fibrillated areas alternate with looser more cystic zones. Note the strong staining of the fibrillated cell processes with PTAH. This tumor is often referred to in the literature as "polar spongioblastoma." PTAH. × 210.

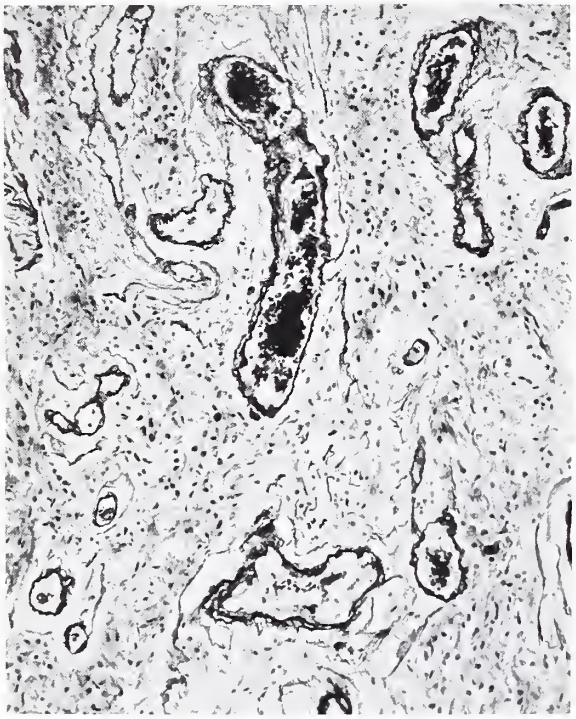

PILOCYTIC ASTROCYTOMA OF JUVENILE TYPE

(Figures 14 and 15 from same case)

Figure 15. This is a characteristic vascular pattern in pilocytic astrocytoma of juvenile type. Silver method for reticulin. × 110.

Again as in the cerebellar astrocytomas, the piloid astrocytomas of juvenile type often show degenerative changes of the tumor cell cytoplasm, with the formation of Rosenthal fibers in the more solid fibrillated zones (fig. 16). The incident and light microscopic features of the Rosenthal fibers have been described in detail by Grcevic and Yates, and their fine structure by Schlote and by others. With the electron microscope the Rosenthal fibers correspond to dense osmiophilic nonmembrane-bound bodies of irregular shape, consisting of granular or amorphous material (fig. 17). They are always associated with the presence of dense arrays of thickened intracytoplasmic glial filaments. The osmiophilic bodies are distinct from the filaments, but can in places be seen to merge into them (fig. 18; Herndon et al.).

These astrocytomas have sometimes been referred to in the literature as "infundibulomas" because of the alleged similarity of their vascular pattern to that of the neurohypophysis (Globus). Admittedly the majority of these tumors seem to arise from this region or from adjacent structures about the third ventricle. However, the histologic pattern is not as distinctive for this area as sometimes claimed, since similar astrocytomas are occasionally encountered in the substance of the cerebral hemispheres, or in relation to other ventricles, such as the

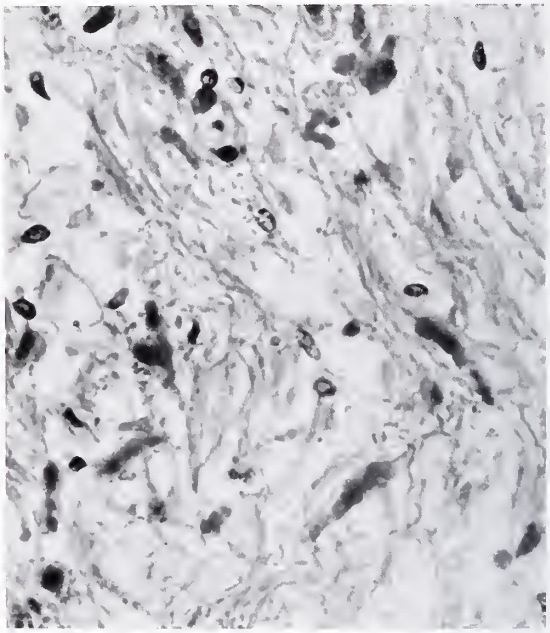

ROSENTHAL FIBERS IN PILOCYTIC ASTROCYTOMA OF JUVENILE TYPE

(Figures 2, 3, and 16 from same case)

Figure 16. These elongated and cigar-shaped, intensely eosinophilic, degenerated glial cells (Rosenthal fibers) are seen in a pilocytic juvenile astrocytoma. × 435. (Fig. 3 from Rubinstein, L. J. Seminario de Neuropatologia, Mérida, Yucatán, Bol. Asoc. Mex. Patol., A. C. 7:13–59, 1969).

lateral and the fourth. In most cases these tumors are massive when they come to examination (Wolman), and therefore an exact site of origin is hard to postulate. Zülch believes that these tumors, which he designates as polar spongioblastomas, may arise from the subependymal glia.

Secondary structures (pp. 11, 12) are never found in relation to the juvenile pilocytic astrocytomas, whether they arise in the region of the third ventricle or elsewhere. These tumors therefore virtually always belong to the grade 1 group of astrocytomas.

The **pontine** and **medullary** tumors in children closely resemble histologically the diffuse cerebral astrocytomas of adults, except for the greater tendency on the part of the tumor cells to be pilocytic. They are therefore sometimes erroneously referred to as 'polar spongioblastomas.' However, this is clearly a secondary change resulting from

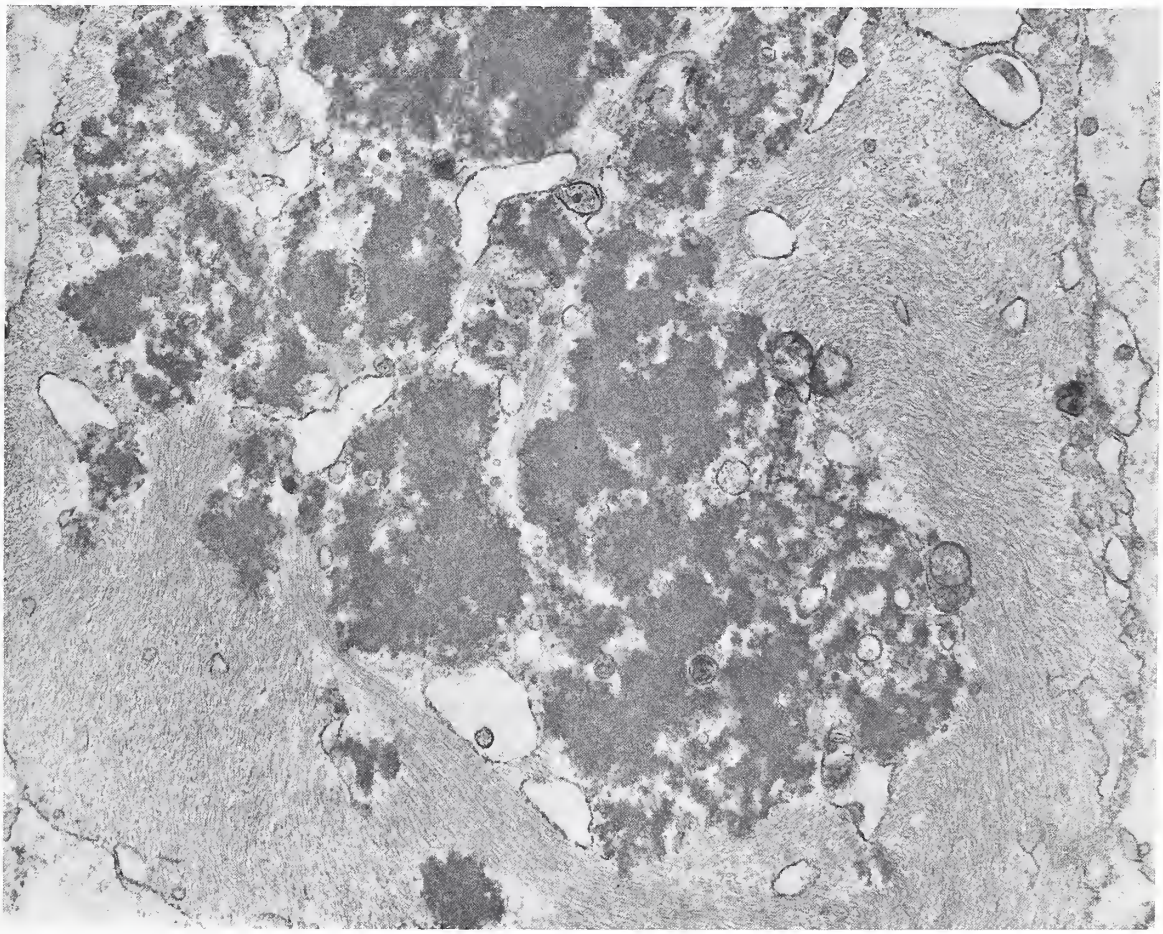

ROSENTHAL FIBERS IN CEREBELLAR ASTROCYTOMA

Figure 17. This electron micrograph of a cystic cerebellar astrocytoma shows irregular, amorphous electron-dense material occupying the center of an astrocytic cell process. This material corresponds to the Rosenthal fibers seen by light microscopy. A dense feltwork of glial filaments surrounds these amorphous deposits. × 13,000. (In collaboration with Dr. Mary M. Herman and Miss Marjorie A. Johnson).

the alignment of the infiltrating tumor cells along preexisting nerve fibers; by contrast the tumor cells occupying the tegmentum are usually stellate. As in the cerebral astrocytomas, the neurons of the invaded gray nuclei tend to be preserved for a considerable time until anaplastic and tissue-destructive changes supervene. The latter, as indicated previously, are frequent. The grading of these astrocytomas therefore varies from 2 to 4, depending on the extent and severity of the supervening anaplastic changes. Secondary structures (pp. 11, 12) are often encountered.

The astrocytomas of the **spinal cord** resemble the fibrillary astrocytomas of the cerebral hemispheres, with a marked tendency to become pilocytic, usually because of the presence of preexisting fiber tracts. For this reason they are sometimes again ambiguously referred to in the literature as polar spongioblastomas.

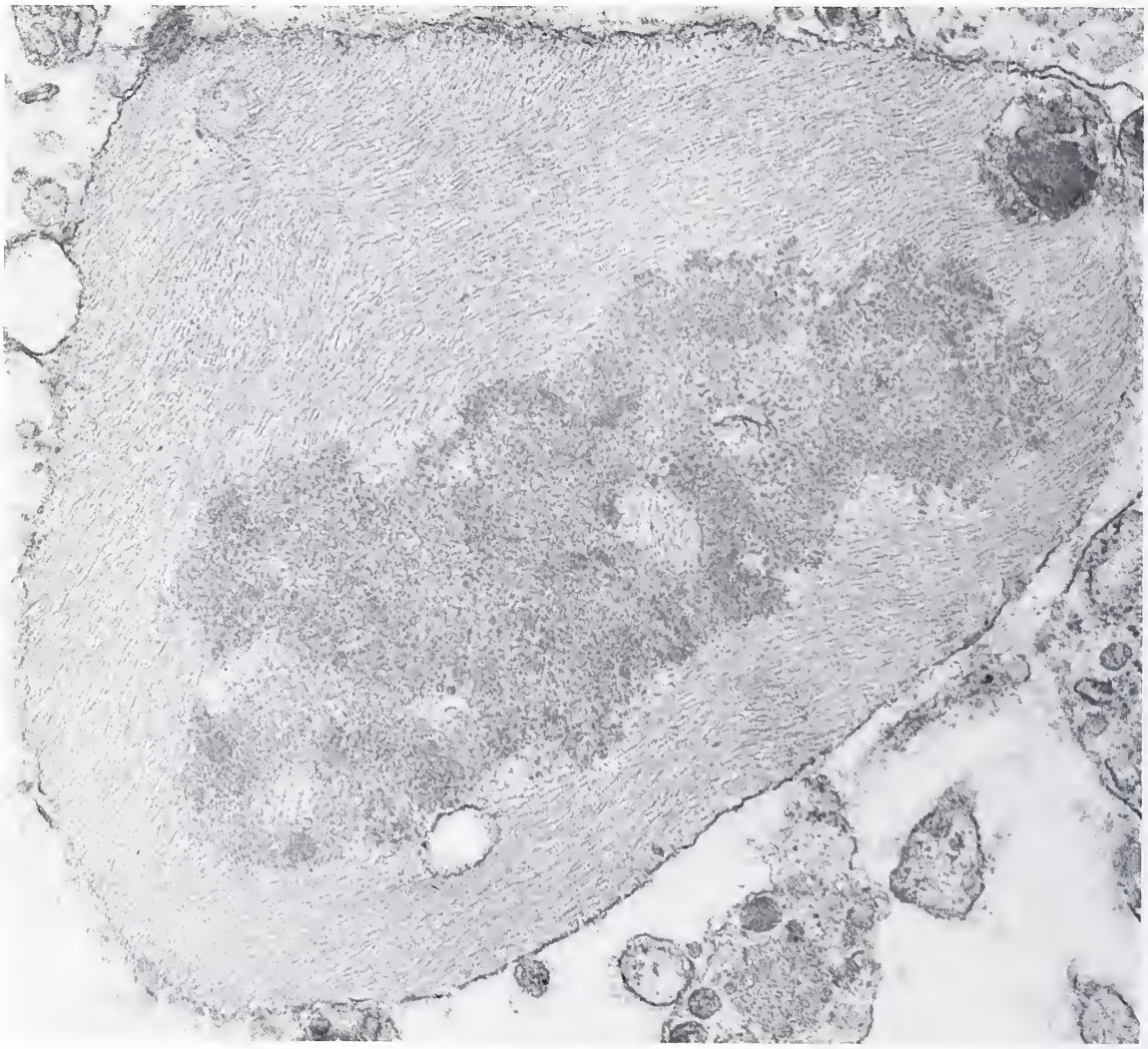

ROSENTHAL FIBERS IN ASTROCYTIC TUMOR CELL PROCESS

Figure 18. This electron micrograph shows glial filaments merging in places with amorphous electron-dense Rosenthal fibers. × 32,400. (In collaboration with Dr. Mary M. Herman and Miss Marjorie A. Johnson).

VARIANTS

Protoplasmic Astrocytoma

In its pure form this is an extremely rare variant. Protoplasmic astrocytes are frequent cell elements in cerebellar astrocytomas and pilocytic astrocytomas of juvenile type. Occasionally they form foci in diffuse, otherwise largely fibrillary cerebral astrocytomas. As a pure type the protoplasmic astrocytoma is found almost exclusively in the cerebral hemispheres. Its borders are relatively ill-defined, but better delineated than the diffuse fibrillary astrocytomas. The cut surface has a semitranslucent homogeneous appearance and is rather soft and somewhat gelatinous. Small cyst formation is frequent. Occasionally much of the tumor is replaced by a large cyst.

Microscopically the picture consists in fairly uniform areas composed of stellate cells with delicate processes, devoid of neuroglial fibrils, and forming a fine cobweb matrix (fig. 19) and small microcysts.

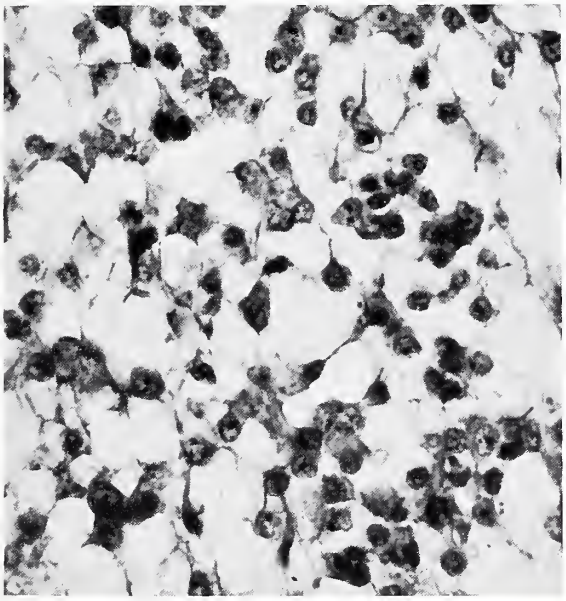

PROTOPLASMIC ASTROCYTOMA

Figure 19. Small stellate nonfibrillated astrocytes with extended well defined processes form a fine cobweb matrix. PTAH. × 480.

Pilocytic Astrocytoma of Adult Type

This rather uncommon form of diffuse cerebral astrocytoma is composed of elongated, strongly fibrillated, piloid astrocytes that form an intersecting pattern (fig. 20). In these tumors the piloid shape of the cells is not the result of their morphologic adaptation to preexisting nerve fiber tracts, nor does the microscopic picture resemble that of the pilocytic astrocytomas of juvenile type. In contrast to the latter the histologic architecture is uniform. In addition, along these pilocytic areas, stellate and gemistocytic foci are sometimes found. Frequently these astrocytomas show cytologic evidence of anaplastic change, which may progress to the florid picture of glioblastoma multiforme (fig. 30).

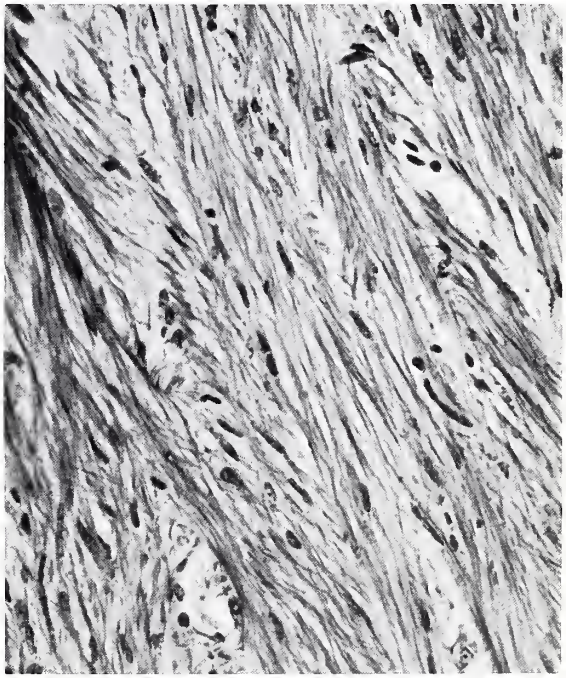

PILOCYTIC ASTROCYTOMA OF ADULT TYPE

Figure 20. This intersecting pattern of elongated, strongly fibrillated pilocytic astrocytes produces a uniform histologic picture, in contrast to the pilocytic astrocytoma of juvenile type. PTAH. × 270.

Gemistocytic Astrocytoma

As a pure form gemistocytic astrocytomas are relatively uncommon. In many cases, however, fields of gemistocytic tumor are found intermingled with areas of fibrillary stellate astrocytoma. The pure gemistocytic astrocytomas are found only in the cerebral hemispheres of adults. They are often relatively well circumscribed, with a gray homogeneous, almost granular cut surface, and a soft consistency. Microscopically they are composed of closely packed astrocytic cells with angulated or somewhat globoid outlines, rather prominent eccentric nuclei with large nucleoli, and a homogeneous hyaline and deeply eosinophilic cytoplasm. These tumors are occasionally erroneously referred to as 'protoplasmic' astrocytomas; in fact they always show abundant fibrillated cytoplasmic processes (pl. II-B), but the neuroglial fibers are confined to the periphery of the cell. In places the tumor cells are arranged around blood vessels and form perivascular pseudorosettes (fig. 21). For this reason some authors have referred to these neoplasms as astroblastomas, but a perivascular arrangement is not the prominent feature in gemistocytic astrocytomas. In our experience these tumors frequently undergo malignant change in the course of time.

Electron microscopically this type of astrocytoma shows the cytoplasm is occupied by variable amounts of endoplasmic reticulum, mitochondria, a few dense membrane-bound bodies, and bundles of compact glial filaments (Luse; Duffell et al.). These are found mostly at the periphery of the cell which has short blunt processes.

Subependymal Giant Cell Astrocytoma

This name is given to a tumor that is characteristically associated with tuberous sclerosis; when discovered, it should arouse suspicion of this condition. However, it may also be found occasionally in the absence of the disease. The tumor almost always arises from the wall of the lateral ventricle and presents as an intraventricular mass that obstructs the foramen of Monro and is apt to produce hydrocephalus. The tumor is sharply defined, with a soft, homogeneous, grayish cut surface, occasionally pinkish red and hemorrhagic because of its great vascularity. Focal calcification is common.

Microscopically the cells are composed of giant and irregular forms, many of which resemble gemistocytic astrocytes. Others have a more pyramidal shape or are extremely elongated with a "straplike" appearance (figs. 22, 23). In places the histologic pattern is a streaming one; in others

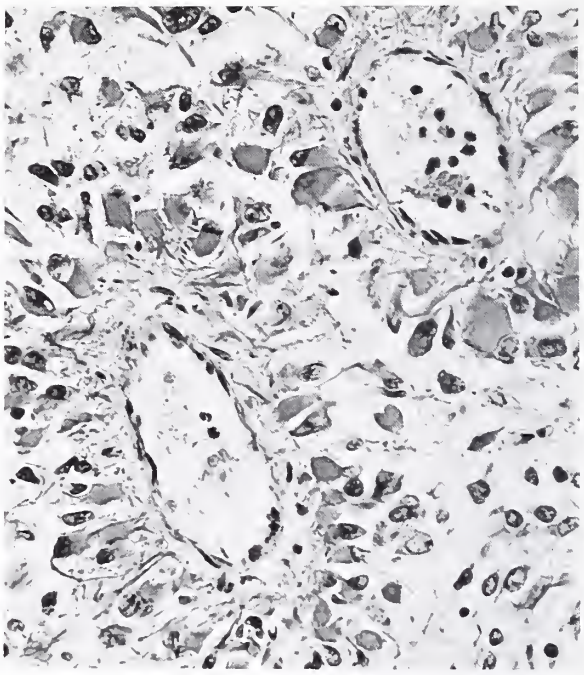

GEMISTOCYTIC ASTROCYTOMA
(Figure 21 and Plate II-B from same case)
Figure 21. This area of gemistocytic astrocytoma shows a perivascular pseudorosette arrangement of the tumor cells. PTAH. × 270.

it is highly cellular and compact without any definite architecture. In still other places there may be a conspicuous arrangement of perivascular pseudorosettes. The cytoplasm of the cells is hyaline, eosinophilic, and homogeneous. The nuclei tend to be eccentric and often have a prominent nucleolus, creating a superficial resemblance to ganglion cells. This feature has sometimes invited the diagnosis of ganglioneuroma or gangliocytoma. However, truly neoplastic nerve cells are very seldom present in these tumors. The cell elements do not usually have Nissl substance, and neurofibrils cannot be demonstrated with the appropriate technics. The tumors are sometimes highly

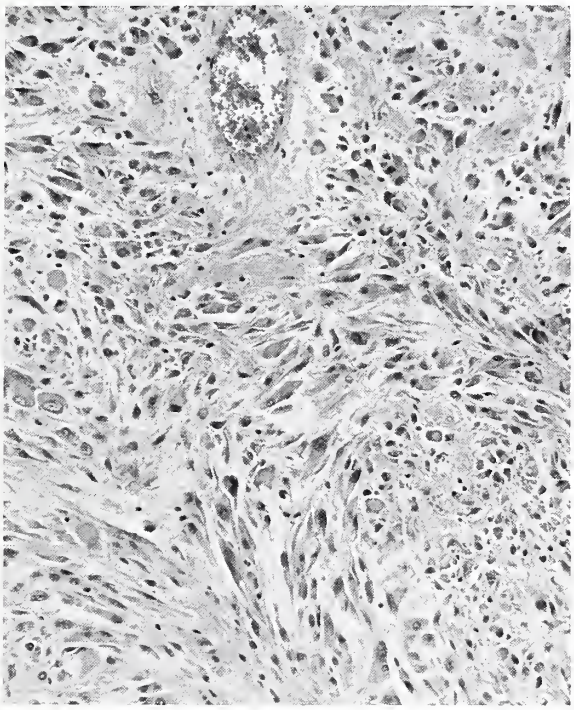

SUBEPENDYMAL GIANT CELL ASTROCYTOMA

(Figures 22 and 23 from same case)

Figure 22. This intraventricular tumor is from a 10-year-old boy with tuberous sclerosis. Giant and elongated astrocytes form a streaming pattern in places. × 125.

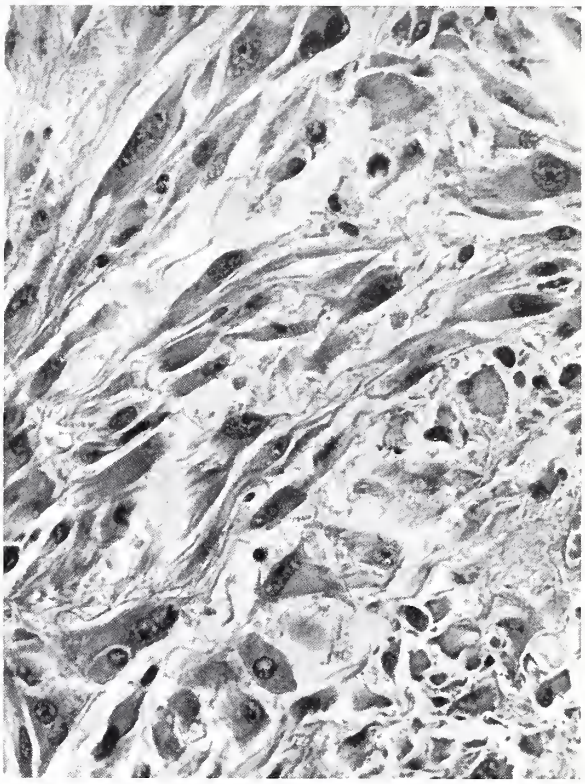

SUBEPENDYMAL GIANT CELL ASTROCYTOMA

(Figures 22 and 23 from same case)

Figure 23. This high power view reveals pyramidal and elongated straplike tumor cells with large nuclei and prominent nucleoli. There is a superficial resemblance to neuronal nuclei. No histologic evidence of malignancy was found in this tumor. × 360.

vascular, but the vascular walls are usually thin and there is no endothelial proliferation. The tumor cell nuclei occasionally show some hyperchromatism, but mitotic figures are extremely infrequent. Malignant changes, such as necrosis, foci of increased density, and cellular anaplasia are exceptional. The biologic behavior of these tumors conforms to their benign histologic characteristics, and is that of slowly growing neoplasms, gradually producing obstruction to the cerebrospinal fluid circulation. They

probably arise from the subependymal "candle gutterings" characteristic of tuberous sclerosis. It is of interest that the cortical tubers in this disease do not appear to be the site of origin of tumors, either glial or neuronal.

Gliomatosis Cerebri

This very rare form of widespread glial neoplastic transformation, usually found in subjects in the second and third decade, may involve considerable areas of the cerebral hemispheres, cerebellum, and brainstem (Dunn and Kernohan). Grossly and microscopically the tumor has much in common with the diffuse cerebral astrocytoma of adults, of which it is probably an extreme example. The tumor elements are often elongated, darkly staining glial cells, originating from and spreading along the molecular layer (fig. 8) and beneath the ependyma. The widespread nature of the lesion is usually regarded as evidence that a neoplastic transformation has taken place over a wide field (Willis, 1960; Scherer, 1940). The tumor has occasionally been reported in association with neurofibromatosis and tuberous sclerosis. Some examples in conformity with other cerebral astrocytomas may show one or more areas of focal anaplastic change, with the classic microscopic picture of glioblastoma multiforme.

MALIGNANT ASTROCYTOMA

SYNONYMS AND RELATED TERMS: Astrocytoma, grade 3; dedifferentiated astrocytoma.

Reference has frequently been made to the tendency of certain astrocytomas to undergo a malignant evolution. It has been estimated (Russell and Rubinstein) that in the cerebral astrocytomas alone some degree of anaplastic change is found in nearly 80 percent of cases examined at necropsy, an estimate which is in close agreement with the figures given by Scherer (1940). When this evolution takes place, postmortem findings reveal one focus or occasionally more foci that are grayish when fixed and somewhat hemorrhagic (fig. 28). Microscopically they show the features of glioblastoma multiforme. In the gemistocytic astrocytomas it has been estimated that possibly 80 percent convert to glioblastoma multiforme. There is also clinical evidence, from repeated biopsies on the same patients over a number of years, that anaplasia plays a part in the gradual evolution of these tumors. In the diffuse pontine astrocytomas in children, we have estimated that 60 percent show evidence of anaplastic change, which is in agreement with the observations of Willis (1962). By contrast less than 10 percent of the cerebellar astrocytomas show histologic malignant characteristics, and such an evolution is exceptional among the pilocytic astrocytomas of juvenile type.

Aside from the typical glioblastomas (p. 55) there seems to exist a form of astrocytoma that shows evident anaplastic features *de novo*, for which the term **malignant astrocytoma** seems appropriate. Microscopically these features fall short of the classic histologic picture of glioblastoma multiforme. They consist in increased cellularity, nuclear irregularity and hyperchromatism, occasional giant cells, vascular endothelial proliferation, and a variable number of mitotic figures. Frequently the astrocytic lineage of the tumor cells remains evident from the demonstration of neuroglial fibers (fig. 29). Pilocytic astrocytomas of the adult type are often cytologically malignant, and astroglial differentiation may be lost (fig. 30). Essentially, therefore, these tumors might be thought to correspond to the grade 3 astrocytomas of the classification by Kernohan and Sayre, especially since more extensive sampling often discloses elsewhere the presence of complete dedifferentiation to glioblastoma.

GROWTH AND SPREAD. Reference has already been made in the appropriate microscopic descriptions to certain morphologic features that characterize the growth and spread of the different types of astrocytomas within the brain parenchyma. **Invasion of the subarachnoid space** on the surface of the tumor, and **of the Virchow-Robin spaces** within it, is a common feature in all astrocytomas irrespective of their type, but its presence does not denote a malignant tumor. It is met in diffuse fibrillary growths (pl. II-C), in more than 50 percent of the benign circumscribed cerebellar astrocytomas (fig. 24), and in many examples of pilocytic astrocytoma of juvenile type. As a result a characteristic irregular fasciculated pattern is produced (pl. II-C) that is partly accounted for by the proliferation of connective tissue fibers in the subarachnoid space by the meningeal fibroblasts. The tumor cells form small clusters separated by these fibers (fig. 25). Focal invasion of the perivascular space by tumor may produce marked enlargement of this space, as in the example of malignant cerebral astrocytoma illustrated in figure 26. In places the pia-glial membrane is ruptured by the invading tumor cells and occasionally the tumor cells in the Virchow-Robin space appear more anaplastic than those within the brain (fig. 26).

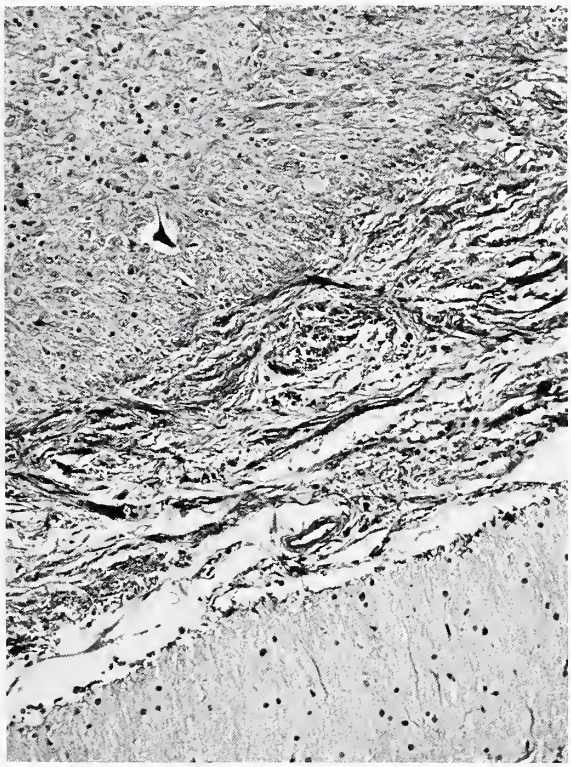

INVASION OF LEPTOMENINGES BY CEREBELLAR ASTROCYTOMA

(Figures 11, 24, and Plate I-C from same case)

Figure 24. There is invasion of the subarachnoid space by fibrillated tumor cells from a poorly cellular area of cerebellar astrocytoma (above). The adjacent folium (below) is normal. PTAH. × 145.

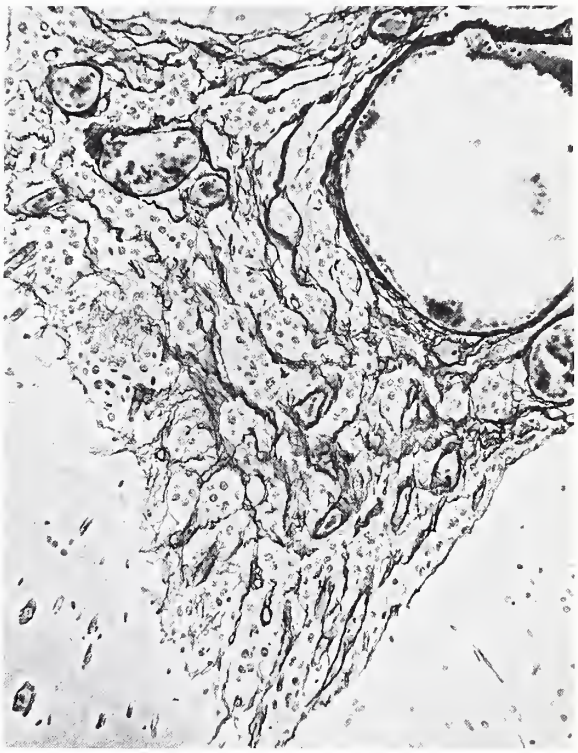

INVASION OF LEPTOMENINGES BY CEREBELLAR ASTROCYTOMA

Figure 25. Note the proliferation of connective tissue fibers in the leptomeninges resulting from focal invasion by a cerebellar astrocytoma. Silver impregnation for reticulin. × 108.

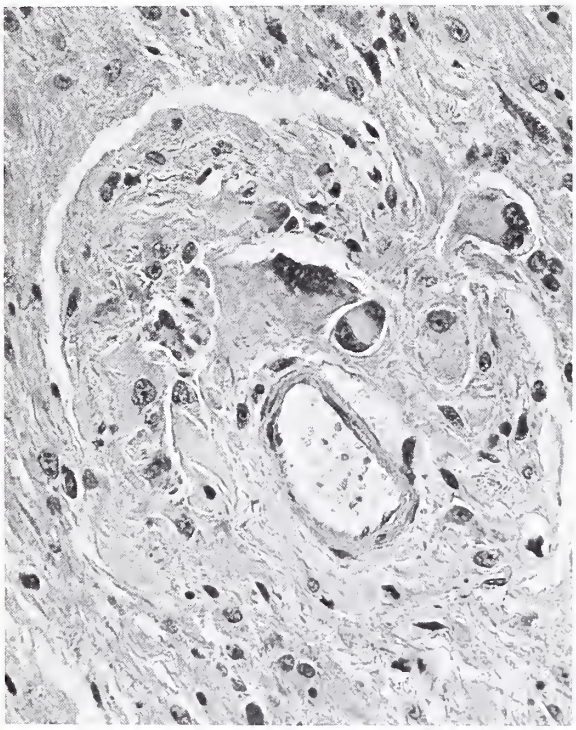

INFILTRATION OF VIRCHOW-ROBIN SPACE BY A DIFFUSE CEREBRAL ASTROCYTOMA

Figure 26. Marked enlargement of the Virchow-Robin space is produced by tumor invasion in a diffuse malignant cerebral astrocytoma. The tumor cells have ruptured through the pia-glial membrane on the upper right. Note malignant features of the cells in the Virchow-Robin space. PTAH. × 300.

As spread takes place in diffusely infiltrating astrocytomas, areas may appear that are identical with those found in astroblastomas (p. 51), and occasionally a curious rhythmic pattern is seen resembling that found in the true polar spongioblastoma (p. 53). This feature (fig. 27) is not due to the alignment of the tumor cells along preexisting nerve fibers and is therefore not a true secondary structure (pp. 11, 12), but appears to be a transient morphologic phenomenon usually associated with evident anaplastic changes elsewhere.

Metastasis from astrocytomas through the cerebrospinal fluid pathways is rare. It is not a complication to be necessarily anticipated following focal invasion of the leptomeninges, since the latter is a frequent phenomenon. It is more likely to arise once the growth has breached through the ventricular ependyma. In most cases this is accompanied by anaplastic change in the tumor, which then behaves as a glioblastoma. However, distant dissemination through the cerebrospinal fluid pathways occasionally occurs with histologically benign astrocytomas of the cerebellum, third ventricle, and hypothalamus.

TREATMENT. The treatment of choice for cerebral astrocytomas is as radical surgical removal as possible followed by radiation. Although it is stated that astrocytomas are not radiosensitive there is some evidence that long-term survival is improved by postoperative radiotherapy (see below). Pilocytic astrocytomas of the hypothalamic and chiasmatic regions are usually not amenable to radical extirpation because of their location, but occasionally much of the tumor can be removed; postoperative radiation should then be given in the hope of slowing down or arresting further growth. When the tumor is inaccessible, shunting procedures performed in order to relieve the obstructive hydrocephalus have in a number of cases been followed by unusually long survival.

The treatment of choice for cerebellar astrocytomas is total extirpation. This alone is the most effective treatment. It is generally held that radiotherapy has little to offer in those cerebellar astrocytomas that are

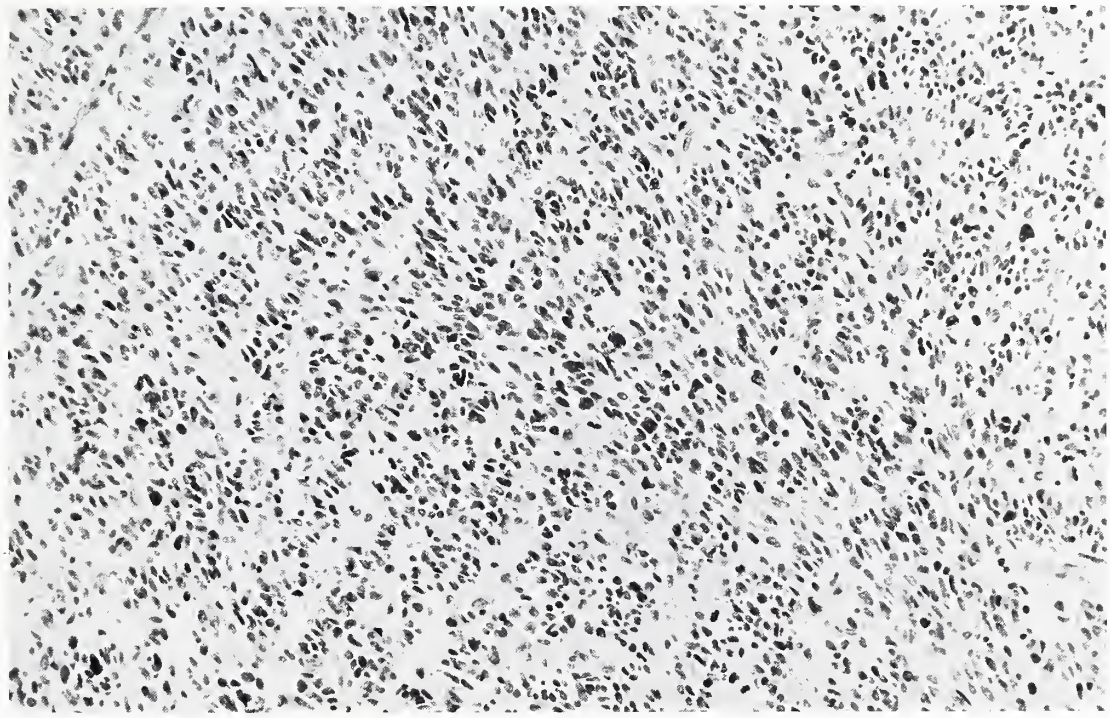

PALISADING EFFECT IN MALIGNANT DIFFUSE ASTROCYTOMA

Figure 27. This illustrates the palisading effect of tumor cells superficially resembling polar spongioblastoma in a diffusely infiltrating mixed malignant glioma, partly astrocytic and partly oligodendroglial. × 185.

well differentiated and amenable to complete surgical removal (Schulz et al.). In some cases, however, especially those that have become adherent to the medulla or involve the brainstem secondarily, only partial removal can be performed. When given postoperative radiation, these patients may benefit from many years of survival. The development of leptomeningeal fibrosis in the posterior fossa with consequent hydrocephalus and repeated episodes of meningeal and ependymal infections is a tragic, occasional complication which may attend the successful removal of cerebellar astrocytomas. The pontine gliomas are of course not accessible to surgical removal, and the only treatment available is radiotherapy. Shunting procedures may be indicated.

PROGNOSIS. As has been made clear from the foregoing discussion, the prognosis of the cerebral astrocytomas is quite unpredictable in view of their diffuse character, the difficulty of total extirpation, and their natural history. Large series emanating from neurosurgical clinics give figures of long-term survival that are more hopeful than might have been expected from data obtained from anatomic pathologic material. Such figures should be treated with caution. According to Pool and Kamrin, the average survival time for patients with supratentorial astrocytoma treated by subtotal excision followed by radiotherapy is 70 percent for one year, 55 percent for two years, and 30 percent for five years. According to Bouchard and Pierce, postoperative radiotherapy markedly

improves the chances of long-term survival following subtotal excision; thus, after three years 52 percent of those treated by surgery alone had survived as compared to 64 percent of those treated by surgery plus radiotherapy; at five years the difference was greater, that is, 26 percent compared to 49 percent. In the diffuse cerebral astrocytomas the average postoperative survival is 5 years and 4 months (Elvidge); of 19 cases, 8 had survived for periods of 8 to 18½ years. Prolonged survival up to 12 and 15 years has occasionally been reported from other sources (McCormick et al.).

Figures are difficult to obtain in regard to the prognosis of pilocytic astrocytomas of the third ventricle. Some cases survive for many years following diagnostic biopsy procedure, shunting operations for the relief of hydrocephalus, and radiation.

The average postoperative survival for gemistocytic astrocytomas in Elvidge's series was 3 years and 8 months. Of the 18 patients that were followed, 8 had survived for periods of 4 to 10 years. The longest survival was 10 years and 4 months.

In the cerebellar astrocytomas the average postoperative survival was 13 years. The prognosis is much more favorable in the cystic than in the noncystic tumors (16.9 years compared to 6.5 years). Long survival up to 20 years or more is therefore the rule, even when only part of the tumor has been removed. By contrast the diffuse cerebellar growths have a much poorer prognosis because of their infiltrative character and their tendency to undergo anaplasia.

Despite the usually tragic course of brainstem astrocytomas some have been stated to respond remarkably well to radiation therapy. The data, often in the absence of histologic confirmation, are difficult to evaluate. Pool and Kamrin report survival periods from 4 to 9 years and occasionally longer; one patient was alive and well 30 years after a biopsy indicating a midbrain astrocytoma. Even taking into account the possibility of diagnostic errors inherent in administering radiotherapy procedures without histologic verification, the prognosis is perhaps better than would have been anticipated. According to Bouchard, 39 percent of the patients treated by radiotherapy survive for 3 years, and 32 percent for 10 years.

According to Slooff and associates the average postoperative survival of patients with a grade 1 astrocytoma of the spinal cord is 101 months, and 32 percent of these patients survive longer; the longest postoperative survival in this group was 31 years. Of the patients with grade 2 astrocytoma, the average length of survival was 44 months, and 18 percent of the patients survived longer than this period; the longest survival time in this group was 17 years. No definite correlation could be obtained between the length of postoperative survival and the type of treatment administered.

DIFFERENTIAL DIAGNOSIS. Diagnostic difficulties are occasionally encountered in neurosurgical pathology in distinguishing a poorly cellular diffuse fibrillary astrocytoma from reactive gliosis. To a large measure the difficulties depend on the amount of tissue obtained. If the biopsy is exiguous it may be impossible to reach an unequivocal diagnosis. In practice most neurosurgical specimens are, or should be, generous enough to permit an exhaustive examination of the biopsy fragments and a definite conclusion. In reactive gliosis the astrocytes are usually dispersed in a very regular fashion, and although they may be

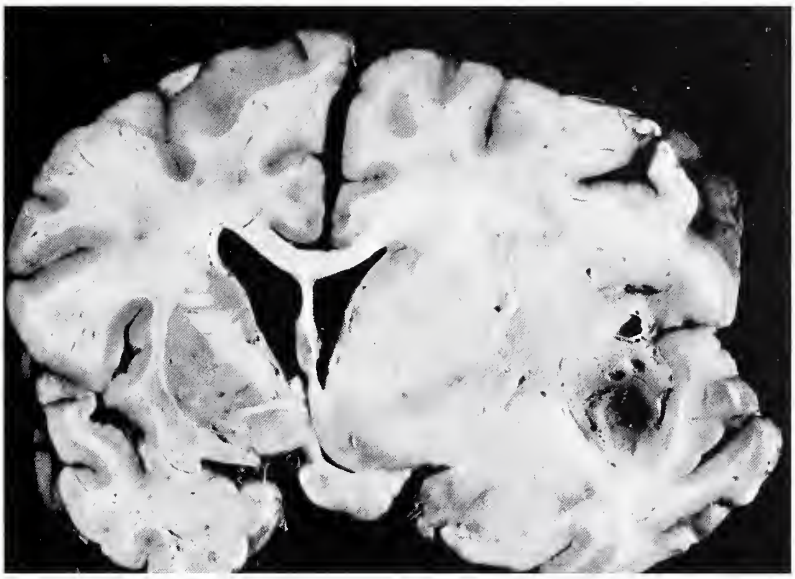

MALIGNANT CHANGE IN DIFFUSE CEREBRAL ASTROCYTOMA

Figure 28. Diffuse astrocytoma replaces the right frontoparietal and medial temporal white matter, and most of the right basal ganglia. The normal anatomic markings are indistinct or lost. A small dark hemorrhagic focus is seen in the insula beneath a small cyst in the tumor. This focus showed microscopically the features of glioblastoma multiforme. This is from the case of a 39-year-old woman with an 8-year clinical history of intracranial disease. (Courtesy of the Armed Forces Institute of Pathology).

much enlarged they show little nuclear hyperchromatism, no nuclear irregularity, and no mitotic figures. By contrast, in a diffuse astrocytoma some nuclear irregularity and hyperchromatism is virtually always present. The discovery of mitotic figures in astrocytes is with one specific exception virtually diagnostic of neoplasia. Moreover, in a diffuse astrocytoma irregularities of cell concentration are often detected; in particular the increased aggregates around the neurons, beneath the pia, and around the blood vessels are indicative of the secondary structures of Scherer (1938) already described (pp. 11, 12). A diagnostic error occasionally arises in biopsies from demyelinating diseases with prominent reactive astrocytic hyperplasia. Cases of Schilder's disease with enlarged gemistocytic reactive astrocytes may be mistaken for gemistocytic astrocytomas, but the presence of large foamy macrophages among the astrocytes should provide a safeguard against this misinterpretation. In unsuspected progressive multifocal leucoencephalopathy, the differential diagnosis from a malignant glioma may be impossible in a small biopsy because of the nuclear hyperchromatism and abnormal mitotic figures characteristically found in the bizarre abnormal giant astrocytes. A marked reactive gliosis, reminiscent of a pilocytic astrocytoma of juvenile type, may also occur in the walls of craniopharyngiomas. Malignant meningiomas and infiltrating sarcomas may also induce a marked hyperplasia of the reactive astrocytes that may mimic tumor formation, and in a few cases may actually evolve to a local gliomatous change (p. 198).

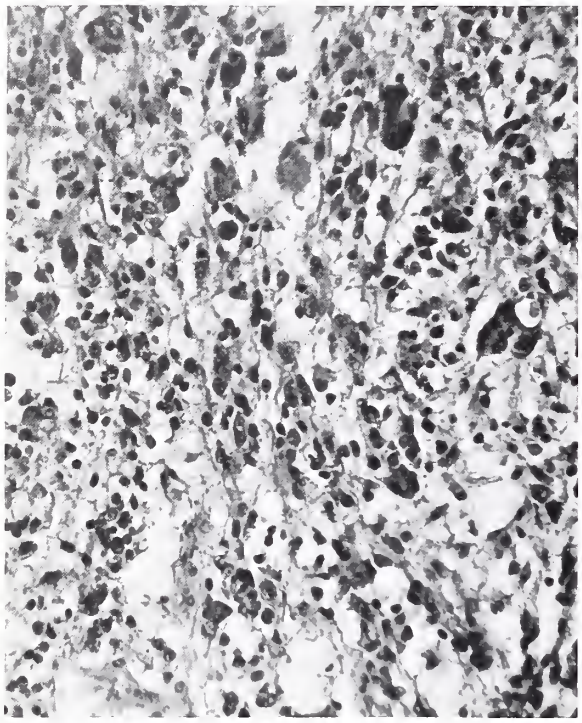

Fig. 29

MALIGNANT ASTROCYTOMA

(Figures 6, 29, 74–78, and Plate XIII-D from same case)

Figure 29. This highly cellular glioma shows pleomorphism, hyperchromatism, and multinucleated giant cells. The astrocytic lineage of the tumor cells is still easily recognizable. Elsewhere (fig. 6) the tumor was a typical fibrillary astrocytoma. Its biologic behavior was similar to that of a glioblastoma. × 210.

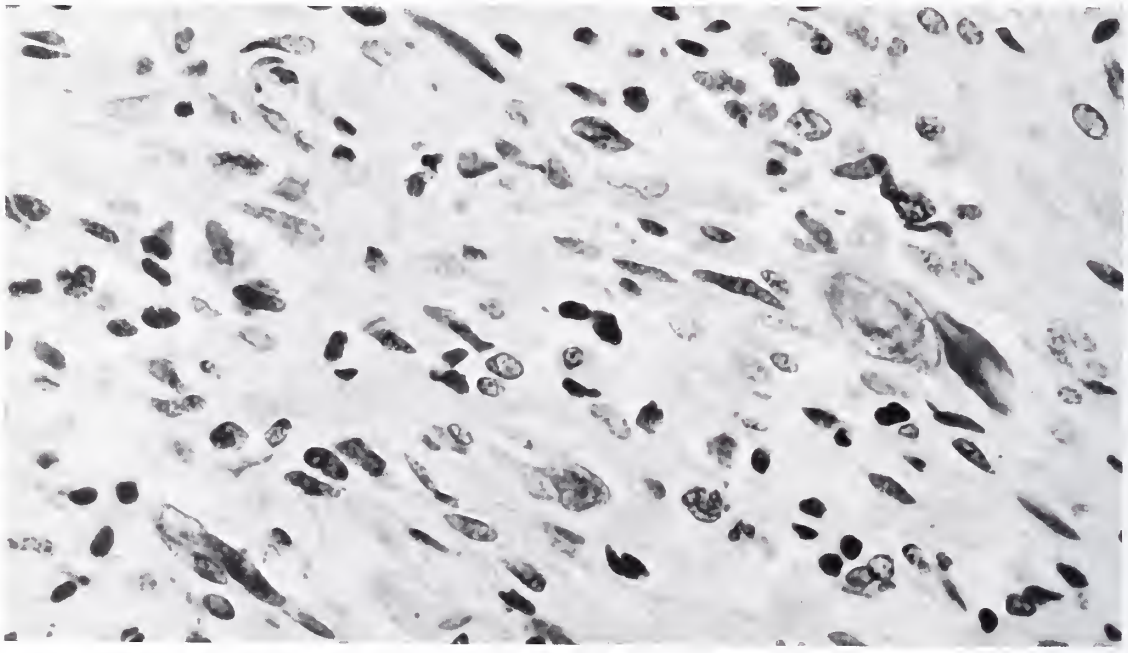

MALIGNANT PILOCYTIC ASTROCYTOMA

Figure 30. These malignant pilocytic astrocytic cells are seen in a left frontal pole glioma in a 30-year-old woman. Elsewhere they showed the picture of glioblastoma multiforme. There is marked pleomorphism of the tumor cells, and occasional hyperchromatic giant cells. × 600. (Fig. 10 from Rubinstein, L. J. Seminario de Neuropatologia, Mérida, Yucatán, Bol. Asoc. Mex. Patol., A. C. 7:13–59, 1969).

Very occasionally, a considerable diagnostic difficulty may challenge the neurosurgeon and pathologist confronted by a large **cerebellar cyst** in which no mural nodule has been found at operation. The cyst wall may consist of a concentration of glial cells in various stages of degeneration, with a profusion of Rosenthal fibers. The glial nuclei show no atypia, and the appearances are similar to those of the wall of a syringomyelic cavity. The problem of deciding whether the lesion is an old burnt-out cystic astrocytoma or a simple glial cyst of the cerebellum with severe reactive gliosis may be impossible to resolve. This has been encountered twice in my recent experience, both cases being in adults aged 62 and 50 respectively. Two similar examples, in adults also, are described and speculatively discussed by Cushing in his series of cerebellar astrocytomas.

The differential diagnosis between malignant astrocytoma (astrocytoma grade 3) and **glioblastoma multiforme** is often an academic exercise. Frequently a superficial biopsy from a glioblastoma may yield only well differentiated astrocytic tumor, whereas the more malignant portion is harbored in the deeper part of the brain. Occasionally a diffuse infiltration of the brain by a metastatic **amelanotic melanoma** may mimic the spread of a poorly differentiated cerebral astrocytoma. Also at times a diffuse piloid astrocytoma growing in the parapontine space has been mistaken at surgery for an **acoustic schwannoma**; the reverse may also occur (p. 212). Finally some astrocytomas, particularly those arising in the cerebellum and in the walls of the third ventricle, are intensely vascular, and the vasculature may at first glance appear to be the predominant histologic component. These tumors are occasionally referred to as "angiogliomas." This entity is not clear-cut; most examples are either highly vascular gliomas, usually of the astrocytic series, or less likely vascular malformations surrounded by a conspicuous reactive hypertrophic gliosis. Difficulties are occasionally said to arise in the cerebellum in distinguishing a **capillary hemangioblastoma** with surrounding reactive gliosis from a highly vascular astrocytoma; where doubt exists, the second diagnosis is usually correct.

References

Bailey, P., and Eisenhardt, L. Spongioblastomas of the brain. J. Comp. Neur. 56:391–430, 1932.

Bouchard, J. Central Nervous System, Chapter 13 of Textbook of Radiotherapy. (Ed.) Fletcher, G. Philadelphia: Lea and Febiger, 1966.

_____, and Pierce, C. B. Radiation therapy in the management of neoplasms of the central nervous system, with a special note in regard to children: 20 years' experience 1939–1958. Amer. J. Roentgen. 84:610–628, 1960.

Cushing, H. Experiences with the cerebellar astrocytomas. A critical review of 76 cases. Surg. Gynec. Obstet. 52:129–204, 1931.

Duffell, D., Farber, L., Chou, S., Hartmann, J. F., and Nelson, E. Electron microscopic observations on astrocytomas. Amer. J. Path. 43:539–554, 1963.

Dunn, J., Jr., and Kernohan, J. W. Gliomatosis cerebri. Arch. Path. 64:82–91, 1957.

Elvidge, A. R. Long-term survival in the astrocytoma series. J. Neurosurg. 28:399–404, 1968.

Globus, J. Infundibuloma. A newly recognized tumor of neurohypophyseal derivation with a note on the saccus vasculosus. J. Neuropath. Exp. Neurol. 1:59–80, 1942.

Grcevic, N., and Yates, P. O. Rosenthal fibres in tumours of the central nervous system. J. Path. Bact. 73:467–472, 1957.

Herndon, R. M., Rubinstein, L. J., Freeman, J. M., and Mathieson, G. Light and electron microscopic observations on Rosenthal fibers in Alexander's disease and multiple sclerosis. J. Neuropath. Exp. Neurol. 29:525–551, 1970.

Hossmann, K. A., and Wechsler, W. Zur Feinstruktur menschlicher Spongioblastome. Deutsch. Z. Nervenheilk. 187: 327–351, 1965.

Kernohan, J. W., and Sayre, G. P. Tumors of the Central Nervous System. Fascicle 35, Atlas of Tumor Pathology. Washington: Armed Forces Institute of Pathology, 1952.

Kersting, G. Tissue Culture of Human Gliomas, pp. 165–202. In: Progress in Neurological Surgery, Vol. 2. (Eds.) Krayenbühl, H., Maspes, P. E., and Sweet, W. H. Chicago: Year Book Medical Publishers, Inc., 1968.

Lumsden, C. E. The Study by Tissue Culture of Tumours of the Nervous System, pp. 334–420. In: Russell, D. S., and Rubinstein, L. J. Pathology of Tumours of the Nervous System, 3d ed. London: Edward Arnold, 1971.

Luse, S. A. Electron microscopic studies of brain tumors. Neurology 10:881–905, 1960.

McCormick, W. F., Gerber, H. W., and Mergner, W. J. Prolonged survival with extensive astrocytoma. Case report. J. Neurosurg. 27:449–455, 1967.

Peters, A., Palay, S. L., and Webster, H. de F. The Fine Structure of the Nervous System. The Cells and Their Processes. New York: Hoeber Medical Division, Harper & Row, 1970.

Pool, J. L., and Kamrin, R. P. The Treatment of Intracranial Gliomas by Surgery and Radiation, pp. 258–299. In: Progress in Neurological Surgery, Vol. 1. (Eds.) Krayenbühl, H., Maspes, P. E., and Sweet, W. H. Chicago: Year Book Medical Publishers, Inc., 1966.

Poser, C. M. The Relationship Between Syringomyelia and Neoplasm. Springfield, Ill.: Charles C Thomas, 1956.

Raimondi, A. J. Ultrastructure and the Biology of Human Brain Tumors, pp.. 1–63. In: Progress in Neurological Surgery, Vol. 1. (Eds.) Krayenbühl, H., Maspes, P. E., and Sweet, W. H. Chicago: Year Book Medical Publishers, Inc., 1966.

Russell, D. S., and Bland, J. O. W. Further notes on the tissue culture of gliomas with special reference to Bailey's spongioblastoma. J. Path. Bact. 39:375–380, 1934.

_____, and Rubinstein, L. J. Pathology of Tumours of the Nervous System, 3d ed. London: Edward Arnold, 1971.

Scherer, H. J. Structural development in gliomas. Amer. J. Cancer 34:333–351, 1938.

_____. Cerebral astrocytomas and their derivatives. Amer. J. Cancer 40:159–198, 1940.

Schlote, W. Rosenthalsche "Fasern" und Spongioblasten im Zentralnervensystem. II. Elektronenmikroskopische Untersuchungen. Bedeutung der Rosenthalschen "Fasern". Beitr. path. Anat. 133:461–480, 1966.

Schulz, M. D., Wang, C-C., Zinninger, G. F., and Tefft, M. Radiotherapy of Intracranial Neoplasms, pp. 318–370. In: Progress in Neurological Surgery, Vol. 2. (Eds.) Krayenbühl, H., Maspes, P. E., and Sweet, W. H. Chicago: Year Book Medical Publishers, Inc., 1968.

Slooff, J. L., Kernohan, J. W., and MacCarty, C. S. Primary Intramedullary Tumors of the Spinal Cord and Filum Terminale. Philadelphia: W. B. Saunders Co., 1964.

Solomon, A., Perret, G. E., and McCormick, W. F. Multicentric gliomas of the cerebral and cerebellar hemispheres. J. Neurosurg. 31:87–93, 1969.

Willis, R. A. Pathology of Tumours, 3d ed. London: Butterworth & Co., Ltd., 1960.

_____. The Pathology of the Tumours of Children, p. 28. Springfield, Ill.: Charles C Thomas, 1962.

Wolman, L. Infundibuloma. J. Path. Bact. 77:283–296, 1959.

Zülch, K. J. Brain Tumors. Their Biology and Pathology, 2d American ed., pp. 147–153. New York: Springer Publishing Co., 1965.

ASTROBLASTOMA

DEFINITION AND CYTOGENESIS. This tumor, originally described by Bailey and Bucy, presumably arises from mature astrocytes, but has a characteristic histologic picture from which its name is derived. Because of its rarity in a pure form, its existence is sometimes questioned. Some authors classify it as a subgroup of the astrocytomas and make little distinction between it and the gemistocytic astrocytoma. It is also true that foci of astroblastomatous tumor may sometimes be found in glioblastomas or dedifferentiated cerebral astrocytomas. Despite its rarity it deserves separate consideration as a clinicopathologic

entity. Its natural history places it between the astrocytoma and the glioblastoma.

INCIDENCE. The majority of astroblastomas are found in young subjects, usually in the second or third decades. The cerebral hemispheres are the usual sites; occasionally they arise in the cerebellum or even the spinal cord.

GROSS. The tumor is well circumscribed. Where viable tissue is present, its cut surface is homogeneous grayish or pink and soft (pl. I-D). Small foci of necrosis and hemorrhage are frequent. Either small or large cysts may be present. Calcification is not a feature.

MICROSCOPIC. The tumor is highly cellular and shows a typical arrangement around blood vessels with the formation of perivascular pseudorosettes (fig. 31). It is richly vascular, the blood vessels being either thin-walled or occasionally thickened, hyaline, and acellular. In areas which have undergone necrosis, intense and highly vascularized mesenchymal proliferation may be present. The tumor cells are usually relatively small, triangular or rectangular, with their cell bodies directed toward the blood vessel walls, to which they are attached by delicate foot processes or terminal cytoplasmic expansions. Foot processes are often

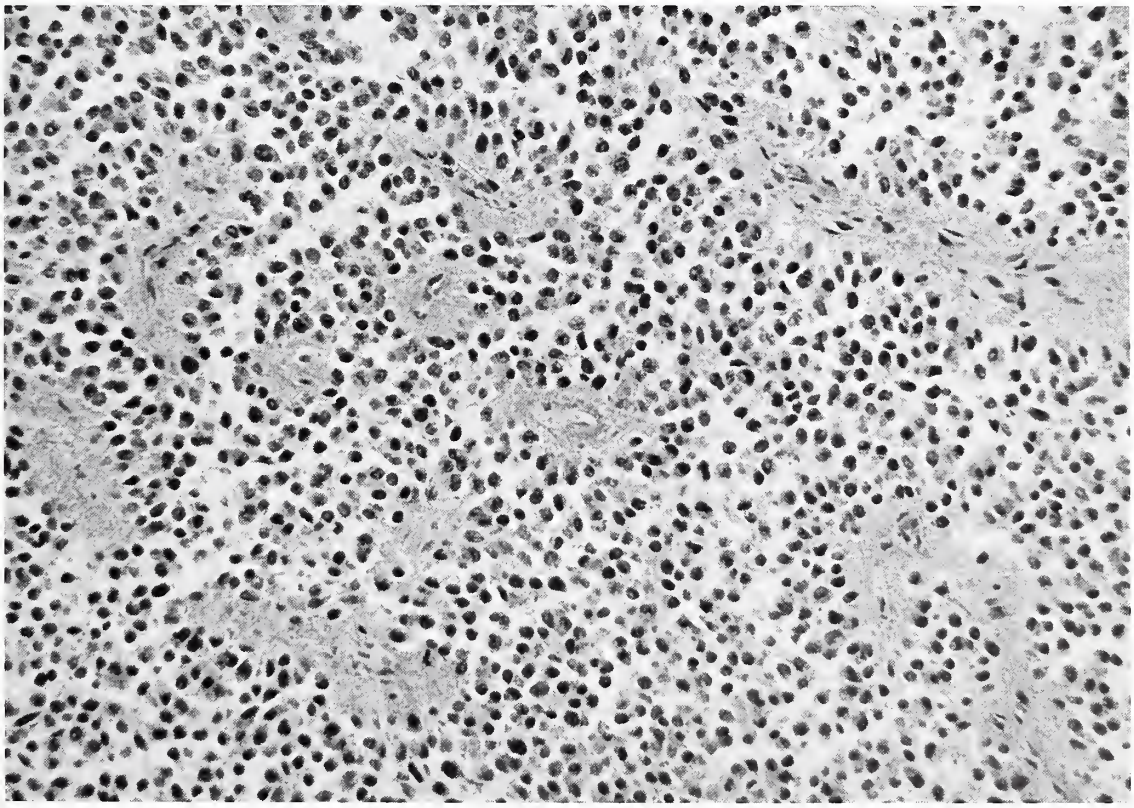

ASTROBLASTOMA

Figure 31. This microscopic view of a large circumscribed right temporal lobe tumor in a 28-year-old woman shows the typical arrangement of astroblastic cells around blood vessels forming pseudorosettes. No neuroglial fibers are present. PTAH. × 210.

well demonstrated with appropriate silver impregnations for astrocytes (fig. 32). The tumor has a somewhat loose texture; the intervening spaces between the perivascular pseudorosettes are occupied by the cell bodies of elements whose processes are probably out of the plane of the section. Mitotic figures are usually scant, but necrosis may be extensive. The foci of necrosis are not necessarily associated with increased anaplasia of the tumor, but the latter may take place at a subsequent stage. An important difference from gemistocytic astrocytomas with perivascular pseudorosettes is the sparse to absent neuroglial fibrils in astroblastomas.

BIOLOGIC EVOLUTION. It is difficult to generalize about the natural history of these very rare tumors. It is apparent from Bailey and Bucy's original series that at least some of them do dedifferentiate to glioblastoma multiforme. Nevertheless the prognosis is not necessarily that of a rapidly fatal tumor, and some patients have survived for several years after diagnostic biopsy before recurrence or anaplastic changes have taken place. The prognosis must therefore be regarded as indeterminate.

TREATMENT. The treatment is as radical excision as feasible, followed by radiation therapy.

DIFFERENTIAL DIAGNOSIS. Perivascular pseudorosettes, although characteristic of astroblastomas, are found also in other tumors. Occasionally glioblastomas or anaplastic astrocytomas show focal areas indistinguishable from pure astroblastoma (fig. 32). The gemistocytic astrocytoma (fig. 21) may show perivascular pseudorosettes, but gemistocytes are strongly fibrillated and astroblastomas are not. The other neuroglial tumor with which the astroblastoma is frequently confused is the ependymoma, because the latter too has a characteristic arrangement of perivascular pseudorosettes. However, the ependymoma has more compact texture between the pseudorosettes, and the processes of ependymoma cells directed toward the blood vessels taper to a point. Moreover, ependymomas are often strongly fibrillated. Finally, nonneuroglial tumors too may occasionally show an arrangement of perivascular pseudorosettes: these may be found in metastatic carcinoma, melanoma, and in polymorphic cell sarcoma.

ASTROBLASTS (SILVER IMPREGNATION)

Figure 32. Silver impregnated processes of astroblastic cells are directed toward the wall of a blood vessel in a section from a glioblastoma showing focal astroblastomatous areas. Scharenberg's modification of Hortega's double silver carbonate impregnation. × 360.

References

Bailey, P., and Bucy, P. C. Astroblastomas of the brain. Acta Psychiat. et Neurol. 5:439–461, 1930.

POLAR SPONGIOBLASTOMA

DEFINITION AND CYTOGENESIS. The term "polar spongioblastoma" or "spongioblastoma polare" is often applied to tumors described elsewhere in this fascicle under the subheadings of piloid astrocytoma of the third ventricle, diffuse pontine astrocytoma, astrocytoma of the spinal cord, and cerebellar astrocytoma. For reasons elaborated in detail elsewhere (Russell and Rubinstein; Rubinstein), this appellation does not seem suited to designate these well differentiated forms of astrocytoma. The true polar spongioblastoma as originally defined by Russell and Cairns is a tumor which, in its microscopic appearance and biologic behavior, has the primitive character that warrants its name: the majority of the component cells display the simplified morphologic features that recall the spongioblasts seen in preparations of the cerebrum in 16-week-old embryos. Also in its histologic picture and natural history this tumor has a kinship with some forms of medulloblastoma. Although again a rare neuroglial tumor, its immediately recognizable microscopic characteristics justify its place as a separate clinicopathologic entity.

INCIDENCE. Polar spongioblastomas usually arise in the first or second decade and are usually located in the region of the third or fourth ventricle. Because of their rarity no meaningful statement can be made on their incidence.

GROSS. The tumors are generally well demarcated, grayish white, fairly firm, and often attached to the ventricular wall.

MICROSCOPIC. The histologic picture is highly distinctive. The cells are arranged in parallel fashion, forming fairly compact bands or palisades (fig. 33). The cell groups are separated by a delicate and regularly arranged vascular connective tissue stroma. Vascular endothelial proliferation is usually not found. Under higher power most of the cells are polar with delicate cytoplasmic processes (fig. 34). Neuroglial fibrils are usually scanty. When present they are very delicate and taper from the unipolar or bipolar cytoplasmic extensions of these cells. The nuclei are oval and dark staining. Giant or multinucleated cells, or cellular pleomorphism are not features.

Neuroglial fibrils may, however, be more evident in areas in which the tumor cells begin to differentiate into small stelate astrocytes (fig. 34). Occasionally the tumor shows more extensive areas of differentiation, in which the microscopic picture is identical with the benign cerebellar astrocytoma of childhood. Conversely, foci of polar spongioblastoma are occasionally found in cerebellar astrocytomas.

The palisading of the tumor cells also recalls the rhythmic pattern found in some forms of medulloblastoma, which the polar spongioblastoma resembles by its propensity to spread through the cerebrospinal fluid pathways and its malignant invasive behavior. Occasionally also foci of "pure" polar spongioblastoma may, like astroblastic foci, be met in isolated fields in glioblastomas or dedifferentiating diffuse cerebral astrocytomas (fig. 27).

SPREAD AND BIOLOGIC EVOLUTION. The biologic behavior of this tumor is in accord with its primitive morphologic character. It tends to be locally invasive and may metastasize widely throughout the cerebrospinal leptomeninges.

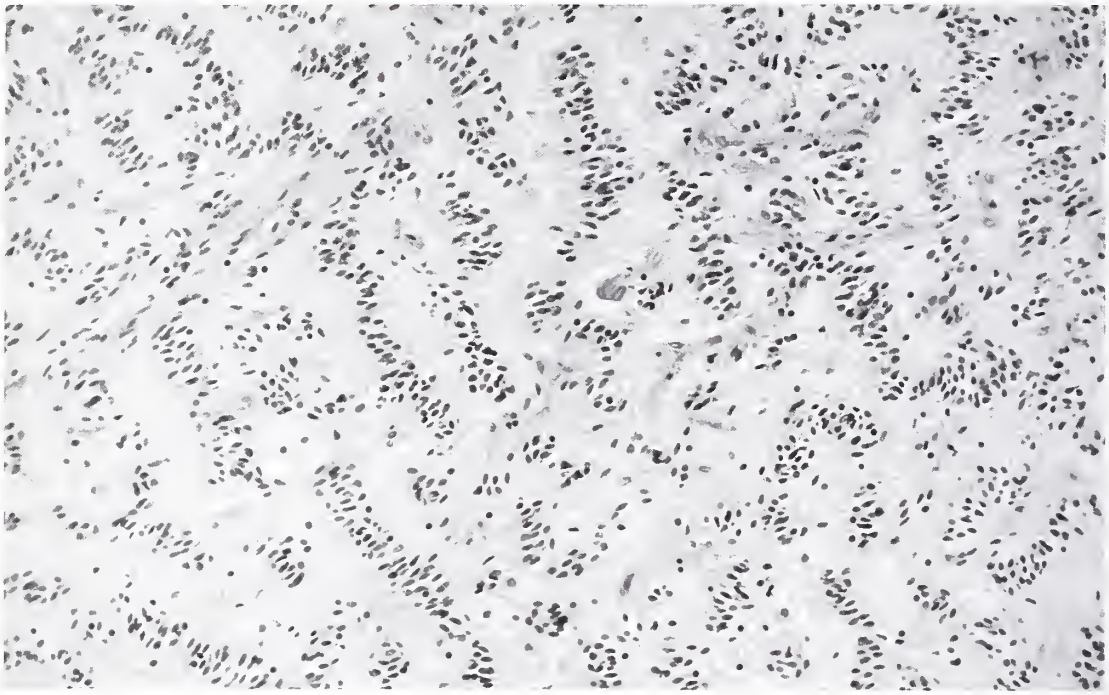

POLAR SPONGIOBLASTOMA

(Figures 33 and 34 from same case)

Figure 33. This overall view of a fourth ventricle tumor in a 2½-year-old boy shows the typical palisading arrangement of cells. × 190.

POLAR SPONGIOBLASTOMA

(Figures 33 and 34 from same case)

Figure 34. Many of the cells are polar with delicate cytoplasmic processes. Note occasional differentiation to small stellate fibrillary astrocytes. PTAH. × 315.

Fig. 34

TREATMENT. Polar spongioblastomas should be treated like medulloblastomas. Therefore radiation of the entire neuraxis is the treatment of choice.

PROGNOSIS. The prognosis of these tumors is poor in view of their primitive character and their tendency to seed through the cerebrospinal fluid pathways. In some cases, however, the presence of extensive areas of more mature astrocytoma may invite a somewhat more favorable prognosis, with the hope that this may indicate an attempt on the part of the tumor to differentiate. Polar spongioblastomas are so rare that limited experience should dictate caution in offering a prognosis on the basis of a biopsy.

DIFFERENTIAL DIAGNOSIS. The histologic picture is so characteristic that there is little difficulty in recognizing the tumor at first glance. Some medulloblastomas, however, have a rhythmic pattern which resembles that of the polar spongioblastoma. Occasionally the arrangement of the cells toward the blood vessels recalls the structure of an ependymoma, but the resemblance is remote.

References

Rubinstein, L. J. Discussion on polar spongioblastomas. Acta Neurochir. Supp. X:126–132, 1964.

Russell, D. S., and Cairns, H. Polar spongioblastomas. Arch. Histol. (B. Air.) 3:423–441, 1947.

———, and Rubinstein, L. J. Pathology of Tumours of the Nervous System, 3d ed. London: Edward Arnold, 1971.

GLIOBLASTOMA MULTIFORME

SYNONYMS AND RELATED TERMS: Glioblastoma; spongioblastoma multiforme; astrocytomas grades 3 and 4.

DEFINITION AND CYTOGENESIS. This tumor represents the most anaplastic form of primary intracranial neoplasm in the older age groups. Originally regarded as a glioma derived from and composed of primitive embryonal cells, it is now widely accepted as an extreme manifestation of anaplasia and dedifferentiation on the part of mature glial tumor cells, mostly astrocytic. This view has led Kernohan and Sayre to discard the term glioblastoma altogether and replace it with the designation of astrocytoma grades 3 and 4. However, the name is so firmly entrenched in the literature that it is felt little is gained by not retaining it, especially since there are examples in which an astrocytic derivation is not really evident. The pros and cons of these arguments have been extensively discussed elsewhere (Russell and Rubinstein) in the additional context of Scherer's (1940) conception of the existence of two types of glioblastoma: one arising *de novo* (primary), and one that is clearly the result of dedifferentiation in a preexisting astrocytoma (secondary). In the light of personal experience, it was estimated that 60 percent of glioblastomas examined postmortem belong to the "primary" group of Scherer, but that even in these tumors searching microscopic examination frequently discloses a likely origin from rapidly growing dedifferentiating astrocytomas (Russell and Rubinstein). It was therefore concluded that most examples of glioblastomas are probably derived by anaplasia from a preexisting astrocytoma of relatively restricted size, and that their characteristic appearances can be attributed to the rapid progression of anaplastic changes spreading throughout the entire neoplastic area. Yet the difficulties presented by this problem were too great to allow of dogmatism, and in the present state of our knowledge the name glioblastoma had better be retained.

INCIDENCE. This tumor usually accounts for over 50 percent of all primary

gliomas. Its peak age incidence is between 45 and 55 years, but it may arise at any age. I have examined a congenital example in the right basal ganglia of a stillborn infant. Males are more frequently afflicted than females by a ratio of 3 to 2.

CLINICAL DATA AND NATURAL HISTORY. This rapidly growing tumor usually causes symptoms of less than six months duration prior to seeking medical assistance. Aside from signs referable to generalized increased intracranial pressure, focal symptoms are related to the localization of the neoplasm within the brain. Those in a frontal lobe or in the anterior part of the corpus callosum and spreading bilaterally into the hemispheres often cause symptoms of rapidly progressive dementia. Some examples arising in a previously slowly growing astrocytoma may have a longer history of several years of focal signs, such as epilepsy, upon which a dramatic acceleration of the intracranial symptoms has supervened.

SITES. MULTIPLICITY. ASSOCIATED LESIONS. Glioblastomas may arise in any part of the central nervous system, but there is general agreement that the frontal lobe is the most frequent site (figs. 35, 57; pl. III-A). Second in frequency is the temporal lobe. The central part of the brain is often involved, especially the corpus callosum. The cerebellum is a rare site; more often the tumor in the cerebellum is an astrocytoma with progressive features of dedifferentiation that fall short of the fullblown picture of glioblastoma. Primary glioblastomas of the pons and medulla are seldom encountered, but secondary glioblastomatous change is a frequent occurrence in the pontine astrocytomas in children (p. 37). The spinal cord is a rare site: 15 examples of grade 3 and 5 cases of grade 4 astrocytoma are analyzed in the monograph by Slooff and associates.

Multiple foci of glioblastoma are sometimes found (figs. 35, 57). As indicated in the Introduction of this fascicle (p. 10) the incidence of multiple glioblastomas has been estimated between 2.5 and 4.9 percent of all primary gliomas. An association of glioblastoma and meningioma in a different part of the cerebrum has occasionally been recorded (Alexander). I have personally examined five such examples: no statistical significance appears to be attached to this concomitance. An association of glioblastoma with multiple sclerosis has occasionally been found (p. 5), but its significance is obscure.

GROSS. To the naked eye the glioblastoma often appears relatively well circumscribed, but its margins are ill-defined. The most characteristic macroscopic feature is the highly variegated cut surface of the neoplasm: grayish or pinkish foci of moderately firm, viable growth alternate with extensive areas of creamy yellow necrosis and red or brown foci of recent or old hemorrhage. The latter are frequent, but seldom extensive. The marked increase of vascularization of the tumor is sometimes manifest by the presence of small pinpoint petechiae, which represent the cut surfaces of small enlarged blood vessels. Cysts may be present (pl. III-A) and are occasionally multiple. Occasionally a single large cyst occupies much of the neoplasm. The cut surface is usually soft, but where extensive necrosis has taken place, intensive mesenchymal proliferation may give the tumor a firmer consistency. A similar phenomenon is found when the tumor abuts onto the pial surface and becomes firmly attached to the leptomeninges and in some cases to the dura.

In such cases when a surface tumor is presented to the neurosurgeon, abnormal firmness and the whitish homogeneous appearance may invite at first the mistaken impression of a meningioma; further exploration of its deeper part then clearly demonstrates its soft glial consistency and invasive character. Multiplicity may be seen with two or more widely separated tumor masses (fig. 57), or more often as one large mass with a small separate satellite focus (fig. 35).

The outline of the tumor is usually globular when it occupies the central white matter; those in the frontal lobe not uncommonly invade the basal ganglia and those in the temporal lobe often do so, with further extension into the brainstem. A classic appearance is provided by the so-called "butterfly" type (pl. III-D), in which a central glioblastoma occupying the corpus callosum extends bilaterally into the medial portions of each centrum semiovale.

MICROSCOPIC. The histologic picture of glioblastoma multiforme varies considerably. The tumor is always highly cellular, but the cells may be either fairly uniform or extremely pleomorphic, with many intermediary stages between the two within the same example. In wet films obtained at surgery for diagnostic purposes the tumor smears easily. Its high cellularity, its relatively poor differentiation, the lack of cytoplasmic fibrillated processes, and the pleomorphic darkly staining nuclei usually permit an easy diagnosis of anaplastic glioma (pl. III-B). Often, however, the tumor cells are so undifferentiated that their astrocytic origin may hardly be recognized in sections (fig. 36). Other fields contain relatively well differentiated astrocytic tumor cells with hyperchromatic nuclei (fig. 37). Some areas show marked pleomorphism of the tumor cells with many mitotic figures, often atypical (figs. 38, 39), while others consist largely of elongated, fusiform cells, to which the name "spongioblast" is frequently given.

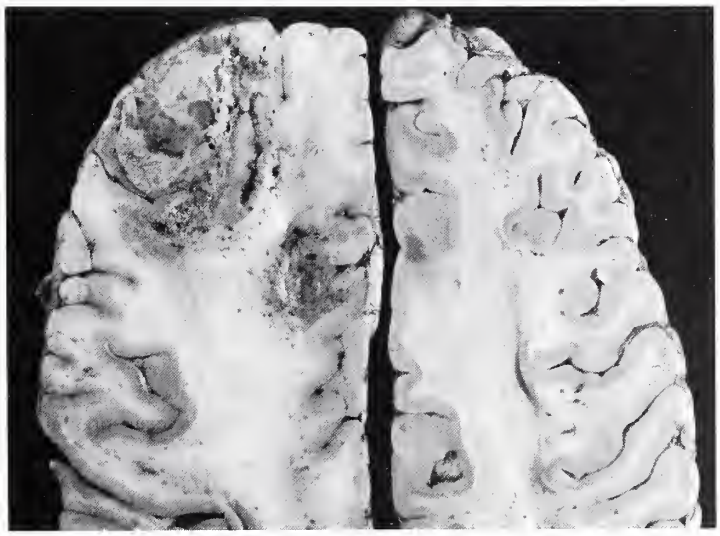

GLIOBLASTOMA

Figure 35. This multicentric glioblastoma shows two distinct foci of relatively well defined variegated tumor, with areas of hemorrhage and necrosis, occupying the left frontal cortex and subcortical white matter. (Courtesy of the Armed Forces Institute of Pathology).

PLATE III

FRONTAL GLIOBLASTOMA MULTIFORME

A. This large inferior frontal glioblastoma multiforme was found in a 59-year-old woman. Two large cysts containing brownish gelatinous material are present in the center of the tumor. Note the right cingulate herniation.

SMEAR FROM A GLIOBLASTOMA

B. This pleomorphic cellular tumor is composed of cells showing darkly staining irregular nuclei and ill-defined cytoplasmic outlines and processes. The anaplastic and poorly differentiated features and the darkly staining nuclei indicate a malignant anaplastic glioma. Morris. × 400.

LEPTOMENINGEAL SPREAD IN GLIOBLASTOMA

(Plate III-C and Figure 72 from same case)

C. This glioblastoma multiforme arose from the floor of the third ventricle and spread widely throughout the cerebrospinal leptomeninges and ventricles. The base of the brainstem is covered by a gelatinous neoplastic exudate which obscures its surface and the cranial nerves.

SARCOMA ARISING IN A GLIOBLASTOMA MULTIFORME

D. An extensive necrotic central glioblastoma of the "butterfly" type occupies the posterior part of the corpus callosum and infiltrates the medial parietal white matter on both sides. Below and to the right of the main mass there is a distinct, apparently separate nodule, mostly homogeneous and grayish white, and slightly hemorrhagic along its periphery. Microscopically this represents a discrete focus of fibrosarcoma arising in a glioblastoma multiforme.

MIXED GLIOBLASTOMA AND FIBROSARCOMA

(Plate III-E and Figures 64–67 from same case)

E. This is the characteristic marmoreal pattern of glioblastoma (pale yellow areas) infiltrated by blue-staining fibroblastic zones. Azocarmine. × 120.

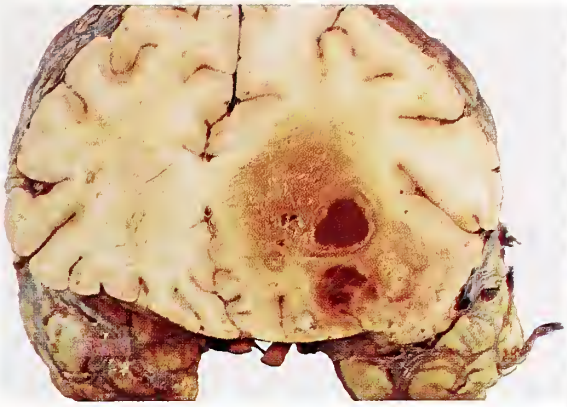

A

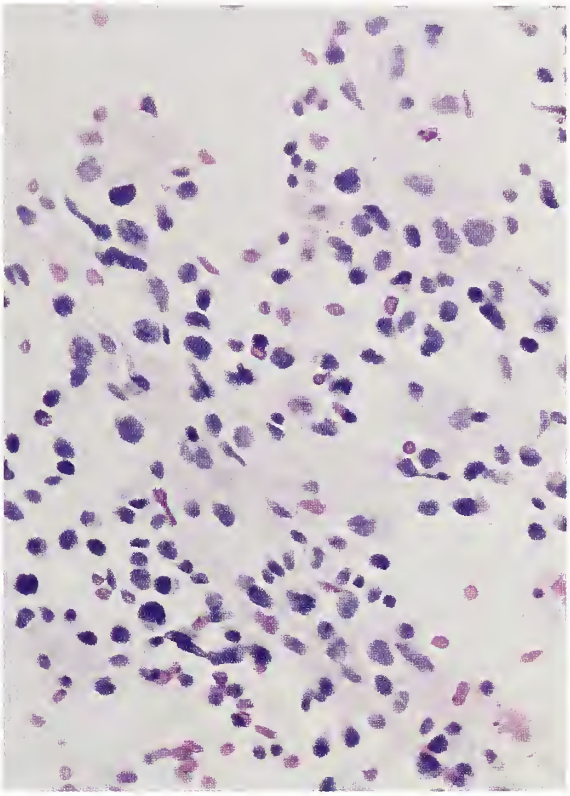

B

C

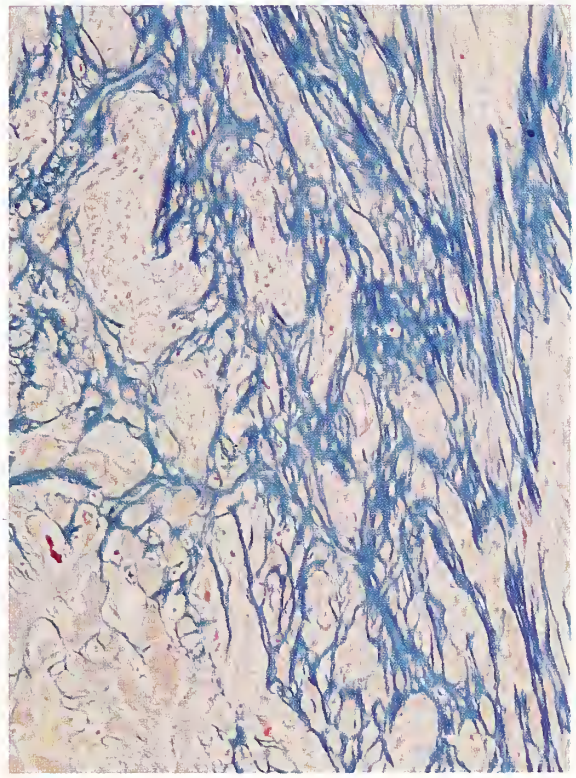

E

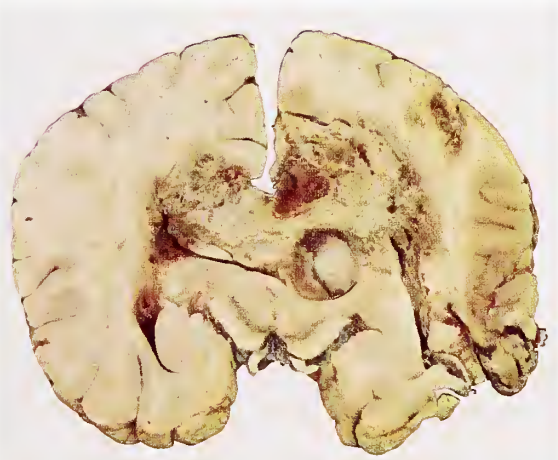

D

PLATE III

GLIOBLASTOMA MULTIFORME

(Figures 36, 43, 70, and 71 from same case)

Figure 36. Undifferentiated pleomorphic tumor cells are seen in glioblastoma multiforme. Several of these may be faintly recognized as astrocytic. Note mitotic figure. × 445.

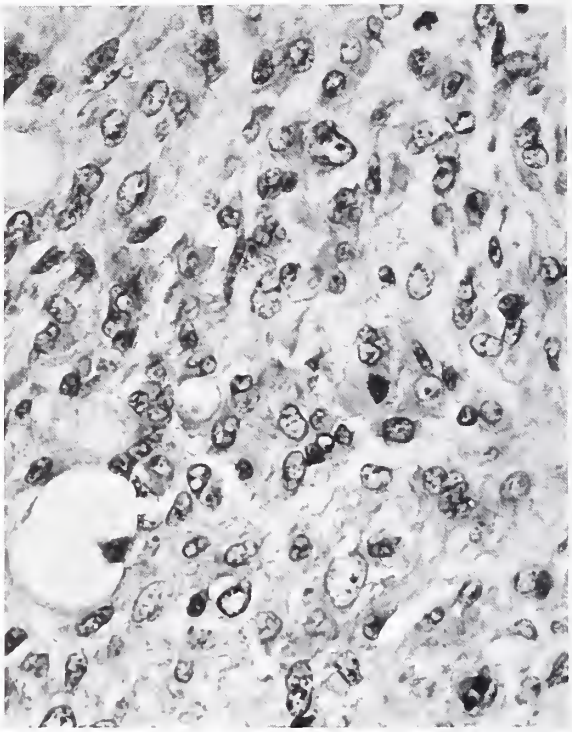

Fig. 36

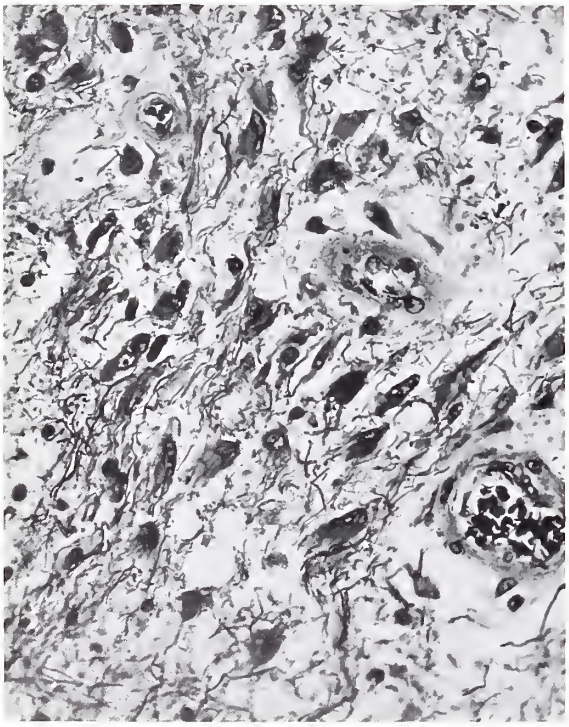

Fig. 37

GLIOBLASTOMA MULTIFORME

Figure 37. These relatively well differentiated but pleomorphic astrocytic cells are also seen in a glioblastoma multiforme. PTAH. × 330. (Fig. 4 from Russell, D. S., and Rubinstein, L. J. Ganglioglioma: A case with long history and malignant evolution. J. Neuropath. Exp. Neurol. 21:185–193, 1962).

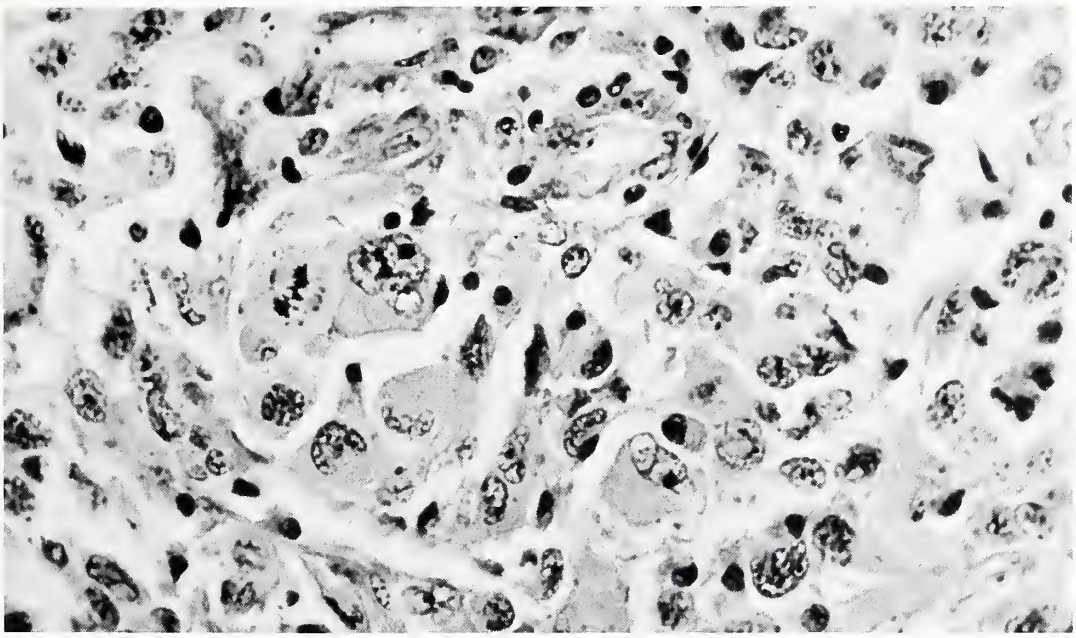

GLIOBLASTOMA MULTIFORME

(Figures 38, 39, 44, and 45 from same case)

Figure 38. Multiforme appearance of the histologic picture is evident. The tumor cells show marked pleomorphism, with irregular hyperchromatic nuclei. This is a highly anaplastic area, in which the astrocytic origin of the tumor cells cannot be recognized. Note the mitotic figures. PTAH. × 450.

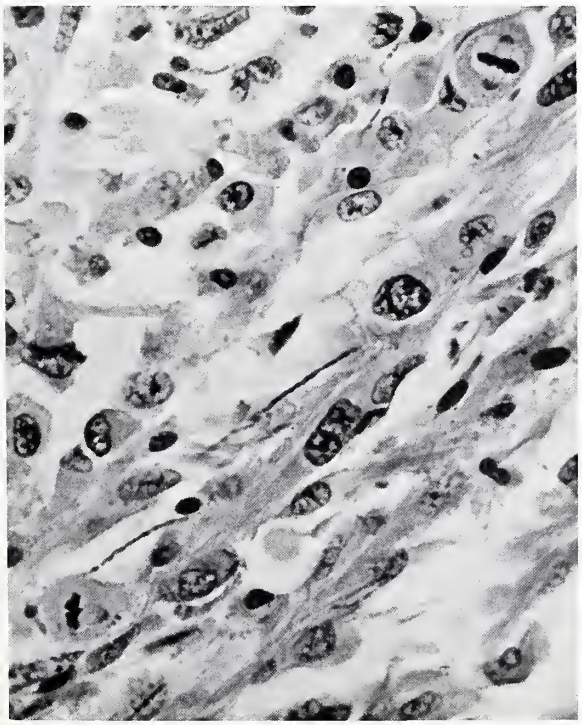

Fig. 39

MITOTIC FIGURES IN GLIOBLASTOMA MULTIFORME

Figure 39. In another field note the marked cellular atypia, with mitotic figures in upper right and lower left corners. PTAH. × 540.

These are usually anaplastic cells of astrocytic lineage, since neuroglial fibrils can often be demonstrated with the appropriate stains (fig. 40). These cells frequently tend to cluster around central areas of incipient or more severe necrosis, resulting in the classic appearance of pseudopalisades, a virtually diagnostic microscopic feature of glioblastoma multiforme (fig. 41; pl. XV-B).

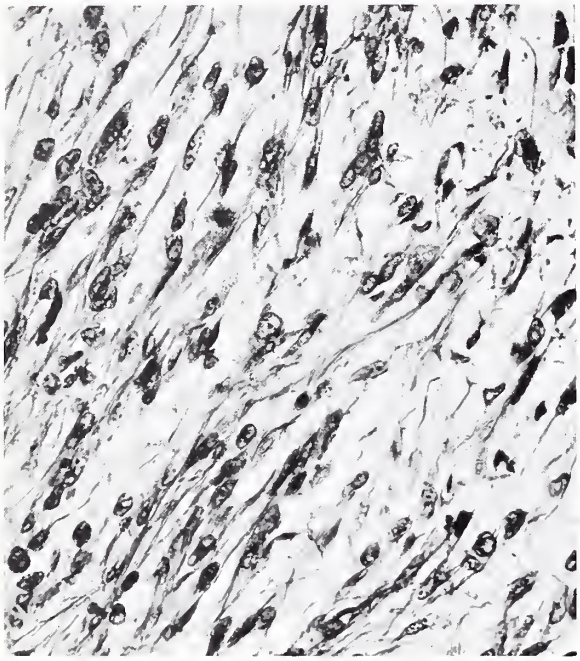

Fig. 40

"SPONGIOBLASTS" IN GLIOBLASTOMA MULTIFORME

Figure 40. This is a "spongioblastic" area in a glioblastoma multiforme. Many of the tumor cells are fusiform. They are sometimes called "spongioblasts," but should more properly be regarded as anaplastic tumor cells of astrocytic lineage. Strongly fibrillated cell processes and neuroglial fibrils are well demonstrated. PTAH. × 330.

Other areas consist largely of small round or oval cells with very ill-defined cytoplasmic outlines (fig. 42). In these an astrocytic origin is not evident and the possibility that they may represent anaplastic forms of oligodendrocytes cannot be dismissed; however, impregnation for oligodendrocytes with special silver carbonate technics are usually negative. Giant and multinucleated forms

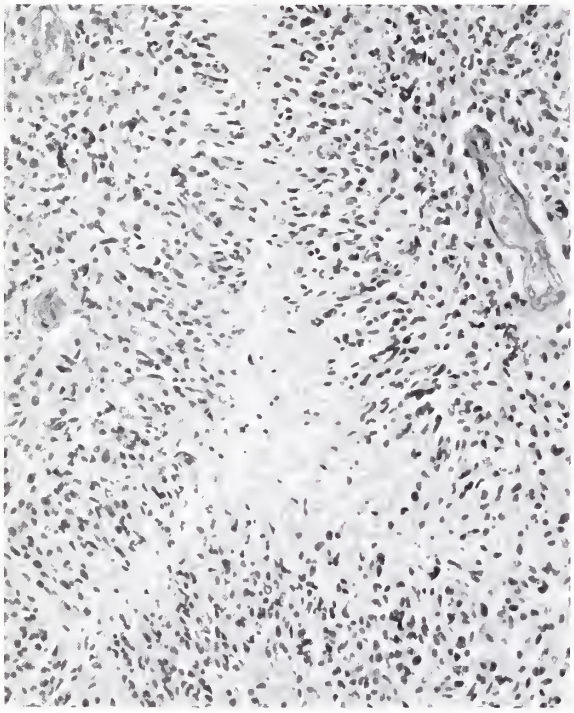

GLIOBLASTOMA. PSEUDOPALISADES

Figure 41. This area of pseudopalisading with central necrosis is typical of a glioblastoma multiforme. × 175.

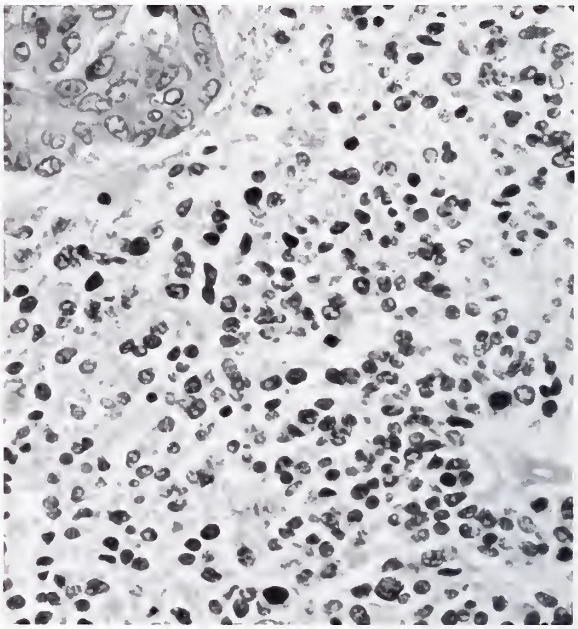

GLIOBLASTOMA MULTIFORME

Figure 42. This is a microcellular area in a glioblastoma. In this field many tumor cells show round or oval nuclei with very ill-defined cytoplasmic outlines. The nuclei are hyperchromatic. Vascular endothelial proliferation is present. The tumor cells are quite undifferentiated and no statement as to their cytogenesis is possible. × 400.

are frequent in glioblastomas, and may sometimes dominate the picture. A few tumors display this feature so prominently that they have been regarded by some authors as forming a separate group: they are briefly considered as a variant of the glioblastomas in this fascicle (p. 72). In many otherwise typical glioblastomas, however, foci of irregular and highly anaplastic giant cells are often found (fig. 43), clearly reflecting the high grade of malignancy of this neoplasm.

Both intranuclear (fig. 44) and cytoplasmic (fig. 45) inclusion bodies are frequently encountered in glioblastomas. Recent electron microscopic observations suggest that most if not all intranuclear inclusion bodies (fig. 44) are in fact cytoplasmic inclusions lying within nuclear folds (Robertson and MacLean). The large cytoplasmic inclusion illustrated in figure 45 apparently contains lipid material.

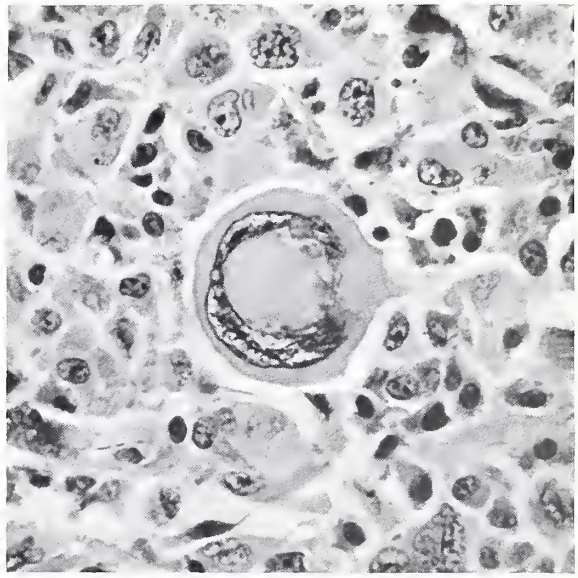

GLIOBLASTOMA MULTIFORME

(Figures 38, 39, 44, and 45 from same case)

Figure 44. A large "intranuclear" inclusion is present in a giant cell in a glioblastoma. This probably represents an inclusion of cytoplasm within nuclear folds. PTAH. × 540.

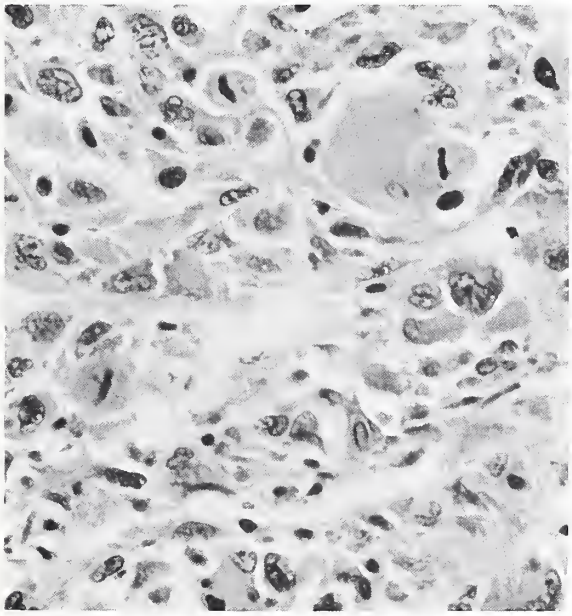

GLIOBLASTOMA MULTIFORME

(Figures 36, 43, 70, and 71 from same case)

Figure 43. Note the highly anaplastic and irregular giant cells with mitoses. × 400.

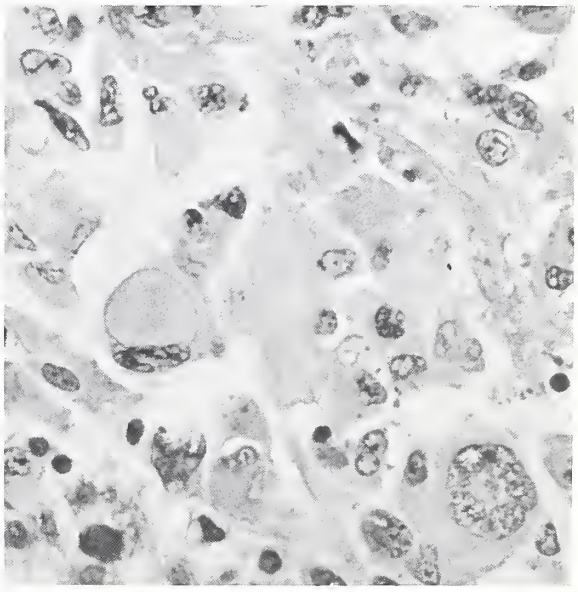

GLIOBLASTOMA MULTIFORME

(Figures 38, 39, 44, and 45 from same case)

Figure 45. The large cytoplasmic inclusion in the cell left of center is filled with lipid material. PTAH. × 540.

Electron microscopic descriptions of glioblastomas stress the considerable pleomorphism of the cells and of the nuclear configuration (Luse; Raimondi). The cell membranes show frequent foldings. A marked increase of mitochondria has also been noted. Many tumor cells have intracytoplasmic glial filaments, which support the view that such cells are anaplastic astrocytes.

The **vascular changes** that accompany the growth of glioblastoma multiforme both within the tumor and in the adjacent brain are of considerable interest and have long been emphasized. The most characteristic change consists in a marked proliferation of the endothelium of the small capillaries feeding the tumor, with the formation of tufts composed of heaped endothelial cells somewhat resembling renal glomeruli (fig. 46). The nuclei of the endothelial cells are often enlarged and mitotic figures may be present among them. Another change consists of focal increases of thin-walled capillary blood vessels, producing a telangiectatic pattern (fig. 47). Thromboses are often seen in these small clustered blood vessels. Organization and subsequent vascularization of these mural thrombi may give rise to further proliferative vascular changes.

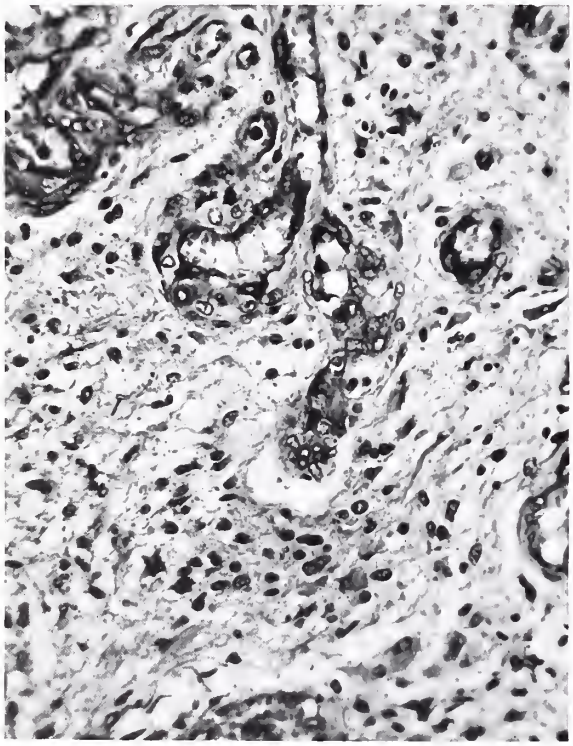

GLIOBLASTOMA MULTIFORME
VASCULAR PATTERNS

(Figures 46, 173–178, and Plate V-D from same case)

Figure 46. Vascular endothelial proliferation is prominent in glioblastoma multiforme. Hyperchromatic endothelial cells form new capillary blood vessels. PTAH. × 300.

GLIOBLASTOMA MULTIFORME
VASCULAR PATTERN

Figure 47. This telangiectatic pattern is seen in a highly vascular small cell glioblastoma multiforme. Many thin-walled blood vessels are closely clustered in this field. ×60.

Sometimes the lumen of tumor vessels may be almost occluded by connective tissue fibers, presumably by proliferation of fibroblasts, although an endothelial origin cannot be excluded. These alterations (fig. 48) may represent an early stage of the sarcomatous transformation that is occasionally found in glioblastoma multiforme and will be described on page 74. Another type of fibroblastic proliferation may consist in a perivascular increase of fibrous connective tissue around a blood vessel, producing a characteristic lacy pattern (fig. 49). This again may possibly herald the formation of a perivascular fibrosarcoma arising in a glioblastoma.

GLIOBLASTOMA MULTIFORME
VASCULAR PATTERN

(Figures 48 and 49 from same case)

Figure 48. This intravascular proliferation of connective tissue fibers in the blood vessels of a glioblastoma may represent an early stage toward a fibrosarcomatous change arising from the blood vessel walls. Silver stain for reticulin. × 100.

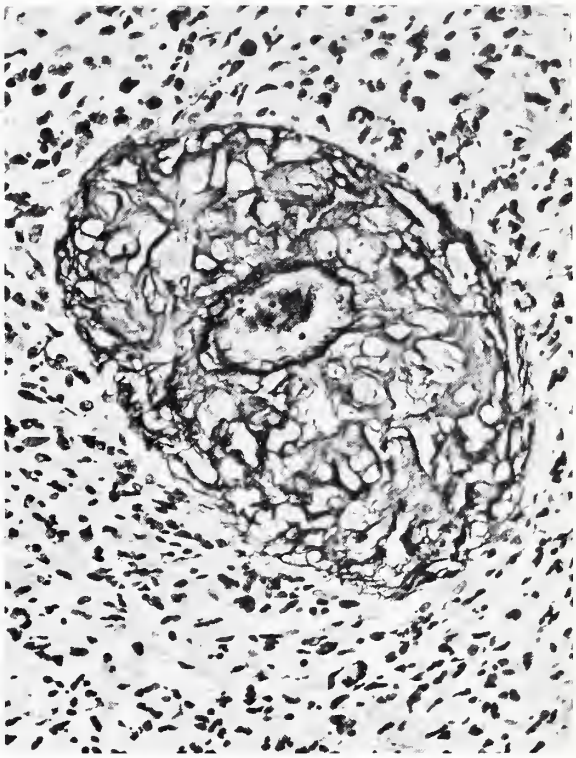

GLIOBLASTOMA MULTIFORME
VASCULAR PATTERN

(Figures 48 and 49 from same case)

Figure 49. This perivascular proliferation of fibrous connective tissue in a glioblastoma forms a characteristic lacy pattern. Silver stain for reticulin. × 200.

An intriguing feature of this type of vascular reaction is that it is not uncommonly found in the normal or reactive brain tissue adjacent to the tumor. This in itself has often been regarded as antecedent to its growth and spread. A remarkable sequence of this event is illustrated in figures 50 through 53. They depict the burgeoning proliferation of vascular endothelial cells beneath the ventricular ependyma, which then ruptures due to the advancing endothelial cells, a phenomenon that clearly precedes the growth of an underlying glioblastoma as it progresses toward and beyond the ventricular surface.

GLIOBLASTOMA MULTIFORME, VASCULAR PATTERNS

Note: Figures 50 through 53 are from the same case and illustrate the various stages of vascular endothelial proliferation that may precede the growth of a glioblastoma as it advances toward the ventricular surface.

Figure 50. Beneath the ventricular ependyma are a few clusters of endothelial cells from newly formed capillaries. Some of them are in close apposition to the ependymal surface, but have not yet ruptured through it. × 290.

Figure 51. At this stage, clusters of endothelial cells have ruptured through the ependyma into the ventricular cavity. × 130.

Figure 52. A more severe stage of this irruption of the vascular endothelium through the ependyma is seen. Small darkly staining tumor cells are present near the proliferating endothelial cells. × 100.

Figure 53. In this field the extensive proliferation of vascular endothelial cells into the cavity of the ventricle is accompanied by obvious invasion of the latter by darkly staining glial cells from a neighboring glioblastoma multiforme. × 100.

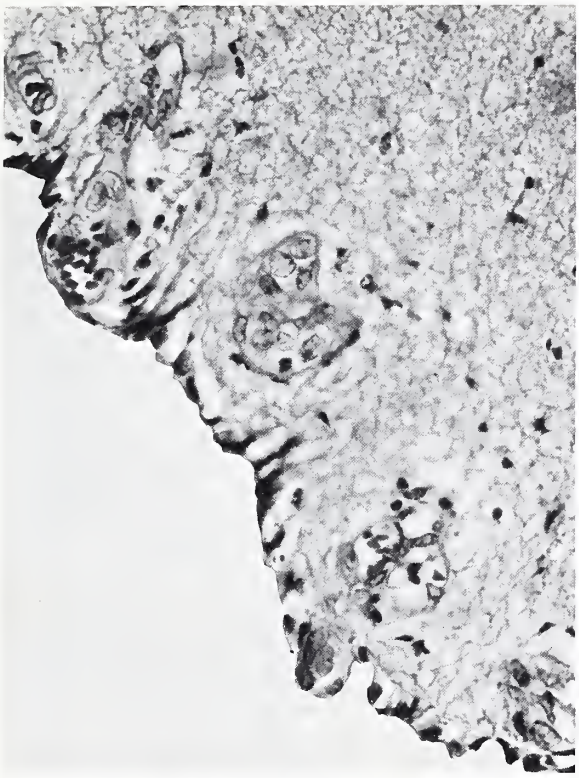

Fig. 50

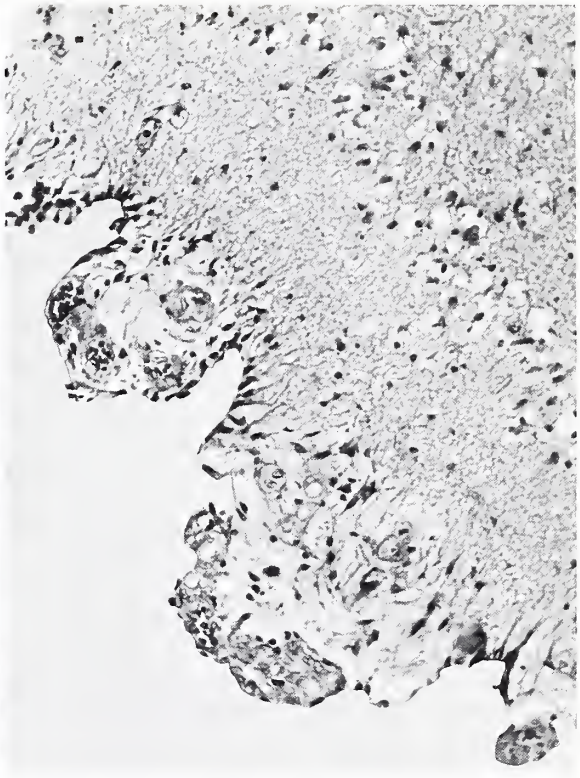

Fig. 51

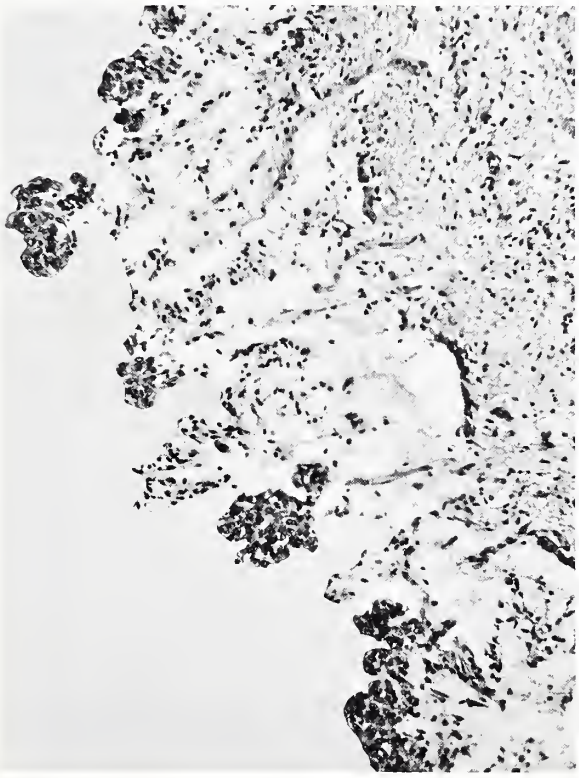

Fig. 52

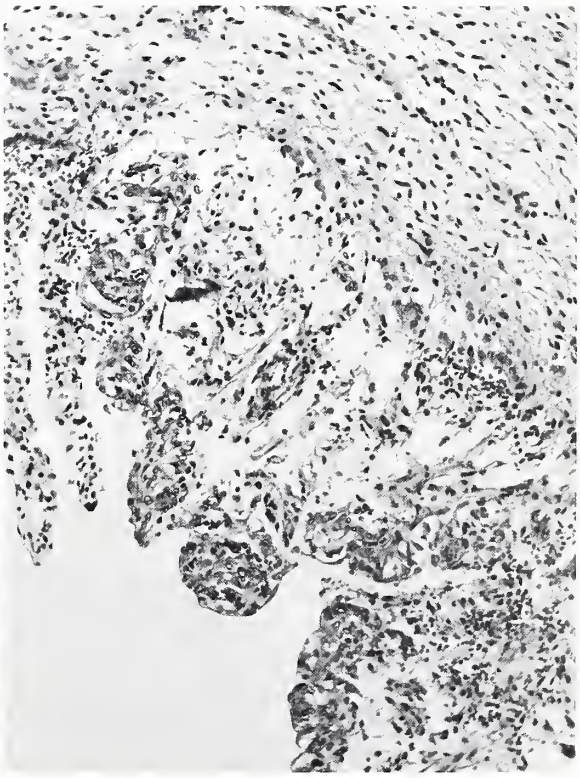

Fig. 53

Although vascular endothelial proliferation is classically associated with glioblastoma multiforme, it is not entirely restricted to it. It is not infrequently encountered in otherwise benign cerebellar astrocytomas and in pilocytic astrocytomas of juvenile type (pp. 32, 35); it is also a frequent finding in oligodendrogliomas (p. 96). In the three above cited tumors this feature does not denote histologic malignancy. All forms of progressive vascular changes from hyperplasia to frank neoplasia have been described (Feigin et al.). It is apparent that vascular endothelial proliferation in the brain is also found in association with nonglial tumors, as for example around metastatic carcinomas, but here the proliferation is much less dramatic than in glioblastomas. This curious phenomenon is not necessarily restricted to glial tumors within the central nervous system. Figure 54 illustrates the remarkable occurrence of vascular endothelial proliferation among gemistocytic astrocytes that occupy a cervical lymph node in a case of glioblastoma multiforme that metastasized extracranially. Whether the proliferating endothelial cells are derived from actual metastatic transfer of original stromal elements which accompanied the tumor within the brain, or whether they are the result of stroma-inductive influences by the metastasized glial cells upon the infiltrated lymph node cannot be decided, but the problem lends itself to experimentation.

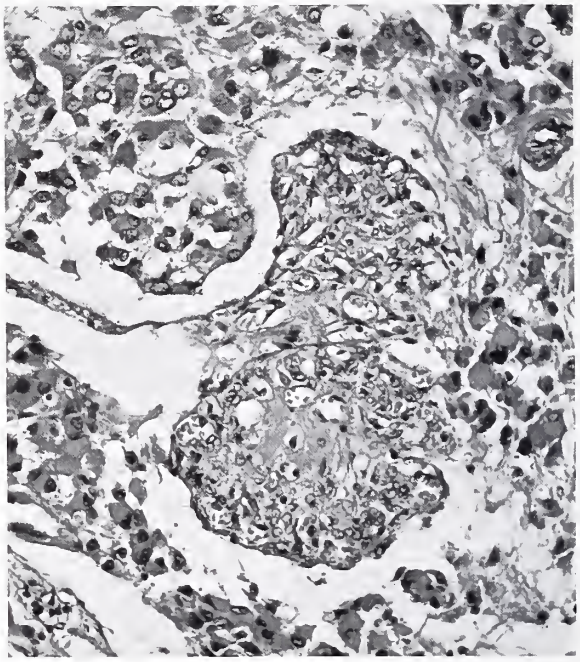

VASCULAR ENDOTHELIAL PROLIFERATION IN EXTRANEURAL METASTASIS OF A GLIOBLASTOMA

(Figures 54 and 79 from same case)

Figure 54. Vascular endothelial proliferation is present among the astrocytoma cells that occupy a cervical lymph node following extraneural spread of a glioblastoma multiforme. ×180.

GROWTH AND SPREAD. SECONDARY FEATURES. Although often relatively well circumscribed on gross examination, glioblastomas virtually always show a variable extent of microscopic infiltration further afield. Like other diffusely invasive gliomas they often display the secondary structures of Scherer (1938), in particular subpial and subependymal aggregates of tumor cells at some distance from the main mass (fig. 56). Intrafascicular and perifascicular structures are also frequent. As tumor reaches the brain surface it readily infiltrates the **leptomeninges.** As a result it may present grossly as a collection of irregular grayish raised nodules on the cortical surface, and the adjacent gyri are often wider, firmer, and darker or paler than normal (fig. 55). Microscopically (fig. 56) invasion of the subarachnoid space over the tumor, or of the Virchow-Robin spaces within it, is readily evident by the characteristic fasciculated pattern that results from the proliferation of fibrous connective tissue elements in the leptomeninges secondary to tumor infiltration.

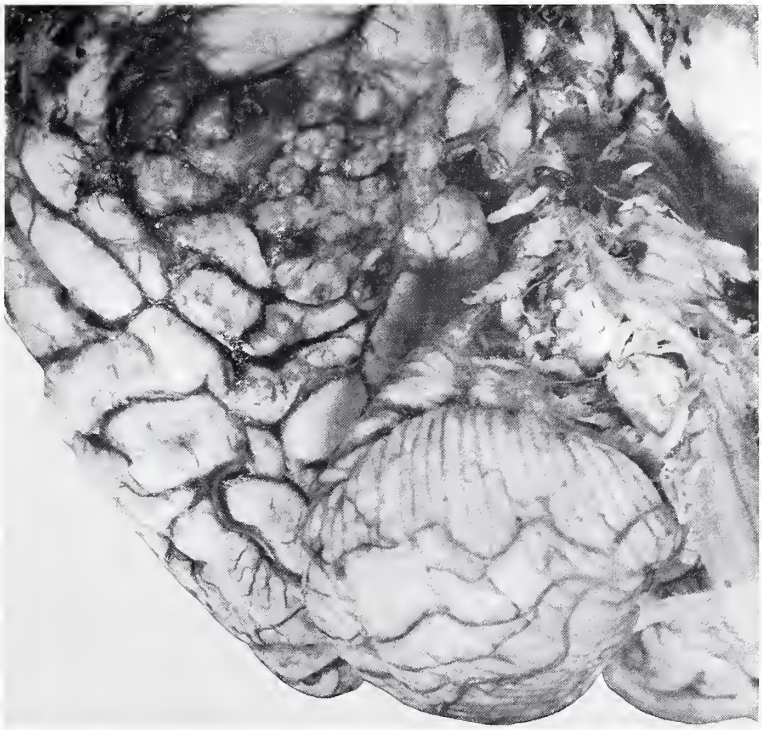

GLIOBLASTOMA MULTIFORME, DIRECT SPREAD

Figure 55. This is the gross appearance of glioblastoma multiforme reaching the pial surface. The cortical surface shows irregular, nodular, grayish elevations, and the adjacent gyri are wider and darker than normal.

LEPTOMENINGEAL INVASION BY GLIOBLASTOMA

Figure 56. Microscopic picture of invasion of the leptomeninges by a glioblastoma multiforme. The fasciculated pattern in the subarachnoid space results from the proliferation of fibrous connective tissue in the leptomeninges consequent to tumor infiltration. Note the subpial secondary structures in the cortex on either side of the leptomeningeal invasion. × 110.

Fig. 56

Subsequent attachment to the **dura** is a frequent sequel. Usually only the inner layer of the dura is invaded, but as a result considerable fibrous connective tissue proliferation occurs that may extend for some distance within the tumor substance. The part of tumor that is attached to the dura may then be unusually firm, sometimes woody hard, and whitish (fig. 57). At operation it may present as a relatively circumscribed mass and may lull the surgeon into the belief that the tumor is a meningioma. As further removal is effected, the diffusely invasive nature of the neoplasm becomes evident. Microscopically the tumor cells near the dura are separated by a rich connective tissue fiber network and become elongated, or pilocytic. They are closely intermingled with the proliferating, usually pale staining fibroblasts (fig. 58), and a biopsy taken from this region may be misinterpreted as a fibrosarcoma. Histologic stains for connective tissue fibers (fig. 59) are highly positive and may further compound the error.

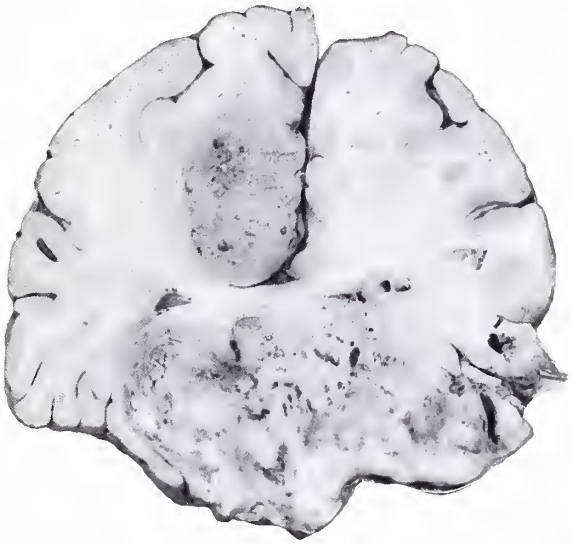

GLIOBLASTOMA MULTIFORME—
MULTIFOCAL GLIOMA, SECONDARY
ATTACHMENT TO THE DURA

Figure 57. This gross picture represents a multicentric glioblastoma multiforme. A distinct nodule of tumor occupies the left supracallosal gyrus and subcortical white matter. It is separated by the genu of the corpus callosum from another variegated mass of glioblastoma that has become firmly tethered to the orbital dura. Tumor adherent to the dura is very firm and whitish, due to the considerable fibrous connective tissue proliferation secondary to dural invasion.

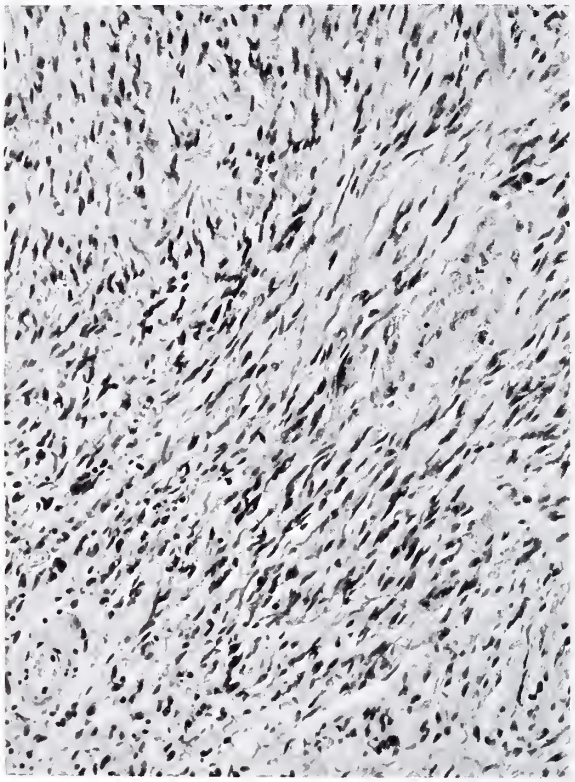

GLIOBLASTOMA INVADING THE DURA

(Figures 58 and 59 from same case)

Figure 58. This is the microscopic picture of glioblastoma invading the inner layer of the dura. As a result there is marked fibrous connective tissue proliferation on the part of the dural fibroblasts, and this extends into the superficial portion of the tumor. Many tumor cells have become elongated or pilocytic. In this field and at this power it is virtually impossible to differentiate the infiltrating tumor cells from fibroblasts. van Gieson. × 130.

GLIOBLASTOMA INVADING THE DURA

(Figures 58 and 59 from same case)

Figure 59. A reticulin stain reveals the marked connective tissue proliferation that is responsible for the elongated shape adopted by the glial cells. With this histologic picture a superficial biopsy from the tumor may invite the erroneous diagnosis of a dural fibrosarcoma. Silver stain for reticulin. × 100.

Another source of diagnostic error may arise when secondary mesenchymal proliferation has occurred as a result of extensive necrosis within a glioblastoma, creating a microscopic picture that is largely dominated by cellular, fibrous, and vascular mesodermal elements. These are the tertiary structures described by Scherer (1938). Degeneration and necrosis in the tumor at first calls forth a large number of microglial cells. Silver impregnations for microglia and frozen preparations for sudanophilic material will often confirm this; thus, in paraffin preparations there is often a high proportion of polygonal cells within the tumor which in fact belong to the macrophage series. As cicatrization takes place in the necrotic areas, pale staining histiocytes and fibroblasts with notched or bilobed nuclei, a pale nucleoplasm, distinct nuclear membranes, and delicate single or multiple nucleoli become the prevalent cell elements (fig. 60). In other areas this process of organization is accompanied by an intense neovascularization, as a result of which thin-walled capillary blood vessels closely cluster together to produce an almost telangiectatic pattern (fig. 61).

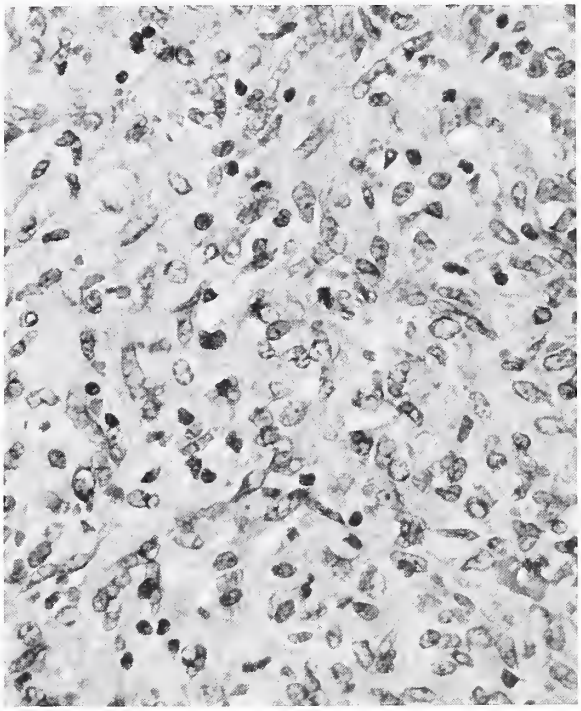

GLIOBLASTOMA MULTIFORME
TERTIARY STRUCTURES

Figure 60. This highly cellular focus is composed of pale staining fibroblasts and histiocytes and darkly staining microglia and lymphocytes in the central area of a glioblastoma. Extensive necrosis and mesenchymal proliferation have taken place in this tumor. × 340.

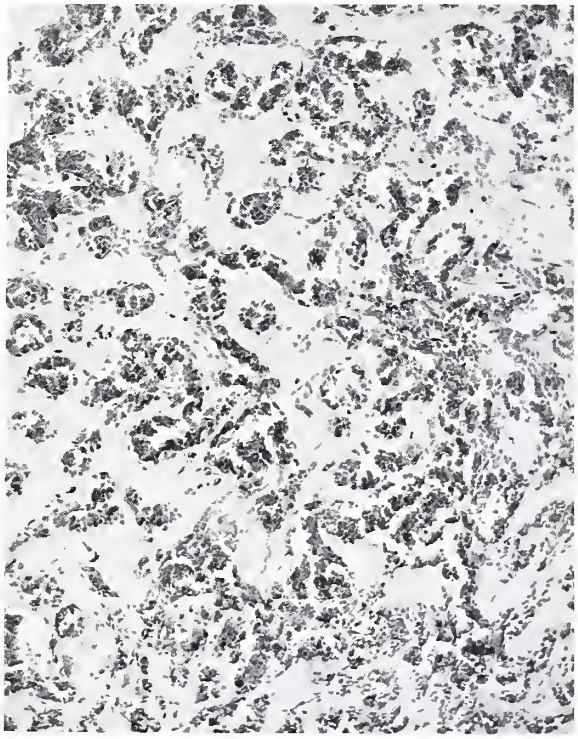

GLIOBLASTOMA MULTIFORME
TERTIARY STRUCTURES

Figure 61. This highly vascularized area is found in the center of a glioblastoma multiforme in which extensive necrosis has taken place. The vessels are thin-walled and closely clustered together, producing a telangiectatic appearance. × 135.

Direct spread beyond the dura seldom takes place in the absence of previous external operative decompression. Occasionally when shunting procedures have relieved obstructive hydrocephalus and therefore allowed further extension of the growth beyond the size that normally results in fatal termination, or when radiation given to the tumor has permitted a longer survival period than usual, **transgression of the dura** may occur. Spontaneous invasion of a major dural sinus (fig. 74) has thus been reported to have paved the way to extraneural metastasis (Rubinstein, 1967). Direct extension to **bone**, especially the tegmental part of the petrous temporal bone, is occasionally found with temporal lobe glioblastomas, and may be secondary to the dural herniation of the cerebral cortex that takes place in the middle fossa as a result of sustained increased intracranial pressure (Sanerkin; Nager).

VARIANTS

Giant Cell Glioblastoma

Giant and multinucleated tumor cells are a frequent microscopic feature in glioblastoma multiforme. In some examples they seem to dominate the histologic picture. In these cases certain gross and microscopic features have led to their recognition as a separate tumor entity by some workers. Because of the unusual abundance of connective tissue that is sometimes present, these tumors have sometimes been regarded as a form of sarcoma, designated as giant cell fibrosarcoma (Kernohan and Uihlein), or "monstrocellular sarcoma" (Zülch). On the other hand the presence of large pyramidal cells with eccentric nuclei and prominent nucleoli has also sometimes invited the interpretation of ganglion cells. However, neither Nissl substance nor neurofibrils can be demonstrated in these neoplasms.

The tumors may occur at any age. Grossly they may be unusually well defined, more so than classical glioblastomas. Cysts of various sizes are frequent. Foci of necrosis may be extensive. The cut surfaces are sometimes more homogeneous and granular than the usual forms of glioblastoma.

MICROSCOPIC. The characteristic feature is the presence of bizarre irregular, frequently multinucleated giant cells with coarse, often blunt or pyramidal processes, and large vesicular nuclei with conspicuous nucleoli. The tumor cells show frequent

phagocytic activity. Mitotic figures are numerous and often atypical. The general architecture is not remarkable, but in places the tumor cells appear closely related to small blood vessels (fig. 62), suggesting perivascular pseudorosettes. The neoplasm is usually remarkably vascular, but the blood vessels are thin-walled and devoid of endothelial proliferation. Neoplastic cells do not line these vascular spaces. The blood vessels are often very closely packed together, and sometimes cuffed with lymphocytes and plasma cells. Reticulin fibers are often abundant and may extend between the smaller tumor cells, but tend to be sparse among the large bizarre giant cells. This connective tissue, to which extraordinary importance is sometimes attached, can almost always be found related to the intense vascularization of the tumor. Moreover, more extensive microscopic examination of these tumors often reveals areas of unequivocal classic glioblastoma or astrocytoma (fig. 63). This has also been the experience of others (Becker et al.). Recent electron microscopic

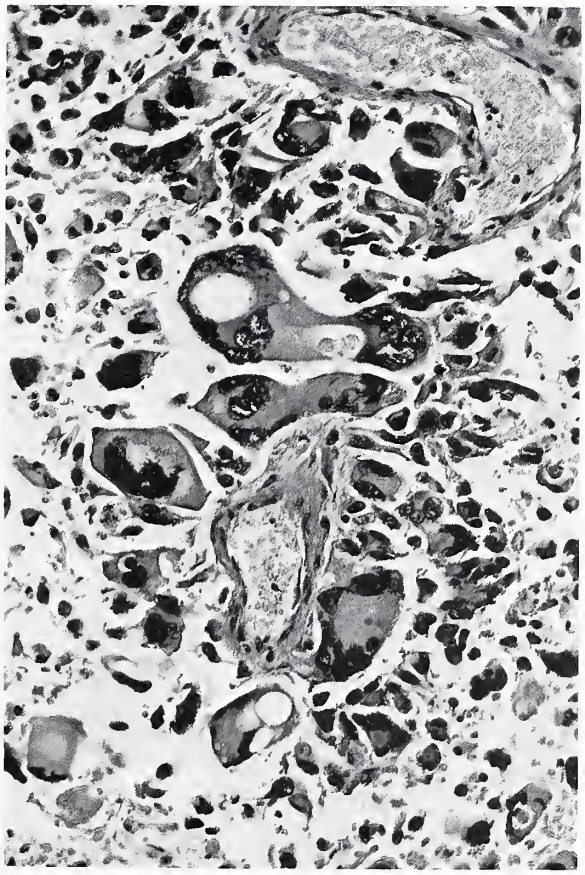

GIANT CELL GLIOBLASTOMA

(Figures 62 and 63 from same case)

Figure 62. Bizarre irregular multinucleated giant cells are in places closely attached to the blood vessel walls. This tumor is occasionally referred to as a "monstrocellular sarcoma." This was a well defined medial frontoparietal, rather granular tumor in a 63-year-old man. ×160.

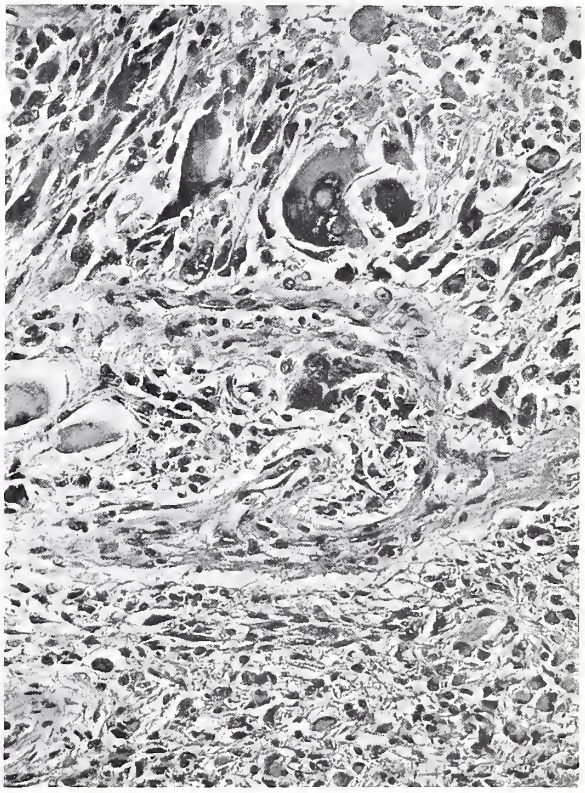

GIANT CELL GLIOBLASTOMA

(Figures 62 and 63 from same case)

Figure 63. This picture taken from another field shows side by side the giant cells on top and the obvious astrocytomatous part of the tumor on the bottom. Transitions are also seen between these two cell types. × 160.

studies of two such tumors and a comparison of their ultrastructural features with those of three fibrosarcomas and five glioblastomas have endorsed their neuroglial origin (Lynn et al.). There is therefore good collective evidence to support the view that this tumor is a variant of glioblastoma.

The prognosis is not necessarily as sinister as the microscopic picture would imply. Because of its unusually good circumscription, total or subtotal excision is occasionally achieved by the amputation of a lobe. In such cases unusually long survivals have been noted. However, there may be recurrence after a number of years. Further spread of these tumors in the cerebrospinal fluid pathways and even extracranially has also been reported (Zülch).

It is my opinion that some of the tumors described by Zülch as "monstrocellular sarcoma" fall within the category of the giant cell glioblastoma and that others belong to the group of mixed glioblastoma and fibrosarcoma.

Mixed Glioblastoma and Fibrosarcoma

As indicated on page 65, the proliferation of vascular endothelium and fibroblasts that is so frequent a feature in glioblastomas may occasionally progress to a florid sarcomatous transformation of these elements with the final picture of a mixed glioblastoma and fibrosarcoma. This development has been described by Feigin and his coworkers, by Rubinstein (1956, 1964), and by others. The full evolution of this process is rare and has been estimated by Feigin to take place in about 2 percent of gliomas.

It seems to occur most frequently in temporal lobe glioblastomas and is almost always associated with the firm secondary attachment of the tumor to the dura. As a result the neoplasm has a lobulated outer surface and can be readily dissected from the surrounding brain, thus grossly resembling a meningioma (fig. 64). The consistency of the tumor is very firm, sometimes woody hard. On section, however, extensive central foci of creamy yellow necrosis are found, while the more peripheral part of the growth is tough, pale gray, and homogeneous. Sometimes the zone of tumor most remote from the dura is more ill-defined

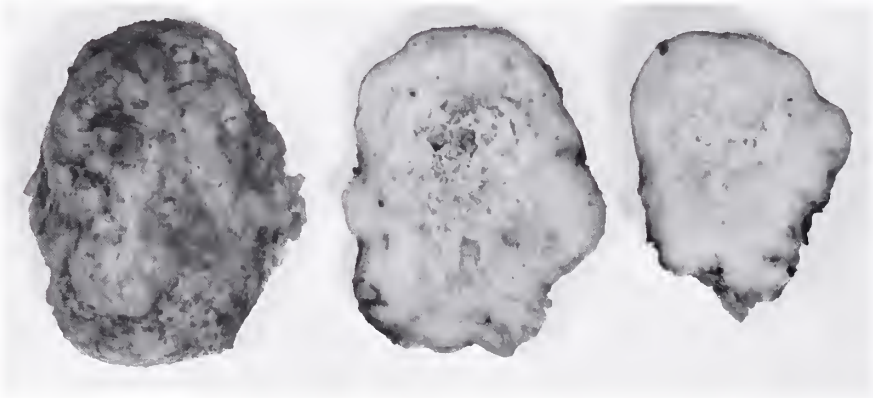

MIXED GLIOBLASTOMA AND FIBROSARCOMA

(Figures 64–67 and Plate III-E from same case)

Figure 64. This well defined temporal lobe tumor in a 48-year-old man was readily dissected from the surrounding white matter and grossly resembles a meningioma. It measured 4x3.3x3 cm. and weighed 29 grams. The external surface is lobulated. The texture of the tumor was very firm. On section (middle and right), however, extensive central foci of yellow necrosis are present; the more peripheral part is firm and homogeneously pale gray.

and obviously invades the surrounding brain in the manner typical of a glioblastoma. Exceptionally a distinct, apparently separate nodule of firm, homogeneous, grayish white sarcoma is disclosed by chance in an otherwise typical glioblastoma (pl. III-D).

Microscopically all transitional stages may be seen from simple hyperplastic vascular endothelial proliferation to obvious malignant change of the endothelial cells or of fibroblasts extending tangentially from the vessel walls (fig. 65). As a result, areas of glioblastoma become intersected by cellular and fibrous sarcomatous tissue, producing a marmoreal pattern which is not easily recognized in hematoxylin and eosin preparations but is clearly evident in stains for the demonstration of connective tissue (figs. 66, 69; pl. III-E). Under high power the contrasting cytologic characteristics of anaplastic glial cells, with their looser texture and their pale staining cell processes, and the more darkly staining and compactly arranged fibroblastic sarcoma cells are easily demonstrated in routine stains (figs. 67, 68). Mitotic figures are found in both cell types.

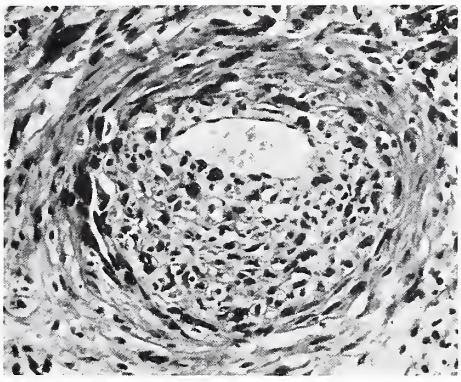

GLIOBLASTOMA AND FIBROSARCOMA

Figure 65. Malignant endothelial proliferation is seen in the blood vessel wall of a glioblastoma multiforme. Fusiform fibroblasts extend tangentially from the vessel wall. van Gieson. × 155. (Fig. 10 from Rubinstein, L. J. Morphological problems of brain tumors with cell population. Acta Neurochir., Supp. X:141–158, 1964).

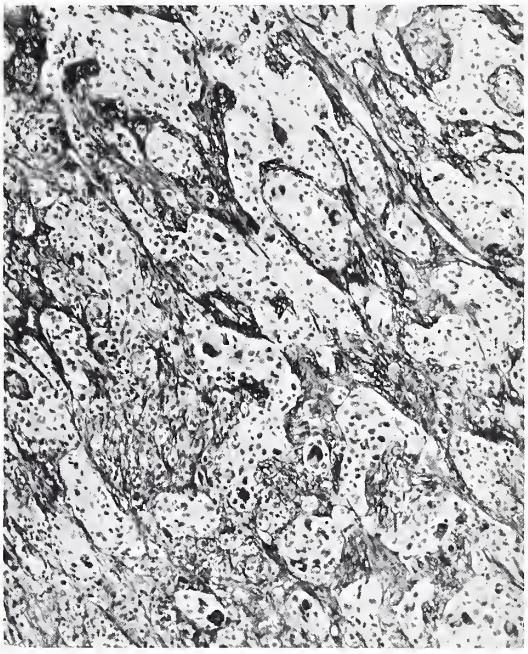

GLIOBLASTOMA AND FIBROSARCOMA

Figure 66. This is the characteristic marmoreal pattern of glioblastoma (clear areas) infiltrated by darkly staining fibroblastic zones. van Gieson. × 69. (Fig. 13 from Rubinstein, L. J. The development of contiguous sarcomatous and gliomatous tissue in intracranial tumours. J. Path. Bact. 71:441–459, 1956).

Other areas (figs. 70, 71) show a perivascular arrangement of fibrosarcomatous cells, often clearly outlined by reticulin stains (fig. 71): unlike the perivascular arrangement of glial cells, the long axis of the tumor cells is tangential or parallel to the blood vessel walls, whereas in gliomas the long axis of glial cells is of course perpendicular.

The tissue culture characteristics of these mixed tumors have been described by Gullotta, and the concept of progressive neoplastic transformation of the vascular endothelium in glioblastomas has received

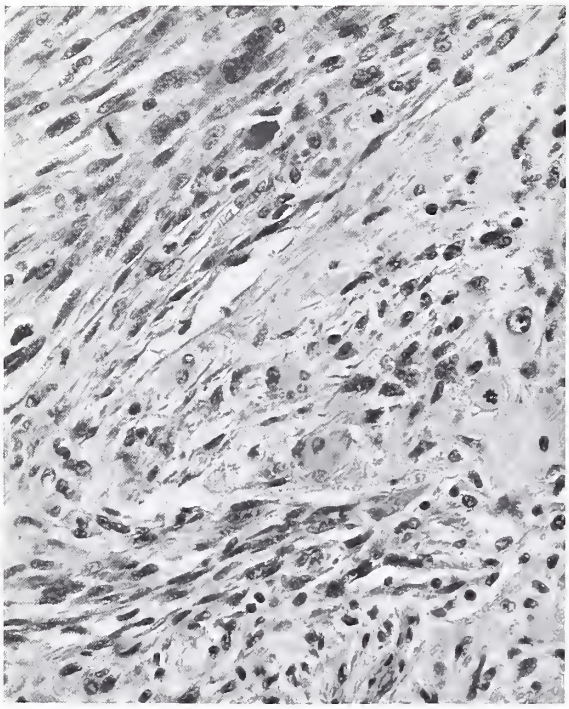

GLIOBLASTOMA AND FIBROSARCOMA

Figure 67. The central zone of glioblastoma is flanked on either side by more compact highly cellular zones of fibrosarcoma. Note mitotic figures. × 230.

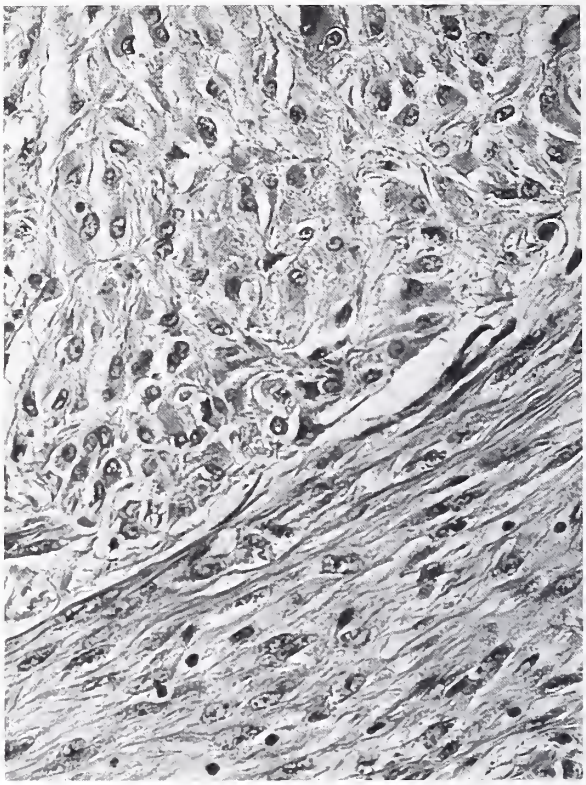

MIXED GLIOBLASTOMA AND FIBROSARCOMA

Figure 68. Another case of mixed glioblastoma and fibrosarcoma reveals the contrasting cytology of astrocytic glioma (upper) and fibrocytic sarcoma cells (lower). × 260. (Fig. 24 from Rubinstein, L. J. Sarcomas of the Nervous System. In: Pathology of the Nervous System, Vol. 2. (Ed.) Minckler, J. New York: McGraw-Hill Book Company, 1971).

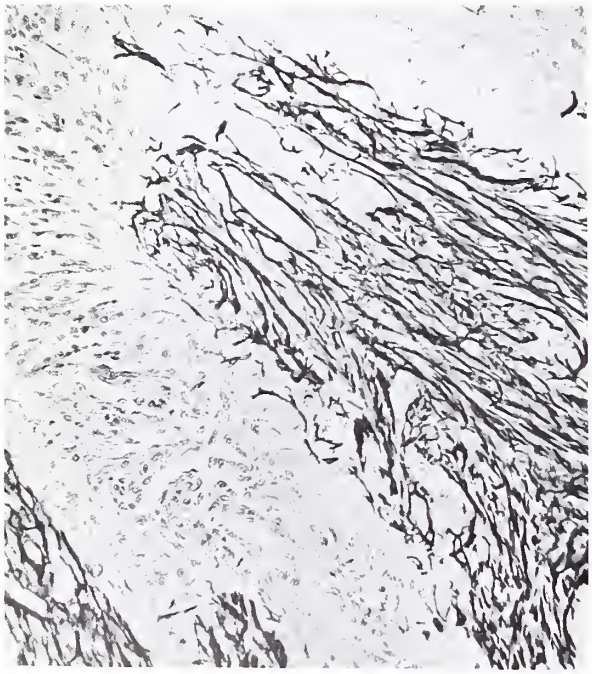

Fig. 69

GLIOBLASTOMA AND FIBROSARCOMA

Figure 69. Reticulin-free zones of glioma cells are intersected by sheets of fibrosarcoma cells separated by abundant reticulin fibers. Silver stain for reticulin. × 135.

support from experimental work by Greene and Harvey. These workers have described the independent development of sarcomas in the subcutaneous tissues of hamsters and mice from human glioblastoma-derived guinea pig brain tumors and their adjacent hyperplastic vascular stroma.

Although the sarcomatous change is regarded as a secondary phenomenon, the impression is often gained that it occurs *pari passu* with the growth and spread of the glioma. This sarcomatous picture must be clearly distinguished from the more frequent instances in which an extensively necrotic glioblastoma shows a nonneoplastic proliferation of mesenchymal elements: this may consist of large numbers of microglial cells (fig. 60) and of richly vascular granulation tissue (fig. 61). Occasionally it happens that the sarcoma reaches such

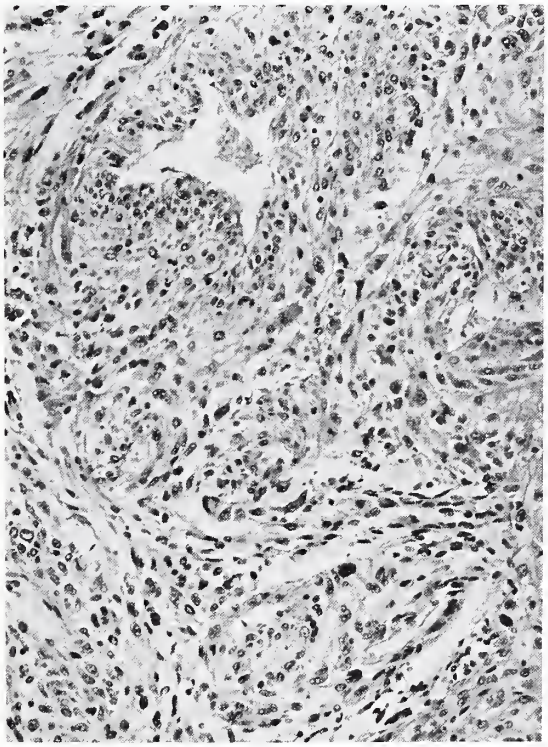

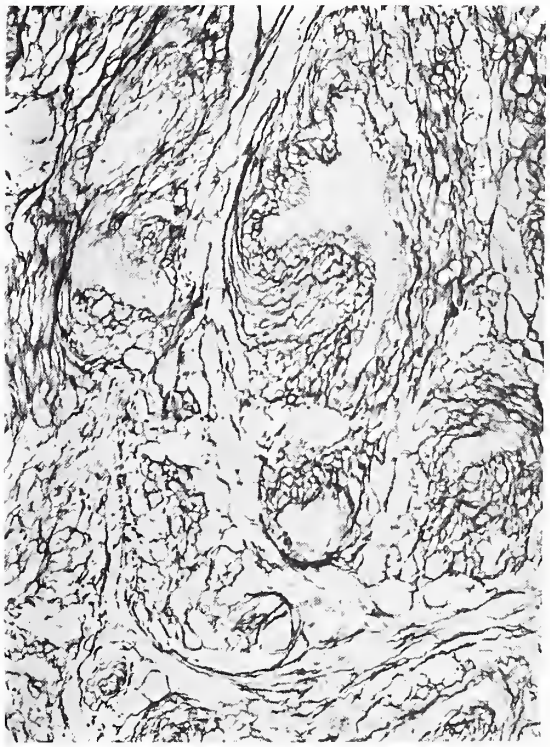

MIXED GLIOBLASTOMA AND FIBROSARCOMA

(Figures 36, 43, 70, and 71 from same case)

Figure 70. This illustrates a perivascular proliferation of fibrosarcomatous cells in a mixed glioblastoma and fibrosarcoma. van Gieson. × 120. (Fig. 139 from Russell, D. S., and Rubinstein, L. J. Pathology of Tumours of the Nervous System, 3d ed. London: Edward Arnold, 1971; also fig. 17 from Rubinstein, L. J. Morphological problems of brain tumors with cell population. Acta Neurochir., Supp. X:141–158, 1964).

Figure 71. A reticulin stain of the same field reveals a conspicuous pattern of reticulin fibers in the areas surrounding the blood vessel spaces, corresponding to the foci of perivascular fibrosarcoma. Silver stain for reticulin. × 110. (Fig. 140 from Russell, D. S., and Rubinstein, L. J. Pathology of Tumours of the Nervous System, 3d ed. London: Edward Arnold, 1971; also fig. 18 from Rubinstein, L. J. Morphological problems of brain tumors with cell population. Acta Neurochir., Supp. X:141–158, 1964).

massive proportions that the glioma is almost entirely overshadowed. A biopsy from a left posterior temporal tumor removed six months before death demonstrated a mixture of sarcoma and glioma that could easily be distinguished (figs. 70, 71). In the fatal recurrence six months later the appearances were largely those of perivascular fibrosarcoma, and only one small portion was found to disclose its essentially gliomatous origin. In two cases in my experience metaplasia had also taken place in the sarcomatous areas, with the production of cartilage. Goldman has recently reported an exceptional example in which the sarcomatous element showed rhabdomyoblastic metaplasia.

Although most cases of mixed glioma and fibrosarcoma of this type are associated with glioblastoma, occasionally this development is witnessed in other forms of glioma. I have examined one example of oligodendroglioma (figs. 100, 101) in which a similar malignant evolution of the proliferating vascular elements had taken place.

METASTATIC SPREAD. Spread from a glioblastoma through the **cerebrospinal fluid pathways** is not uncommon, and usually follows invasion of, and rupture into, the ventricular cavity. As a result diffuse dissemination may occur throughout the ventricular system and the cerebrospinal leptomeninges. The brain may then be covered by a gelatinous neoplastic exudate which obscures the ventral surface of the brainstem and the cranial nerves (pl. III-C). The spinal cord may either be extensively covered by an opaque grayish white exudate, which is characteristically thicker on its dorsal aspect (fig. 72), or show numerous discrete nodules of subarachnoid growth. These are again more prominent on the dorsal aspect, may infiltrate the spinal nerve roots, including those of the cauda equina,

GLIOBLASTOMA MULTIFORME SPREAD THROUGH CEREBROSPINAL FLUID PATHWAYS

(Figure 72 and Plate III-C from same case)

Figure 72. The posterior surface of the spinal cord is completely covered by a thick confluent, grayish white neoplastic exudate. Transverse section demonstrates the collar of tumor, which is thicker on the posterior aspect of the cord (arrow).

and form a single mass that occupies the fundus of the thecal sac. In the ventricles, metastatic spread may either consist in discrete nodules of growth or present as a widespread layer of neoplastic tissue that lines the ventricular ependyma throughout (fig. 73); the resulting appearance is sometimes referred to as "ependymitis blastomatosa."

Reinvasion of the substance of the brain and spinal cord from metastatic deposits in the subarachnoid space or the ventricles is frequent. The appearances may then be difficult to distinguish microscopically from a primary origin, since the reinvading tumor cells blend imperceptibly with the host tissues. Invasion of the spinal nerve roots, including the cauda equina, may also occur; occasionally this provides a pathway by which the tumor cells, by permeating the nerve roots along their dural sleeves, may spread beyond them outside the central nervous system.

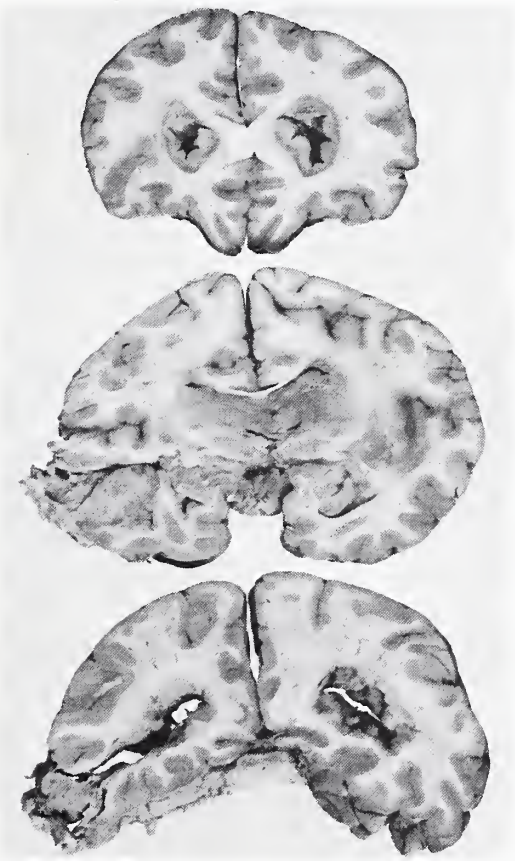

GLIOBLASTOMA MULTIFORME SPREAD THROUGH CEREBROSPINAL FLUID PATHWAYS

Figure 73. Widespread metastatic spread of tumor lines the ventricles, from a massive recurrent left temporal glioblastoma multiforme in a 21-year-old woman. This is the gross picture of "ependymitis blastomatosa."

As mentioned in the Introduction on page 13, acceptable examples of remote **extracranial** metastasis have been described in increasing numbers in recent years. Glioblastomas now form the majority of gliomas with this unusual complication (Smith et al., 1969a). Aside from a rare case in which distant dissemination was apparently the result of the spontaneous transgression of the dura by tumor and its subsequent permeation of the adjacent superior sagittal sinus (Rubinstein, 1967), in most other reported instances there had been one or more previous operations. This suggests that remote metastasis is a surgical hazard mediated by radical operative treatment and that repeated craniotomy for recurrence of the growth may be the enhancing factor.

Venous permeation either of the dural veins or sinuses (fig. 74) or at the site of remote metastasis (fig. 75) is often demonstrated. Microscopically the metastatic tumor cells usually retain the same morphologic features as in the brain (fig. 76). The most frequent sites of metastases according to Smith and associates (1969a) are the lungs and cervical lymph nodes (fig. 79). Metastasis in the bone marrow may also occur (figs. 77, 78) and marrow replacement by tumor cells is sometimes accompanied by myelosclerosis and extramedullary hematopoiesis.

GLIOBLASTOMA MULTIFORME. EXTRANEURAL METASTASES

(Figures 6, 29, 74–78, and Plate XIII-D from same case)

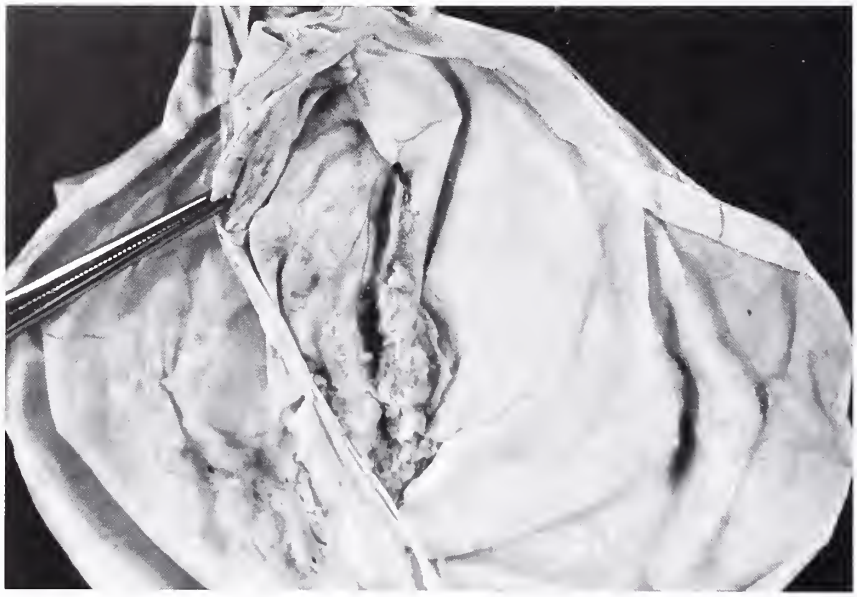

Figure 74. Gross invasion of the superior longitudinal sinus by a tumor arising in the medial frontoparietal region is illustrated. (Fig. 2 from Rubinstein, L. J. Development of extracranial metastases from a malignant astrocytoma in the absence of previous craniotomy. J. Neurosurg. 26:542–547, 1967).

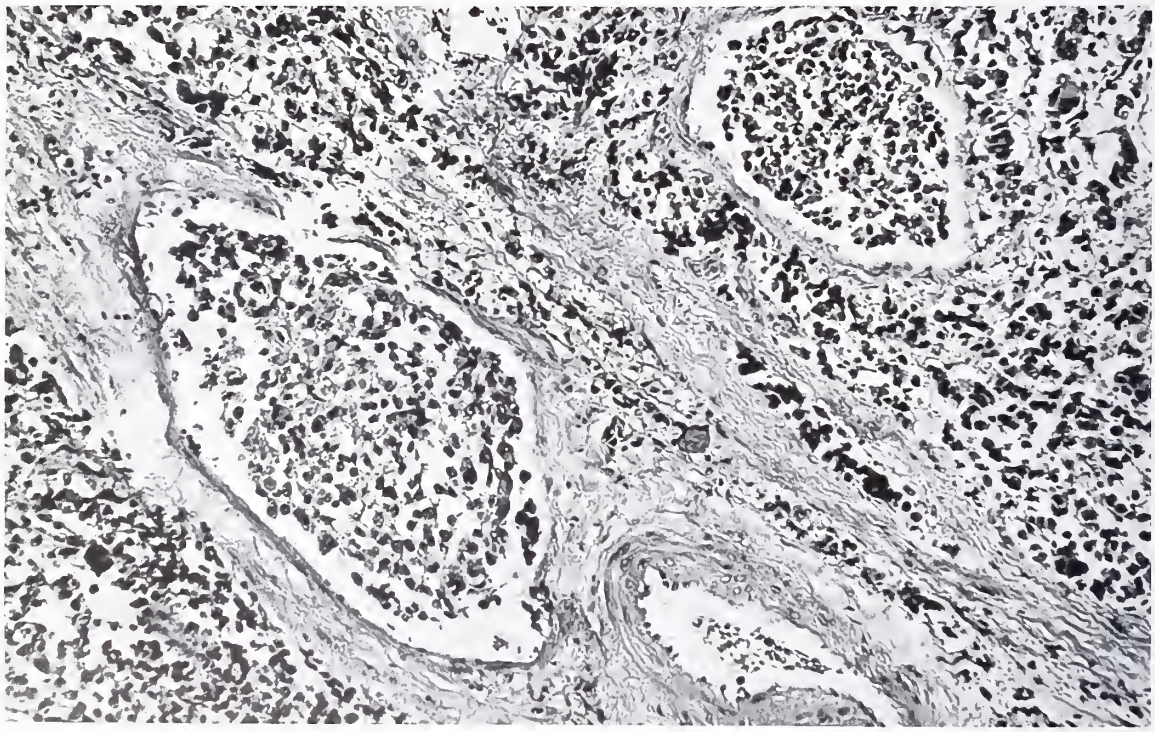

Figure 75. Venous permeation by anaplastic glioma cells is shown in a retroperitoneal mass from a metastasis of glioblastoma. × 150. (Fig. 8 from Rubinstein, L. J. Development of extracranial metastases from a malignant astrocytoma in the absence of previous craniotomy. J. Neurosurg. 26:542–547, 1967).

GLIOBLASTOMA MULTIFORME. EXTRANEURAL METASTASES

(Figures 6, 29, 74–78, and Plate XIII-D from same case)

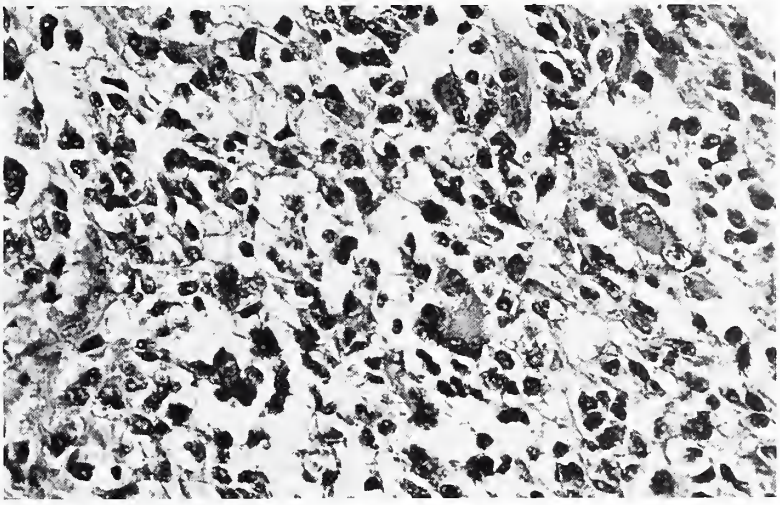

Figure 76. Anaplastic astrocytomatous cells are shown in a retroperitoneal lymph node from a metastasizing glioblastoma. The cytologic features are identical with those of a malignant intracranial astrocytoma. × 300.

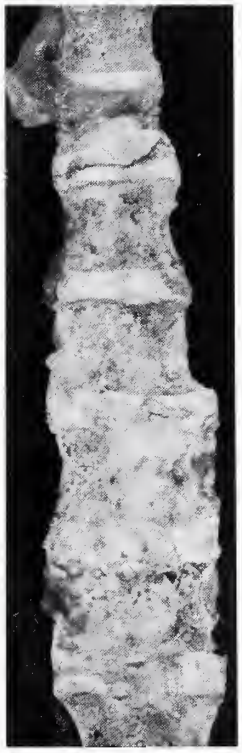

Figure 77. There is extensive replacement of the thoracic and lumbar vertebral marrow by yellowish gray tumor. (Fig. 3 from Rubinstein, L. J. Development of extracranial metastases from a malignant astrocytoma in the absence of previous craniotomy. J. Neurosurg. 26:542–547, 1967).

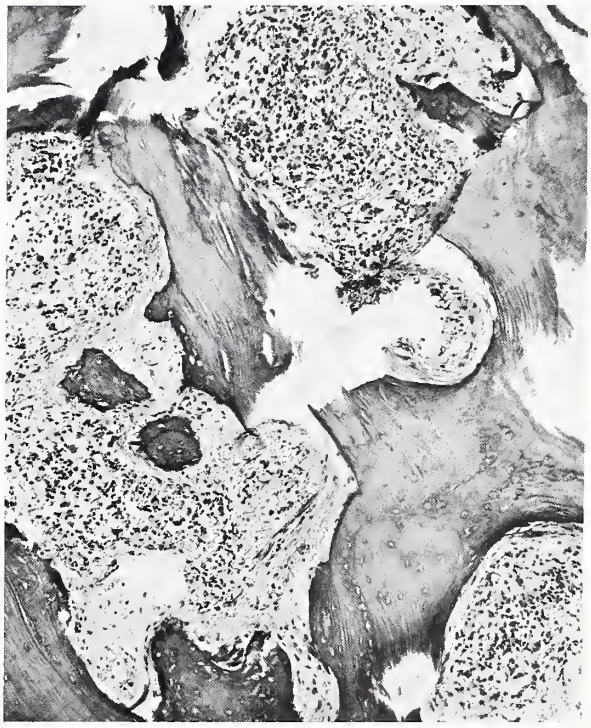

Figure 78. This low power microscopic picture of the vertebral bone marrow shows extensive replacement by small darkly staining glial cells. × 63. (Fig. 6 from Rubinstein, L. J. Development of extracranial metastases from a malignant astrocytoma in the absence of previous craniotomy. J. Neurosurg. 26:542–547, 1967).

EXTRACRANIAL METASTASIS OF A GLIOBLASTOMA IN A LYMPH NODE

(Figures 54 and 79 from same case)

Figure 79. Clusters of gemistocytic astrocytes are seen in the sinusoids of a cervical lymph node in a case of metastasizing glioblastoma. × 145.

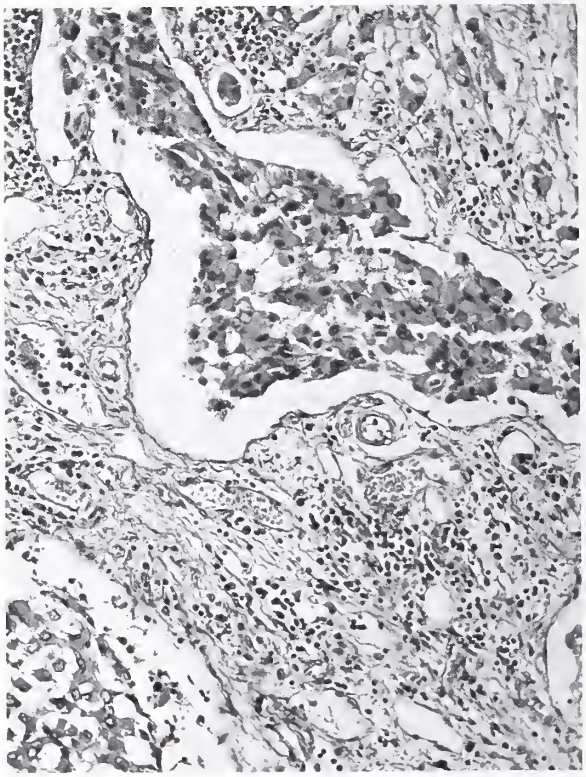

Fig. 79

Interestingly, when extraneural metastases develop in a mixed glioblastoma and fibrosarcoma both tissue elements are usually, although not invariably, found in the distant deposits (Smith et al., 1969b).

TREATMENT. Despite the sinister prognosis of glioblastomas, the generally accepted mode of treatment is to perform as radical surgical removal as possible, with the hope of providing the patient with at least a few months of comfort. A pessimistic outlook on this tumor has often led surgeons in the past to adopt a conservative attitude and to limit themselves to an exploratory needle biopsy for histologic confirmation without further treatment. Pool and Kamrin advise against this approach because of the difficulty in localizing the lesion, the chances of erroneous diagnosis, and the fact that needle biopsy alone may triple the mortality for glioblastoma as compared to the results of decompressive craniotomy. For these reasons, they feel that open craniotomy is the safest and most reliable method of verifying the tumor, followed by as extensive a removal as feasible. With modern diagnostic and anesthetic procedures, subtotal excision of a glioblastoma now has a 20 percent immediate postoperative mortality. Although it is not a radiosensitive tumor, there is increasing agreement that the quality of survival of those treated justifies the procedure even though the length of survival may not be greater for patients given postoperative radiation compared to the results of surgery alone (Schulz et al.). Careful clinical analyses by Jelsma and Bucy (1967, 1969) suggest that patients who had extensive tumor resection followed by postoperative radiation represent the optimal results obtainable at this time. Both the length of postoperative survival and the quality of the survival were much better following extensive resection than following partial resection or biopsy.

Attempted treatment of glioblastomas with the arterial infusions of antimetabolites such as vincristine has been disappointing so far (Owens). These tumors have also been treated with radioisotopes, but the survival times obtained with extensive surgical

treatment followed by radioisotope treatment do not appear to differ from those resulting from conventional radiation after surgical removal (Mundinger). Attempts are now being made to treat glioblastomas by internal carotid infusion with bromouridine (BUdR) combined with methotrexate and followed by radiation, with apparently promising results (Wilson and Hoshino). Similarly, the evaluation of BCNU, a nitrosourea compound, as a neuro-oncolytic agent (Wilson et al.) is in the experimental stages.

Radiation of glioblastomas under whole body hypothermia has also been attempted (Bloch et al.) in the hope of benefiting from an apparent increase in radiosensitivity of these tumors. The overall results have been disappointing.

PROGNOSIS. The prognosis of these tumors is almost invariably fatal. In the series of Jelsma and Bucy (1967) 75 percent of the patients treated with surgery alone and 40 percent of those treated with surgery followed by radiation died within nine months. The mortality after two years is almost 90 percent.

Survival has extended more than two years for a few cases. Jelsma and Bucy list 10 such patients all of whom were between the ages of 30 and 50; the tumors were essentially astrocytomas with glioblastomatous change rather than primary glioblastomas, and all patients had as complete a resection as possible. Exceptional examples of longer survival, up to 17 and 23 years after radical removal of a glioblastoma, have also been reported (Elvidge and Barone).

DIFFERENTIAL DIAGNOSIS. Diagnostic difficulties may arise in biopsies obtained from the superficial part of a glioblastoma when it infiltrates the leptomeninges and dura (p. 68). The presence of an abundant network of reticulin fibers may invite the diagnostic error of sarcoma. More extensive microscopic examination of the deeper part of the tumor usually provides the correct diagnosis. A fusiform glioblastoma may superficially resemble a spindle cell sarcoma; the presence of PTAH positive fibers and the absence of reticulin fibers will establish the diagnosis of glioma. In a small biopsy the highly anaplastic forms of glioblastoma may be difficult to distinguish from poorly differentiated metastatic carcinoma or from an amelanotic melanoma. The latter may be especially difficult to exclude in view of its tendency to spread diffusely into the brain, thus mimicking a malignant glioma. Some glioblastomas with large vesicular nuclei and prominent nucleoli may also mimic metastatic carcinoma and sometimes adopt in places an epithelial-like architecture; in this manner too they may resemble metastatic melanoma. Conversely the presence of discrete foci of intensely cellular anaplasia in the almost normal surrounding brain may simulate deposits from an oat cell carcinoma of the lung. The giant cell glioblastoma is sometimes interpreted on the basis of its abundant connective tissue as a giant cell fibrosarcoma or as a sarcoma arising from the blood vessels (p. 72). The absence of malignant cells immediately lining the vessel walls speaks against a vascular origin, especially since perivascular spread of glioma cells in the Virchow-Robin spaces is a frequent phenomenon. Fibrosarcomas of the dura may occasionally contain highly bizarre giant cells, but the presence of unequivocal fibrosarcomatous areas in adjacent fields will establish the correct diagnosis. Some of Zülch's monstrocellular sarcomas appear from the illustrations to be mixed fibrosarcomas and glioblastomas. These tumors frequently contain bizarre giant multinucleated cells. The diagnosis of

mixed glioblastoma and fibrosarcoma rests on the finding of unequivocal areas of fibrosarcoma juxtaposed to fields of glioblastoma, and should not include those tumors in which a vigorous but nonneoplastic desmoplastic reaction has taken place in a glioblastoma following central necrosis or infiltration of the dura.

References

Alexander, W. S. Multiple primary intracranial tumours. Meningioma associated with glioma; report of a case. J. Neuropath. Exp. Neurol. 7:81–88, 1948.

Becker, D. P., Benyo, R., and Roessmann, U. Glial origin of monstrocellular tumor. Case report of prolonged survival. J. Neurosurg. 26:72–77, 1967.

Bloch, M., Bloom, H. J. G., Penman, J., and Walsh, L. Observations on patients with cerebral astrocytoma (glioblastoma multiforme) treated by irradiation under whole-body hypothermia. Brit. J. Cancer 20:722–728, 1966.

Elvidge, A. R., and Barone, B. M. Long-term postoperative survival in two cases of glioblastoma multiforme. J. Neurosurg. 22:382–386, 1965.

Feigin, I. H., and Gross, S. W. Sarcoma arising in glioblastoma of the brain. Amer. J. Path. 31:633–653, 1955.

_____, Allen, L. B., Lipkin, L., and Gross, S. W. The endothelial hyperplasia of the cerebral blood vessels with brain tumors, and its sarcomatous transformation. Cancer 11:264–277, 1958.

Goldman, R. L. Gliomyosarcoma of the cerebrum. Report of a unique case. Amer. J. Clin. Path. 52:741–744, 1969.

Greene, H. S. N., and Harvey, E. K. The development of sarcomas from transplants of the hyperplastic stromal endothelium of glioblastoma multiforme. Amer. J. Path. 53:483–499, 1968.

Gullotta, F. Zur in vitro-Diagnostik gliös-mesenchymaler Mischgeschwülste. Deutsch. Z. Nervenheilk. 186:323–335, 1964.

Jelsma, R., and Bucy, P. C. The treatment of glioblastoma multiforme of the brain. J. Neurosurg. 27:388–400, 1967.

_____, and Bucy, P. C. Glioblastoma multiforme. Its treatment and some factors effecting survival. Arch. Neurol. 20:161–171, 1969.

Kernohan, J. W., and Sayre, G. P. Tumors of the Central Nervous System. Fascicle 35, Atlas of Tumor Pathology. Washington: Armed Forces Institute of Pathology, 1952.

_____, and Uihlein, A. Sarcomas of the Brain. Springfield, Ill.: Charles C Thomas, 1962.

Luse, S. A. Electron microscopic studies of brain tumors. Neurology 10:881–905, 1960.

Lynn, J. A., Panopio, I. T., Martin, J. H., Shaw, M. L., and Race, G. J. Ultrastructural evidence for astroglial histogenesis of the monstrocellular astrocytoma (so-called monstrocellular sarcoma of brain). Cancer 22:356–366, 1968.

Mundinger, F. The Treatment of Brain Tumors with Radioisotopes, pp. 202-257. In: Progress in Neurological Surgery, Vol. 1. (Eds.) Krayenbühl, H., Maspes, P. E., and Sweet, W. H. Chicago: Year Book Medical Publishers, Inc., 1966.

Nager, G. T. Gliomas involving the temporal bone. Clinical and pathological aspects. Laryngoscope 77:454–488, 1967.

Owens, G. Chemotherapy of Brain Tumors, pp. 190–201. In: Progress in Neurological Surgery, Vol. 1. (Eds.) Krayenbühl, H., Maspes, P. E., and Sweet, W. H. Chicago: Year Book Medical Publishers, Inc., 1966.

Pool, J. L., and Kamrin, R. P. The Treatment of Intracranial Gliomas by Surgery and Radiation, pp. 258–299. In: Progress in Neurological Surgery, Vol. 1. (Eds.) Krayenbühl, H., Maspes, P. E., and Sweet, W. H. Chicago: Year Book Medical Publishers, Inc., 1966.

Raimondi, A. J. Ultrastructure and the Biology of Human Brain Tumors, pp. 1–36. In: Progress in Neurological Surgery, Vol. 1. (Eds.) Krayenbühl, H., Maspes, P. E., and Sweet, W. H. Chicago: Year Book Medical Publishers, Inc., 1966.

Robertson, D. M., and MacLean, J. D. Nuclear inclusions in malignant gliomas. Arch. Neurol. 13:287–296, 1965.

Rubinstein, L. J. The development of contiguous sarcomatous and gliomatous tissue in intracranial tumours. J. Path. Bact. 71:441–459, 1956.

_____. Morphological problems of brain tumors with mixed cell population. Acta Neurochir., Supp. X: 141–158, 1964.

_____. Development of extracranial metastases from a malignant astrocytoma in the absence of previous craniotomy. J. Neurosurg. 26:542–547, 1967.

Russell, D. S., and Rubinstein, L. J. Pathology of Tumours of the Nervous System, 3d ed., pp. 168–170. London: Edward Arnold, 1971.

Sanerkin, N. G. Transdural spread of glioblastoma multiforme. J. Path. Bact. 84:228–233, 1962.

Scherer, H. J. Structural development in gliomas. Amer. J. Cancer 34:333–351, 1938.

———. Cerebral astrocytomas and their derivatives. Amer. J. Cancer 40:159–198, 1940.

Schulz, M. D., Wang, C-C., Zinninger, G. F., and Tefft, M. Radiotherapy of Intracranial Neoplasms, pp. 318–370. In: Progress in Neurological Surgery, Vol. 2. (Eds.) Krayenbühl, H., Maspes, P. E., and Sweet, W. H. Chicago: Year Book Medical Publishers, Inc., 1968.

Slooff, J. L., Kernohan, J. W., and MacCarty, C. S. Primary Intramedullary Tumors of the Spinal Cord and Filum Terminale, pp. 43–61. Philadelphia: W. B. Saunders Company, 1964.

Smith, D. R., Hardman, J. M., and Earle, K. M. Metastasizing neuroectodermal tumors of the central nervous system. J. Neurosurg. 31:50–58, 1969a.

———, Hardman, J. M., and Earle, K. M. Contiguous glioblastoma multiforme and fibrosarcoma with extracranial metastasis. Cancer 24:270–276, 1969b.

Wilson, C. B., and Hoshino, T. Current trends in the chemotherapy of brain tumors with special reference to glioblastomas. J. Neurosurg. 36:589–603, 1969.

———, Boldrey, E. B., and Enot, K. J. 1,3-bis (2-chloroethyl)-1-nitrosourea (NSC–409962) in the treatment of brain tumors. Cancer Chemother. Rep. Pt. 1, 54:273–281, 1970.

Zülch, K. J. Brain Tumors. Their Biology and Pathology, 2d American ed., pp. 221–224. New York: Springer Publishing Co., 1965.

OLIGODENDROGLIOMAS

SYNONYMS AND RELATED TERMS: Oligodendrocytoma; oligodendroblastoma.

DEFINITION AND CYTOGENESIS. This tumor, originally described by Bailey and Bucy, is derived from and composed of oligodendrocytes in various stages of differentiation. From the histologic point of view the tumor is frequently not a pure one, but the mixture of cell population is often not evident in ordinary paraffin preparations, and may be appreciated only with special staining or metallic impregnation technics. Nevertheless, in most cases the oligodendroglioma presents a cytologic picture that is characteristic enough to permit immediate recognition. Variations in tissue pattern and cell forms occur, however, and will be described in some detail. As a clinicopathologic entity, the oligodendroglioma is difficult to define since it displays considerable variation in its natural history, and its biologic behavior cannot be predicted. Attempts to correlate the latter with histologic features have been unrewarding.

INCIDENCE. Oligodendrogliomas constitute approximately 5 to 7 percent of all primary intracranial gliomas in man. They are the most frequent gliomas in dogs, and account for 48 percent of the primary neuroectodermal neoplasms collected in various animal species by Lüginbühl.

In man, the sexes are about equally affected. The tumor occurs at any age, but is most often identified in adults, usually in the fourth and fifth decades.

CLINICAL DATA AND NATURAL HISTORY. Many oligodendrogliomas grow slowly and produce long-standing focal symptoms only, such as Jacksonian or temporal lobe epilepsy. Some present with a clinical history going back for 5 to 15 years. I have seen two cases in which the tumor, by its localization, was referable to a history going back for 27 and 28 years respectively. One example reported by Freeman and Feigin had a clinical evolution of 35 years. By contrast many examples present with a few months history of space-occupying lesion of increasing size, similar to a glioblastoma. Some patients give a long history of focal symptoms with a more recent acceleration in the clinical picture.

Small silent or clinically arrested examples are occasionally found at postmortem examination.

SITES. Most oligodendrogliomas arise in the cerebral hemispheres, most often in the frontal lobe. Some present as intraventricular tumors. A few originate in the cerebellum or in the spinal cord.

GROSS. The tumor usually presents as a well defined, circumscribed, globular mass occupying the white matter and adjacent cortex, and it is often cystic (pl. IV-A). The cysts may be small or extensive. The texture of the tumor is usually soft and in places may be gelatinous due to mucinous degeneration. Foci of calcification are often present both in the center of the tumor and more frequently along its periphery and in the adjacent brain. They may be sufficiently extensive to be detected radiologically (fig. 80). Foci of hemorrhage are frequent. They are usually small, but occasionally massive hemorrhage may take place: gross bleeding in a glial tumor sufficiently severe to produce the clinical picture of a stroke is very unusual, but when it occurs it is most likely in an oligodendroglioma.

MICROSCOPIC. In the typical case the microscopic appearance is so characteristic as to be immediately recognizable. The most obvious feature under low power is the monotony of the microscopic fields, which are occupied by highly cellular and usually fairly compact collections of uniform cells with regular spheroidal central nuclei and clear cytoplasm (fig. 81). The uniform and highly cellular character of the tumor is well demonstrated in brain smears obtained at the time of surgery (pl. IV-C). In sections the higher power confirms the regular cytologic features of the tumor cells, which are arranged in uniform sheets intersected by a regular delicate vascular stroma, and emphasizes the round, darkly

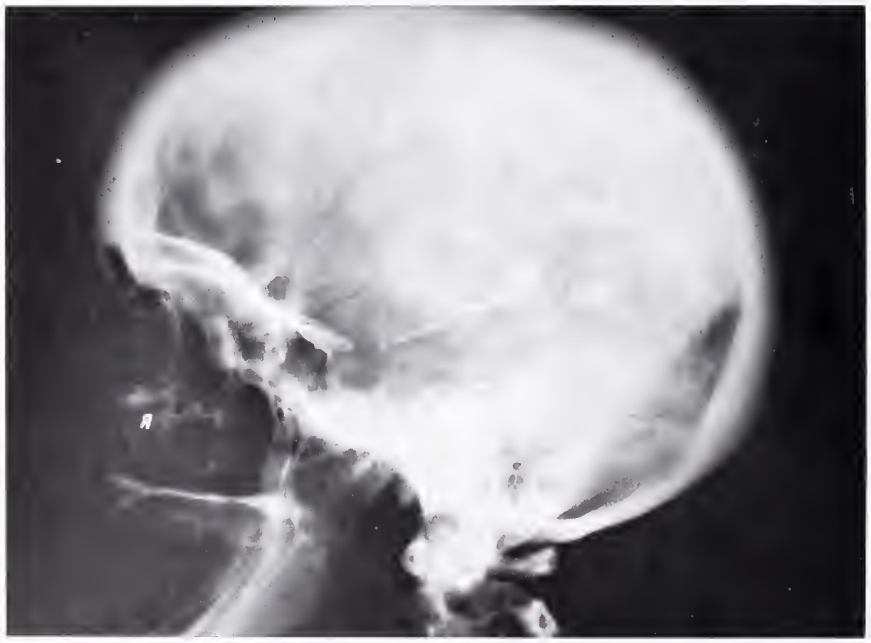

OLIGODENDROGLIOMA. CALCIFICATIONS

Figure 80. Extensive calcifications are demonstrated radiologically in an oligodendroglioma. (Courtesy of Dr. L. M. Zatz, Stanford, Calif.).

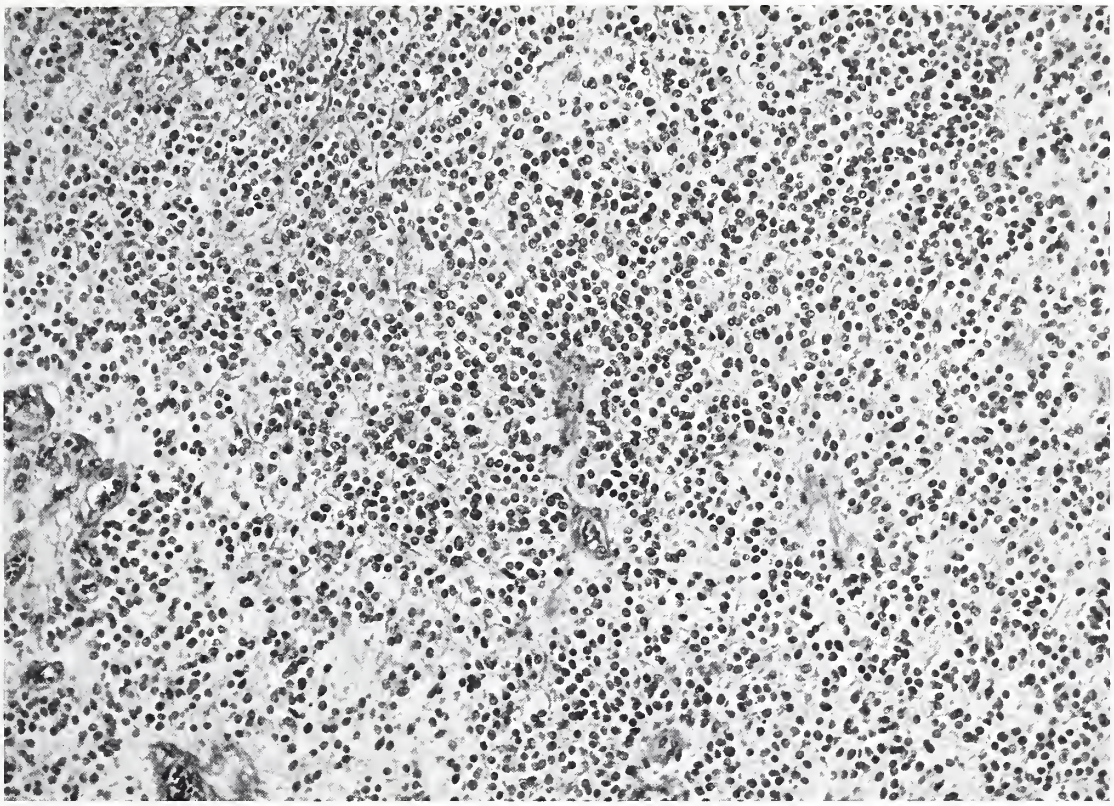

OLIGODENDROGLIOMA

(Figures 81–83 and Plate IV-A from same case)

Figure 81. This shows the general architectural and cytologic appearance of oligodendroglioma. PTAH. × 175.

staining nuclei and the clear, perinuclear halos (fig. 82). These halos are also found in nonneoplastic oligodendrocytes, where they are the result of "acute swelling" in postmortem material. They are usually regarded as artifacts due either to autolysis or the fixation procedure. They are usually not seen on frozen sections.

With special stains no neuroglial fibers are seen, but phosphotungstic acid hematoxylin emphasizes the clear, perinuclear halos by accentuating the delicate cytoplasmic membrane of the oligodendrocytes (fig. 82). In places, the tumor cells are no longer round, but may be elongated with fusiform nuclei. This arrangement is sometimes seen when the tumor infiltrates a major nerve fiber tract. While the cells could be misinterpreted as fusiform astroglia, neuroglial fibers cannot be demonstrated in these areas (fig. 83). Frequently tumor oligodendrocytes form regularly arranged clusters intersected by rather more prominent strands of vascular connective tissue (figs. 84, 99).

In addition to the pale perinuclear halos, the cytoplasm of the tumor cells occasionally contains faintly basophilic material that may stain for mucin. As shown in figure 85 and plate IV-B, some of the large clear cells may be intensely positive with periodic acid Schiff procedure. This is due to so-called mucinous degeneration. This well known change also occurs in normal oligodendrocytes, which thereby convert into so-called "mucocytes."

OLIGODENDROGLIOMA

(Figures 81–83 and Plate IV-A from same case)

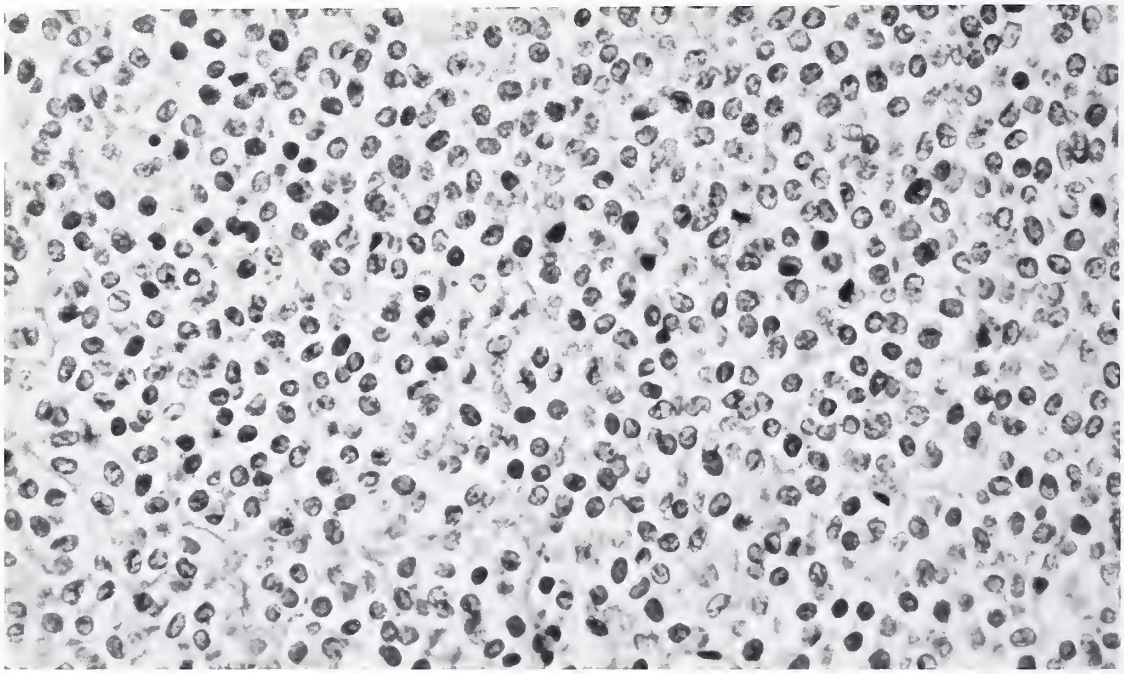

Figure 82. This classic microscopic picture of oligodendroglioma shows a regular cytology, spheroidal nuclei, clear perinuclear cytoplasmic halos, and delicate cytoplasmic membranes. Note the absence of neuroglial fibers. PTAH. × 480. (Fig. 18 from Rubinstein, L. J. Seminario de Neuropatologia, Mérida, Yucatán, Bol. Asoc. Mex. Patol., A. C. 7:13–59, 1969).

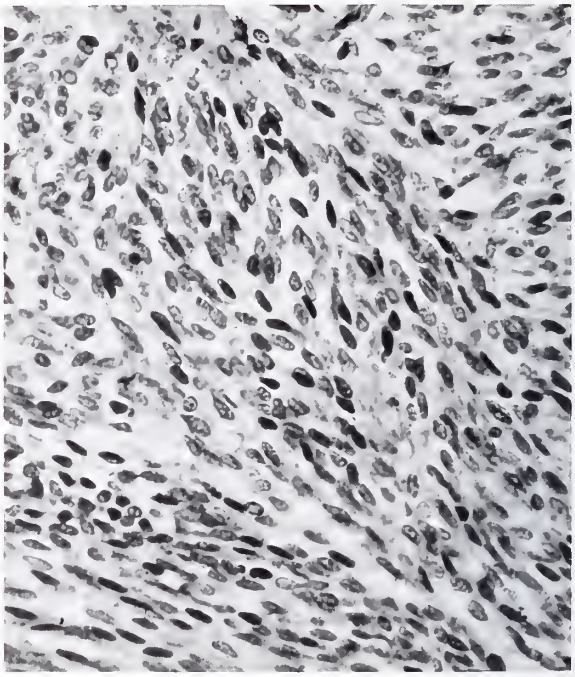

Figure 83. This adjacent area of oligodendroglioma illustrates spindle-shaped tumor cells and fusiform nuclei. Neuroglial fibers are not present. PTAH. × 340.

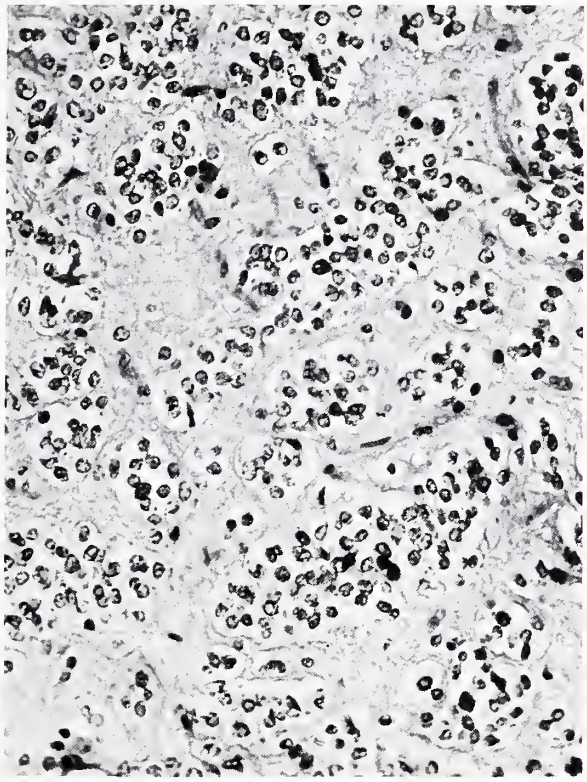

OLIGODENDROGLIOMA

(Figures 84 and 89 from same case)

Figure 84. Clusters of oligodendroglial cells with perinuclear halos are intersected by thin strands of delicate vascular connective tissue stroma. × 265.

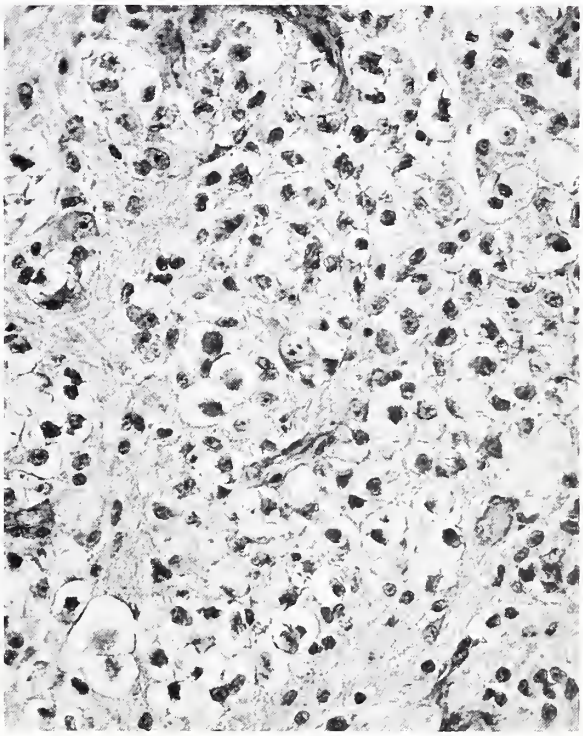

OLIGODENDROGLIOMA WITH MUCINOUS CHANGE

(Figures 85, 98, 100, 101, and Plate IV-B from same case)

Figure 85. Clusters of pale oligodendroglial cells show typical cytologic features and perinuclear halos. Much of the clear area was found to be intensely PAS positive. Mucinous degeneration in the same oligodendroglioma is shown in plate IV-B. × 265.

Although the presence of perinuclear halos is diagnostic, other areas frequently lack this feature, especially in the better preserved portions. Here, positive impregnation for oligodendrocytes with the appropriate silver carbonate technic may then be successful. These areas may show compact arrangements of solid cellular foci (fig. 86), or in some cases very closely packed and densely staining cellular clumps that may at first suggest metastatic carcinoma (fig. 87). The latter appearance is usually seen in biopsy specimens and is probably due to surgical traction or to fixation artifact, since it is found in the peripheral part of the biopsy fragments; it is usually absent in the center of the biopsy specimen (fig. 88). Mitotic figures are highly variable. They may be absent in some fields and quite frequent in others (fig. 88).

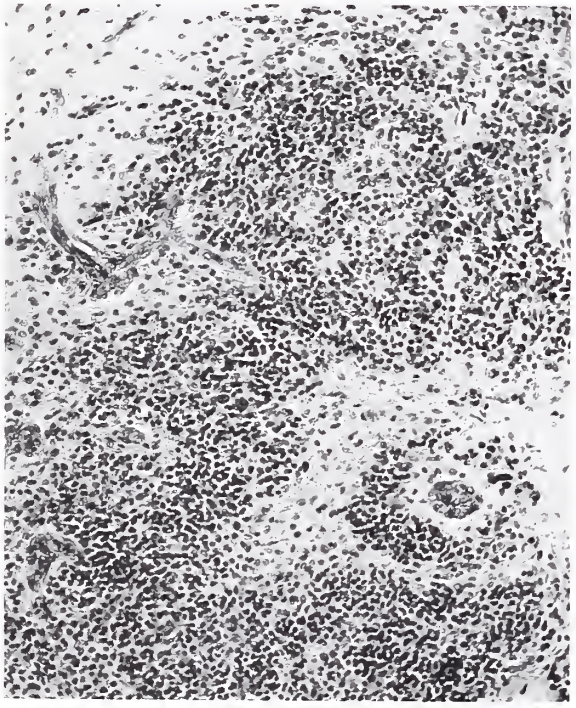

OLIGODENDROGLIOMA

(Figures 86 and 90 from same case)

Figure 86. Compactly arranged solid cellular areas without perinuclear halos are seen in an otherwise typical oligodendroglioma. × 130.

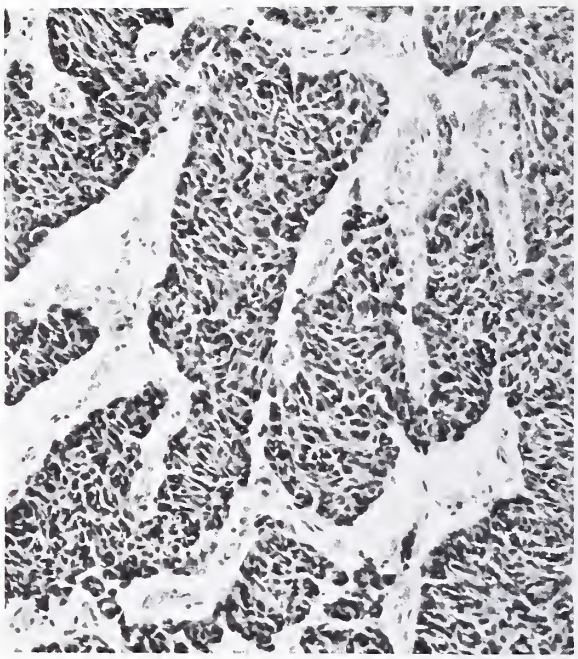

OLIGODENDROGLIOMA

(Figures 87, 88, 103, and 104 from same case)

Figure 87. This oligodendroglioma forming masses of closely packed densely staining tumor cells without perinuclear halos resembles a metastatic carcinoma. This appearance, observed almost always in biopsy material is probably artifactual, since it is usually found in the peripheral parts of the specimen. It may be due to surgical traction artifact. The more central zones of such a biopsy show different cytologic features, illustrated in figure 88. × 145.

Other architectural tissue patterns may be displayed. Occasionally a rhythmic palisading arrangement of the tumor cells is found, mimicking a polar spongioblastoma (fig. 89). In other areas tumor cells may be arranged around blood vessels, either in single layers to form pseudorosettes (fig. 90) or in multiple layers to form perivascular collars (fig. 91). Occasionally, adjacent to typical oligodendroglial cells, large ballooned signet ring cells containing pale eosinophilic cytoplasm are found (fig. 92).

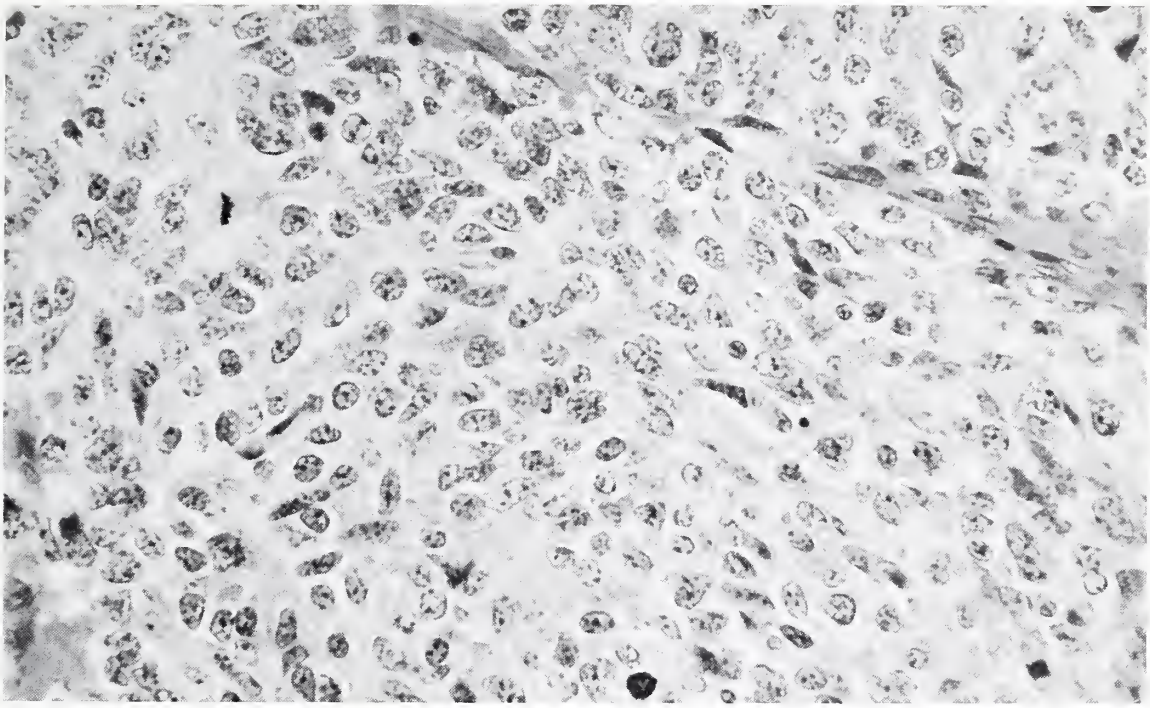

OLIGODENDROGLIOMA

(Figures 87, 88, 103, and 104 from same case)

Figure 88. The tumor cells in this central area are closely packed and consist of rather polymorphic nuclei and ill-defined cytoplasmic outlines. There is only a suggestion of perinuclear halo. Note mitotic figures. × 450.

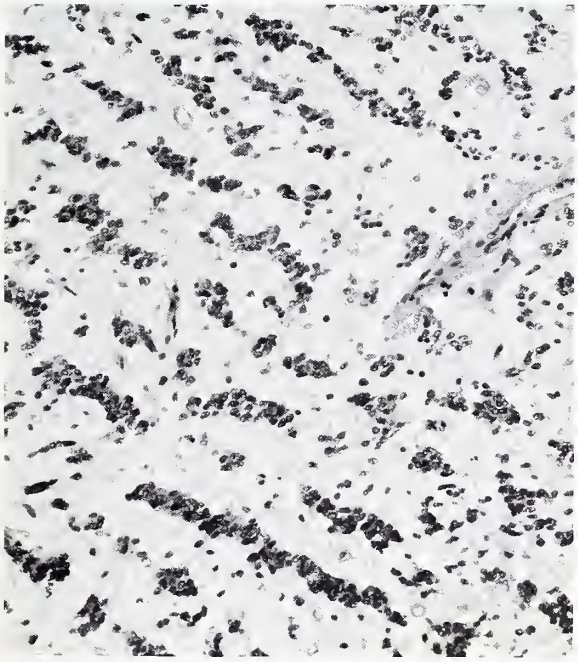

Fig. 89

OLIGODENDROGLIOMA PALISADING PATTERN

(Figures 84 and 89 from same case)

Figure 89. Rhythmic palisading effect of tumor cells arranged in rows is seen in this oligodendroglioma. × 145.

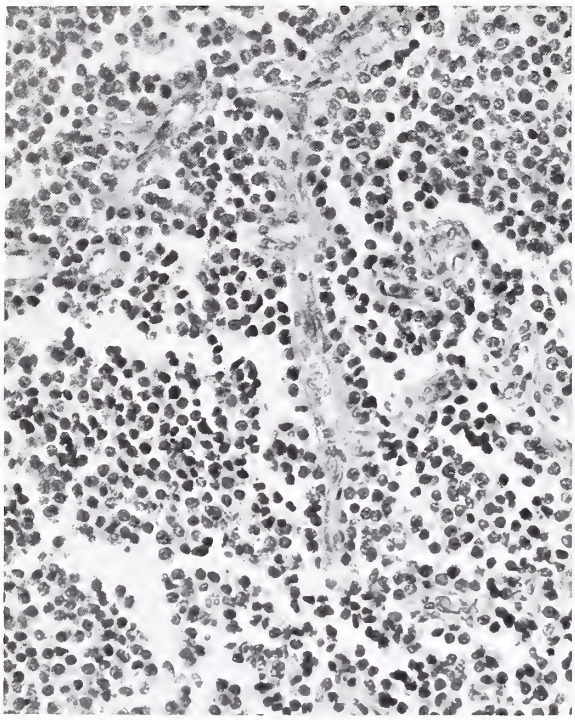

Fig. 90

OLIGODENDROGLIOMA

(Figures 86 and 90 from same case)

Figure 90. This illustrates an arrangement of tumor cells around blood vessels forming papillary structures and perivascular pseudorosettes. × 210.

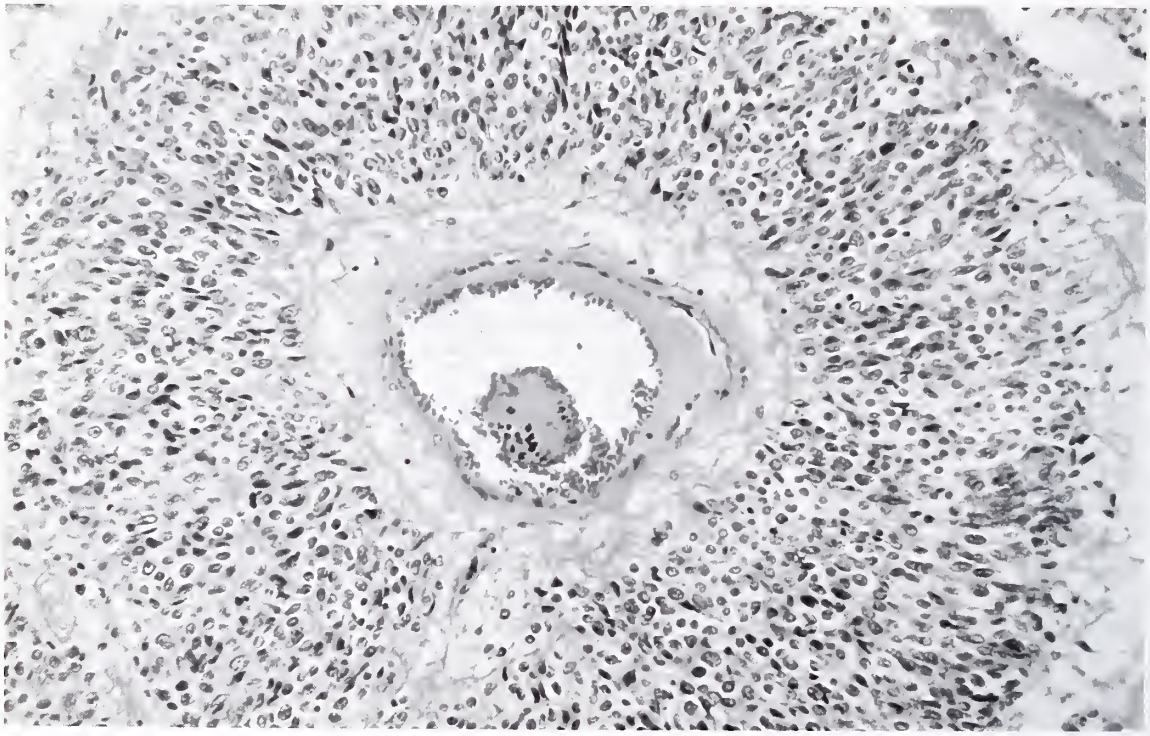

OLIGODENDROGLIOMA. PERIVASCULAR ARRANGEMENT

Figure 91. This illustrates an arrangement of tumor cells in multiple layers around a blood vessel in an oligodendroglioma. × 180.

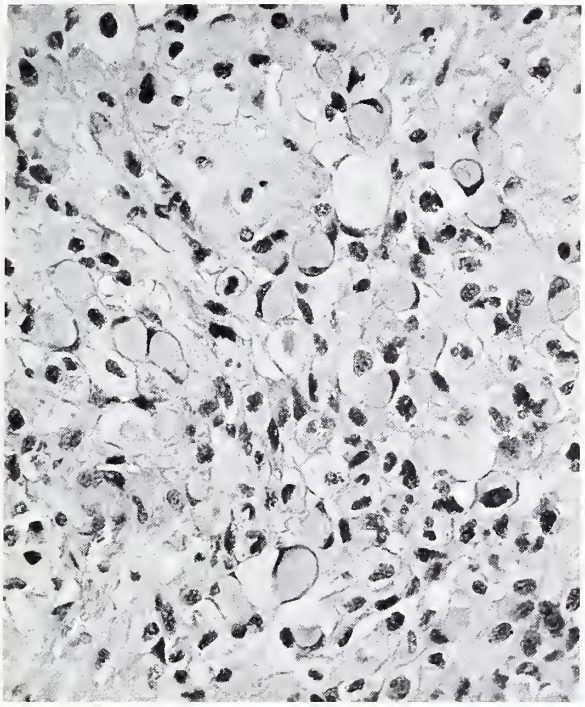

OLIGODENDROGLIOMA
SIGNET RING CELLS

Figure 92. Large ballooned signet ring cells containing pale eosinophilic cytoplasm are shown adjacent to typical oligodendroglial cells in an oligodendroglioma. It is probable that the signet ring cells represent a form of oligodendroglia. No neuroglial fibers are present in this area. × 265.

Although gemistocytic astrocytes are not uncommonly found as part of the mixed picture in a composite oligodendroglioma and astrocytoma, these round cells are probably a form of oligodendroglia, since neuroglial fibers cannot be demonstrated. As in some forms of highly vascular astrocytomas, coarse round hyaline droplets and bodies are sometimes found in oligodendrogliomas (fig. 93).

Electron microscopic observations of these tumors have been made by Luse, and by Raimondi. Numerous mitochondria, sometimes abnormally enlarged, have been noted in some cases. Of particular interest is the observation of Robertson and Vogel, who found highly organized, overlapping, or concentrically arranged lamellae originating from glial cell processes in some oligodendrogliomas. They suggest a capacity on the part of tumor oligodendrocytes to form sheathlike structures (fig. 94).

A frequent microscopic feature, already noted as a gross and radiologic characteristic, is the presence of **calcifications** (fig. 95). These may be found both within the tumor and in the adjacent brain. They are often, although not invariably, related to the blood vessel walls.

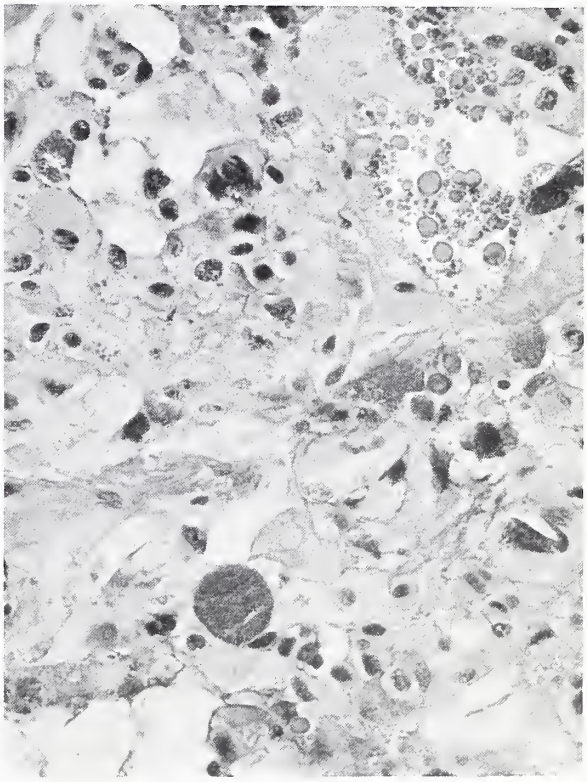

OLIGODENDROGLIOMA. HYALINE
DROPLETS AND GRANULAR BODIES

Figure 93. Coarse hyaline droplets and granular bodies are sometimes found in a typical oligodendroglioma. × 305.

OLIGODENDROGLIOMA

Figure 94. This electron micrograph of an oligodendroglioma reveals enwrapping of the cytoplasmic processes. The concentric orientation of several lamellae in both laminated figures is apparent. In the larger figure, process 1 forms the outermost lamella, process 2 encircles three-fourths of the circumference, process 3 about one-half, and processes 4 and 5 form smaller arcs. This configuration suggests that additional layers are formed by encircling processes, and that the concentricity of the layers is the result of fusion of the ends of the processes. ×44,000. (Courtesy of Dr. David M. Robertson, Kingston, Ontario; also fig. 12 from Robertson, D. M., and Vogel, F. S. Concentric lamination of glial processes in oligodendrogliomas. J. Cell Biol. 15:313–334, 1962).

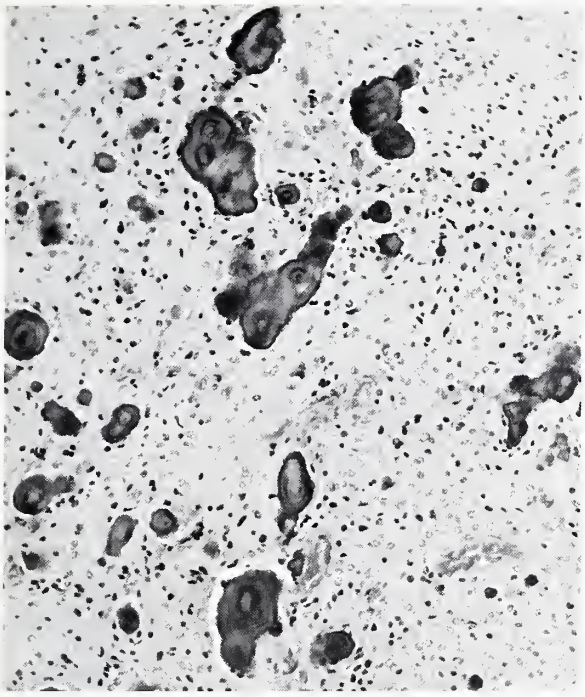

CALCIFICATIONS IN OLIGODENDROGLIOMA

Figure 95. Focal densely staining calcifications (or calcospherites) are common in an oligodendroglioma. × 145.

Occasionally, atypical giant cells are present in a glioma that has otherwise the typical architecture, vascular stroma, and cellular features of an oligodendroglioma (fig. 96). These appearances have been stressed by Zülch and Wechsler and given the name of "polymorphous oligodendroglioma." In my experience this is a rare cytologic feature. Its significance is uncertain. Many of the "polymorphous oligodendrogliomas" of Zülch would be classified by others as mixed oligodendrogliomas and astrocytomas, or as forms of glioblastoma multiforme. The electron micrographs of Zülch and Wechsler illustrate glial filaments in the cytoplasm of some of their examples. The malignant evolution of oligodendrogliomas will be discussed on page 97.

Relatively little attention has been paid to the **stromal** and **vascular** elements in oligodendrogliomas. Characteristically the tumor is intersected by a tenuous connective tissue stroma in which the thin-walled blood vessels are usually stated not to show endothelial proliferation. This regular pattern is

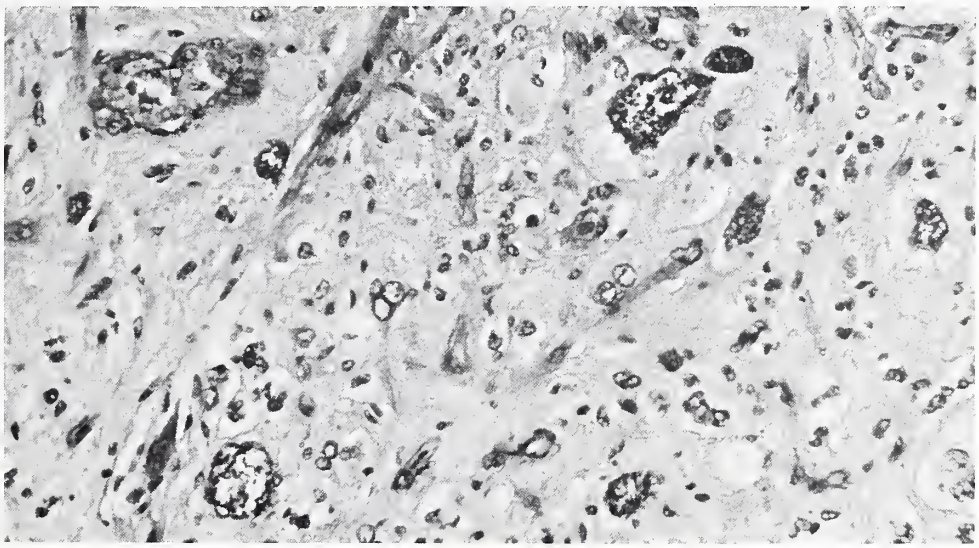

GIANT CELLS IN OLIGODENDROGLIOMA

Figure 96. This picture of atypical giant cells in an oligodendroglioma is probably identical with the "polymorphous oligodendroglioma" of Zülch. × 200.

well shown in reticulin preparations (fig. 97). Sometimes this connective tissue network is more densely intermeshed and separates clusters of oligodendrocytes (fig. 98). Vascular endothelial proliferation is not uncommonly found in oligodendrogliomas (fig. 99) and, contrary to common belief, does not seem to anticipate subsequent malignant behavior. The vascular hyperplasia may be marked. Figures 100 and 101 illustrate a malignant proliferation of endothelial cells in an oligodendroglioma that also contained foci of sarcoma; these probably arose from the neoplastic transformation of blood vessel elements analogous to the mixed glioblastomas and fibrosarcomas previously described on page 74 as variants of glioblastoma.

MIXED FORMS. Oligodendrogliomas often contain glial elements that are recognizably not oligodendroglial. These may include fibrillary or protoplasmic astrocytes, gemistocytes, astroblasts, and spongioblasts. Frequently these various cell forms are closely intermingled, although the prevalent cell component remains that of an oligodendroglioma. Probably 50 percent of tumors generally classified as oligodendrogliomas in fact consist of such mixed cell forms. Biologically, however, their behavior is usually that of an oligodendroglioma. The presence of a mixed cell population poses im-

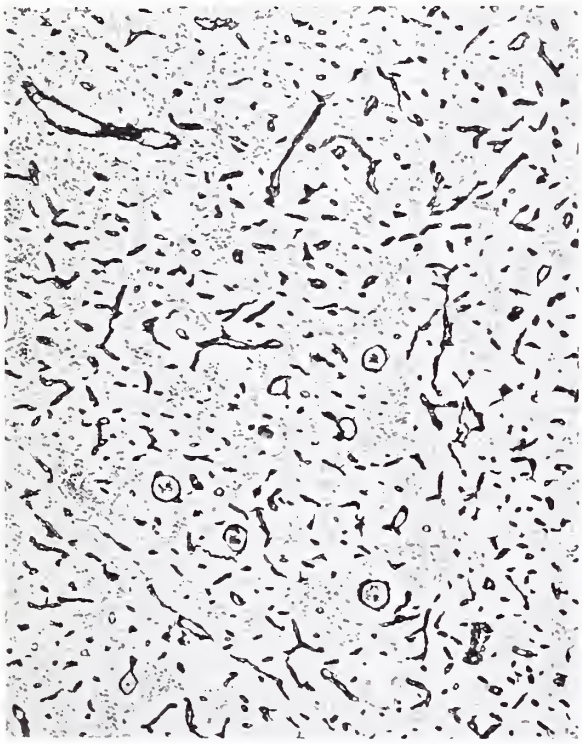

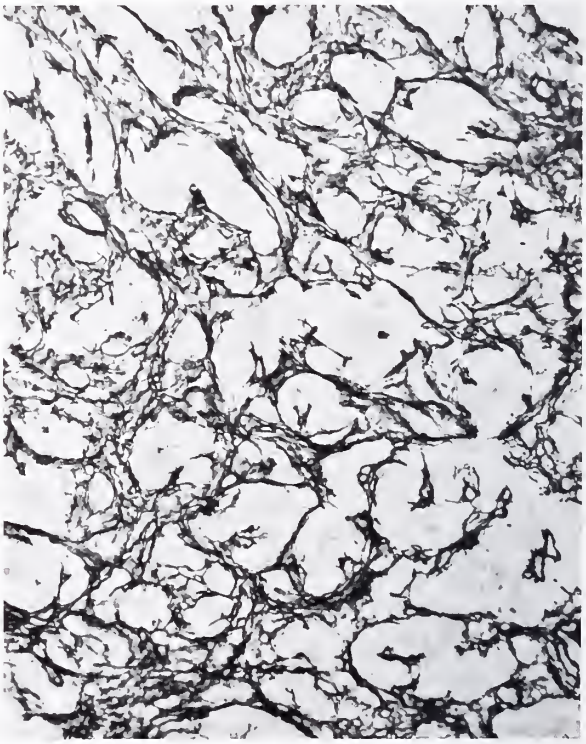

OLIGODENDROGLIOMA. STROMAL AND VASCULAR ELEMENTS

Figure 97. A low power view reveals the connective tissue pattern in a typical oligodendroglioma. The regular arrangement of the thin-walled stroma intersecting the tumor cells is well shown. Silver stain for reticulin. × 60.

(Figures 85, 98, 100, 101, and Plate IV-B from same case)

Figure 98. This shows a more intense reticulin network forming an intersecting stroma separating clusters of oligodendroglial cells. Silver stain for reticulin. × 120.

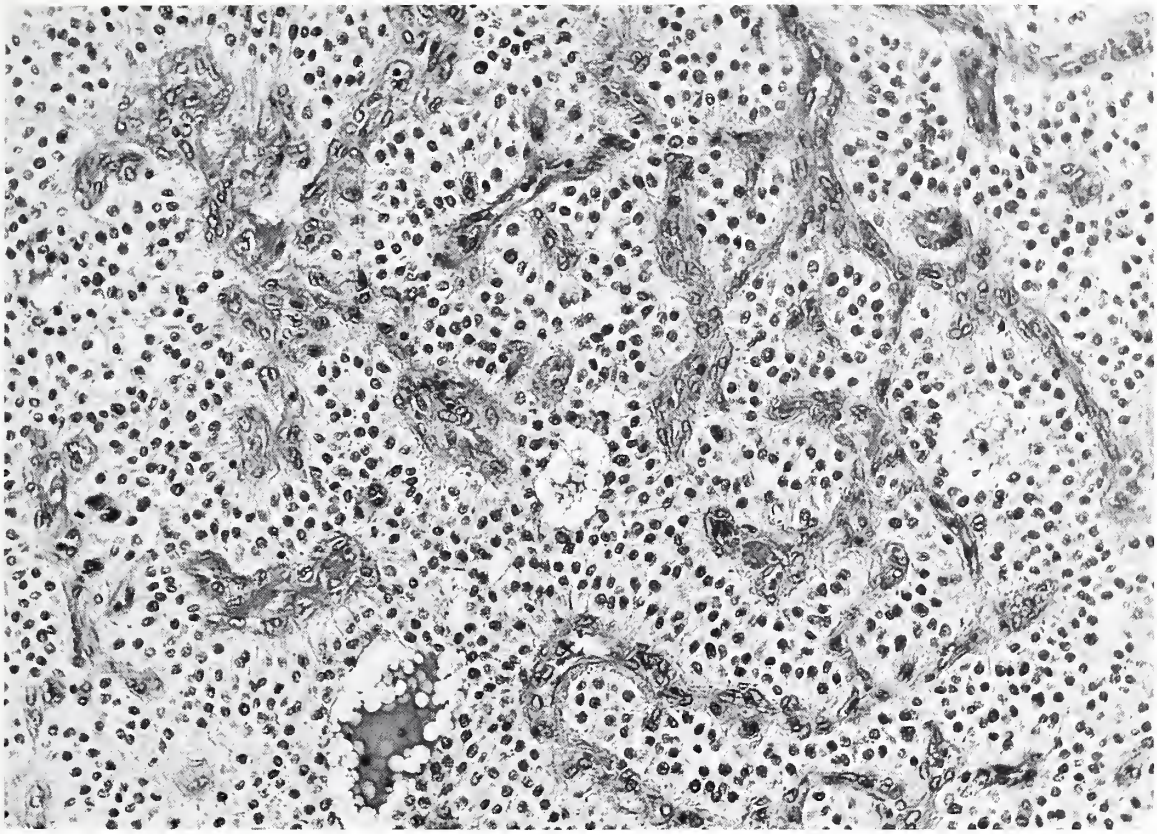

OLIGODENDROGLIOMA. VASCULAR ENDOTHELIAL PROLIFERATION

Figure 99. Note the vascular endothelial proliferation in an oligodendroglioma. × 200.

portant cytologic problems in the further evolution of the tumor, especially in relation to its malignant potential. Aside from the close intermingling of various cell forms, oligodendrogliomas not infrequently contain distinct foci of pure astrocytoma (fig. 102).

MALIGNANT CHANGES. The lack of correlation between the histologic picture and the clinical behavior of the tumor has made of the oligodendroglioma essentially a morphologic rather than a clear-cut biologic entity. Although these tumors frequently grow slowly and may undergo long evolution, others may grow rapidly and behave in a highly malignant fashion. Little help is gained by an attempt to determine the degree of maturity of the tumor cell types, since often the most typical foci of oligodendroglioma seen in paraffin preparations are refractory to appropriate silver carbonate impregnations. Attempts therefore at separating oligodendrocytomas from more primitive forms, so-called oligodendroblastomas, are futile. Similarly the grading of oligodendrogliomas from a prognostic point of view is often disappointing, since many of the cytologic and histologic features that normally serve as criteria for a grading system are found to be unreliable in practice. The presence of mitotic figures, obviously associated with a rapid rate of growth, is not necessarily attended by an increase of anaplastic features in the tumor cells, or with a more sinister

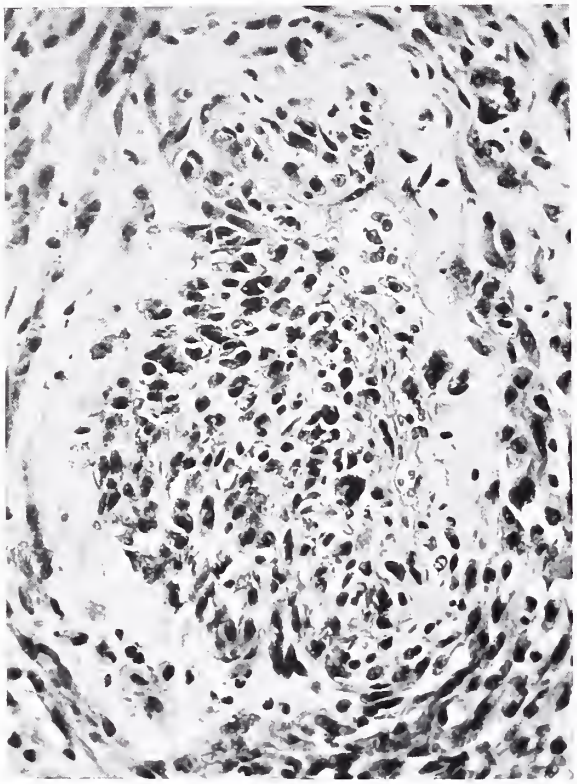

OLIGODENDROGLIOMA. MALIGNANT VASCULAR PROLIFERATION

Figure 100. This represents malignant endothelial proliferation in an oligodendroglioma that also contained areas of sarcoma, probably arising from the neoplastic transformation of vascular wall elements. × 230.

(Figures 85, 98, 100, 101, and Plate IV-B from same case)

Figure 101. A reticulin preparation of the same field demonstrates intense connective tissue proliferation. Silver stain for reticulin. × 115.

prognosis after subtotal extirpation. As mentioned before, vascular endothelial proliferation is often found in otherwise typical oligodendrogliomas. Calcification, although frequently accompanying long-standing tumors, is not necessarily indicative of a better prognosis and may be associated with a rapid fatal recurrence. Attempts have also been made to separate "isomorphous" from "polymorphous" oligodendrogliomas. In such instances criteria of recognition become even more questionable. Although giant cells are occasionally met in oligodendrogliomas in the absence of other features of anaplasia, their significance is obscure.

On the other hand, several experiences are on record in which a more rapid acceleration in the growth of the tumor has been attended by increased anaplasia of its cytologic features and a terminal picture indistinguishable from that of a glioblastoma multiforme. The development of malignant changes of this kind has been described and reviewed by Barnard. In many of the tumors, however, the problem was complicated by the presence of obvious astrocytic elements. In these cases the development of glioblastomatous features may have been the result of malignant changes in the astrocytomatous component, as conceded by

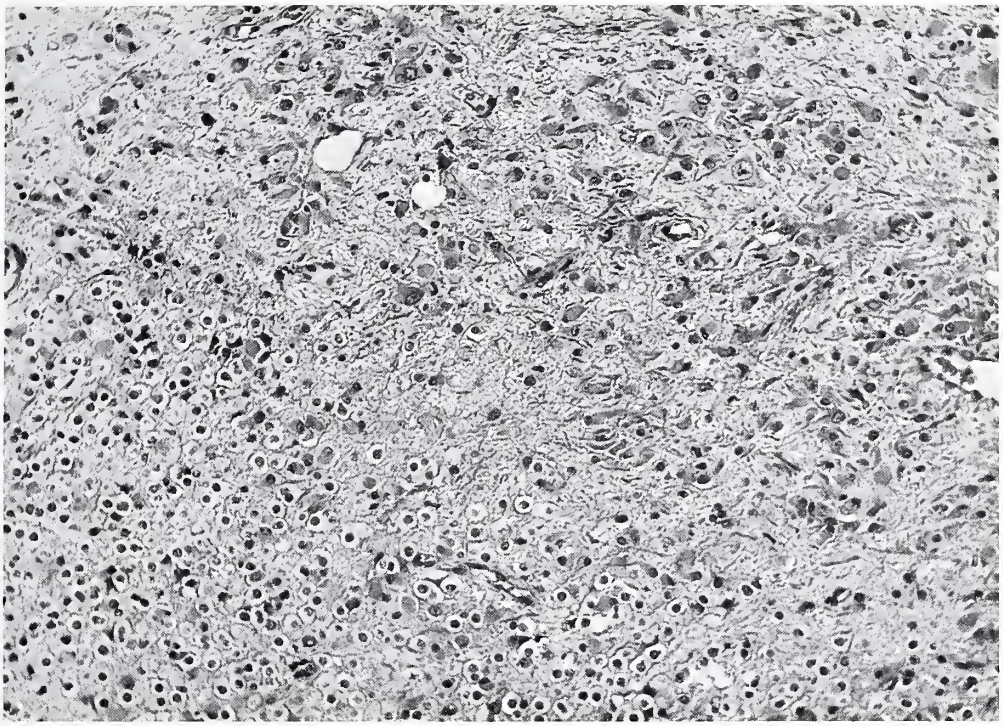

MIXED OLIGODENDROGLIOMA AND ASTROCYTOMA

Figure 102. This illustrates a typical area of oligodendroglioma (lower left) adjacent to an area of fibrillary astrocytoma (upper right). × 195.

Barnard. Finally there are examples of glioblastoma multiforme in which no evidence of a derivation from astrocytic elements can be postulated (p. 55), and the possibility of its originating from a rapidly dedifferentiating oligodendroglioma must then be entertained. In the final analysis therefore, the diagnosis of a malignant oligodendroglioma should be made with extreme caution on the basis of a biopsy only, and unfortunately in most cases a true evaluation of the tumor can be made only at the end of its course.

GROWTH AND SPREAD. METASTASIS. Although the tumor is often well defined grossly, microscopic examination of various segments of its periphery often discloses more diffuse infiltration further afield. The secondary structures of Scherer (pp. 11, 12) are not uncommonly found, and may be seen either beneath the pia (fig. 103) or more characteristically around the neurons (fig. 104); the latter are reminiscent of the phenomenon of satellitosis seen in nonneoplastic brain.

Metastatic dissemination of oligodendrogliomas is well known to occur through the cerebrospinal fluid pathways (Beck and Russell; Best). Spread may be massive, as in medulloblastomas and glioblastomas, or a slow chronic process evolving over a period of years. It is not necessarily associated with anaplastic changes in the original tumor. The primary tumor may be inconspicuous, abutting the ventricle. As a consequence of the gradual diffuse infiltration of the subarachnoid space by tumor, the leptomeninges may mimic the picture of chronic inflammation, with resulting hydrocephalus (Best).

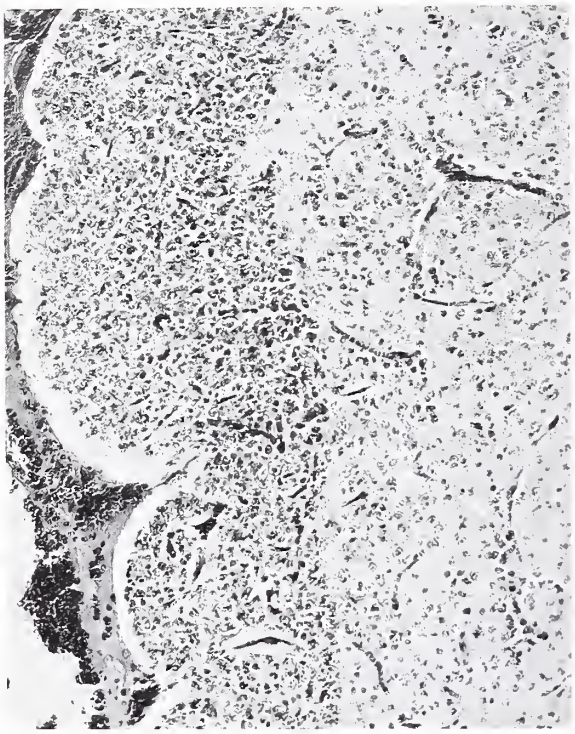

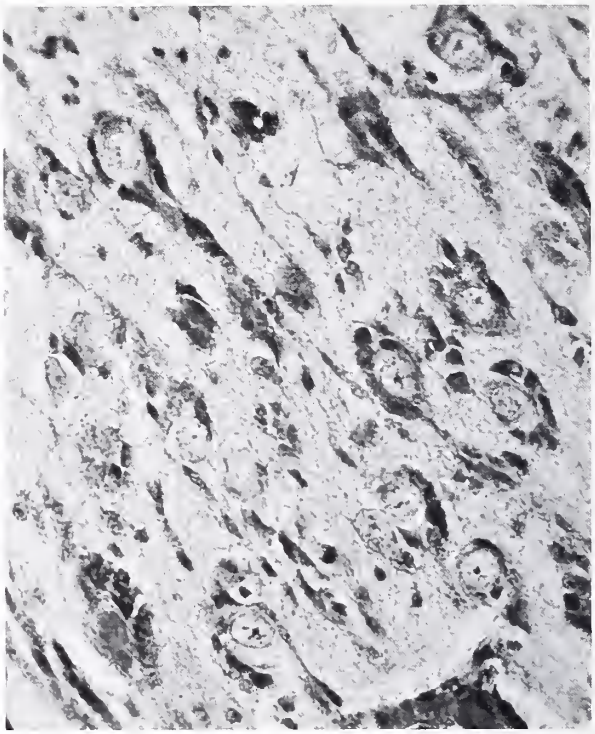

OLIGODENDROGLIOMA. GROWTH AND SPREAD

(Figures 87, 88, 103, and 104 from same case)

Figure 103. This is a subpial secondary structure in an oligodendroglioma. × 115.

Figure 104. This adjacent field illustrates secondary perineuronal structures in an oligodendroglioma. × 325.

The total length of the clinical history in these cases may extend over many years.

Remote metastases from oligodendrogliomas have been recorded in a few cases (James and Pagel; Spataro and Sacks). In both reports, extracranial deposits developed after repeated craniotomies and massive infiltration of the extracranial soft tissues had occurred.

TREATMENT. The treatment of choice is as radical surgical removal as possible. Opinions vary whether the tumor is radiosensitive and whether postoperative radiation should be given. According to Sheline and associates a significant improvement of survival was shown in a small group of patients given postoperative radiation compared with those treated by surgery alone. Shenkin believes that, although the oligodendrogliomas are sensitive to radiation, the latter should be withheld until postoperative recurrence of the tumor is evident: this opinion is opposed by Weir and Elvidge. Many treatment centers give postoperative radiation despite the lack of statistically significant experience in the management of these tumors.

PROGNOSIS. The prognosis of oligodendroglioma is notoriously uncertain. Recurrence is a frequent sequel, occurring in about 50 percent of the cases (Roberts and German). In the series analyzed by these workers, including the patients originally operated on by Harvey Cushing, the average postoperative survival period was 5.6 years; the longest was 36 years. Patients

with total removal of the tumor had a lower mortality and longer survival than those with partial removal only. According to Weir and Elvidge, 41 percent of their 63 patients had a postoperative survival of five years, a figure that compared favorably with the supratentorial astrocytomas in the same series.

DIFFERENTIAL DIAGNOSIS. The diagnosis is usually easy if enough tissue is available for sampling, but difficulties may be met in small biopsy fragments, especially in relation to other glial tumors. Astrocytomas composed of small stellate cells with delicate processes may resemble oligodendrogliomas in their uniform histologic picture; special stains for neuroglial fibers are then necessary. Some highly cellular oligodendrogliomas, particularly those in which no perinuclear halo is evident, may resemble microcellular glioblastomas. A primary tumor from the posterior fossa composed of small, uniform, darkly staining cells may provoke the differential diagnosis between medulloblastoma and oligodendroglioma; indeed, some workers believe that medulloblastomas may be partly composed of oligodendrocytes. Bodian and Lawson interpreted many medulloblastomas in the posterior fossa as undifferentiated oligodendrogliomas and regarded supratentorial oligodendrogliomas in children as differentiated forms of medulloblastoma. The regular cells and the delicate intersecting vascular connective tissue network are found also in pineocytomas; when the cytoplasm in the latter is indistinct with a picture reminiscent of perinuclear halos, differential diagnosis from an oligodendroglioma may be extremely difficult.

Oligodendrogliomas may also be confused with nonglial tumors. A classic trap for the unwary is the small biopsy taken from the depth of a frontal lobe in an unsuspected case of chromophobe adenoma of the pituitary that has extended above the sella turcica into the third ventricle: the uniform cellular appearance of the diffuse type of pituitary adenoma may closely mimic that of an oligodendroglioma. The peripheral portions of a uniform oligodendroglioma may stain so darkly as to form distinct clusters that resemble foci of metastatic oat cell carcinoma (fig. 86). Confusion may also arise occasionally between a highly vascular oligodendroglioma and a cerebellar hemangioblastoma: the pale staining stromal cells of the latter have been misinterpreted as oligodendroglial, and the error may be compounded by the fact that some oligodendrogliomas are extremely vascular.

Some oligodendrogliomas situated near the surface may invade the leptomeninges early and become tethered to the dura. As a consequence the overlying proliferation of fibrous connective tissue from the dura, and the "epithelial" appearance of the underlying glioma may mimic the picture of an endotheliomatous meningioma. Since the oligodendroglioma is often well defined and may be entirely removable, the differential diagnosis in these circumstances may be surprisingly difficult. Difficulties also occasionally arise in distinguishing a diffusely infiltrating oligodendroglioma forming secondary structures around blood vessels from the reticulum cell sarcoma-microglioma group when the latter is unusually uniform. When in doubt a reticulin stain will demonstrate the characteristic increase of reticulin fibers in the invaded perivascular spaces in reticulum cell sarcoma-microglioma; if frozen tissue is available, the appropriate metallic impregnation for oligodendroglial and microglial cells should be performed.

PLATE IV

OLIGODENDROGLIOMA

(Plate IV-A and Figures 81–83 from same case)

A. This is a large, well defined, extensively cystic and hemorrhagic oligodendroglioma invading the right lateral ventricle in a 14-year-old girl. Note the severe external herniation of the brain following surgical decompression. (Courtesy of Dr. J. E. Olvera Rabiela, Mexico City, Mexico; also fig. 17 from Rubinstein, L. J. Seminario de Neuropatologia, Mérida, Yucatán, Bol. Asoc. Mex. Patol., A. C. 7:13–59, 1969).

OLIGODENDROGLIOMA

(Plate IV-B and Figures 85, 98, 100, and 101 from same case)

B. Swollen oligodendrogliomatous cells are filled with intensely PAS positive material. PAS. × 160.

SMEAR FROM OLIGODENDROGLIOMA

C. This smear was obtained from a homogeneous, highly cellular tumor composed of uniform spherical nuclei with a delicate chromatin network. Note mitotic figure in circle. Morris. × 400.

SUBEPENDYMOMA

(Plate IV-D and Figure 122 from same case)

D. This highly fibrillated appearance is demonstrated in a classic subependymoma filling the fourth ventricle, found incidentally postmortem in a 63-year-old man. There was no dilatation of the lateral or third ventricles. Holzer stain for glia. × 300.

SMEAR FROM EPENDYMOMA

E. This smear from an ependymoma shows a characteristic fernlike pattern produced by the arrangement of multiple layers of ependymoma cells around a central thin-walled vascular core. Morris. × 265.

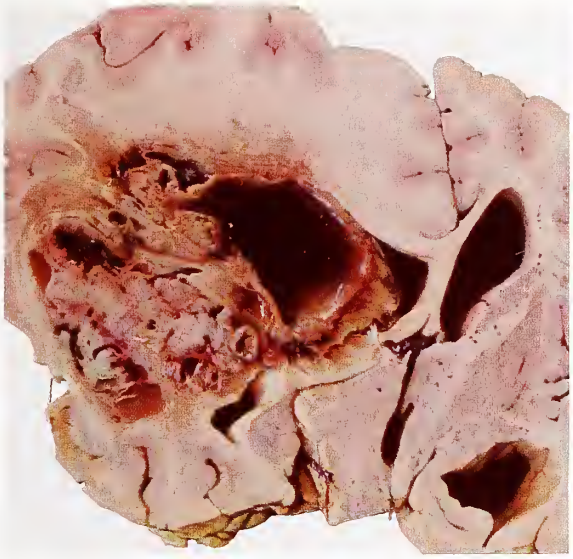

A

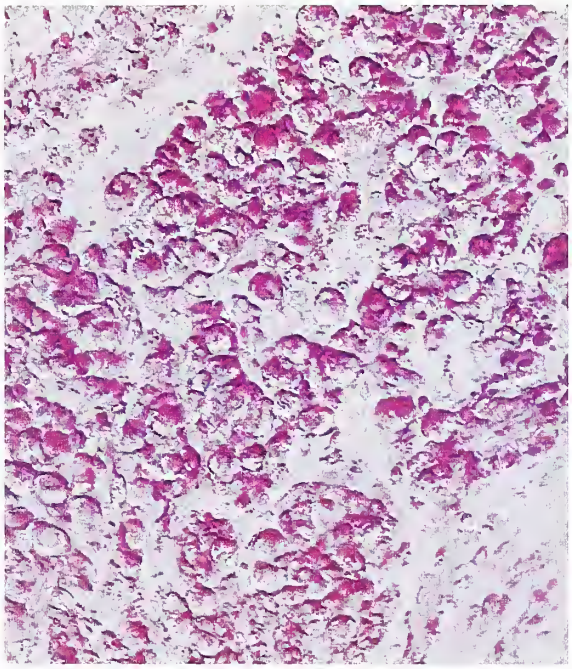

B

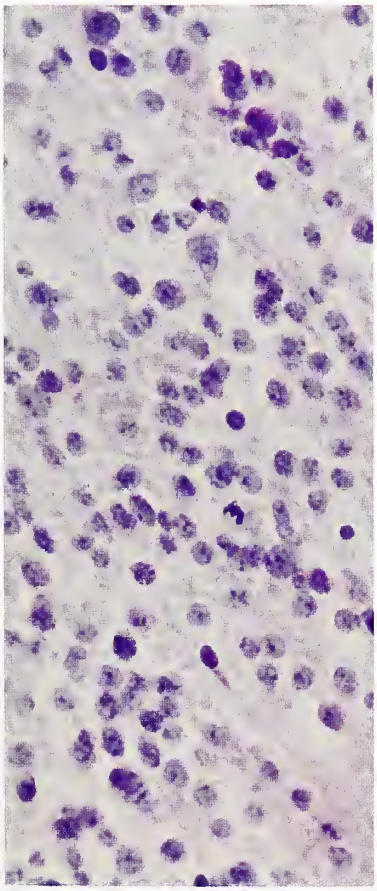

C

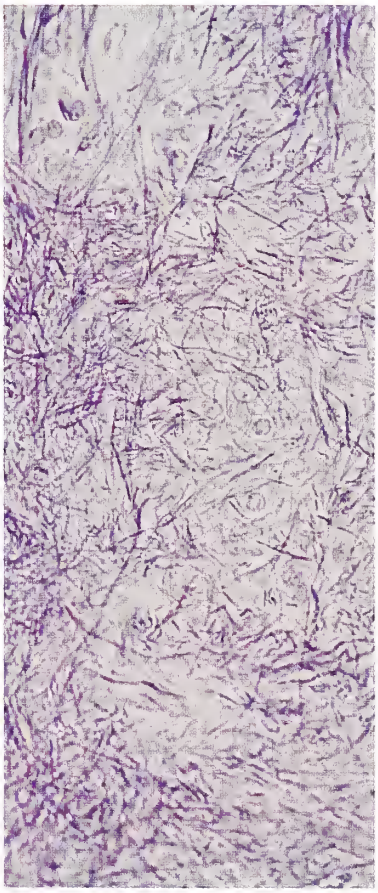

D

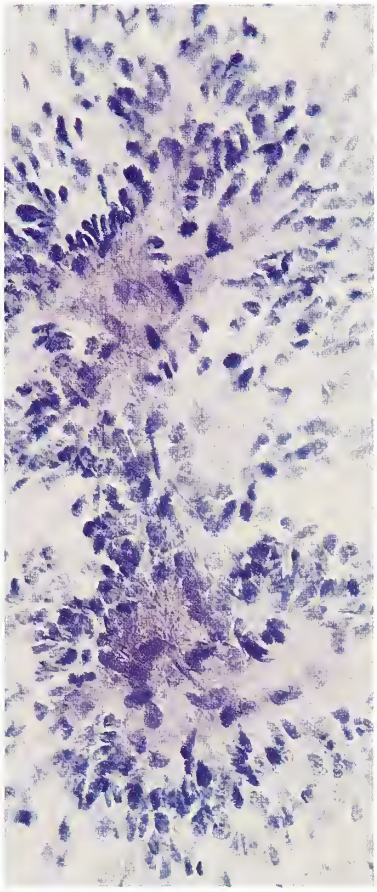

E

PLATE IV

References

Bailey, P., and Bucy, P. C. Oligodendrogliomas of the brain. J. Path. Bact. 32:735–751, 1929.

Barnard, R. O. The development of malignancy in oligodendrogliomas. J. Path. Bact. 96:113–123, 1968.

Beck, D. J. K., and Russell, D. S. Oligodendrogliomatosis of the cerebrospinal pathway. Brain 65:352–372, 1942.

Best, P. V. Intracranial oligodendrogliomatosis. J. Neurol. Neurosurg. Psychiat. 26:249–256, 1963.

Bodian, M., and Lawson, D. The intracranial neoplastic diseases of childhood. A description of their natural history based on a clinico-pathological study of 129 cases. Brit. J. Surg. 40:368–392, 1953.

Freeman, L., and Feigin, I. Oligodendroglioma with 35-year survival. J. Neurosurg. 20:363–365, 1963.

James, T. G. I., and Pagel, W. Oligodendroglioma with extracranial metastasis. Brit. J. Surg. 39:56–65, 1951.

Lüginbühl, H. Comparative aspects of tumors of the nervous system. Ann. N. Y. Acad. Sci. 108, Art. 3:702–721, 1963.

Luse, S. A. Electron microscopic studies of brain tumors. Neurology 10:881–905, 1960.

Raimondi, A. J. Ultrastructure and the Biology of Human Brain Tumors, pp. 1–63. In: Progress in Neurological Surgery, Vol. 1. (Eds.) Krayenbühl, H., Maspes, P. E., and Sweet, W. H. Chicago: Year Book Medical Publishers, Inc., 1966.

Roberts, M., and German, W. J. A long term study of patients with oligodendrogliomas. Follow-up of 50 cases, including Dr. Harvey Cushing's series. J. Neurosurg. 24:697-700, 1966.

Robertson, D. M., and Vogel, F. S. Concentric lamination of glial processes in oligodendrogliomas. J. Cell Biol. 15:313–334, 1962.

Scherer, H. J. Structural development in gliomas. Amer. J. Cancer 34:333–351, 1938.

Sheline, G. E., Boldrey, E. B., Karlsberg, P., and Phillips, T. L. Therapeutic considerations in tumors affecting the central nervous system; oligodendrogliomas. Radiology 82:84–89, 1964.

Shenkin, H. A. The effect of roentgen-ray therapy on oligodendrogliomas of the brain. J. Neurosurg. 22: 57–59, 1965.

Spataro, J., and Sacks, O. Oligodendroglioma with remote metastases. Case report. J. Neurosurg. 28: 373–379, 1968.

Weir, B., and Elvidge, A. R. Oligodendrogliomas. An analysis of 63 cases. J. Neurosurg. 29:500–505, 1968.

Zülch, K. J., and Wechsler, W. Pathology and Classification of Gliomas, pp. 1–84. In: Progress in Neurological Surgery, Vol. 2. (Eds.) Krayenbühl, H., Maspes, P. E., and Sweet, W. H. Chicago: Year Book Medical Publishers, Inc., 1968.

EPENDYMOMAS

DEFINITION. Ependymomas are neoplasms composed of, and usually derived from, differentiated ependymal cells.

MORPHOLOGIC FEATURES OF THE NORMAL AND ABNORMAL EPENDYMAL CELL. The recognition of ependymomas rests either on the presence of cell forms that morphologically recall mature ependymal elements, or, since rare examples may display more primitive cytologic features, on the formation of rosettes with a well defined central lumen. Of special importance is the demonstration of **cilia** and **blepharoplasts.** In the normal ependyma, blepharoplasts present as small darkly staining dots just within the limit of resolution of the light microscope and are lined along the luminal side of the cytoplasm as it borders the ventricular cavity (fig. 105). They are best demonstrated with phosphotungstic acid hematoxylin, and sometimes with iron hematoxylin or with the Holzer stain for glia. Occasionally they are argentophilic (fig. 113). They correspond in electron micrographs to the basal bodies in which the ciliary shafts terminate in the cytoplasm, as illustrated in the rat ependyma by Brightman and Palay (fig. 107). When ependymal cells are displaced from the ventricular surface they often lose their cilia, and the blepharoplasts

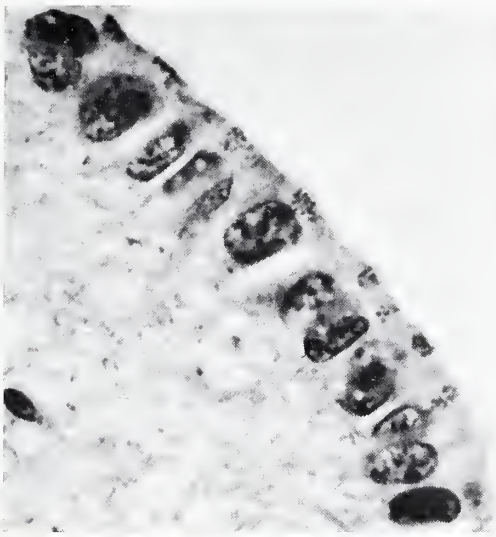

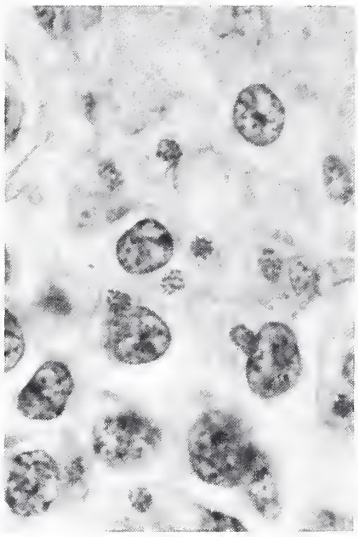

BLEPHAROPLASTS

Figure 105. Groups of blepharoplasts are noted along the luminal border in the cytoplasm of normal ependymal cells lining the lateral ventricle. PTAH. × 1260.

Figure 106. Groups of blepharoplasts are seen on one side of the nuclei of ectopic paraventricular ependymal cells. PTAH. × 1280.

tend to lie near the nucleus, where they form distinct clusters in an area of more lightly stained cytoplasm (fig. 106). These structures are therefore a diagnostic hallmark for the recognition of ependymal cells, but are often admittedly difficult to identify, especially in biopsy material, since the staining properties of the blepharoplasts are similar to those of mitochondria. Furthermore the frequent presence of neuroglial fibrils in these tumors when seen in cross sections may make the confident recognition of blepharoplasts impossible.

Another feature of the nonneoplastic ependymal cell is its capacity to acquire as a reactive phenomenon a tapering fibrillated process and strongly staining intracytoplasmic fibrils. This may occur either as the result of chronic low grade inflammation or in the vicinity of invading intracerebral tumors (Russell and Rubinstein). The presence of cytoplasmic glial filaments in normal as well as in neoplastic ependymal cells has also been confirmed with the electron microscope (fig. 107; Brightman and Palay; Raimondi; Zülch and Wechsler). These observations are helpful in establishing that ependymomas are often strongly fibrillated. The subependymal glial cells, which are normally intimately related to the ependymal cells, may also possibly play a part in the formation of ependymomas, and this too may account for the fact that fibrillated astrocytic cells sometimes constitute the predominant cell forms. This is of special relevance to the understanding of a variant of the ependymoma, termed "subependymoma," which will be described on page 116.

NATURAL HISTORY AND CLINICAL DATA. The majority of ependymomas grow slowly as circumscribed neoplasms that seldom spread further afield or display

NORMAL EPENDYMAL CELL (ADULT RAT)

Figure 107. This electron micrograph shows three adjacent ependymal cells of the third ventricle. Note the numerous irregular folds along the cell surfaces, partially or completely enveloping the ciliary shafts (c). The apical portion of the cytoplasm contains the basal bodies (or blepharoplasts) (b) and their rootlets (r). Whorls of cytoplasmic filaments are also seen, usually near the nuclei, in both longitudinal and transverse sections. The surface specializations shared by two of the adjacent cells include two apically situated fasciae adherentes (f), joined by a gap junction (g). One of the cell processes lying within the ventricle may be neuronal in origin (n). A centriole (ce) lies adjacent to the nucleus of the lower cell. × 17,000. (Courtesy of Dr. Milton W. Brightman, Bethesda, Md.; also fig. 4 from Brightman, M. W., and Palay, S. L. The fine structure of ependyma in the brain of the rat. J. Cell Biol. 19:415–439, 1963).

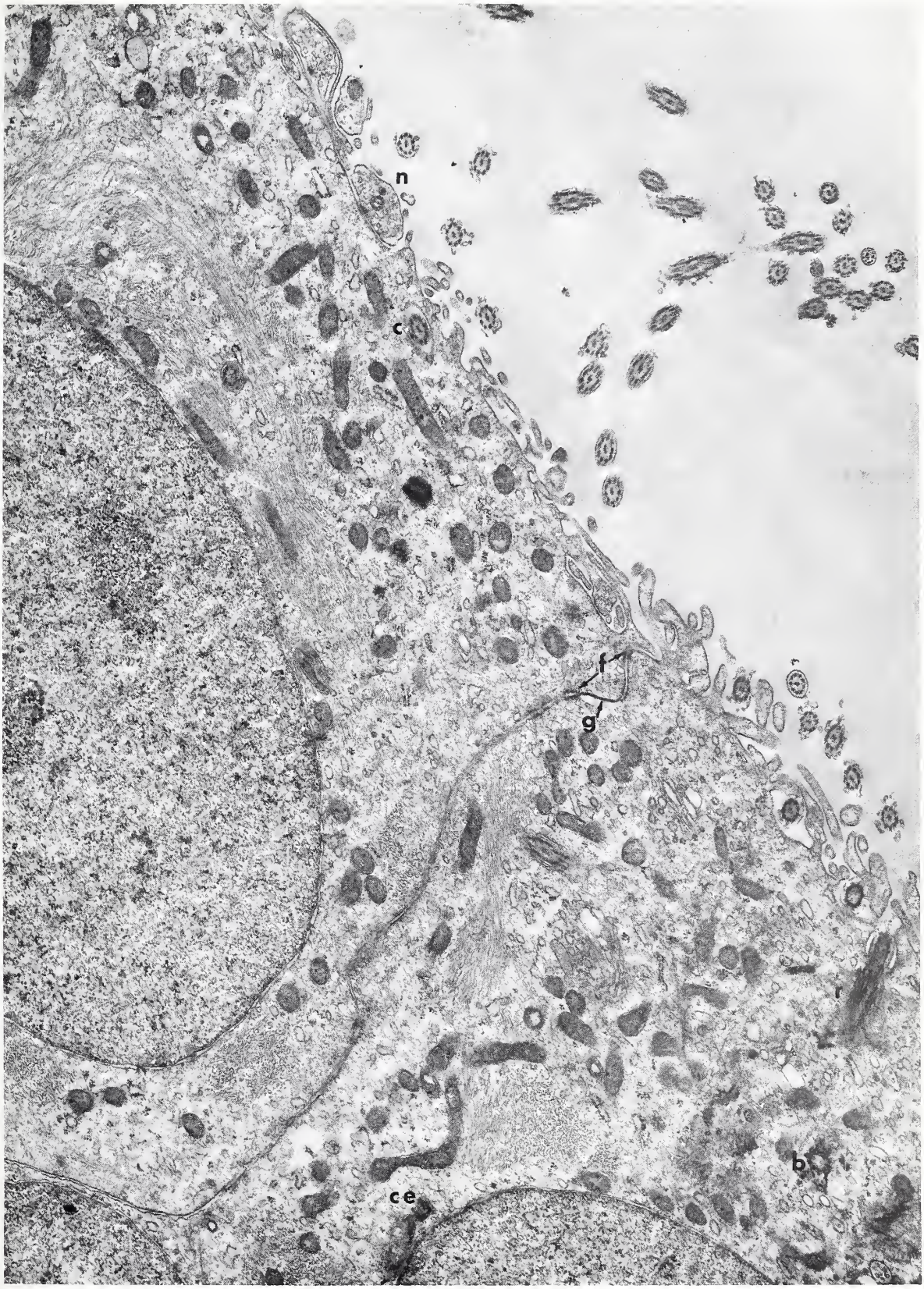

Fig. 107

cytologic malignancy. Symptoms are generally due to the presence of a space-occupying lesion whose clinical effects vary according to its location above or below the tentorium, or in the spinal canal. Those arising from the filum terminale may give rise to symptoms referable to the nerve roots of the cauda equina. Occasionally the tumor may long be clinically silent and present with a short history suggesting a rapidly progressive meningitis (fig. 108), or there may be a long history of mental deterioration due to progressive hydrocephalus, suggestive of diffuse cerebral degenerative disease (figs. 109, 110). Although histologically benign, many ependymomas are a dangerous operative risk because of their situation, and therefore the prognosis may be relatively poor.

INCIDENCE. Ependymomas constitute approximately 5 to 6 percent of all **intracranial** gliomas. According to the large series of Fokes and Earle, those situated in the cerebral hemispheres are evenly distributed through all age groups whereas, in the infratentorial examples, those in the first decade of life constitute the largest single category (33 of 83 cases). Ependymomas account for 8 percent of intracranial gliomas in children. By contrast the small symptomless subependymomas found incidentally in the fourth ventricle are usually encountered in middle-aged or elderly subjects.

In the **spinal cord**, ependymomas constitute the majority of intramedullary gliomas, accounting for 63 percent of them according to Slooff and his associates. The age distribution of their cases indicates a fairly even distribution from the second to the sixth decade, with a peak in the fourth decade of life.

SITES. Intracranial ependymomas are, as may be anticipated, typically intraventricular tumors. The fourth ventricle is the most common site, accounting for 70 percent of the intracranial cases reviewed by Fokes and Earle. In the spinal cord, 37 percent of the ependymomas originate in the lumbar and sacral regions, many from the filum terminale or conus medullare. Many of these belong to the variant of myxopapillary or papillary ependymoma of the filum terminale, described on page 118.

Extraspinal ependymomas arising in the sacrum have also been reported (Cooper et al.).

MULTIPLICITY. ASSOCIATED LESIONS. Multiple intramedullary ependymomas are a classic feature of the central form of von Recklinghausen's neurofibromatosis. The association of spinal ependymoma and syringomyelia has also been well documented (Poser).

GROSS. Ependymomas are almost always well demarcated. Those arising in the fourth ventricle may gradually expand the cisterna magna and protrude in the subarachnoid space to form a sizable tongue-like projection (fig. 109). This may further surround and compress the dorsal and lateral aspects of the medulla and upper cervical cord (fig. 108). This characteristic form of growth has been described by Courville and Broussalian, and termed "plastic ependymoma"; many of these tumors originate from the lateral recesses of the fourth ventricle and project from the foramina of Luschka as rather soft papillary masses. The cut surfaces are usually homogeneous, grayish and granular, and occasionally focally hemorrhagic (fig. 110). The large tumors, especially those arising above the tentorium, may be cystic. Small, gritty foci of calcification may be found in both the infratentorial and the supratentorial examples.

Fig. 108

EPENDYMOMA

(Figures 108, 111, 112, and 116 from same case)

Figure 108. Large ependymoma from the fourth ventricle of a 10-month-old infant boy, who presented with a short clinical history of meningeal irritation. A collar of tumor surrounds the posterior and lateral aspects of the medulla (so-called "plastic ependymoma"). Note the marked flattening of the cerebral convolutions, due to chronic obstructive hydrocephalus.

EPENDYMOMA PRESENTING IN CISTERNA MAGNA

(Figures 109 and 110 from same case)

Figure 109. A tongue of firm, pinkish gray granular tumor that arose in the fourth ventricle of a 65-year-old woman is plugging the cisterna magna. The collar of tissue dorsal to it is part of the markedly edematous medulla. There is bilateral grooving of the cerebellar tonsils, and the midline structures of the posterior fossa had severely herniated into the foramen magnum.

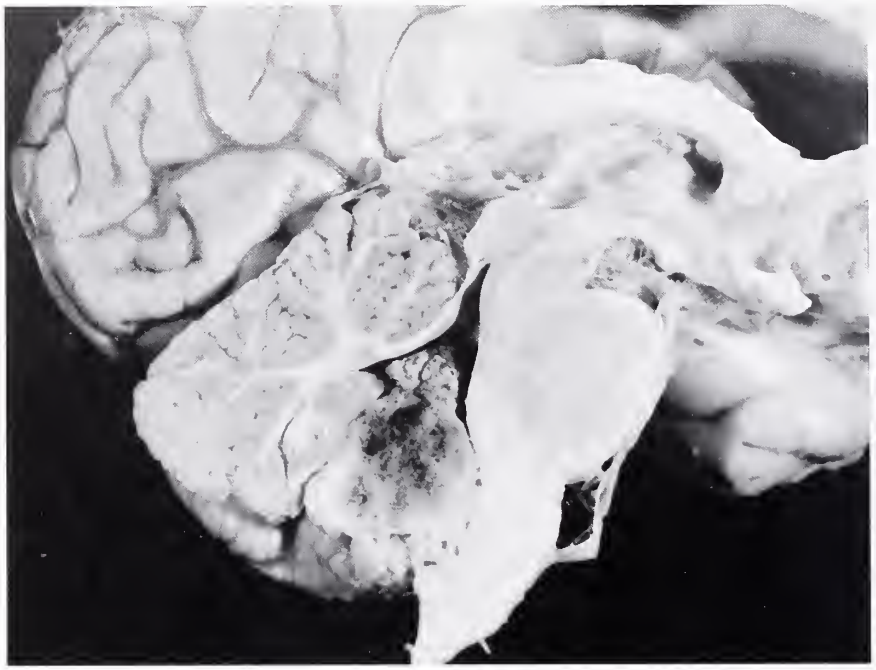

EPENDYMOMA OF FOURTH VENTRICLE

(Figures 109 and 110 from same case)

Figure 110. This midsagittal section of the posterior fossa structures shows the major part of the fourth ventricle filled by a fairly well defined growth, granular and pink at its periphery, and centrally hemorrhagic. Note the nodular projection of the tumor into the central part of the fourth ventricle as well as its caudal extension into the greatly enlarged cisterna magna. The cerebellum is not grossly invaded. There is marked dilatation of the lateral ventricle due to internal hydrocephalus. This tumor was found in a 65-year-old woman who had a history of mental deterioration over the past three years and changes in gait for six months. A clinical diagnosis of diffuse degenerative cerebral disease had been made. Microscopically this tumor was a papillary ependymoma.

In the spinal cord ependymomas usually form well defined, elongated intramedullary masses that can be shelled out at surgery. The special variant to be described below as myxopapillary may either consist of a similarly circumscribed fusiform swelling of the filum that displaces the roots of the cauda equina laterally, or may, by the time it is exposed at surgery, infiltrate the thecal sac more diffusely and make surgical removal impossible.

MICROSCOPIC. The ependymomas are fairly cellular neoplasms with a regular histologic pattern and cytologic features indicative of low malignant potential. The cell bodies may be polygonal or fusiform, often angulated and triangular. Typically the nuclei are very regular, round or slightly ovoid, with delicate pinpoint chromatin nodes surrounded by a distinct nuclear membrane. This contrasts with the more irregular, coarsely stained chromatin nodes found in other primary gliomas. Except in the rare malignant examples, mitotic figures are not a feature. The blood vessels are usually thin-walled, and devoid of endothelial proliferation. Foci of necrosis are uncommon, but may be found in the larger examples in

the absence of other evidence of histologic malignancy. Cellular pleomorphism, hyperchromatism, multinucleation, and giant cell formation are very uncommon, and when present should arouse the suspicion of malignant change.

The most characteristic and essentially diagnostic feature of the ependymomas is the presence of ependymal **rosettes** (figs. 111, 113, 115) around which the tumor cells are aligned to reproduce in miniature the lining of the normal ependymal cavity. Cilia can sometimes be demonstrated, and blepharoplasts are virtually always found with special staining technics along the free borders of the ependymal cells (fig. 113). In some areas the rosettes are more elongated and have a tubular shape (fig. 112). In other areas the tumor may show a more uniform

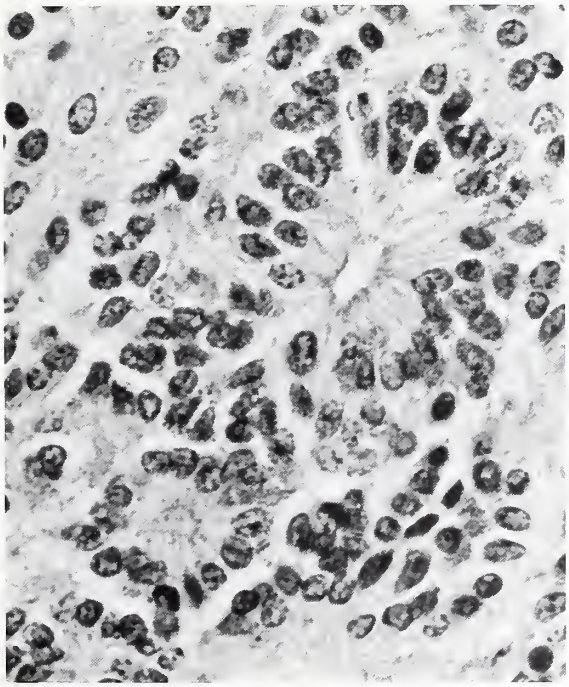

EPENDYMAL ROSETTES

(Figures 108, 111, 112, and 116 from same case)
Figure 111. These are typical ependymal rosettes with a small central lumen. PTAH. × 650.

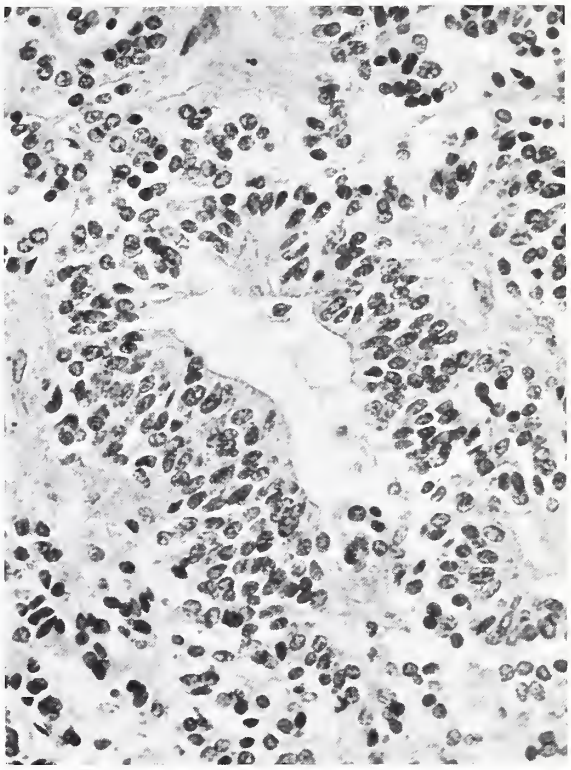

EPENDYMAL ROSETTES

(Figures 108, 111, 112, and 116 from same case)
Figure 112. This incomplete tubule in another area is lined by ependymal cells. PTAH. × 395.

appearance without any special architectural features (fig. 114), but the picture varies from field to field and the diagnostic rosettes may be disclosed in adjacent areas (fig. 115).

Special stains often demonstrate that the tumor cells are strongly fibrillated (fig. 115). In some cases this may be due to the admixture of astrocytic elements among the tumor cells, presumably a participation of the subependymal neuroglia in the neoplastic process. However, there is little doubt that many of the fibrillated cells like those demonstrated in figure 115 are actually ependymal, in view of their nuclear characteristics and the demonstration of blepharoplasts in their cytoplasm.

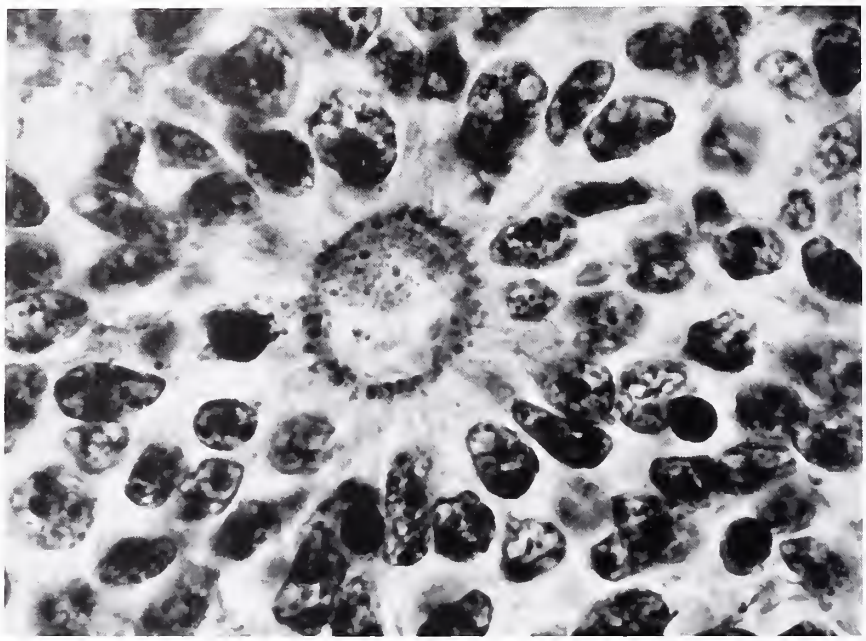

BLEPHAROPLASTS IN EPENDYMAL ROSETTE

(Figures 113, 134, and Plate V-A from same case)

Figure 113. Distinct granular blepharoplasts surround the lumen of an ependymal rosette; in this case, the blepharoplasts were argentophilic. This is from a case of medulloepithelioma that showed ependymomatous differentiation in places. Bielschowsky silver stain. × 1500. (Fig. 7 from Deck, J. H. N. Cerebral medulloepithelioma with maturation into ependymal cells and ganglion cells. J. Neuropath. Exp. Neurol. 28:442–454, 1969).

CELLULAR EPENDYMOMA

(Figures 114, 115, 222, 223, 312, 314, and Plate VI-B from same case)

Figure 114. This cellular, relatively compact intramedullary tumor is one of several ependymomas in a 17-year-old girl with central neurofibromatosis. × 240.

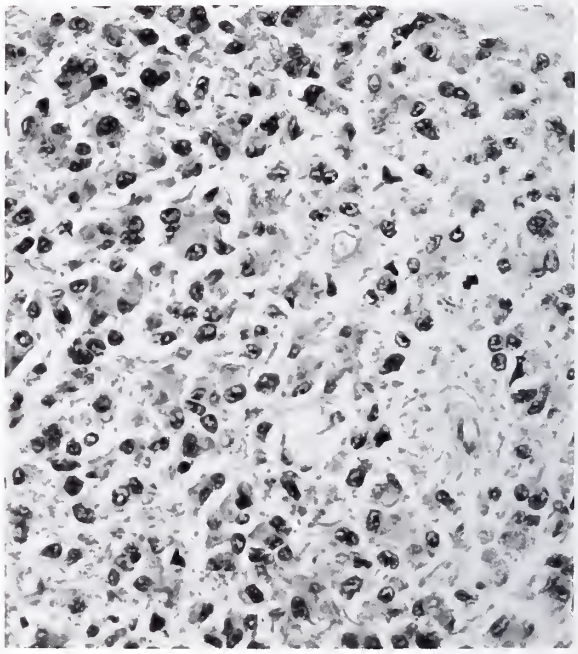

Fig. 114

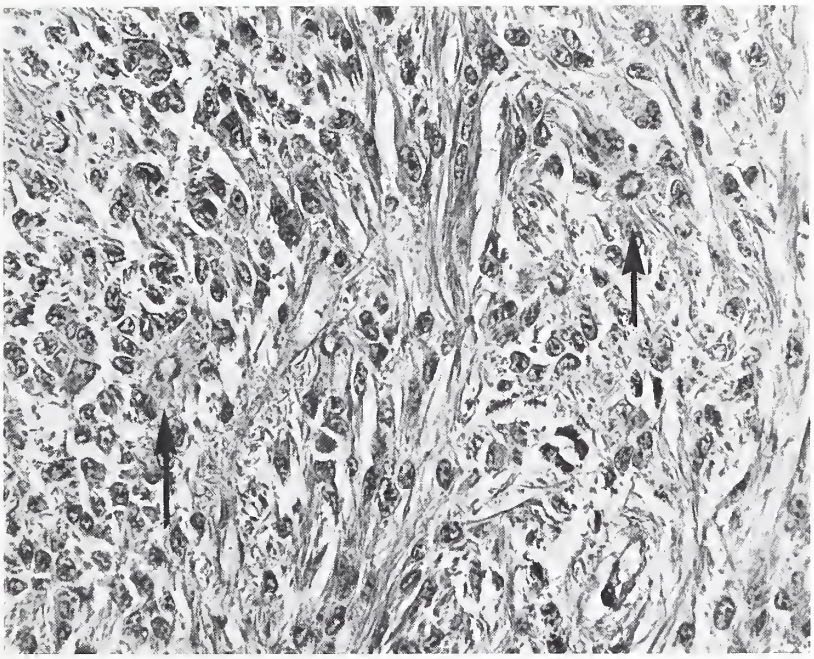

FIBRILLATED EPENDYMAL CELLS IN EPENDYMOMA

(Figures 114, 115, 222, 223, 312, 314, and Plate VI-B from same case)

Figure 115. The tumor cells from an adjacent area show prominent fibrillated processes and neuroglial fibrils. Note two distinct ependymal rosettes (arrows). PTAH. × 360. (Fig. 28 from Rubinstein, L. J. Seminario de Neuropatologia, Mérida, Yucatán, Bol. Asoc. Mex. Patol., A. C. 7:13–59, 1969).

Another characteristic feature of ependymomas is the formation of **perivascular pseudorosettes** (fig. 116). The blood vessels are surrounded by the radiating tapering processes of the tumor cells, which are oriented toward the vessel wall. This architecture is best demonstrated in smears obtained at surgery (pl. IV-E). The arrangement resembles that seen in astroblastomas, but the ependymomas do not have actual footplates on the vessel walls. Pseudorosette formation may be the only feature in biopsy specimens of ependymomas, but in some cases the areas showing perivascular pseudorosettes may be adjacent to those displaying typical ependymal rosettes (figs. 108, 111, 112, 116). It must be admitted that, in general, perivascular pseudorosettes are a more common feature in ependymomas than ependymal rosettes, and that the search for cilia and blepharoplasts is often unrewarded. An inability to demonstrate them should therefore not preclude the diagnosis.

An architectural variant of the ependymoma, uncommon in my experience, results from the formation of **papillary** structures, in which the cells, sometimes arranged in multiple layers, form a delicate arrangement of papillae and tubules (fig. 117).

The presence of **cartilage** has occasionally been reported in otherwise typical ependymomas or mixed astrocytomas and ependymomas originating in the fourth ventricle (Siqueira and Bucy). The cartilaginous transformation does not appear to be due to a metaplasia of the mesodermal stroma. The explanation for this curious phenomenon is not clear.

PERIVASCULAR PSEUDOROSETTES IN EPENDYMOMA

(Figures 108, 111, 112, and 116 from same case)

Figure 116. The perivascular arrangement of delicately fibrillated cells results in pseudorosette formation. PTAH. × 175.

PAPILLARY EPENDYMOMA

Figure 117. This papillary and tubular ependymoma arose in the third ventricle. van Gieson. × 150.

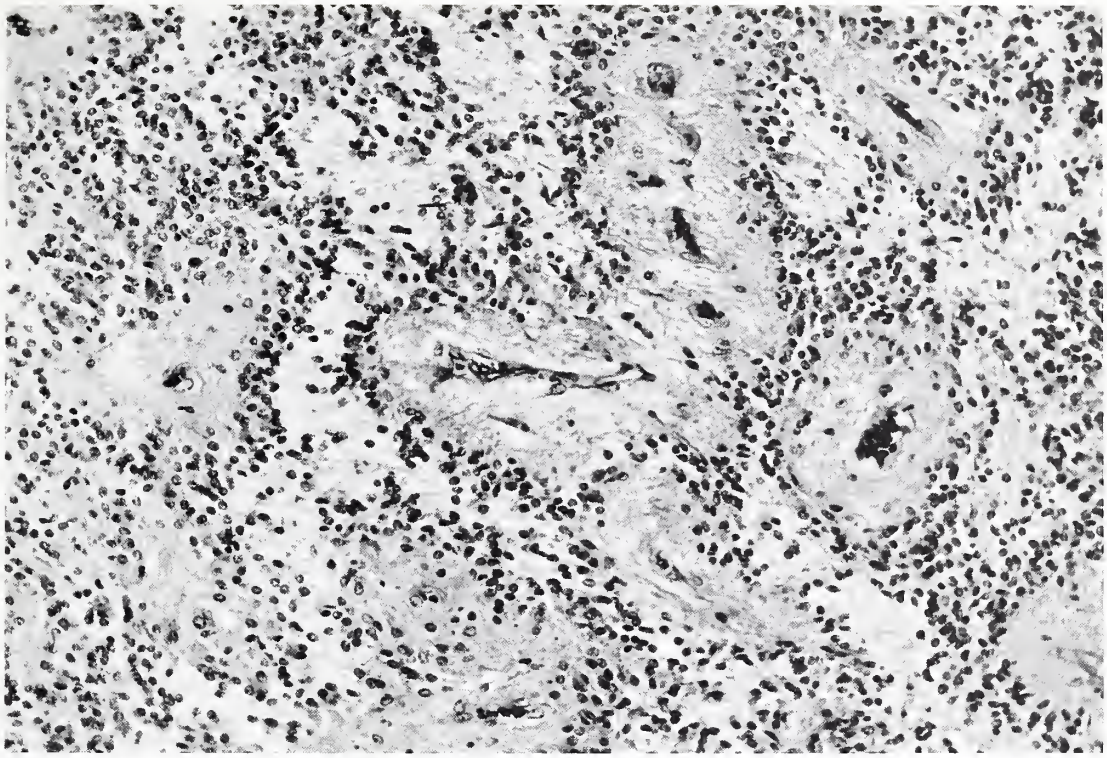

Fig. 116

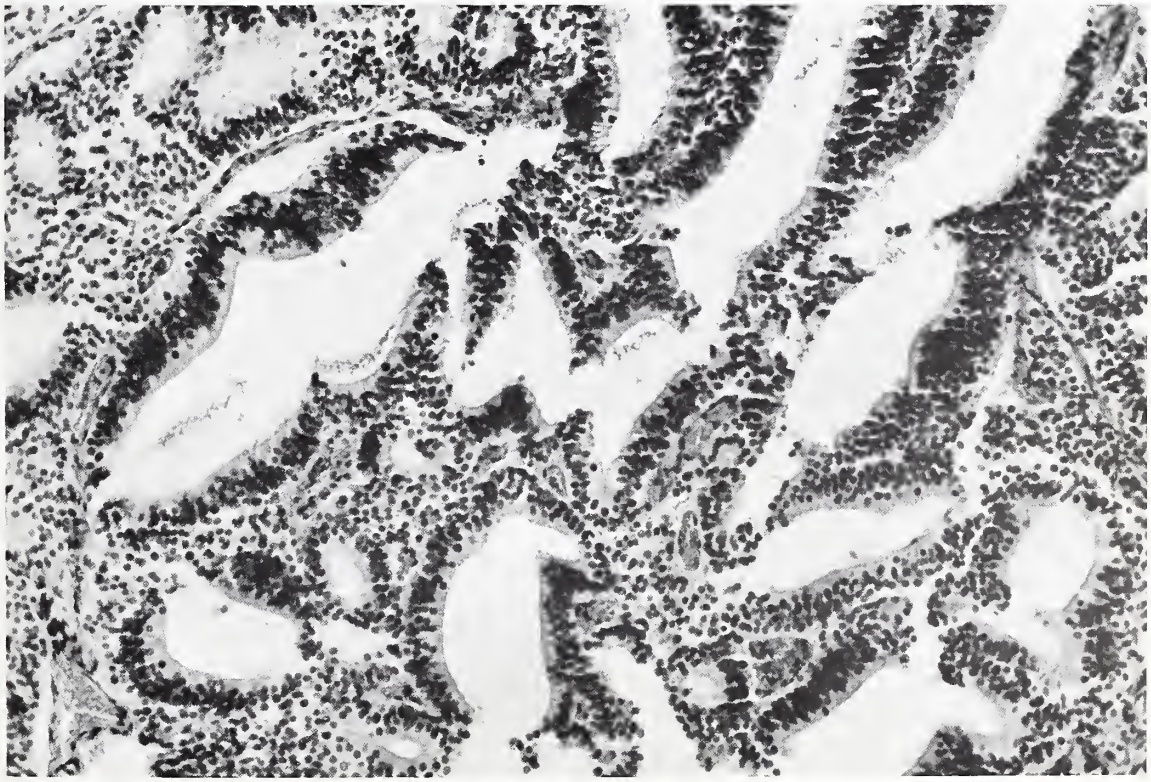

Fig. 117

VARIANTS

Subependymoma

SYNONYMS AND RELATED TERMS: Subependymal astrocytoma; subependymal glomerate astrocytoma.

This tumor is regarded in most cases as a variant of ependymoma. The reasons for this view are twofold: first, microscopic areas histologically identical with those found in subependymomas are not infrequently seen in otherwise classic ependymomas; second, many of the cells display the nuclear and cytoplasmic characteristics of ependymal cells. These tumors are unusually strongly fibrillated, a feature that may be due to a heavy admixture of subependymal neuroglial elements. There is no question, however, that occasionally small fibrillated subependymal tumors do arise that are composed entirely of astrocytes and have no ependymal elements.

The majority of subependymomas are found incidentally at necropsy in the fourth ventricle of middle-aged or elderly subjects. They have also been described as originating in the lateral ventricles (fig. 119) and in the cervical cord. They may be single or occasionally multiple (figs. 118, 119). Grossly they present as small, hard, lobulated, whitish nodules that may completely occupy the cavity of the fourth ventricle without producing internal hydrocephalus (fig. 118). These tumors presumably represent one of the most benign forms of glial neoplasm, in which growth may be assumed to have become arrested before causing symptoms referable to interruption of the flow of cerebrospinal fluid. It is not clear whether all should be regarded as primarily neoplastic or whether some are not in the nature of a malformation. Some may possibly be the result of a reactive proliferative process on the part of the ependymal and subependymal glia in view of (1) their morphologic resemblance to the ependymal granulations seen in chronic low grade inflammation, and (2) multiple ependymomas occupying the cavity and lateral recesses of the fourth ventricle that were associated with a chronic ependymitis due to a protracted cryptococcal leptomeningitis as shown in figure 118. Very occasionally the tumor grows to a larger size and gives rise to obstructive hydrocephalus, although its histologic pattern remains indistinguishable from the small incidentally discovered examples.

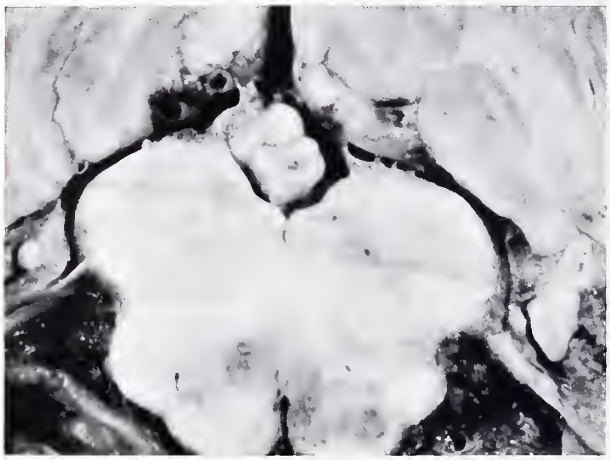

MULTIPLE SUBEPENDYMOMAS

Figure 118. Three discrete whitish subependymomatous nodules occupy the cavity and the lateral recesses of the fourth ventricle. This was an incidental postmortem finding in a 59-year-old man with chronic granular ependymitis associated with long-standing cryptococcal meningitis.

MICROSCOPIC. These tumors are often poorly cellular, with the cells forming small nests scattered in an acellular fibrillated matrix (fig. 120). The neuroglial nature of the fibers is well demonstrated with special stains (pl. IV-D). Under higher power small ependymal rosettes or perivascular pseudorosettes may be seen in a few areas,

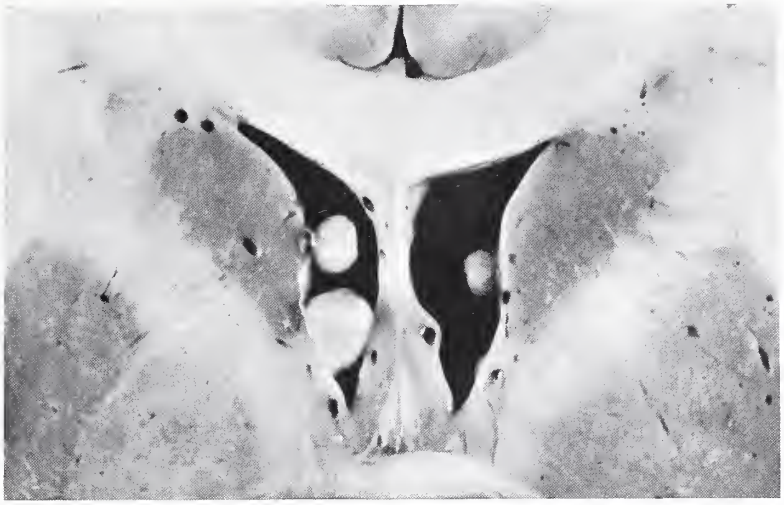

MULTIPLE SUBEPENDYMOMAS

(Figures 119 and 121 from same case)

Figure 119. Multiple nodules of subependymoma were found as an incidental finding along the walls of the lateral ventricles in a 54-year-old man.

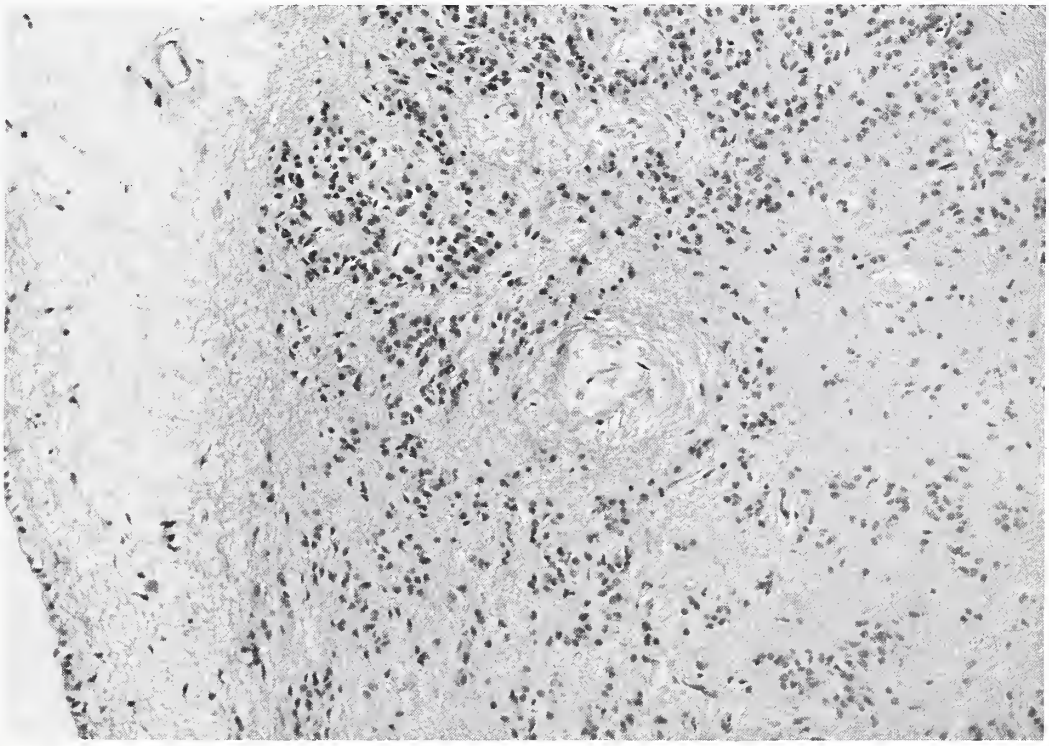

SUBEPENDYMOMA

Figure 120. This is an overall view of a highly fibrillated subependymoma found incidentally in the fourth ventricle of an 82-year-old woman. The ependymal lining is on the left. × 180.

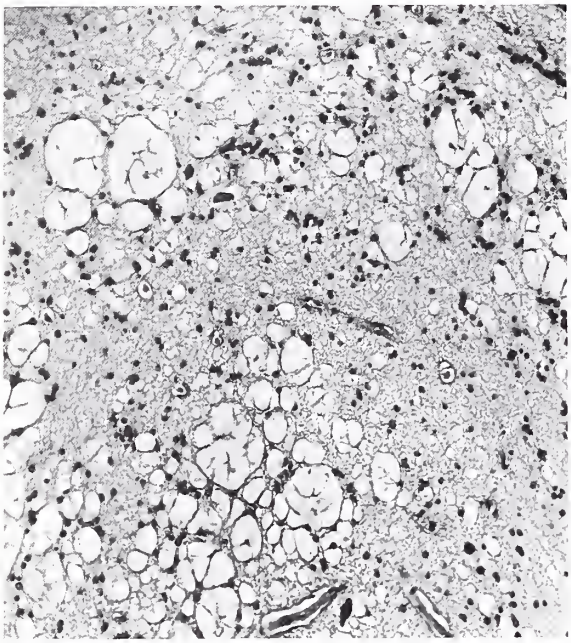

SUBEPENDYMOMA

(Figures 119 and 121 from same case)

Figure 121. This shows the microcystic architecture of a highly fibrillated subependymoma, one of four such nodules disclosed as incidental findings along the walls of the lateral ventricles of a 54-year-old man. × 108.

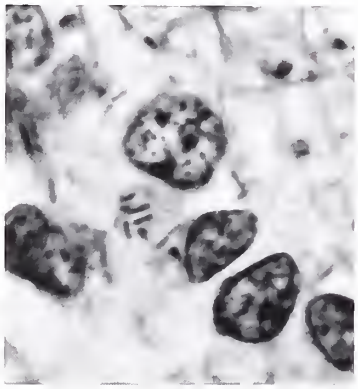

SUBEPENDYMOMA
BLEPHAROPLASTS

(Figure 122 and Plate IV-D from same case)

Figure 122. Five small rod-shaped blepharoplasts are present in the cytoplasm between three ependymal nuclei. PTAH. × 1300.

but often the tumor cells have no special orientation. Not infrequently special stains will demonstrate the presence of blepharoplasts (fig. 122), a feature which supports the view that most subependymomas are variants of the ependymoma. Occasionally the histologic architecture of the subependymoma shows a loose texture, with the formation of microcysts (fig. 121).

Myxopapillary Ependymoma of the Filum Terminale

Ependymomas account for the overwhelming majority of gliomas arising in the region of the conus medullaris and filum terminale. They appear to form a distinct clinicopathologic variant, associated with a classic and easily recognizable histologic picture. The name of myxopapillary ependymoma, originally applied by Kernohan (1932) to this group, seems therefore appropriate since they appear to occur exclusively in that region. It must, however, be admitted that some papillary examples do not show the mucinous degeneration of the connective tissue stroma that is so characteristic of these neoplasms.

These tumors may occur at any age, but a distinct majority occur in the fourth decade of life. The microscopic structure frequently recalls that seen in the normal filum terminale (fig. 123). The myxopapillary tumors are composed of well defined cuboidal or low columnar cells, often with a clear cytoplasm, arranged in a papillary fashion around a central core of hyaline acellular connective tissue that is rich in blood vessels (fig. 124). Mucinous degeneration, positive with mucicarmine and PAS, is a frequent feature in the connective tissue of these tumors, but may also be evident in the tumor cells themselves; in this case, it is possible that some of the tumor cells are

oligodendroglial, since other elements besides ependymal cells are normally present in the filum terminale. The intensely vascular connective tissue stroma again recalls the normal structure of the filum terminale in which the connective tissue is a continuation of the pia. The tumors are often highly vascular and hemorrhagic, may present microscopically a telangiectatic appearance, and may give rise to spontaneous subarachnoid bleeding. The papillary ependymomas of the filum terminale, whether myxomatous or not, grow slowly and may occasionally form tumors of considerable size that deform and erode the adjacent sacrum. They may extend massively into the extravertebral soft tissues and have occasionally developed extraneural metastases (p. 123).

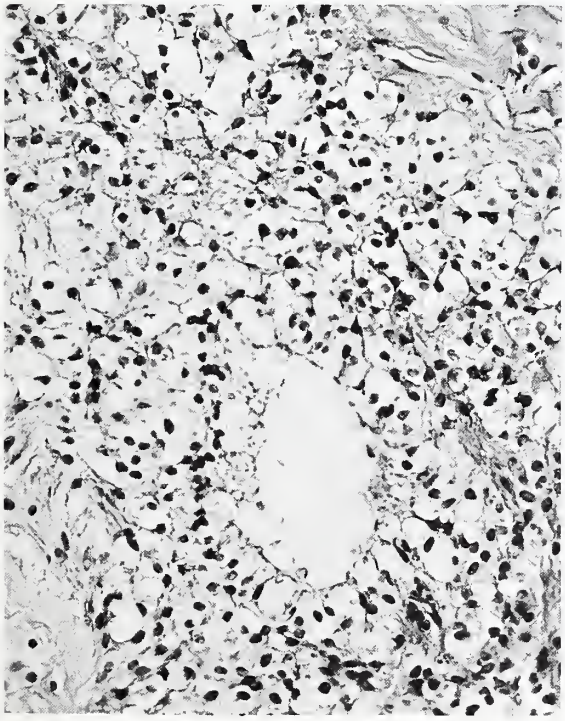

NORMAL FILUM TERMINALE

Figure 123. This is the microscopic appearance of the normal filum terminale for comparison with figure 124. × 265.

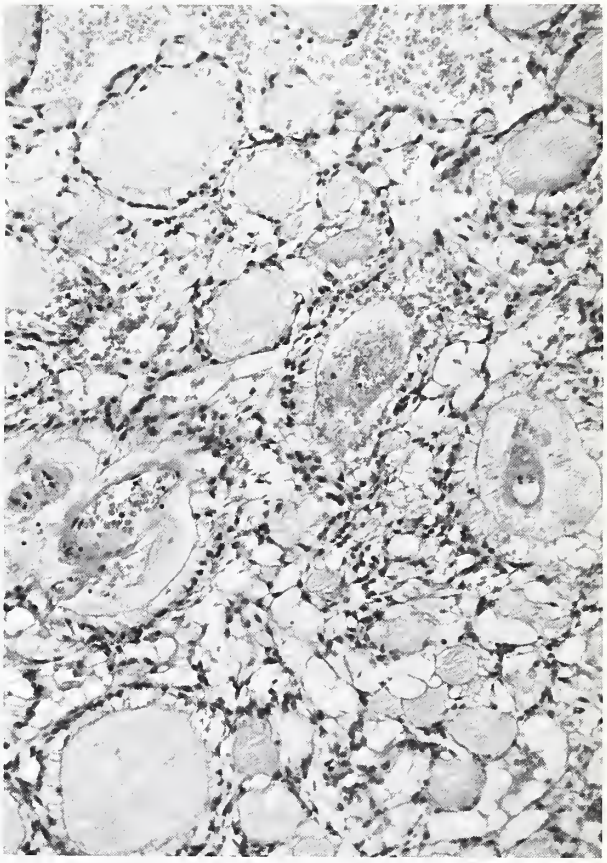

MYXOPAPILLARY EPENDYMOMA OF FILUM TERMINALE

Figure 124. Note the resemblance of the microscopic appearance of this myxopapillary ependymoma of the filum terminale in a 32-year-old man to the normal filum terminale in the preceding figure. × 135.

Malignant Ependymomas. Ependymoblastoma.

In most cases recurrence of an ependymoma is not accompanied by an increase in cytologic malignant characteristics. Occasionally, however, ependymomas may show malignant features, including invasive properties, foci of necrosis, and the appearance of cytologic anaplasia such as increased cellularity, mitotic figures, multinucleation, and giant cell formation. In these cases the

process is essentially a progressive dedifferentiation with the ultimate anaplastic histologic picture reminiscent of a glioblastoma multiforme. A few such examples have been noted, usually arising in the cerebral hemispheres of adults and associated clinically with rapid recurrence after removal. Such an event is rare (Fokes and Earle). These examples should properly be designated malignant ependymomas.

A taxonomic problem arises from the frequent use of the term "ependymoblastoma" as a synonym for the anaplastic form of ependymoma just described. It has long been apparent that the concept of the ependymoblastoma is a nebulous one, and the existence of a tumor entity of that name has been widely questioned, in man at least. It should be recalled that in the original classification of Bailey and Cushing the term ependymoblastoma was used primarily to describe a histologic variant of the benign ependymoma composed of fibrillated cells with tails directed toward the blood vessels, termed "ependymal spongioblasts." This distinction did not imply any marked divergences in cytologic malignancy or biologic behavior, and later review led Bailey and Cushing to discard this separation and therefore the designation of ependymoblastoma. Subsequently the term was adopted as a synonym for malignant ependymoma in the meaning outlined in the preceding paragraph, and without any clear definition of what constituted an "ependymoblast."

Whether the ependymoblastoma as a separate entity has any substance at all must depend on the demonstration of tumors which, while belonging to the ependymal group of neoplasms, are devoid of those features that align them with the glioblastomas, but present a uniform and distinctive histologic appearance in which primitive cell elements predominate. Examples of this type would be expected to arise in very early life. Figure 125 illustrates the gross appearance of a residual fourth ventricle tumor that invaded the vermis and cerebellar hemisphere in a 22-month-old child. The tumor shows uniform cytologic features with a characteristic pattern of thick, darkly staining, anastomosing cords and festoons

MALIGNANT EPENDYMOMA
(EPENDYMOBLASTOMA)

(Figures 125–127 from same case)

Figure 125. This ill-defined granular residual ependymoma in the caudal part of the fourth ventricle invades the cerebellar hemisphere. This malignant tumor in a 22-month-old boy metastasized widely through the cerebrospinal leptomeninges. (Fig. 8 from Rubinstein, L. J. The definition of the ependymoblastoma. Arch. Path. 90:35–45, 1970).

of glial cells forming a rather loose arrangement around the blood vessels (fig. 127). Mitotic figures are numerous. In many places distinct ependymal rosettes are present (fig. 127, inset). The tumor had widely metastasized throughout the cerebrospinal leptomeninges and reinvaded the brain and the spinal cord extensively (fig. 126). Many of the cells are of primitive type, some being faintly polar and recalling spongioblasts.

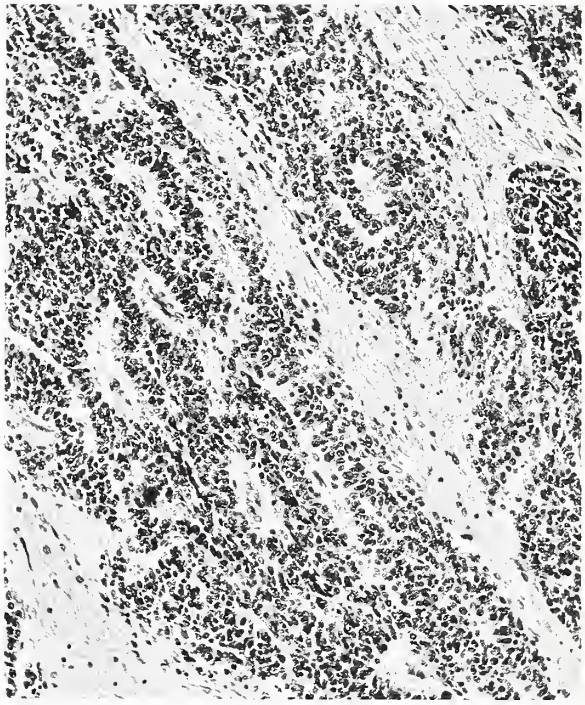

MALIGNANT EPENDYMOMA
(EPENDYMOBLASTOMA)

(Figures 125–127 from same case)

Figure 126. Metastatic tumor extensively infiltrates the spinal cord consequent to widespread subarachnoid spread. × 100. (Fig. 11 from Rubinstein, L. J. The definition of the ependymoblastoma. Arch. Path. 90:35–45, 1970).

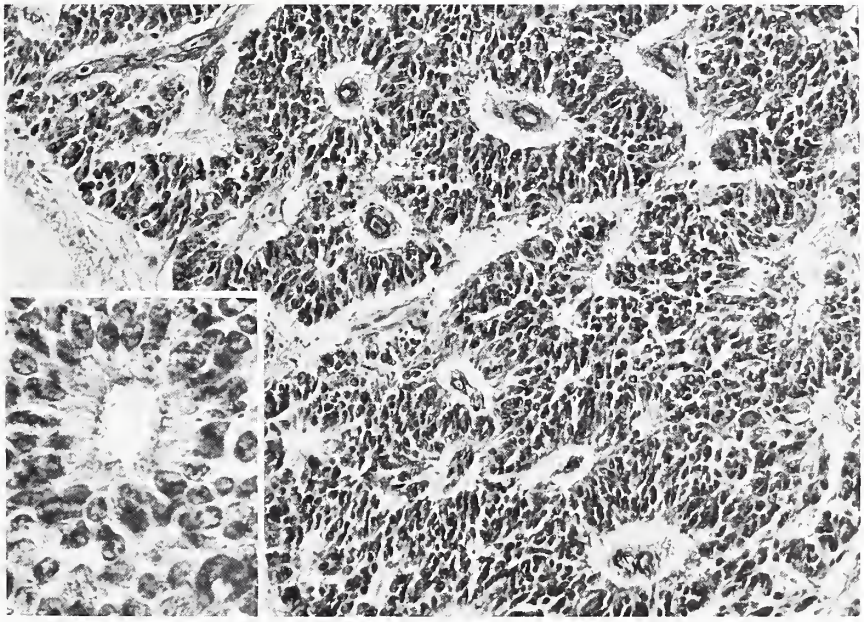

MALIGNANT EPENDYMOMA (EPENDYMOBLASTOMA)

(Figures 125–127 from same case)

Figure 127. In this area the tumor is composed of solid cords of closely packed darkly staining cells with central cores of thin-walled blood vessels. This field is taken from an area in the leptomeninges. PTAH. × 175. Inset: Distinct ependymal rosette with central lumen taken from another area of tumor in the subarachnoid spread. PTAH. × 500. (Fig. 10 from Rubinstein, L. J. The definition of the ependymoblastoma. Arch. Path. 90:35–45, 1970).

In another malignant example arising in the cerebral hemisphere of a 22-month-old infant (fig. 128), the rosettes (fig. 129) were surrounded by several layers of cells that included mitotic figures reminiscent of a retinal neuroepithelioma. It would seem therefore that a very rare type of primitive ependymal tumor may exist, characterized mostly by embryonal cell forms, but showing ependymomatous differentiation in places. Its biologic behavior corresponds to its primitive cytologic appearance. It is highly malignant clinically, with a tendency to local invasion, recurrence, and diffuse spread. A more detailed analysis and a redefinition of the term ependymoblastoma have been given elsewhere on the basis of these two neoplasms (Rubinstein), and two further identical examples, one of them congenital, have since been reviewed from outside sources.

MALIGNANT EPENDYMOMA
(EPENDYMOBLASTOMA)

(Figures 128 and 129 from same case)

Figure 128. A malignant frontoparietal tumor that was separate from the ventricle and arose in a 22-month-old infant is shown invading the surrounding brain. Note the dense cellularity and the ependymomatous tubule (right lower corner). See detail of rosette in figure 129. × 90. (Fig. 2 from Rubinstein, L. J. The definition of the ependymoblastoma. Arch. Path. 90:35–45, 1970).

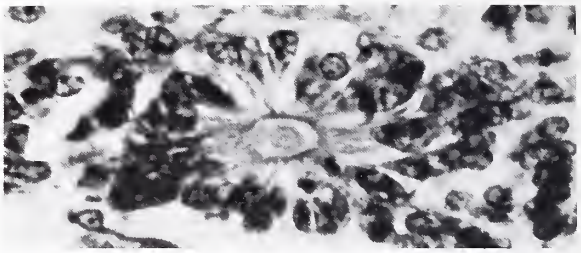

ROSETTE IN MALIGNANT
EPENDYMOMA
(EPENDYMOBLASTOMA)

(Figures 128 and 129 from same case)

Figure 129. This rosette encircles a lumen and consists of several layers of cells, some containing mitotic figures. Note the resemblance to the rosettes found in neuroepithelioma of the retina. × 600. (Fig. 5 from Rubinstein, L. J. The definition of the ependymoblastoma. Arch. Path. 90:35–45, 1970).

The great majority of ependymomas are therefore benign gliomas that should be designated grade 1. The variants designated as subependymoma and myxopapillary ependymoma similarly merit this low grading on the basis of their cytologic appearance, although eventual slow growth of a myxopapillary ependymoma of the filum terminale may give rise to extraneural metastases (p. 123). The more malignant forms of ependymoma, whether dedifferentiating toward glioblastoma or the rare primitive forms tentatively designated as ependymoblastomas, show obvious cellular and histologic evidence of malignant and aggressive growth. The rarity of these cases suggests that little additional information

would be gained by adopting a system of grading for these exceptional examples. No correlation could be made by Fokes and Earle between cytologic grading and survival time.

METASTATIC SPREAD. Aside from the exceptional example of primitive ependymoma (ependymoblastoma) quoted above, metastatic spread in the subarachnoid space of otherwise histologically benign ependymomas has been described. Despite the intraventricular situation of the tumor, it is a relatively rare event, and only exceptionally significant enough to cause clinical symptoms. Most instances of leptomeningeal dissemination are incidental microscopic findings at postmortem examination. The incidence of cerebrospinal metastases in ependymomas appears to have been exaggerated in some series, because of the inclusion, among the ependymomas, of medulloblastomas showing characteristic Homer Wright rosettes (see Differential Diagnosis, p. 125).

Extraneural metastases from both cranial and spinal ependymomas have been well documented in a few cases. Most have been slowly growing, recurring neoplasms in which extraneural spread followed the encroachment by tumor on the adjacent extracranial and extravertebral soft tissues, usually without histologic evidence of increased malignancy. Metastases have generally been reported in the regional lymph nodes and the lungs (Glasauer and Yuan).

Examples of metastasizing myxopapillary and papillary ependymoma of the cauda equina have been reported respectively by Weiss and by Patterson and his associates. These were cases that recurred on two or more occasions after initial operation, and in which metastases developed 10 and 17 years respectively after the onset of the illness. Figure 131 illustrates the microscopic appearance of a pulmonary metastasis from a papillary ependymoma (fig. 130) that arose in the lower part of the spinal canal and had caused extensive destruction of the sacrum, ilium, and lower ribs. The tumor had infiltrated the adjacent soft tissues and permeated the common iliac veins and the inferior vena cava. Metastatic foci were also found in one large abdominal lymph node. This case is of

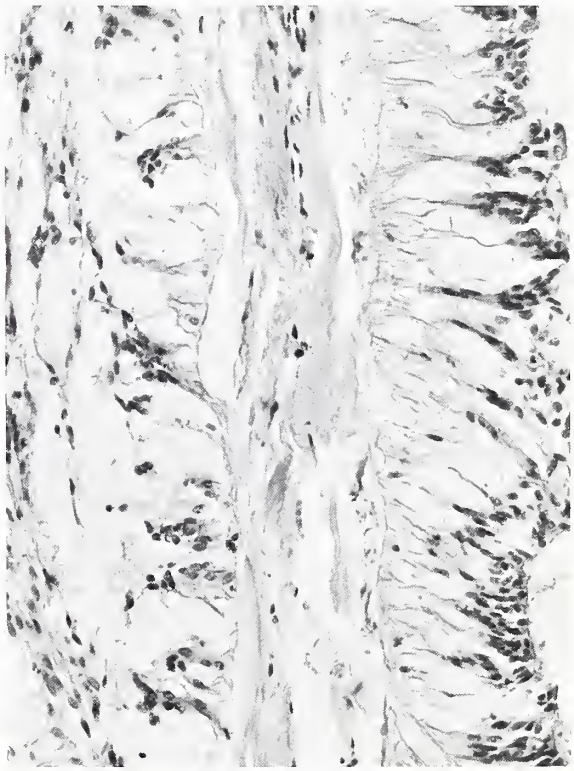

EPENDYMOMA OF CAUDA EQUINA
EXTRANEURAL METASTASES

(Figures 130 and 131 from same case)

Figure 130. This papillary ependymoma arose in the lower part of the spinal canal in a woman aged 46 at death. The tumor, after extensively eroding the sacrum and the ilium, ultimately metastasized to an abdominal lymph node and to the lungs. This complication supervened upon a clinical history of 29 years (see text). × 190.

special interest in that the illness, in this woman aged 46 years at death, extended for a total length of 29 years (Rubinstein and Logan).

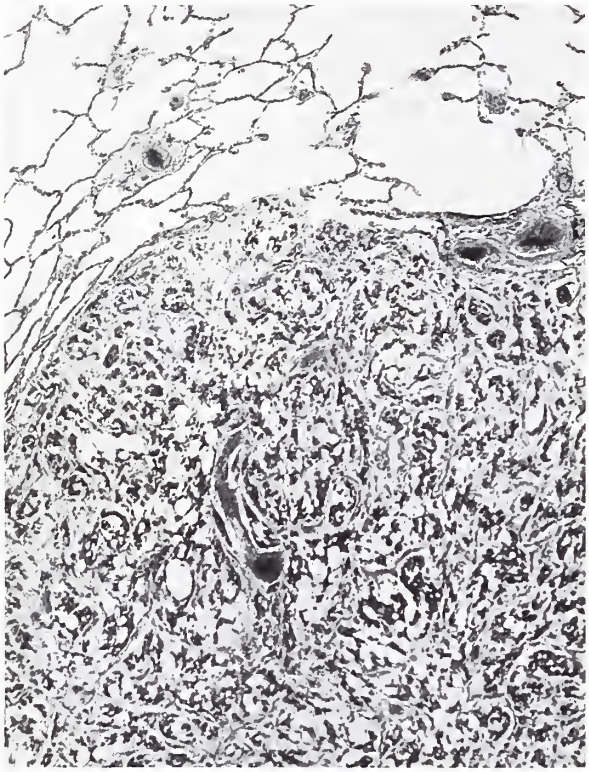

EPENDYMOMA OF CAUDA EQUINA
EXTRANEURAL METASTASES

(Figures 130 and 131 from same case)

Figure 131. A low power view shows a metastatic focus of ependymoma in the lung. × 48. (Fig. 5 from Rubinstein, L. J., and Logan, W. J. Extraneural metastases in ependymoma of the cauda equina. J. Neurol. Neurosurg. Psychiat. 33:763-770, 1970).

TREATMENT. The method of treatment is as radical surgical removal as possible. Unfortunately in fourth ventricle ependymomas, secondary attachment to, or origin from, the floor of the medulla all too often make total removal impossible. Local radiotherapy is usually given as a postoperative measure (Schulz et al.). The series of Fokes and Earle indicates a longer postoperative survival rate for patients with posterior fossa tumor who have had combined surgery and postoperative radiation than for those treated by surgery alone. The figures referable to supratentorial examples are too small to be significant. There is no justification in benign ependymomas for the administration of radiotherapy throughout the entire neuraxis. Only in those exceptional cases in which there is histologic evidence of malignancy is such a procedure indicated.

PROGNOSIS. The majority of ependymomas are benign; even partial removal may be followed by a long period of remission, and recurrence may be protracted. Unfortunately the localization of the tumor often makes surgical intervention very hazardous. Most early series reported a 5-year postoperative survival of only 25 percent. More recent series in which radiotherapy was combined with surgery give higher figures, ranging from 40 to 70 percent (Schulz et al.). In the series of Fokes and Earle the average survival of patients with posterior fossa tumors following operation and radiotherapy was 53 months, as opposed to 33 months following surgery alone.

In the spinal cord the average postoperative survival of patients with grades 1 and 2 ependymomas of the spinal cord was respectively 151 months and 111 months, according to Slooff and associates. The survival rate after five years was better than 50 percent for the grade 1 and 2 ependymomas. Their figures generally suggest that the ultimate prognosis is improved with the more extensive forms of treatment.

DIFFERENTIAL DIAGNOSIS. There is much confusion over the recognition of

ependymomas in surgical biopsies. Many cases of medulloblastoma are misinterpreted as ependymomas on the basis of the presence of Homer Wright rosettes. Figure 132 illustrates the essential differences between the various rosettes found in tumors of the nervous system. Part of the confusion arose because of the decision by Bailey and Cushing to designate as pseudorosettes all those cellular formations that did not surround a definite central lumen. The term rosette was therefore restricted to those originally described by Flexner in retinal neuroepitheliomas (or retinoblastomas), and to the ependymal rosettes found in ependymomas. The Homer Wright rosettes originally described in sympathicoblastomas are also found in medulloblastomas (p. 133). They do not surround a central lumen, but include faintly staining, tangled fibrillated material that occasionally has an affinity for silver preparations for neurofibrils. These formations, termed pseudorosettes by Bailey, are not germane to the ependymoma, and when discovered in a posterior fossa tumor identify it as a medulloblastoma.

The presence of perivascular pseudorosettes is common to both ependymomas and astroblastomas. The differential diagnosis may be difficult in the absence of typical ependymal rosettes; however, astroblastomas do not contain neuroglial fibrils, and their processes usually terminate either in a footplate or as an expanded portion of their cytoplasm. By contrast the perivascular formations in an ependymoma taper toward the blood vessel into a point.

Misinterpretation also exists in differentiating papillary ependymomas from choroid plexus papillomas. The difference lies in the nature of the stroma: in the

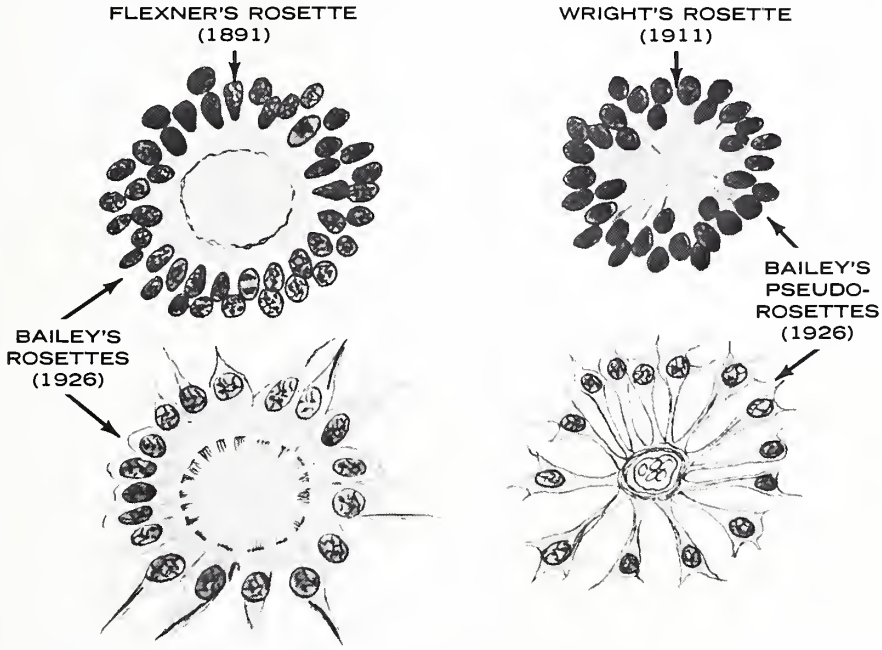

ROSETTES

Figure 132. This diagram illustrates the different types of rosettes found in tumors of the nervous system. (Courtesy of Professor Dorothy S. Russell, London, England; also fig. 10 from Russell, D. S. The pathology of intracranial tumours. Postgrad. Med. J. 26:109–125, 1950).

ependymoma, the supporting cells are neuroglial, while choroid plexus tumors have a characteristic vascular connective tissue stroma. Moreover the papillary formations in ependymomas often show stratification of the component cells, whereas the choroid plexus papillomas are covered by single thin, tall columnar cells. Choroid plexus tumors are often almost identical in architecture and cytologic features to normal choroid plexus, and except for a few infantile examples do not display cilia or blepharoplasts.

Finally, diagnostic confusion may occasionally arise in a small biopsy specimen between an ependymoma and the sinusoidal, or papillary form of chromophobe adenoma of the pituitary. The error is less likely to occur once the possibility springs to mind.

References

Bailey, P., and Cushing, H. A Classification of the Tumors of the Glioma Group on a Histogenetic Basis with a Correlated Study of Prognosis. Philadelphia: J. B. Lippincott Company, 1926.

Brightman, M. W., and Palay, S. L. The fine structure of ependyma in the brain of the rat. J. Cell Biol. 19:415–439, 1963.

Cooper, I. S., Craig, W. M., and Kernohan, J. W. Tumors of the spinal cord; primary extramedullary gliomas. Surg. Gynec. Obstet. 92:183–190, 1951.

Courville, C. B., and Broussalian, S. L. Plastic ependymomas of the lateral recess. Report of eight verified cases. J. Neurosurg. 18:792–799, 1961.

Flexner, S. A peculiar glioma (neuroepithelioma?) of the retina. Johns Hopkins Hosp. Bull. 2:115–119, 1891.

Fokes, E. C., Jr., and Earle, K. M. Ependymomas: clinical and pathological aspects. J. Neurosurg. 30: 585–594, 1969.

Glasauer, F. E., and Yuan, R. H. P. Intracranial tumors with extracranial metastases. J. Neurosurg. 20: 474–493, 1963.

Kernohan, J. W. Cytology and Cellular Pathology of the Nervous System, p. 993, Vol. 3. (Ed.) Penfield, W. New York: Paul B. Hoeber, Inc., 1932.

Patterson, R. H., Campbell, W. G., and Parsons, H. Ependymoma of the cauda equina with multiple visceral metastases. J. Neurosurg. 18:145–150, 1961.

Poser, C. M. The Relationship Between Syringomyelia and Neoplasm. Springfield, Ill.: Charles C Thomas, 1956.

Raimondi, A. J. Ultrastructure and the Biology of Human Brain Tumors, pp. 1–63. In: Progress in Neurological Surgery, Vol. 1. (Eds.) Krayenbühl, H., Maspes, P. E., and Sweet, W. H. Chicago: Year Book Medical Publishers, Inc., 1966.

Rubinstein, L. J. The definition of the ependymoblastoma. Arch. Path, 90:35–45, 1970.

———, and Logan, W. J. Extraneural metastases in ependymoma of the cauda equina. J. Neurol. Neurosurg. Psychiat., 33:763–770, 1970.

Russell, D. S., and Rubinstein, L. J. Pathology of Tumours of the Nervous System, 3d ed. London: Edward Arnold, 1971.

Schulz, M. D., Wang, C-C., Zinninger, G. F., and Tefft, M. Radiotherapy of Intracranial Neoplasms, pp. 318–370. In: Progress in Neurological Surgery, Vol. 2. (Eds.) Krayenbühl, H., Maspes, P. E., and Sweet, W. H. Chicago: Year Book Medical Publishers, Inc., 1968.

Siqueira, E. B., and Bucy, P. C. Chondroma arising within a mixed glioma. J. Neuropath. Exp. Neurol. 25:667–673, 1966.

Slooff, J. L., Kernohan, J. W., and MacCarthy, C. S. Primary Intramedullary Tumors of the Spinal Cord and Filum Terminale. Philadelphia: W. B. Saunders Company, 1964.

Weiss, L. A metastasizing ependymoma of the cauda equina. Cancer 8:161–171, 1955.

Wright, J. H. Neurocytoma or neuroblastoma, a kind of tumor not generally recognized. J. Exp. Med. 12:556–561, 1910.

Zülch, K. J., and Wechsler, W. Pathology and Classification of Gliomas, pp. 1–84. In: Progress in Neurological Surgery, Vol. 2. (Eds.) Krayenbühl, H., Maspes, P. E., and Sweet, W. H. Chicago: Year Book Medical Publishers, Inc., 1968.

TUMORS OF NEURONAL CELLS AND PRIMITIVE BIPOTENTIAL PRECURSORS

MEDULLOEPITHELIOMA

DEFINITION. This extremely rare tumor, apparently derived from the primitive medullary plate and neural tube, was originally classified by Bailey and Cushing as the most primitive of the neoplasms in the central nervous system. Although its existence was subsequently questioned on the basis of a reclassification of some of the older recorded examples, the detailed description in later years of a small number of authentic cases following Treip's report now leaves little doubt as to the definition of this tumor as a distinct nosologic entity which fulfills the criteria initially laid down by Bailey and Cushing.

CYTOGENESIS. All the recently reported examples conform in their cardinal features to Treip's original case, in that they possess an instantly recognizable histologic pattern that recalls the primitive medullary epithelium, to be described. Moreover some of these tumors display differentiating potentialities that are fully in accord with the concept of the medulloepithelioma as the most primitive and multipotential neoplasm in neuro-oncology. It is therefore a truly embryonic tumor.

CLINICAL DATA. As expected, all the authentic examples reported so far have occurred in early life, ranging from the probably congenital case of Treip to the age of five. Clinically the presentation is that of a rapidly growing intracranial neoplasm. The usual site has been the cerebral hemispheres, often in or near the ventricles. Treip's case was located in the midline and extended forward from the midbrain. Occasionally the tumor is clearly separate from the ventricular cavity (pl. V-A). One example has been reported as arising from the cauda equina.

GROSS. The tumor is usually sharply demarcated, with grayish pink, soft friable, highly necrotic and hemorrhagic cut surfaces (pl. V-A).

MICROSCOPIC. The histologic picture is distinctive. Under low power the pattern is that of a very papillary and tubular arrangement of medium or tall columnar cells that recalls the structure of the primitive medullary epithelium (fig. 133). Under high power the columnar cells form bands which have a well defined internal, or luminal, limiting membrane, and a similarly sharply defined external limiting membrane that rests on a delicate vascular connective tissue stroma (fig. 134). The columnar cells have large oval vesiculated nuclei, and may either be arranged in single layers or show pseudostratification (fig. 134). Mitotic figures are often numerous, but are usually confined to those nuclei closely apposed to the internal limiting membrane. Neither cilia nor blepharoplasts can be demonstrated. This is in accord with the cellular characteristics of the columnar epithelium of the primitive medullary plate and neural tube. In places the tubular and papillary areas may merge into solid cellular undifferentiated zones composed of similar cells that lack any special architectural feature. In some cases, as in the example reported by Fowler, the connective tissue stroma may be particularly abundant.

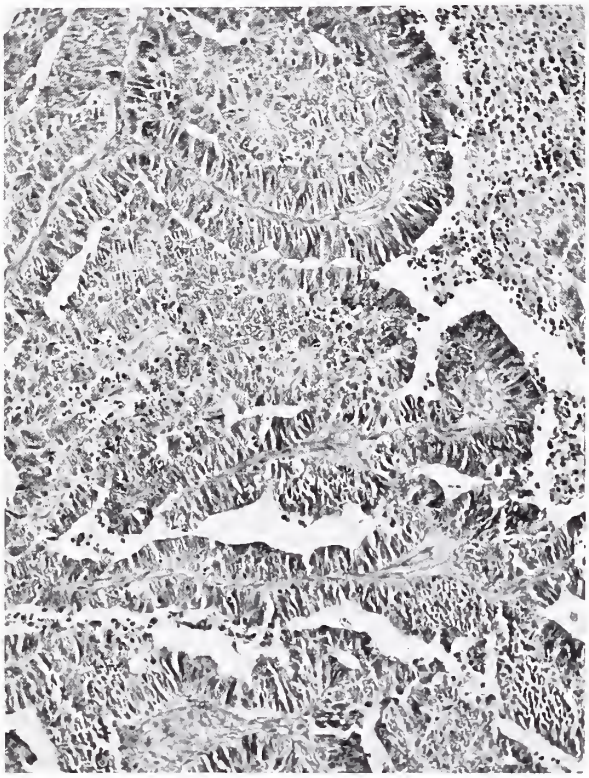

MEDULLOEPITHELIOMA

Figure 133. This low power view of a right temporal medulloepithelioma in a 5-year-old boy shows a marked papillary and tubular architecture. × 100.

MEDULLOEPITHELIOMA

(Figures 113, 134, and Plate V-A from same case)

Figure 134. This high power view of a right parietal medulloepithelioma in a 16-month-old girl reveals tall columnar epithelium showing distinct internal and external limiting membranes. The epithelium rests on a delicate vascular connective tissue stroma. Note mitotic figure in upper left. × 600. (Fig. 4 from Deck, J. H. N. Cerebral medulloepithelioma with maturation into ependymal cells and ganglion cells. J. Neuropath. Exp. Neurol. 28:442–454, 1969).

Most of these primitive tumors show no evidence of cellular maturation, although a number of cells in Treip's case demonstrated neuroblastic differentiation with specific silver impregnations. More advanced **maturation** toward fully formed ganglion cells on the one hand, and well differentiated ependymomatous areas on the other, was seen in the case described in detail by Deck (fig. 134; pl. V-A). Two further divergent lines of maturation, toward astrocytoma and mature ependymoma, have also been described in a tumor reported by Fowler under the designation of embryonic ependymoma. From a personal examination of the sections through the courtesy of Dr. Fowler, I am convinced that it represents a further example of differentiating

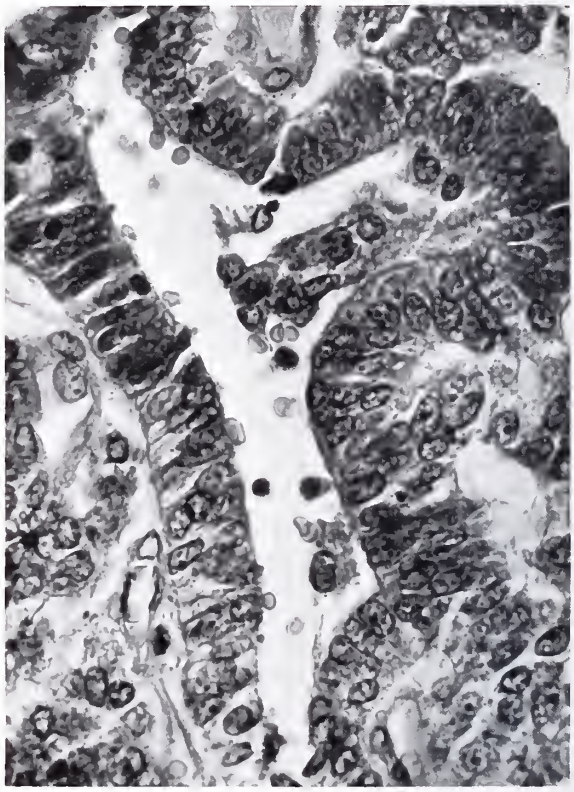

Fig. 134

medulloepithelioma. A detailed discussion of this tumor as a nosologic entity and of its differentiating capabilities in the light of recent autoradiographic and electron microscopic studies of the cytogenesis of the central nervous system is found in Deck's report.

METASTASIS. The biologic behavior of the medulloepithelioma conforms to its primitive histologic character. Recurrences have been reported. In the case of Van Epps and associates, metastatic spread had occurred in the cerebrospinal leptomeninges, and extraneural metastases had developed in the regional cervical lymph nodes following the appearance of several tumor nodules in the craniotomy scar six months after surgery.

TREATMENT. The highly primitive and malignant character of this tumor would counsel radical surgical removal followed by extensive radiation throughout the entire neuraxis.

DIFFERENTIAL DIAGNOSIS. Usually the histologic picture is immediately recognizable. There should be no confusion between this tumor and an ependymoma; cilia and blepharoplasts are present in the latter, and the pattern of ependymal rosettes is distinctive. It is possible that confusion may arise between the medulloepithelioma and some of the more undifferentiated ependymomas referred to above as possibly ependymoblastomas: both are primitive neoplasms, but the appearance of ependymomatous rosettes is again quite distinctive. It must, however, be recalled that at least two of the medulloepitheliomas recorded so far showed ependymomatous differentiation.

Because of the morphologic resemblance of the medulloepithelioma to a well differentiated papillary and tubular columnar-cell adenocarcinoma, any case interpreted as medulloepithelioma in an adult must be open to serious question. In examples originating in the ventricles of children, confusion may also arise with the rare malignant choroid plexus papilloma, or carcinoma. The differential diagnosis may be extremely difficult in this regard, and it can be resolved only by the finding of well differentiated zones of choroid plexus papilloma and of areas of transition to the more malignant portions.

Dispute has also arisen in distinguishing the medulloepithelioma from a teratoma containing neuroepithelial elements (Russell, 1960). In suspected examples containing abundant connective tissue, a special stain such as phosphotungstic acid hematoxylin should be used in order to exclude the presence of striated muscle fibers; the latter would establish the teratomatous nature of the tumor. Finally, the recent recognition among the pineal teratomas of an embryonal type of carcinoma (see Pineal Tumors, p. 276) must also be considered in the differential diagnosis of medulloepithelioma.

References

Bailey, P., and Cushing, H. A Classification of the Tumors of the Glioma Group on a Histogenetic Basis with a Correlated Study of Prognosis. Philadelphia: J. B. Lippincott Company, 1926.

Deck, J. H. N. Cerebral medulloepithelioma with maturation into ependymal cells and ganglion cells. J. Neuropath. Exp. Neurol. 28:442–454, 1969.

Fowler, M. Embryonic ependymoma arising in a cerebral hemisphere. Cancer 21:1150–1156, 1968.

Russell, D. S. A note on cerebral medullo-epitheliomas. J. Path. Bact. 79:403–404, 1960.

Treip, C. S. A congenital medulloepithelioma of the midbrain. J. Path. Bact. 74:357–363, 1957.

Van Epps, R. R., Samuelson, D. R., and McCormick, W. F. Cerebral medulloepithelioma. Case report. J. Neurosurg. 27:568–573, 1967.

MEDULLOBLASTOMAS

DEFINITION AND CYTOGENESIS. The cerebellar medulloblastoma as originally defined by Bailey and Cushing is by general agreement an embryonic tumor. Its cells are largely primitive or poorly differentiated. Its origin is, however, still a matter of speculation, and its differentiating capability one of dispute. As a cell type in embryogenesis the medulloblast postulated by Bailey and Cushing has never been identified. One favored theory advanced by Stevenson and Echlin is that the medulloblastoma is derived from remnants of the fetal **external granular layer**, which normally persists in the infant cerebellum until the end of the first year of life (fig. 135). With metallic impregnation methods, Kershman demonstrated the inward migration of the cells that constitute this layer to form the majority of the neurons in the internal granular layer; divergent differentiation into neuroglia was also postulated by Kershman and has more recently been confirmed in autoradiographic studies on the external granular layer of the mouse (Fujita). The subpial tumor cell aggregates illustrated by Stevenson and Echlin in their cases as morphologic evidence for their hypothesis could admittedly equally indicate the surface zones of preferential tumor origin or spread that have been identified with the secondary structures of Scherer (pp. 11, 12),

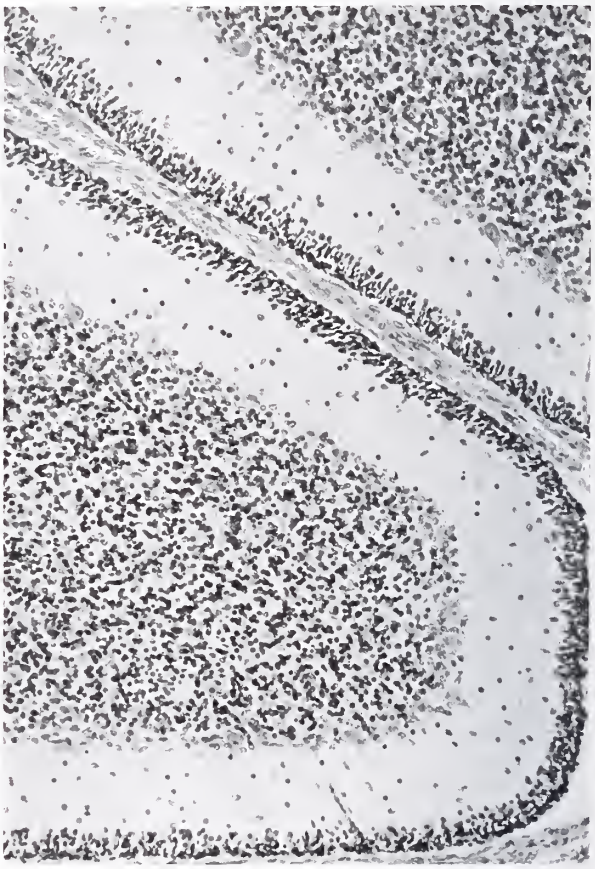

Fig. 135

FETAL EXTERNAL GRANULAR LAYER

(Figures 135, 136, and 157 from same case)

Figure 135. This normal external granular layer approximately 30 micra thick was present in the cerebellar cortex of a 13-week-old infant born two months prematurely. The patient had a cerebellar medulloblastoma, probably congenital. × 110. (Fig. 5 from Kadin, M. E., Rubinstein, L. J., and Nelson, J. S. Neonatal cerebellar medulloblastoma originating from the fetal external granular layer. J. Neuropath. Exp. Neurol. 29:583–600, 1970).

but recent examination of a presumed congenital medulloblastoma in a premature infant has strengthened Stevenson and Echlin's theory. Figure 136 shows, in the cerebellar cortex of this case, an extensive and irregular proliferation of the external granular layer throughout the major portion of the molecular layer. This was adjacent to a midline tumor illustrated in figure 157. The reader is referred to the report by Kadin and associates for further details on this case.

Other postulated sites of origin for cerebellar medulloblastomas include remnants of cell nests in the **posterior medullary velum** (Raaf and Kernohan), thus accounting for the midline examples, and possibly the **anterior medullary velum** (Ringertz and Tola). Recent autoradiographic studies have reconciled these various theories in demonstrating that primitive cells originating in the neuroepithelial roof of the fourth ventricle migrate upward and laterally to form the external granular layer. Assuming an origin of the medulloblastoma from these germinative cells anywhere along their migratory path, it would be reasonable to expect that the majority of the midline examples would occur in earlier age groups, while the laterally situated tumors would more frequently be harbored by adults. In practice this is found to be the case.

INCIDENCE AND CLINICAL DATA. Medulloblastomas account for approximately 6 percent of all intracranial tumors

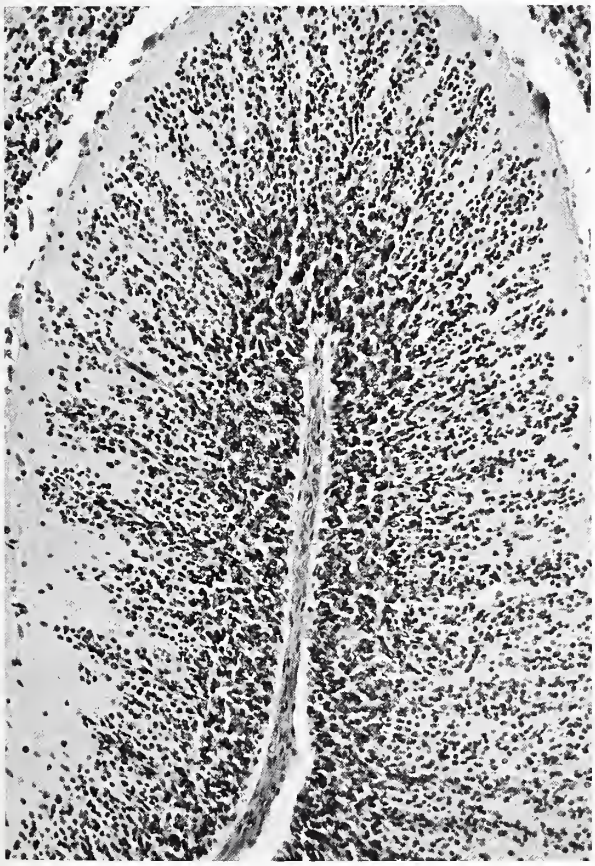

Fig. 136

NEOPLASTIC PROLIFERATION OF FETAL EXTERNAL GRANULAR LAYER IN AN INFANT WITH CEREBELLAR MEDULLOBLASTOMA, PRESUMABLY CONGENITAL

(Figures 135, 136, and 157 from same case)

Figure 136. There is irregular proliferation of the cells of the external granular layer throughout the major portion of the molecular layer, often along the penetrating blood vessels. This field is taken from the cerebellar cortex adjacent to a large midline cerebellar medulloblastoma. × 110. (Fig. 6 from Kadin, M. E., Rubinstein, L. J., and Nelson, J. S. Neonatal cerebellar medulloblastoma originating from the fetal external granular layer. J. Neuropath. Exp. Neurol. 29:583-600, 1970).

of the glioma group. They naturally form a much higher proportion in children in whom, according to the figures of Tola, they account for 25 percent of intracranial tumors, being second only in frequency to the astrocytomas. The predominance of medulloblastomas in childhood is widely recognized with more than 50 percent occurring in the first decade, mostly in its second half. But approximately one third of the cases occur in adolescence and early adulthood, between the ages of 15 and 35; these are mostly situated in the lateral lobes. Contrary to common belief medulloblastomas are also occasionally found in older age groups (pl. V-B) up to the end of the fifth decade. The oldest example of which I am aware was in a man age 61 at death, who had a cerebellar medulloblastoma removed 13 years previously and who died of a massive local recurrence with metastases in the regional cervical lymph nodes. No other tumor was found in the rest of the body. Males are more often affected than females in a ratio of 4 to 3. Incidence in siblings has occasionally been reported (Bickerstaff et al.).

The clinical picture is almost always that of a posterior fossa tumor. Occasionally a small, clinically silent, primary tumor may present with symptoms referable to a larger metastatic mass elsewhere in the central nervous system.

SITE. Although initially postulated by Bailey and Cushing to occur also in the cerebral hemispheres, medulloblastomas are now generally recognized to arise only in the cerebellum. The majority, especially in the first decade, originate in the midline. Those in the older age groups are more likely to occupy a lateral lobe, a preferential site that is in accord with the development and migration of the germinal layer of the cerebellar cortex. However, examples are found in the cerebellar hemispheres in infancy and childhood, and midline tumors are also encountered in older subjects (fig. 158). The lateral-lobe examples in adults often present as apparently extracerebellar masses, attached to the arachnoid but not to the dura. Occasionally such a mass may appear in the region of the tonsil or in the pontocerebellar angle.

GROSS. The **midline tumors** in childhood tend to be soft, rather friable, and fairly well demarcated (fig. 137); the cut surface is usually homogeneous and pale gray, with central areas of necrosis in the larger examples. Hemorrhage, cyst formation, and calcification are uncommon. The tumors arising from the vermis frequently fill the cavity of the fourth ventricle, and may infiltrate its floor. Further extension may take place in contiguity into the cisterna magna. Direct extension above the aqueduct is exceptional.

The **lateral examples** in adults are characteristic, in that they form smooth or slightly lobulated masses often showing an apparently crisp line of cleavage that separates them from the underlying cortical folia. They frequently present on the surface of a hemisphere, usually on its dorsal aspect. The cut surfaces are firm and homogeneous, sometimes a little nodular. The consistency is tough, almost woody. Their apparent circumscription may at first invite the diagnosis of a metastatic tumor. Occasionally the medulloblastoma spreads *en plaque* on the surface of the cerebellum, or there may be diffuse and extensive infiltration of the hemisphere with loss of pattern in the folia and generalized obliteration of the subarachnoid spaces (pl. V-B). In the infiltrated lobe more distinct grayish tumor nodules may be found that are largely extracerebellar; they may be cystic.

MIDLINE CEREBELLAR MEDULLOBLASTOMA

Figure 137. This well defined, homogeneous pale gray medulloblastoma occupies the vermis. There is moderate dilatation of the ventricular system. (Courtesy of the Armed Forces Institute of Pathology).

MICROSCOPIC. The histologic picture of the medulloblastoma is that of a highly cellular tumor composed of darkly staining cells with hyperchromatic nuclei and very ill-defined cytoplasmic outlines, usually without definite architectural arrangement. The cells are spheroidal or oval, frequently polar. A fine fibrillated background is usually present, indicative of the neuroectodermal nature of the tumor, but frequently no further differentiating feature is found. The vascular stroma varies, but usually consists of thin-walled blood vessels devoid of endothelial proliferation; occasionally, however, this is present. Mitotic figures are highly variable. The **rosettes** originally described by Homer Wright in sympathicoblastomas and widely regarded as indicative of **neuroblastic** differentiation are found in one third or less of the cases (fig. 138). Termed "pseudorosettes" by Bailey and Cushing (p. 125), they are, however, highly characteristic and generally diagnostic of medulloblastoma: the carrot-shaped nuclei with a heavy chromatin net are arranged radially about an eosinophilic center in which a delicate tangle of fibrillated material is often seen in hematoxylin-eosin preparations. This material is, unfortunately, usually refractory to silver impregnation technics, but exceptionally in my experience fine distinct neurofibrillar processes may be demonstrated to form a tangled web in the center of the rosette (fig. 139). In smears obtained at the time of surgery, the tumor smears easily to form a thin highly cellular film with darkly staining nuclei. Rosettes are occasionally seen in these preparations (pl. V-C).

PLATE V

MEDULLOEPITHELIOMA

(Plate V-A and Figures 113 and 134 from same case)

A. A sharply circumscribed, fleshy and extensively hemorrhagic tumor occupies the left parietal lobe in a 16-month-old girl. The tumor is quite separate from the lateral ventricle. (Fig. 2 from Deck, J. H. N. Cerebral medulloepithelioma with maturation into ependymal cells and ganglion cells. J. Neuropath. Exp. Neurol. 28:442–454, 1969).

LATERAL-LOBE MEDULLOBLASTOMA

(Plate V-B and Figure 154 from same case)

B. This medulloblastoma is infiltrating diffusely the left cerebellar lobe in a 44-year-old man. Note the loss of pattern in the cerebellar folia due to extensive infiltration of the subarachnoid spaces by the neoplasm. In the center of this infiltration there is a more distinct nodule of tumor that is largely extracerebellar. (Courtesy of Dr. J. E. Olvera-Rabiela, Mexico City, Mexico).

SMEAR FROM A CEREBELLAR MEDULLOBLASTOMA

C. This highly cellular smear from a classic medulloblastoma is composed of darkly staining nuclei. Note the rosette in the upper half of the photomicrograph. Morris. × 400.

GANGLIOGLIOMA

(Plate V-D and Figures 46 and 173–178 from same case)

D. This is part of the poorly cellular ganglionic portion in a ganglioglioma. Ganglion cells of different sizes and shapes show variable amounts of Nissl substance. Some of it is unusually abundant and coarsely clumped, or very irregularly distributed in the cytoplasm. Some of the cells show almost no Nissl bodies. Cresyl violet stain for Nissl. × 300.

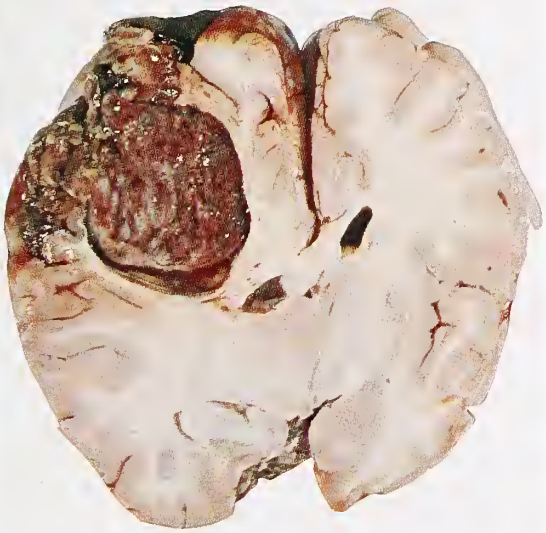

A

B

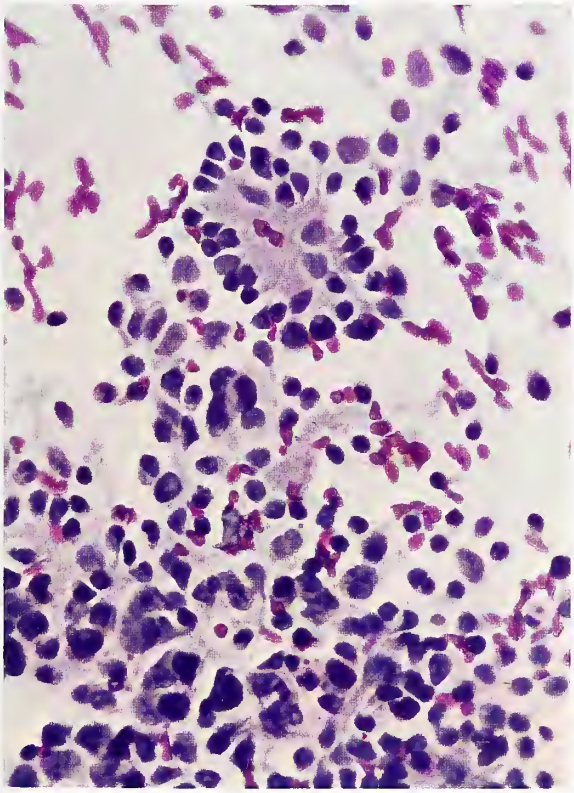

C

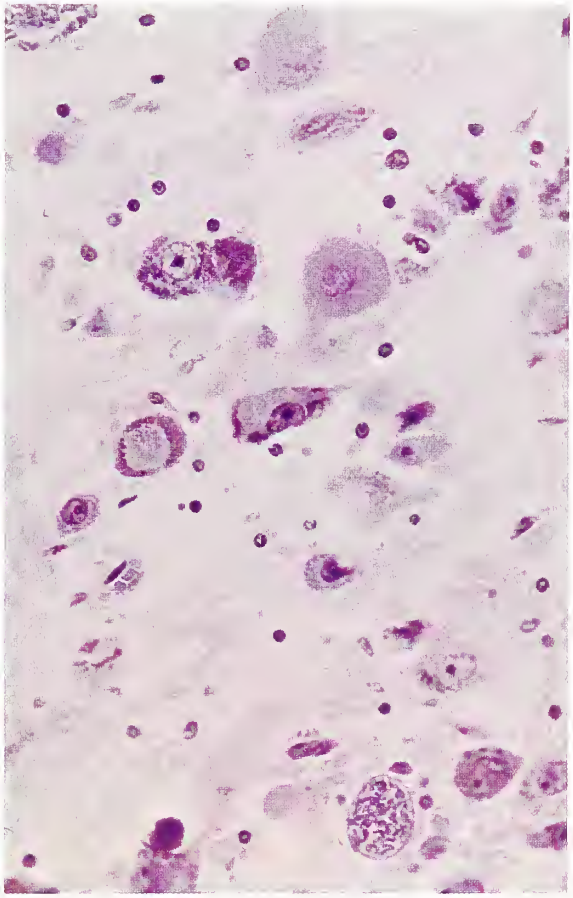

D

PLATE V

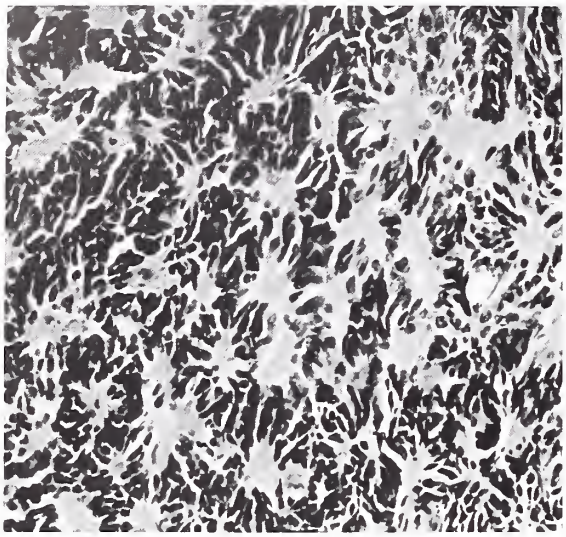

ROSETTES IN MEDULLOBLASTOMA

Figure 138. Numerous Homer Wright rosettes are seen in a recurrent midline cerebellar medulloblastoma of a 15-year-old boy. In other areas the pattern was that of islands and lobules typical of the desmoplastic variant of medulloblastoma. × 200. (Fig. 20 from Rubinstein, L. J., and Northfield, D. W. C. The medulloblastoma and the so-called "arachnoidal cerebellar sarcoma." A critical re-examination of a nosological problem. Brain 87:379–412, 1964).

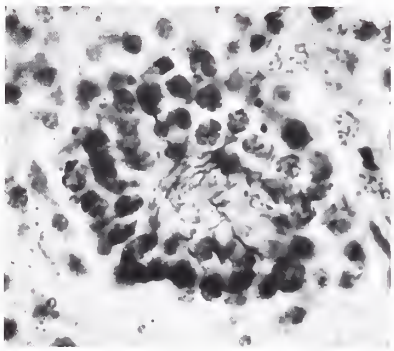

NEUROFIBRILLARY PROCESSES IN ROSETTE OF MEDULLOBLASTOMA

Figure 139. This rosette was found in the leptomeninges of an 8-year-old boy with a medulloblastoma arising in the posterior vermis. Delicate neurofibrillary processes are seen to form a tangle in the center of the rosette. Bodian silver stain on celloidin section. × 600.

In other examples the cells form ill-defined circular whorls (fig. 140); in some of these, fine delicately staining unipolar processes are demonstrable with phosphotungstic acid hematoxylin, suggesting spongioblastic differentiation (fig. 141). Another arrangement is a rhythmic pattern of palisades (fig. 142); in places this pattern seems to merge with the pattern of rosettes previously described, and may be a variant of it. In some cases, unipolar or bipolar cells with the tinctorial properties of spongioblasts are so arranged as to resemble the architecture of the polar spongioblastoma

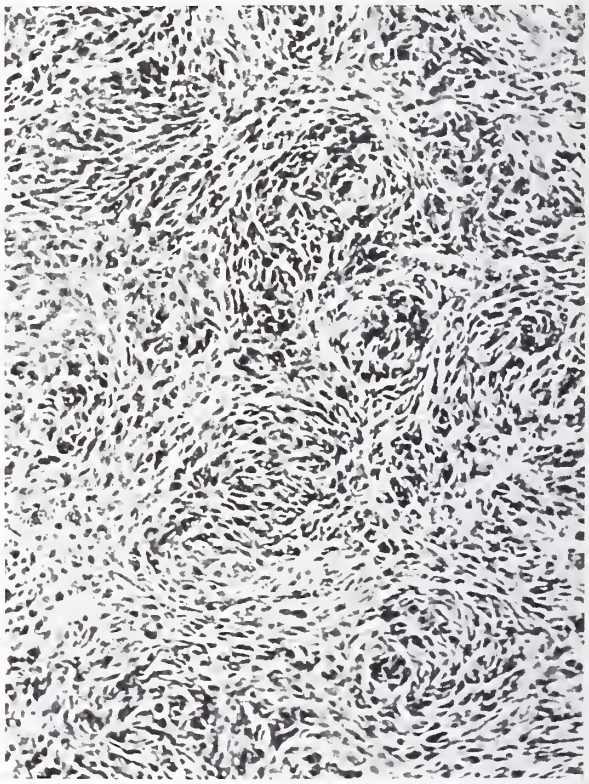

WHORLED PATTERN IN MEDULLOBLASTOMA

(Figures 140 and 141 from same case)

Figure 140. This pattern of cells arranged in whorls is seen in a medulloblastoma of a 4-year-old boy. × 145.

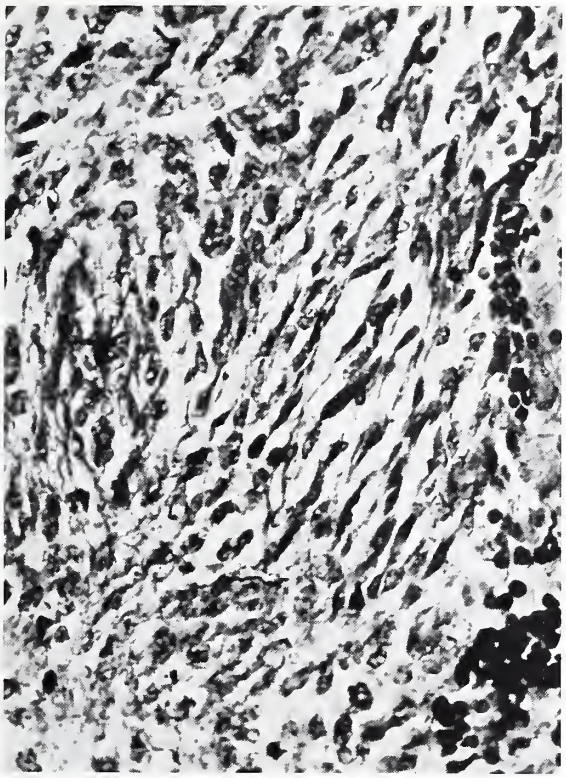

SPONGIOBLASTIC DIFFERENTIATION IN MEDULLOBLASTOMA

(Figures 140 and 141 from same case)

Figure 141. This spongioblastic differentiation with delicately staining unipolar processes occurred in a medulloblastoma. PTAH. × 400.

RHYTHMIC PALISADING OF TUMOR CELLS IN CEREBELLAR MEDULLOBLASTOMA

(Figures 142, 161, 162, and 164–166 from same case)

Figure 142. This rhythmic pattern of palisades and rosettes was found in a recurrent cerebellar medulloblastoma of the vermis in a 5-year-old girl. This field is taken from the temporal cortex, in which reinvasion had taken place as a result of extensive cerebrospinal fluid dissemination four and one-half years after the original operation. van Gieson. × 115.

(see p. 53 and figs. 33, 34), a tumor reported to have a kinship with some forms of medulloblastoma. Exceptionally pseudopalisades around small foci of necrosis may be seen that are indistinguishable from those of glioblastoma multiforme. Figure 143 illustrates a medulloblastoma that arose in the vermis of a 14-year-old boy and metastasized widely throughout the cerebrospinal axis. This rare observation suggests a possible common final pathway of anaplasia in which medulloblastoma and glioblastoma may display identical morphologic features, in accord with the concept originally suggested by Bailey and Cushing that some medulloblastomas may be entirely composed of cells of neuroglial lineage.

Fig. 142

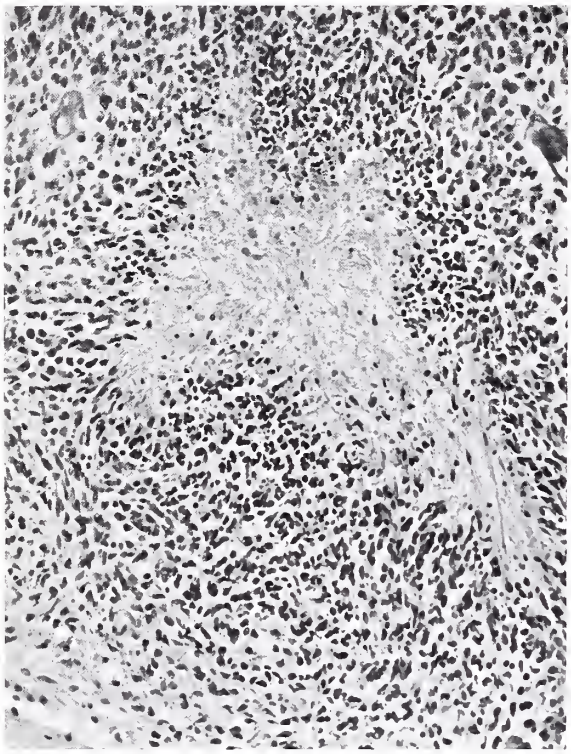

PSEUDOPALISADES IN CEREBELLAR MEDULLOBLASTOMA

Figure 143. An arrangement of pseudopalisades around a small focus of early necrosis is seen in a medulloblastoma with spongioblastic differentiation that arose in the vermis of a 14-year-old boy and metastasized widely through the cerebrospinal fluid pathways. × 140.

Another pattern that may be a cause of confusion with other forms of glioma is a perivascular arrangement of the tumor cells to form a system of pseudorosettes (fig. 144); of course this is not specific for, or diagnostic of, medulloblastoma, but probably constitutes an example of secondary perivascular spread or structure in the meaning of Scherer (pp. 11, 12).

As already mentioned most medulloblastomas show little or no evidence of differentiation. Neuronal maturation seldom goes beyond the formation of neuroblastic rosettes (fig. 138). Occasionally differentiation toward more mature **ganglion** cells is seen (fig. 145), a feature that has also been reported by others (Kane and Aronson; Durity et al.). Differentiation along spongioblastic lines (fig. 141) is endorsed also by Bodian and Lawson, and by Willis. Convincing differentiation toward mature **astrocytes** has not been authenticated in detail and presumably must be exceptional, but is suggested in figure 146. In this recurrent radiated medulloblastoma a field is illustrated in which the tumor cells are highly reminiscent of a malignant astrocytoma.

PERIVASCULAR PSEUDOROSETTES IN MEDULLOBLASTOMA

(Figures 144, 150, and 153 from same case)

Figure 144. This low power view shows the perivascular arrangement of pseudorosettes in a diffusely infiltrating medulloblastoma arising in the cerebellar hemisphere of a 25-year-old woman. Elsewhere the pattern was that of the desmoplastic variant of medulloblastoma. × 75.

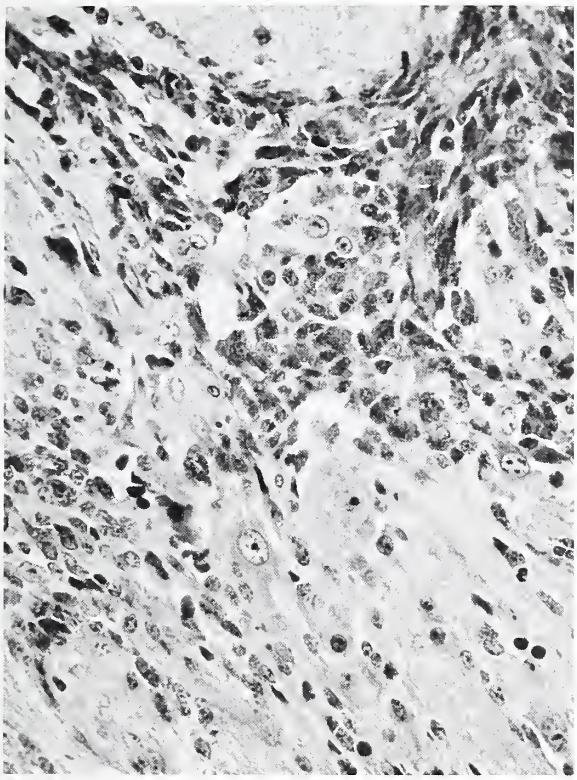

Fig. 145

NEURONAL DIFFERENTIATION IN MEDULLOBLASTOMA

Figure 145. This differentiation to mature ganglion cells occurred in a cerebellar medulloblastoma in a 29-year-old man. × 320.

ASTROCYTIC DIFFERENTIATION IN MEDULLOBLASTOMA

(Figures 146 and 148 from same case)

Figure 146. Astrocytic cells with cytologic pleomorphism are shown in a recurrent radiated medulloblastoma arising in the vermis of an 11-year-old girl. Possibly the cell changes are due to radiation. × 350.

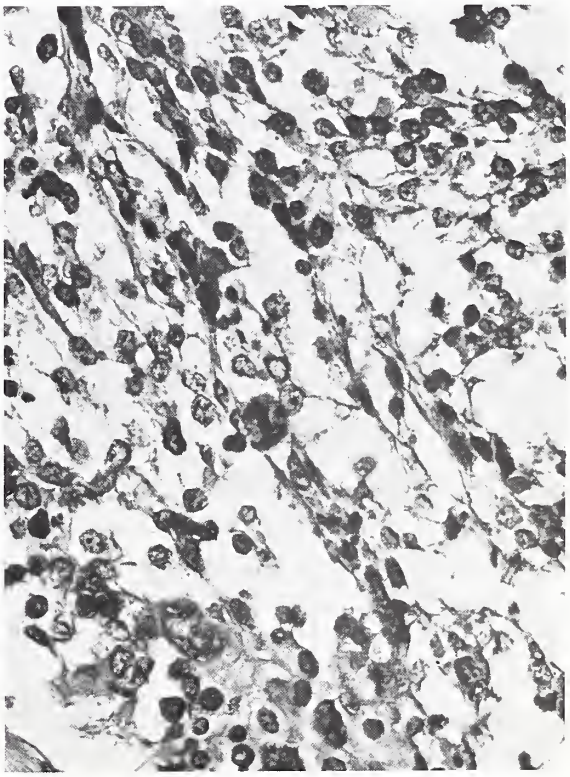

Fig. 146

Finally, differentiation of medulloblastoma into **oligodendroglioma** has also been accepted by Willis and strongly advocated by Bodian and Lawson, although denied by Ringertz and Tola. In a previously reported series of 42 cerebellar medulloblastomas, six examples were cited in which microscopic fields indistinguishable from those of an oligodendroglioma were found (fig. 147). Many of the tumor cells showed perinuclear halos, and they were supported and partitioned by a tenuous and regular vascular stroma; in one case microscopic calcification was present. It should be stressed that in all six cases the microscopic appearances in other areas were indistinguishable from those of a classic medulloblastoma, and that typical rosettes were present in four (Rubinstein and Northfield).

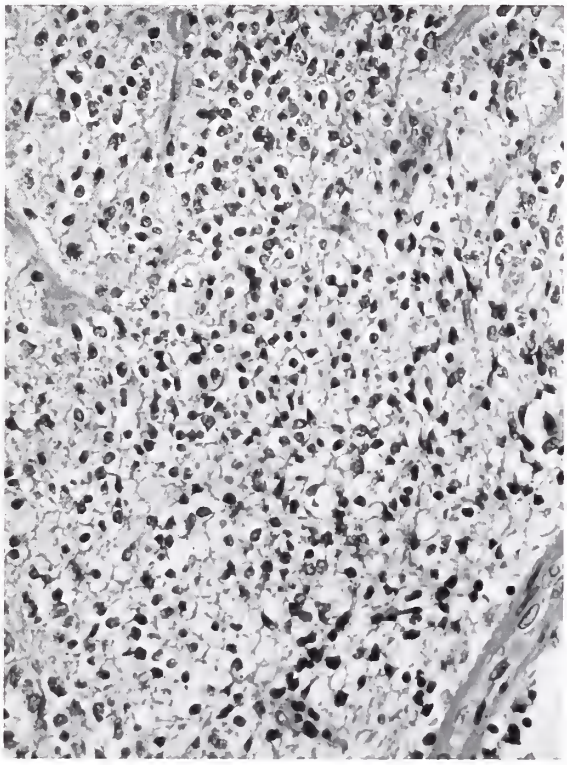

OLIGODENDROGLIAL DIFFERENTIATION IN MEDULLOBLASTOMA

Figure 147. This focus of oligodendroglioma was found in an otherwise typical cerebellar medulloblastoma in a 13-year-old girl. × 260. (Fig. 1 from Rubinstein, L. J., and Northfield, D. W. C. The medulloblastoma and the so-called "arachnoidal cerebellar sarcoma." A critical re-examination of a nosological problem. Brain 87:379–412, 1964).

One must conclude that although most medulloblastomas are quite undifferentiated, collective evidence exists that suggests multipotential differentiation, admittedly exceptional, toward neuronal, spongioblastic, and oligodendroglial cell lines. Thus far electron microscopic studies on a few of these tumors have shed no further light on the problem (Voigt); the fine structural appearances are those of highly primitive tumor elements. Microtubules have been observed in their cell processes (Escourolle and Poirier; Kadin et al.). The interpretation by Escourolle and Poirier that this indicates differentiation of the tumor cells into neuroblasts appears, however, unwarranted in the absence of synaptic complexes, such as have been seen in peripheral neuroblastomas and ganglioneuroblastomas, and in view of the ready demonstration of microtubules in other immature cells of neuroepithelial origin (Vaughn and Peters). As to the interpretation of tissue culture experiments, it is so far contradictory: Lumsden, on the basis of four examples, strongly believes that the tumor cells differentiate into neuroblasts; Kersting denies differentiation along any cell line.

Giant and multinucleated cells are very uncommon in medulloblastomas. Figure 148, however, illustrates the case of an 11-year-old girl who had received radiation therapy four years previously for a posterior fossa tumor. At postmortem examination this was identified as a midline medulloblastoma that partly occupied the fourth ventricle and showed extensive calcification. It is

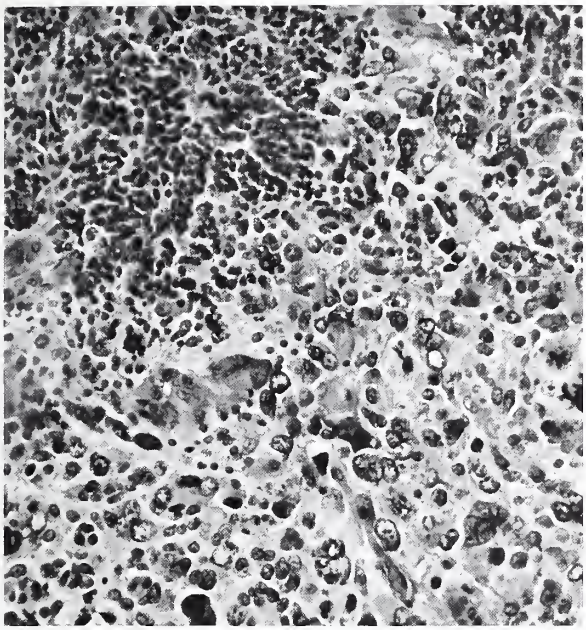

MULTINUCLEATED GIANT CELLS
PROBABLE RADIATION EFFECT
IN MEDULLOBLASTOMA

(Figures 146 and 148 from same case)

Figure 148. Marked pleomorphism and multinucleated giant cells in this medulloblastoma resemble the cytologic features of a glioblastoma. This is probably a radiation effect. × 195.

likely that the morphologic characteristics of some of the tumor cells, which resemble in places those of a glioblastoma, resulted from the radiation. A similar cytologic alteration has been recorded by Oppenheimer.

VARIANTS

Pigmented Papillary Medulloblastoma

A curious variant of the medulloblastoma, reported by Fowler and Simpson and subsequently noted by Rubinstein and Northfield, consists in an arrangement of compact papillary and tubular formations covered by cuboidal and low columnar epithelium, superficially resembling choroid plexus epithelium. The cells are loaded with melanin granules (fig. 149). Other areas have the typical features of medulloblastoma, and the biologic behavior is similar: it metastasizes widely through the cerebrospinal fluid pathways. It has been suggested that this neoplasm may be a variant of the pigmented neuroectodermal tumor of infancy, also known as "retinal anlage" tumor, "melanotic progonoma," and many other designations (Borello and Gorlin).

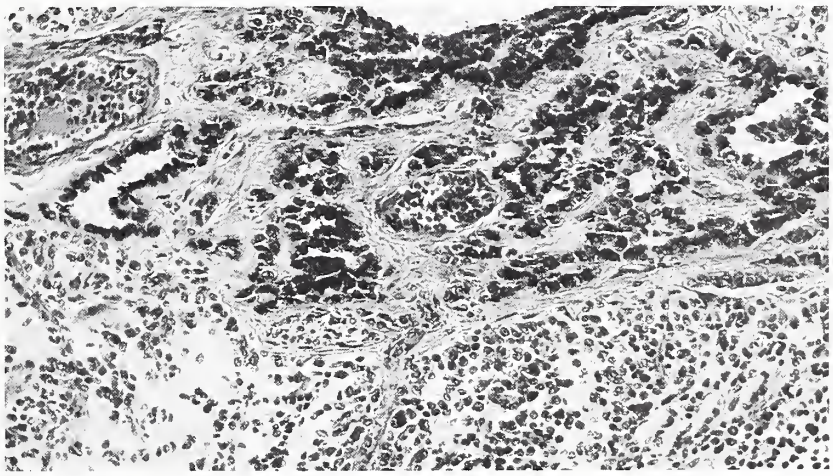

PIGMENTED PAPILLARY FORM OF MEDULLOBLASTOMA

Figure 149. Papillary and tubular formations are covered by heavily pigmented (melanin) cuboidal and low columnar epithelium in this cerebellar neoplasm occupying the vermis and fourth ventricle in a 3-year-old child. This pigmented tumor metastasized widely in the cerebrospinal fluid pathway. × 180. (Courtesy of Dr. J. H. Sung, Minneapolis, Minn.)

Medullomyoblastoma

Another exceptionally rare variant of the medulloblastoma contains smooth or striated muscle fibers (Bofin and Ebels). It has been termed medullomyoblastoma. This neoplasm should probably be considered a form of teratoma (see p. 287), an interpretation compatible with its midline situation. Its origin and place among the medulloblastomas remain speculative. However, extraordinary weight has been given in some quarters to the existence of this tumor in support of the proposition that all medulloblastomas are derived from embryonal mesodermal elements.

GROWTH AND SPREAD. An appreciation of the characteristic forms of spread of medulloblastomas in the cerebellum and leptomeninges is desirable for an understanding of the histologic patterns that are seen under the microscope. As in all diffusely infiltrating gliomas, the subpial secondary structures of Scherer are frequent (fig. 150). Their special incidence in the lateral lobe in young adults has suggested an origin from the superficial part of the molecular layer. This speculation is not susceptible to proof, and examination of any large numbers of medulloblastomas will disclose a wide variety of patterns of infiltration that involve different parts of the cerebellar cortex. **Infiltration of the subarachnoid space** is frequent, usually early, and often massive. As a result the invaded leptomeninges are stimulated into an intense proliferation of connective tissue that often appears the dominant feature under the microscope (figs. 151, 152). This observation has generated singular views on the nature of the medulloblastoma and on the cell of origin of some of its variants. Of practical diagnostic importance is the fact that, as a result of this fibrous connective tissue proliferation, a marked alteration in tumor cell architecture takes place. It is caused by the alignment of the tumor cells in long rows along the connective tissue fibers that have been laid down. This feature is illustrated in figure 152, in which two different histologic preparations of the same field show tumor in the cerebellar parenchyma and in the adjacent subarachnoid space. Another case demonstrates an overall view of the various patterns of infiltration that are found in the molecular and granular layers, and the characteristic arrangement of sinuous trabeculae and islands in the invaded leptomeninges (fig. 153). A closer view of these patterns is seen in figure 154, taken from a

SUBPIAL SECONDARY STRUCTURES IN MEDULLOBLASTOMA

(Figures 144, 150, and 153 from same case)

Figure 150. This illustrates diffuse subpial spread of medulloblastoma in a cerebellar hemispheric tumor in a 25-year-old woman. × 84.

INVASION OF LEPTOMENINGES BY CEREBELLAR MEDULLOBLASTOMA

(Figures 151 and 152 from same case)

Figure 151. Intense proliferation of connective tissue is seen in a cerebellar sulcus infiltrated by medulloblastoma in a 12-year-old boy. Silver stain for reticulin. × 60.

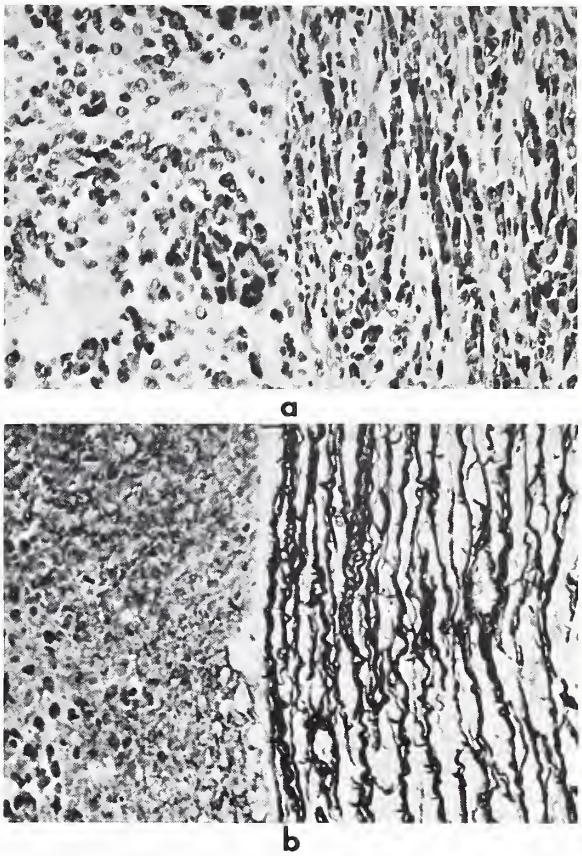

INVASION OF LEPTOMENINGES BY CEREBELLAR MEDULLOBLASTOMA

(Figures 151 and 152 from same case)

Figure 152. The marked alteration of tumor architecture is shown that results from invasion of the leptomeninges and proliferation of fibrous connective tissue in the latter. The same fields in both photomicrographs show tumor cells in the cerebellar parenchyma on the left, and in the subarachnoid space on the right. (a) H & E; (b) Silver stain for reticulin. Both × 250. (Figs. 17 and 18 from Rubinstein, L. J., and Northfield, D. W. C. The medulloblastoma and the so-called "arachnoidal cerebellar sarcoma." A critical re-examination of a nosological problem. Brain 87:379–412, 1964).

diffuse medulloblastoma that infiltrated the entire left cerebellar hemisphere in a 44-year-old man (pl. V-B). In other examples a gradual transition between the classic medulloblastoma and its desmoplastic variant is seen as the former approaches and invades the leptomeninges (fig. 155). Tumors of this kind merge insensibly into the desmoplastic variant of the medulloblastoma (Rubinstein and Northfield), in which a typical pattern of reticulin-free islands and lobules is demonstrated (fig. 156). This is the picture most frequently encountered in tumors arising in the cerebellar hemispheres of adults. However, the pattern is not restricted to that age group or situation: a similar tumor that is presumably congenital was found in the vermis of a newborn infant and apparently originated from the fetal external granular layer (fig. 157).

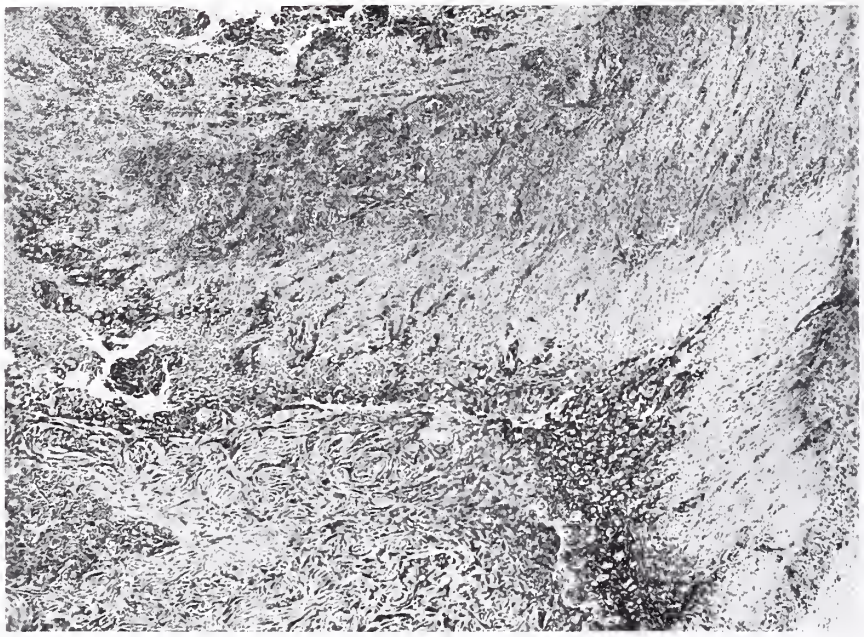

PATTERNS OF INFILTRATION BY MEDULLOBLASTOMA

(Figures 144, 150, and 153 from same case)

Figure 153. The various patterns of infiltration of the molecular and granular layers are seen in this low power view of a cerebellar medulloblastoma in a 25-year-old woman. Note also the characteristic patterns of sinuous trabeculae and islands in the invaded leptomeninges (lower left). × 48.

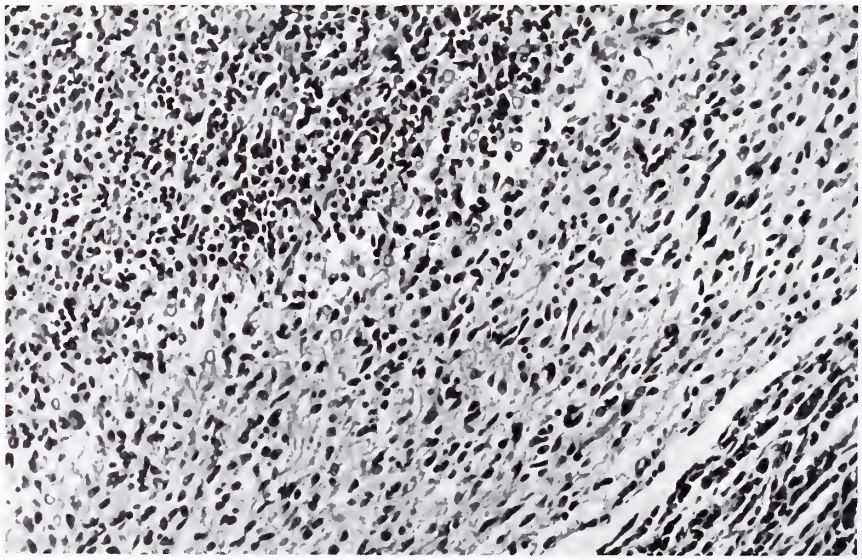

DIFFUSE INFILTRATION OF MOLECULAR AND GRANULAR LAYERS

(Figure 154 and Plate V-B from same case)

Figure 154. This illustrates diffuse infiltration of the granular (upper left) and molecular layers by a cerebellar medulloblastoma originating in the left lateral lobe of a 44-year-old man. Note the characteristic pattern of invasion of the subarachnoid space in the right lower corner of the illustration. × 175. (Courtesy of Dr. J. E. Olvera-Rabiela, Mexico City, Mexico).

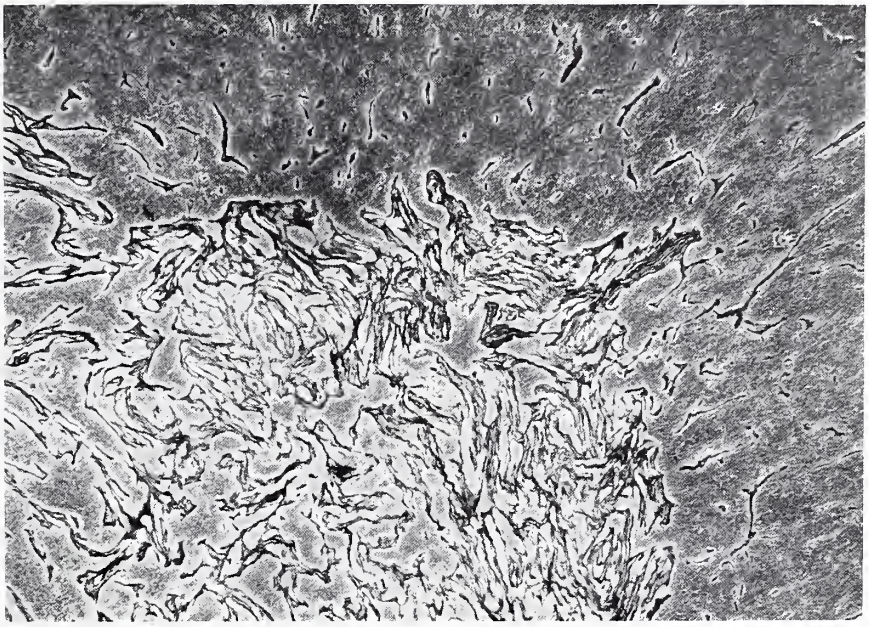

TRANSITION FROM CLASSICAL TO DESMOPLASTIC VARIANT OF MEDULLOBLASTOMA

Figure 155. In this low power view, a medulloblastoma in an 11-year-old boy diffusely replaces the cerebellar cortex (upper and right edges of the illustration) and gradually merges into the desmoplastic pattern as it approaches and invades the leptomeninges (left lower part of illustration). Silver stain for reticulin. × 25.

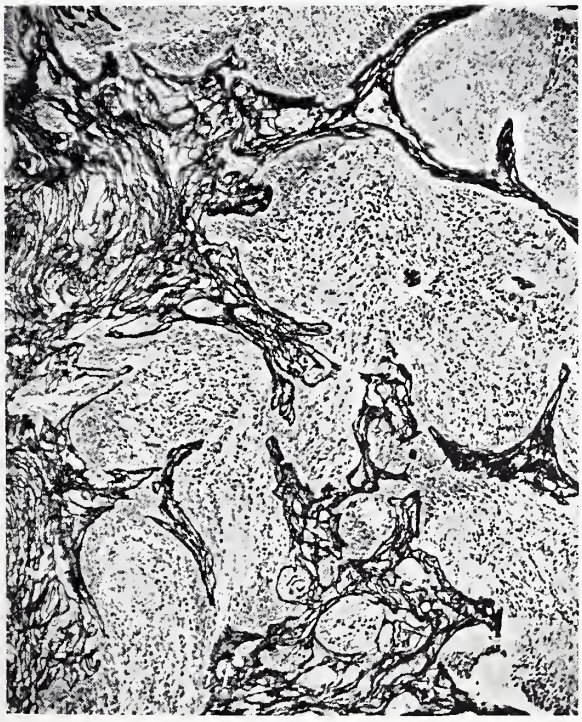

Fig. 156

DESMOPLASTIC VARIANT OF MEDULLOBLASTOMA

Figure 156. This is the characteristic pattern of reticulin-free islands and lobules in a partly extracerebellar, partly intracerebellar tumor situated between the right lobe and the tentorium in a 25-year-old woman. Total extirpation followed by radiotherapy in this case led to almost clinical complete recovery and to postoperative survival of 12 years to date. × 78.

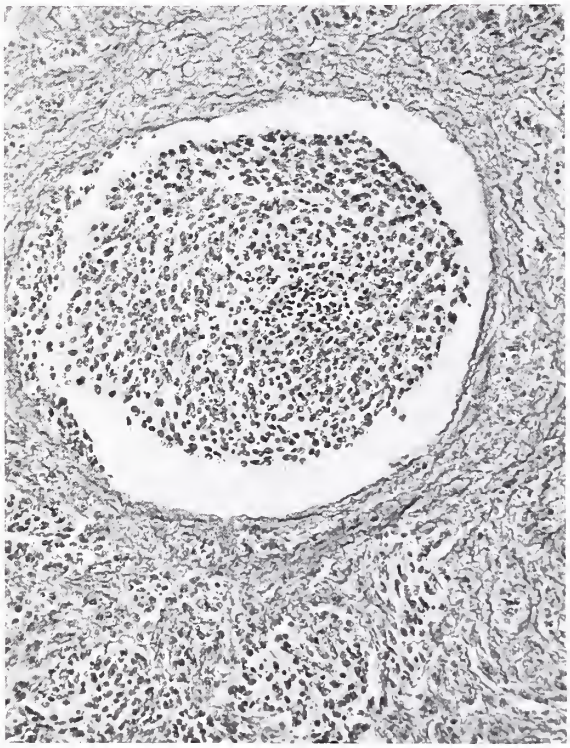

DESMOPLASTIC PATTERN OF MEDULLOBLASTOMA

(Figures 135, 136, and 157 from same case)

Figure 157. A pattern of reticulin-free island surrounded by abundant connective tissue is shown in this neonatal cerebellar medulloblastoma which apparently arose from the fetal external granular layer. Silver stain for reticulin. × 150.

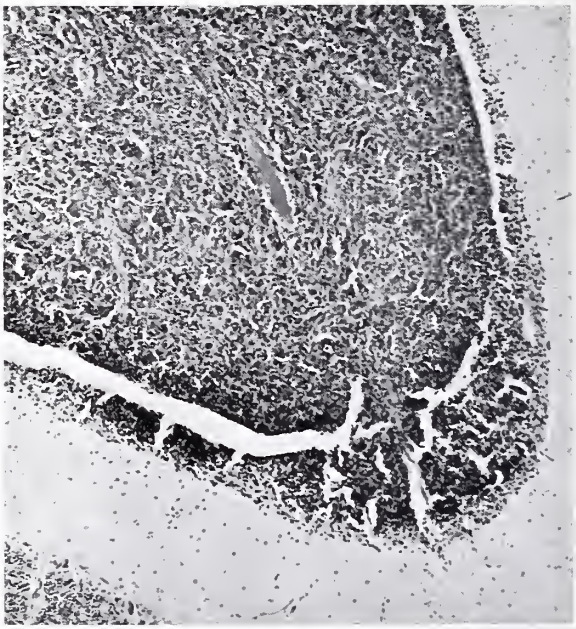

LARGELY EXTRACEREBELLAR GROWTH IN DESMOPLASTIC MEDULLOBLASTOMA

(Figures 158 and 159 from same case)

Figure 158. This desmoplastic type of cerebellar medulloblastoma arose in the vermis of a 32-year-old man. Most of the tumor is situated in the distended subarachnoid space, but overlies a thin rim of subpial growth. × 60. (Fig. 12 from Rubinstein, L. J., and Northfield, D. W. C. The medulloblastoma and the so-called "arachnoidal cerebellar sarcoma." A critical re-examination of a nosological problem. Brain 87:379–412, 1964).

One result of this form of growth is that part of the tumor, or sometimes its major portion, may actually be extracerebellar. As a consequence, in a few too rare fortunate cases surgical extirpation may lead to complete removal of the neoplastic field and unusually long postoperative survival, and even complete cures. This largely extracerebellar extension from a desmoplastic tumor arising in the vermis of a 32-year-old man is represented microscopically in figures 158 and 159. The thin rim of intraparenchymatous tumor is seen in both preparations, and is demonstrated with the silver stain for reticulin to be situated beneath the pia (fig. 159); reticulin fibers are present only among the neoplastic cells that infiltrate the subarachnoid space, an invariable feature in these examples. The recognition of this type of growth is of considerable surgical importance. These tumors, presenting as extracerebellar masses that lie on the surface of a hemisphere, may demonstrate beneath the line of cleavage a thin film of abnormal cerebellar tissue lining the wall of what appears to be a clean operative cavity. Microscopically this tissue is often medulloblastoma, and probably provides the initial neoplastic field from which the tumor originates.

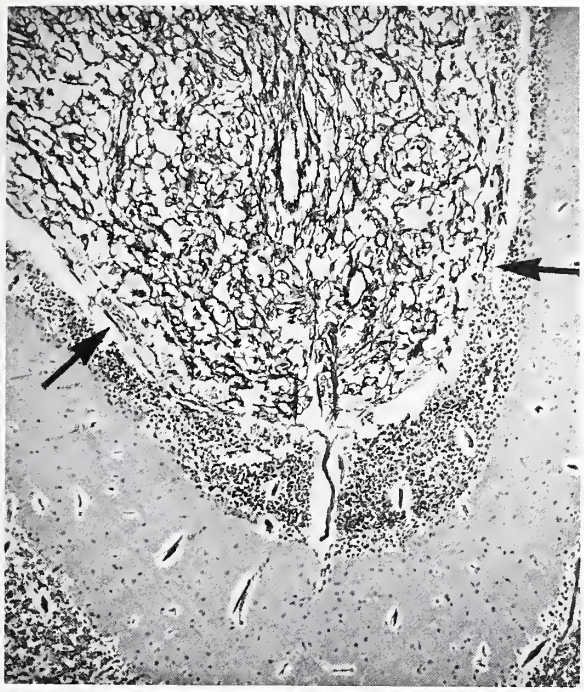

Fig. 159

LARGELY EXTRACEREBELLAR GROWTH IN DESMOPLASTIC MEDULLOBLASTOMA

(Figures 158 and 159 from same case)

Figure 159. Reticulin fibers are present only in the zone of tumor in the subarachnoid space. The pial margin is indicated by arrows. Silver stain for reticulin. × 60. (Fig. 13 from Rubinstein, L. J., and Northfield, D. W. C. The medulloblastoma and the so-called "arachnoidal cerebellar sarcoma." A critical re-examination of a nosological problem. Brain 87:379–412, 1964).

METASTASIS. Metastatic spread of medulloblastoma through the **cerebrospinal fluid pathways** is a well recognized and a common event, seen in over half the cases that come to necropsy. Dissemination is usually extensive. It may be diffuse or nodular. In the former the leptomeninges are covered by a whitish opaque, glistening exudate that may resemble sugar icing (fig. 160); it is usually thickest over the base of the brain

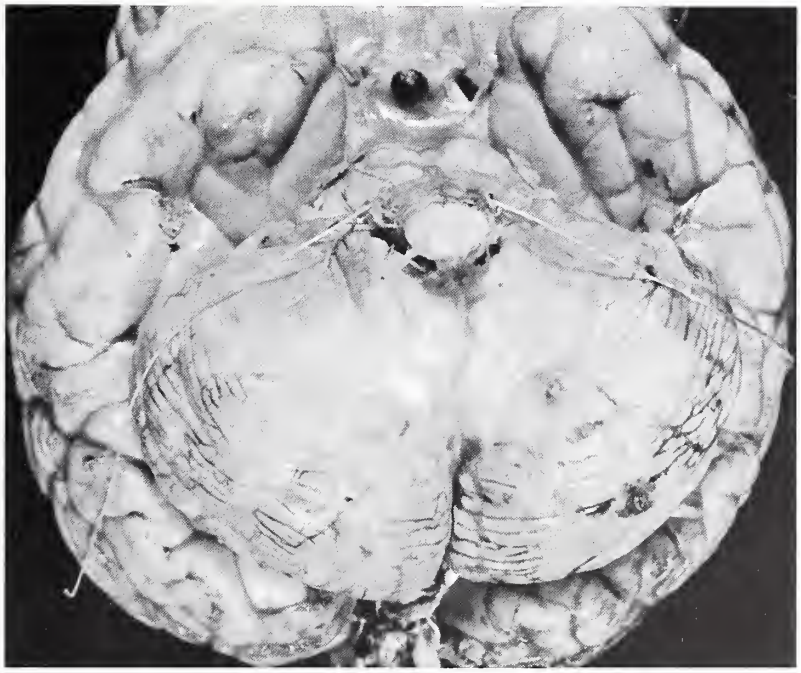

MEDULLOBLASTOMA. METASTATIC SPREAD THROUGH CEREBROSPINAL FLUID PATHWAYS

Figure 160. This illustrates diffuse subarachnoid spread by medulloblastoma, which covers the leptomeninges of the floor of the third ventricle and the inferior surfaces of the cerebellar lobes. (Courtesy of Dr. J. W. Hanbery, Stanford, Calif.)

and the inferior surfaces of the cerebellar hemispheres, and may surround the spinal cord, giving it a "bamboo stick" appearance. Alternatively, discrete nodules may be found throughout the subarachnoid spaces, particularly along the exits of the cranial and spinal nerve roots, with a special tendency to select those of the cauda equina (fig. 161). Intraventricular spread, both diffuse but more frequently nodular, is also common (fig. 162), presumably having occurred in a retrograde manner from the primary growth as it fills the fourth ventricle. Nodular reinvasion of the cortical, basal ganglia, and spinal cord parenchyma from leptomeningeal and ventricular deposits is frequent, and may lead in some cases to the formation of cystic secondary masses that are larger than the primary tumor. The orbital surfaces of the frontal lobes may be preferentially involved (fig. 162). This is possibly due to the relative protection of this area from the therapeutic radiation that is normally given to the rest of the central neuraxis.

While subarachnoid metastasis is common, subdural deposits are extremely rare. Study of a recent personal case of medulloblastoma that arose in the vermis of a 2½-year-old girl demonstrated numerous subdural nodules over the cerebral convexities and on either side of the falx. Massive

Fig. 161

SPINAL SUBARACHNOID SPREAD OF MEDULLOBLASTOMA

(Figures 142, 161, 162, and 164–166 from same case)

Figure 161. Along with focal enlargement of the nerve roots of the cauda equina, discrete fusiform nodules of metastatic spread are seen in a recurrent cerebellar medulloblastoma in a 9½-year-old girl.

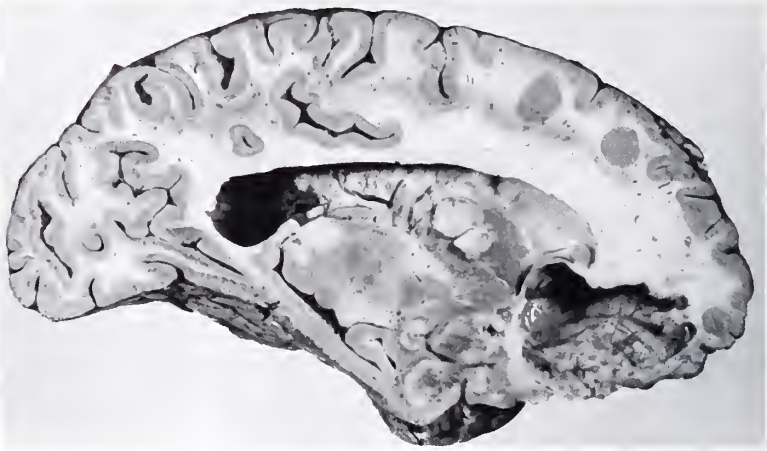

VENTRICULAR METASTASES IN CEREBELLAR MEDULLOBLASTOMA

Figure 162. Sagittal section through the cerebral hemisphere reveals several nodules of tumor infiltrating the basal ganglia and the frontal and temporal cortex. In the right lower area of the photograph the large cystic cavity in the frontal lobe results from an extensive, centrally necrotic retroorbital deposit. (Fig. 2 from Rubinstein, L. J. Extracranial metastases in cerebellar medulloblastoma. J. Path. Bact. 78:187–195, 1959).

subarachnoid infiltration was present over the base. It is reasonable to assume that transgression of the arachnoid at that site must have paved the way to dissemination in the subdural space.

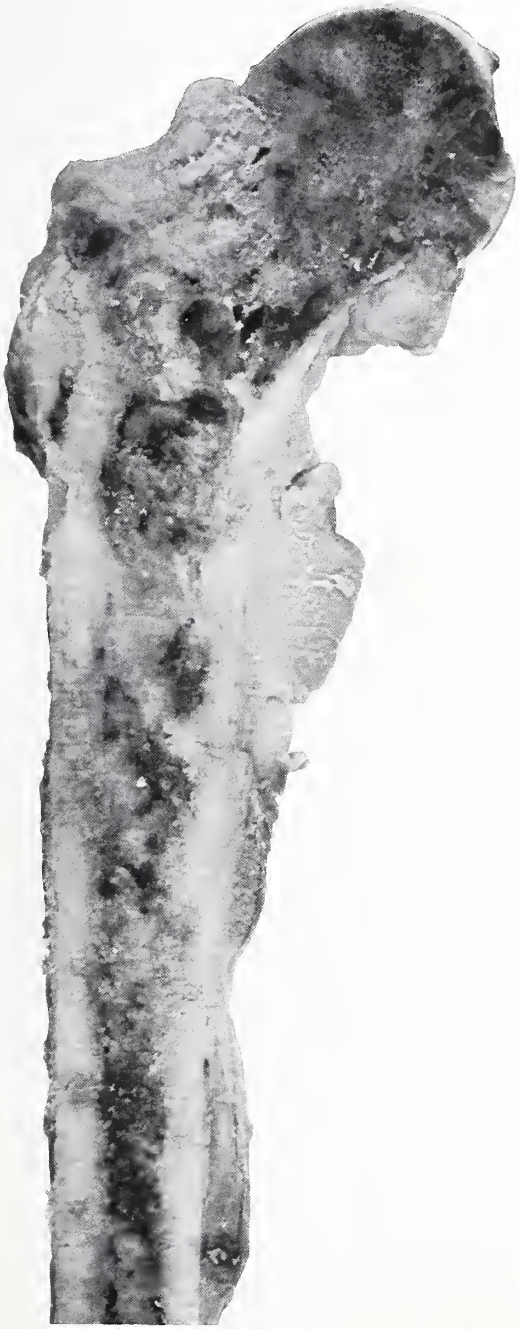

Fig. 163

Extraneural metastases have been reported and are well authenticated (Drachman et al.; Oberman et al.). I have examined five cases in which this complication was demonstrated histologically. Two of these were in medulloblastomas of the desmoplastic type (Rubinstein and Northfield); a third was of unusual interest in that this development, which took place more than four years after the biopsy of a midline tumor, could be ascribed to invasion of the orbit and permeation of the dural veins by a large frontal metastasis (Rubinstein; figs. 161, 162, 164-166). In this instance, therefore, distant spread had occurred independently of the site of previous craniotomy; in most reported cases, however, the latter appears to have paved the way. An artificial pathway for the development of extraneural deposits of medulloblastomas through ventriculovenous shunting procedures for the relief of hydrocephalus has also been described (Makeever and King).

Remote metastases most frequently involve the bone marrow (figs. 163, 165, 166) and the regional cervical lymph nodes (fig. 164). Neoplastic involvement of the osseous system is sometimes extraordinarily extensive (fig. 163). The histologic pattern in the marrow may be that of sinuous whorls of

EXTRANEURAL METASTASES IN CEREBELLAR MEDULLOBLASTOMA

Figure 163. There is massive replacement of the central marrow and bony cortex with conspicuous periosteal involvement by a metastatic cerebellar medulloblastoma of the desmoplastic type arising in a 13-year-old boy. There was extensive neoplastic infiltration of all vertebral bodies, sternum, iliac bones, both femora and tibiae, right humerus, most ribs and skull, the thymus, lymph nodes throughout the body, testes, and pancreas. This widespread metastatic spread took place four years after removal of the original cerebellar tumor.

LYMPHATIC PERMEATION BY METASTATIC MEDULLOBLASTOMA

(Figures 142, 161, 162, and 164–166 from same case)

Figure 164. Metastatic medulloblastoma permeates the medullary sinusoids in a left upper cervical lymph node in a case with extensive cerebrospinal metastases and distant deposits in the femoral and sternal marrow. × 130. (Fig. 9 from Rubinstein, L. J. Extracranial metastases in cerebellar medulloblastoma. J. Path. Bact. 78:187–195, 1959).

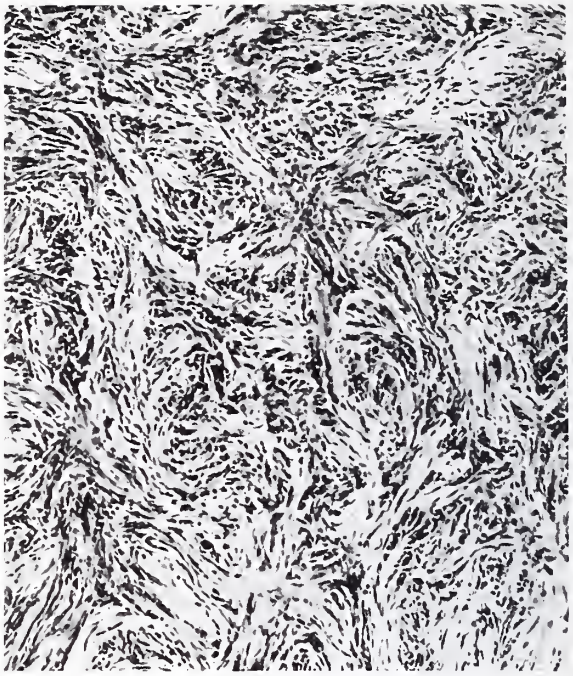

MICROSCOPIC INFILTRATION OF FEMORAL MARROW BY METASTATIC MEDULLOBLASTOMA

(Figures 142, 161, 162, and 164–166 from same case)

Figure 165. A sinuous, somewhat whorled pattern of small darkly staining metastatic medulloblastoma infiltrates the femoral marrow. × 130. (Fig. 8 from Rubinstein, L. J. Extracranial metastases in cerebellar medulloblastoma. J. Path. Bact. 78:187–195, 1959).

tumor cells (fig. 165), an arrangement clearly determined by the laying down of abundant connective tissue in response to tumor invasion (fig. 166). Why the lungs are characteristically free of metastatic deposits in these cases remains unanswered (Drachman et al.).

TREATMENT. Medulloblastomas are highly radiosensitive, and the treatment of choice is radiotherapy of the entire neuraxis. Since the alternative tumors in the posterior fossa in children, the astrocytoma and the ependymoma, should be treated by radical surgery, radiation should never be delivered without histologic confirmation. It must be stressed that this treatment is also mandatory for the laterally located tumors in older age groups, since they are just as likely to recur and to metastasize as the more frequent midline examples in children.

Some neurosurgeons advocate as radical surgical removal of the primary tumor as possible, followed by maximal roentgen therapy. Recent reports suggest that even in the presence of skeletal metastases, an occasional favorable response has been obtained from the intrathecal administration of methotrexate or to intravenous vincristine.

MICROSCOPIC INFILTRATION OF FEMORAL MARROW BY METASTATIC MEDULLOBLASTOMA

(Figures 142, 161, 162, and 164–166 from same case)

Figure 166. In a similar field abundant connective tissue proliferation is evident in response to invasion by medulloblastoma. Silver stain for reticulin. × 130.

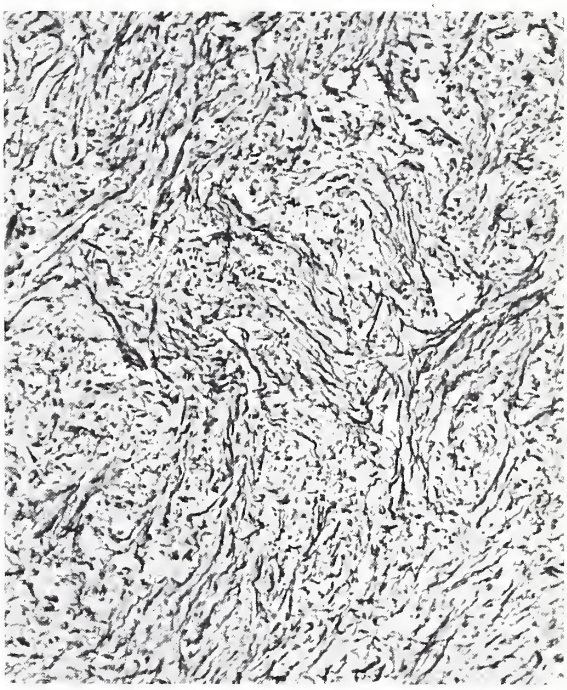

Fig. 166

However, chemotherapy should not be used as an adjuvant to surgery in a tumor as radiosensitive as medulloblastoma, but should be restricted to recurrences that are no longer responsive to x-ray treatment (Wilson).

PROGNOSIS. Radiation is usually followed by a marked regression of signs and symptoms, and apparently complete but temporary clinical recovery frequently lasts for two or three years. Until fairly recently the overall survival rates after five and 10 years were low in most series (Schulz et al.). Local recurrence is the rule and is frequently accompanied, or shortly followed, by extensive dissemination through the cerebrospinal fluid pathways. Bloom and his associates report the unusually high survival rate of 32 percent after five years, and 26 percent after 10 years, after maximal surgical extirpation followed by radiation of the cerebrospinal axis. An even higher 5-year survival figure of 75 percent has recently been recorded in a small group of patients by Hope-Stone. The series reported by Bloom and his associates shows a definite relationship between the age of the patients when first treated and the incidence of fatal recurrence of the tumor. This relationship follows Collins' law for embryonal tumors, in which the critical period of risk of recurrence is calculated as equal to the patient's age at the time of treatment plus nine months for gestation. This important observation requires confirmation. Survival rates of 10 to 20 years have been recorded for some cases, mostly with tumors in the lateral lobes in adults. It seems that the desmoplastic type of medulloblastoma in adults has a more favorable prognosis than the classic midline medulloblastomas in children (Chatty and Earle).

DIFFERENTIAL DIAGNOSIS. In the overwhelming majority of cases a highly cellular tumor composed of closely packed hyperchromatic cells in the posterior fossa

of a child is diagnostic of medulloblastoma. The various histologic patterns, demonstrated in the microscopic descriptions of this tumor and its forms of growth and spread, illustrate the diversity of the cellular architecture that may result from the invasion of various parts of the cerebellar cortex and especially of the subarachnoid space. One should guard against a diagnosis of sarcoma on the basis of an abundant connective tissue fiber network when spread to the subarachnoid space has occurred. In this context the existence of a primary circumscribed arachnoidal sarcoma of the cerebellum must be repudiated. Primary sarcomas may indeed arise from the cerebellar leptomeninges as from the meninges elsewhere in the intracranial cavity, but they do not possess a distinctive pattern that separates them from those above the tentorium. The characteristic reticulin-free islands are not a feature of authentic sarcomas arising in the brain (or, for that matter, anywhere else in the body), and the rare polymorphic cell sarcomas that may occasionally be confused with cerebellar medulloblastomas usually occur in very young subjects, and not in the older age groups. Paradoxically they often produce only relatively small amounts of fibrous connective tissue.

The presence of Homer Wright rosettes is diagnostic of medulloblastomas, not of ependymomas. The latter are only exceptionally malignant, and even then the rosettes are of ependymal type (fig. 129). Other anaplastic or primitive gliomas with which the medulloblastoma might be confused are the microcellular glioblastoma, some malignant forms of oligodendroglioma, the rare cerebral neuroblastoma, and the pineoblastoma. From the cytologic point of view the differential diagnosis between these various neoplasms may be virtually impossible in a limited biopsy. It is widely accepted that medulloblastomas arise solely in the cerebellum, and therefore tumors of similar morphologic structure in other situations should be classified differently; most would probably be either cerebral neuroblastomas or oligodendrogliomas. The pineoblastoma is cytologically indistinguishable from the medulloblastoma; identical rosettes are present in both (fig. 282).

Difficulty may occasionally be encountered in adults in distinguishing between a diffuse malignant cerebellar astrocytoma and a medulloblastoma, especially since both may demonstrate secondary structures. Such an anaplastic astrocytoma may behave biologically like a medulloblastoma, with the development of recurrences that may or may not be accompanied by cerebrospinal metastases. Finally, diagnostic confusion may arise in adult cases between medulloblastomas and highly anaplastic metastatic carcinomas, such as oat cell carcinoma from the bronchus, or infiltration by lymphosarcoma.

References

Bailey, P., and Cushing, H. Medulloblastoma cerebelli, common type of mid-cerebellar glioma of childhood. Arch. Neurol. Psychiat. 14:192–224, 1925.

Bickerstaff, E. R., Connolly, R. C., and Woolf, A. L. Cerebellar medulloblastoma occurring in brothers. Acta Neuropath. 8:104–107, 1967.

Bloom, H. J. G., Wallace, E. N. K., and Henk, J. M. The treatment and prognosis of medulloblastoma in children. A study of 82 verified cases. Amer. J. Roentgen. 105:43–62, 1969.

Bodian, M., and Lawson, D. The intracranial neoplastic diseases of childhood. A description of their natural history based on a clinico-pathological study of 129 cases. Brit. J. Surg. 40:368–392, 1953.

Bofin, P. J., and Ebels, E. A case of medullomyoblastoma. Acta Neuropath. 2:309–311, 1963.

Borello, E. D., and Gorlin, R. J. Melanotic neuroectodermal tumor of infancy—a neoplasm of neural crest origin. Report of a case associated with high urinary excretion of vanilmandelic acid. Cancer 19:196–206, 1966.

Chatty, E. M., and Earle, K. M. Medulloblastoma. A report of 201 cases with emphasis on the relationship of histologic variants to survival. Cancer, in press, 1971.

Drachman, D. A., Winter, T. S., III, and Karon, M. Medulloblastoma with extracranial metastases. Arch. Neurol. 9:518–530, 1963.

Durity, F. A., Dolman, C. L., and Moyes, P. D. Ganglioneuroblastoma of the cerebellum. Case report. J. Neurosurg. 28:270–273, 1968.

Escourolle, R., and Poirier, J. L'ultrastructure du médulloblastome cérébelleux. Ann. Anat. Path. 12:121–136, 1967.

Fowler, M., and Simpson, D. A. A malignant melanin-forming tumour of the cerebellum. J. Path. Bact. 84:307–311, 1962.

Fujita, S. Quantitative analysis of cell proliferation and differentiation in the cortex of the postnatal mouse cerebellum. J. Cell Biol. 32:277–288, 1967.

Hope-Stone, H. F. Results of treatment of medulloblastomas. J. Neurosurg. 32:83–88, 1970.

Kadin, M. E., Rubinstein, L. J., and Nelson, J. S. Neonatal cerebellar medulloblastoma originating from the fetal external granular layer. J. Neuropath. Exp. Neurol. 29:583–600, 1970.

Kane, W., and Aronson, S. M. Gangliogliomatous maturation in cerebellar medulloblastoma. Acta. Neuropath. 9:273–279, 1967.

Kershman, J. The medulloblast and the medulloblastoma: a study of human embryos. Arch. Neurol. Psych. 40: 937–967, 1938.

Kersting, G. Tissue Culture of Human Gliomas, pp. 165–202. In: Progress in Neurological Surgery, Vol. 2. (Eds.) Krayenbühl, H., Maspes, P. E., and Sweet, W. H. Chicago: Year Book Medical Publishers, Inc., 1968.

Lumsden, C. E. The Study by Tissue Culture of Tumours of the Nervous System, Chap. 14, pp. 334–420. In: Russell, D. S., and Rubinstein, L. J. Pathology of Tumours of the Nervous System, 3d ed. London: Edward Arnold, 1971.

Makeever, L. C., and King, J. D. Medulloblastoma with extracranial metastasis through a ventriculovenous shunt. Report of a case and review of the literature. Amer. J. Clin. Path. 46:245–249, 1966.

Oberman, H. A., Hewitt, W. C., Jr., Kalivoda, A. J. Medulloblastomas with distant metastases. Amer. J. Clin. Path. 39:148–160, 1963.

Oppenheimer, D. R. The effect of irradiation on a medulloblastoma. J. Neurol. Neurosurg. Psychiat. 32:94–98, 1969.

Raaf, J., and Kernohan, J. W. Relation of abnormal collections of cells in posterior medullary velum of cerebellum to origin of medulloblastoma. Arch. Neurol. Psych. 52:163–169, 1944.

Ringertz, N., and Tola, J. H. Medulloblastoma. J. Neuropath. Exp. Neurol. 9:354–372, 1950.

Rubinstein, L. J. Extracranial metastases in cerebellar medulloblastoma. J. Path. Bact. 78:187–195, 1959.

————, and Northfield, D. W. C. The medulloblastoma and the so-called "arachnoidal cerebellar sarcoma". A critical re-examination of a nosological problem. Brain 87:379–412, 1964.

Scherer, H. J. Structural development in gliomas. Amer. J. Cancer 34:333–351, 1938.

Schulz, M. D., Wang, C-C., Zinninger, G. F., and Tefft, M. Radiotherapy of Intracranial Neoplasm, pp. 318–370. In: Progress in Neurological Surgery, Vol. 2. (Eds.) Krayenbühl, H., Maspes, P. E., and Sweet, W. H. Chicago: Year Book Medical Publishers, Inc., 1968.

Stevenson, L., and Echlin, F. Nature and origin of some tumors of the cerebellum-medulloblastoma. Arch. Neurol. Psychiat. 31:93–109, 1934.

Tola, J. S. The histopathological and biological characteristics of primary neoplasms of the cerebellum and the fourth ventricle, with some aspects of their clinical picture, diagnosis, and treatment (on the basis of 71 verified cases). Acta Chir. Scand., Supp. 164:1–112, 1951.

Vaughn, J. E., and Peters, A. Electron microscopy of the early postnatal development of fibrous astrocytes. Amer. J. Anat. 121:131–151, 1967.

Voigt, W. H. Elektronenmikroskopische Beobachtungen an menschlichen Medulloblastomen. Deutsch. Z. Nervenheilk. 192:290–309, 1968.

Willis, R. A. Pathology of Tumours, 3d ed. London: Butterworth & Co., Ltd., 1960.

Wilson, C. B. Medulloblastoma. Current views regarding the tumor and its treatment. Oncology 24:273–290, 1970.

Wright, J. H. Neurocytoma or neuroblastoma, a kind of tumor not generally recognized. J. Exp. Med. 12: 556–561, 1910.

NEUROBLASTOMA

DEFINITION AND CYTOGENESIS. This rare and somewhat controversial tumor is derived from and composed of ganglion cell precursors. Maturation to adult cell forms is sometimes seen, but is more often lacking. Frequently these tumors are difficult to recognize and must be left unclassified.

It is likely that some neoplasms that were interpreted as cerebral medulloblastomas should be reclassified as neuroblastomas. The argument is admittedly equivocal since some neuropathologists are inclined to regard the cerebellar medulloblastoma as a form of neuroblastoma arising from the internal granular neurons. The reasons in favor of maintaining a taxonomic separation between the cerebellar medulloblastoma and the cerebral neuroblastoma are twofold: first, the cerebellar medulloblastoma is a well established and common entity with clear-cut clinical and pathologic characteristics, and its name is too firmly entrenched to be replaced; the cerebral neuroblastoma, on the other hand, is an extremely rare tumor about which there is still considerable uncertainty of its incidence, clinical data, and pathologic features. Second, there is enough inferential evidence to assign the origin of the cerebellar medulloblastoma to a particular site of neurocytogenesis in the neuraxis, and evidence of bipotential or multipotential differentiation is sometimes demonstrable; neither of these propositions is true for the cerebral neuroblastoma.

INCIDENCE, SITE, AND CLINICAL DATA. Cerebral neuroblastomas may arise anywhere in the hemispheres. They usually present as rapidly growing neoplasms in childhood. In my experience the age incidence ranges from 2½ months to 9 years. The sex incidence is about equally divided. To our knowledge no data are yet available on the demonstration of catecholamines in these tumors in children, or on the excretion of these amines or their degraded metabolites in the urine, such as are found in neuroblastomas (sympathicoblastomas) arising from the adrenal or sympathetic ganglia.

GROSS. Characteristically neuroblastomas are well defined, even crisply demarcated in places. They are often lobulated, with soft granular, pearly gray cut surfaces, usually with extensive areas of hemorrhage, necrosis, and gelatinous cystic degeneration. Secondary attachment to the dura is occasionally found.

MICROSCOPIC. These tumors are highly cellular. The overall histologic pattern may be remarkably variable, and usually the cytologic differentiation is so poor that the diagnosis of neuroblastoma is easily overlooked. The tumor is composed either of compact sheets of closely packed cells without any special orientation or of an arrangement in small clumps, short trabeculae, or irregular syncytial groups (fig. 167). Between the cell masses poorly cellular areas are found which may show a delicately fibrillated eosinophilic matrix, or often contain large amounts of fibrous connective tissue. Under high power the cells usually have spheroidal or oval, occasionally fusiform, nuclei with a pale vesiculated nucleoplasm, a delicate nuclear membrane, and often a small conspicuous nucleolus (fig. 168). The cytoplasm is usually ill-defined, but may be distinctly polar. The polar extensions may be directed either toward a central blood vessel or toward other cells to form rather poorly defined rosettes (fig. 169). These are very uncommon. Mitotic figures are usually numerous.

CEREBRAL NEUROBLASTOMA

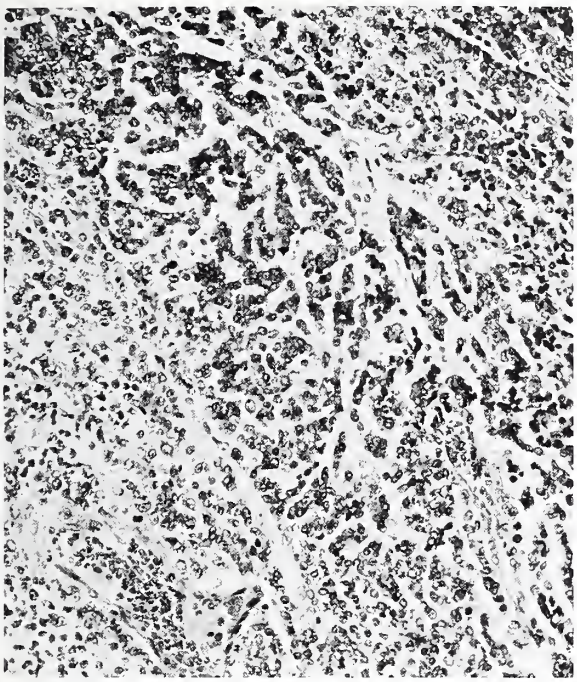

Figure 167. This is a low power view of a sharply demarcated right parietal tumor in a 4-year-old girl, separate from the ventricle. There is a cellular arrangement in small clusters and trabeculae. × 165.

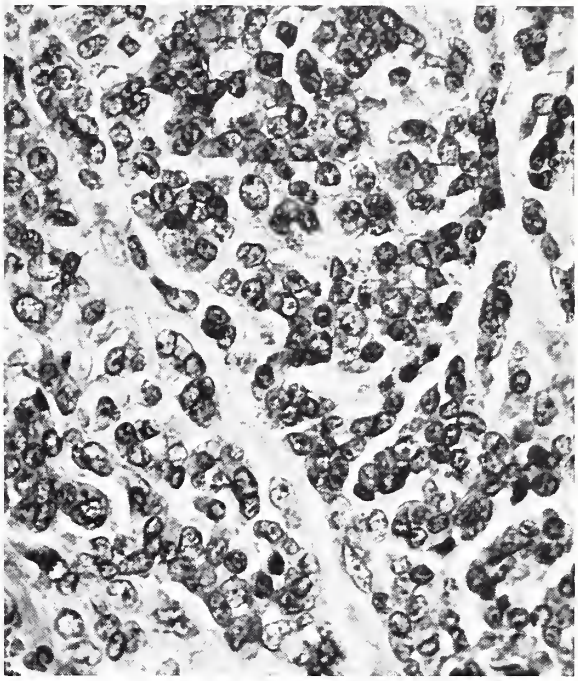

(Figures 167 and 168 from same case)

Figure 168. This high power view reveals small cells with poorly defined cytoplasm, distinct oval or spherical nuclei, and often conspicuous small central nucleoli. × 440.

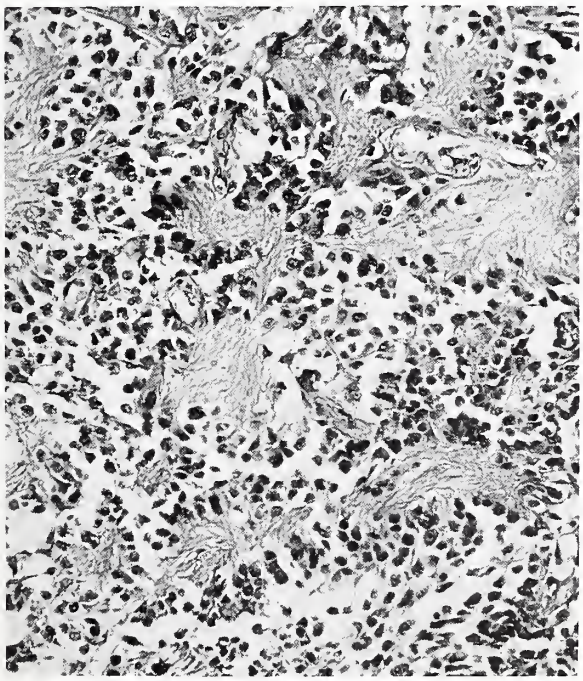

Fig. 169

CEREBRAL NEUROBLASTOMA ROSETTES

Figure 169. These polar cells with fibrillated extensions arranged in rosette formations were found in a cerebral neuroblastoma in a 4-year-old boy. × 180.

The fibrous connective tissue is variable, but may sometimes be extraordinarily abundant (fig. 170). This feature distinguishes the neuroblastoma from other primitive neuroectodermal neoplasms.

In most cases the cells are so undifferentiated that they are refractory to silver impregnation technics for neuroblastic processes and neurofibrils. Occasionally these can be demonstrated in frozen sections. Evidence of further differentiation toward adult neurons is again very uncommon. Where present, gradual transitions may be seen from the small undifferentiated elements to more mature nerve cells, analogous to ganglioneuroblastomas of the autonomic nervous system (figs. 171, 172). In the more differentiated areas the tumor is less densely cellular, and its neuroectodermal fibrillated matrix becomes evident.

CEREBRAL NEUROBLASTOMA

Figure 170. Abundant connective tissue stroma is apparent in this cerebral neuroblastoma. The stroma is markedly increased where the tumor invades the leptomeninges (below). Silver stain for reticulin. × 145.

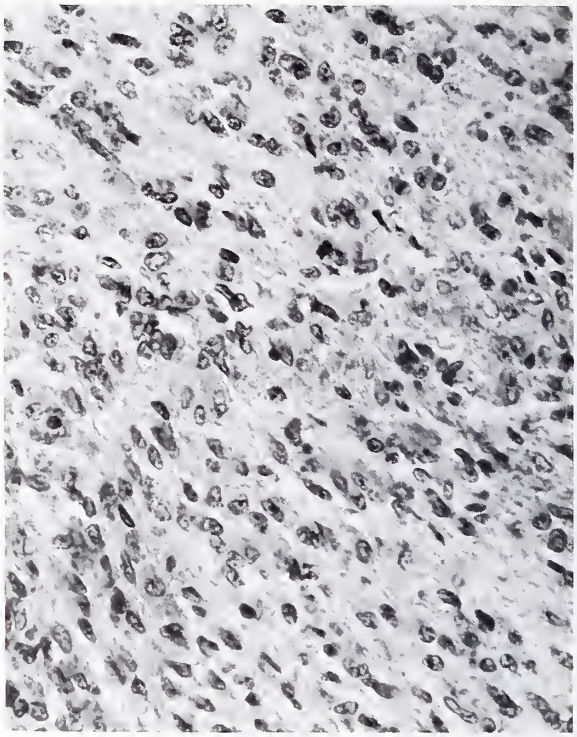

DIFFERENTIATING CEREBRAL NEUROBLASTOMA

(Figures 171 and 172 from same case)

Figure 171. This area from a frontoparietal tumor in a 7-month-old infant reveals a highly cellular tumor with poorly differentiated spindle-shaped nuclei forming a streaming pattern on a delicately fibrillated matrix. × 360.

GROWTH AND SPREAD. A useful diagnostic feature of these tumors is that, unlike most other forms of malignant neuroectodermal neoplasms, cerebral neuroblastomas often show a relatively abrupt transition from the adjacent brain. Microscopic infiltration is, however, usually seen in some areas further afield. A marked hyperplastic neuroglial reaction similar to that which may be stimulated by an invasive sarcoma is sometimes seen. This feature also distinguishes the neuroblastoma from other forms of malignant neuroectodermal tumor. The production of fibrous connective tissue by the tumor stroma (fig. 170) may, by analogy with the desmoplastic forms of medullo-

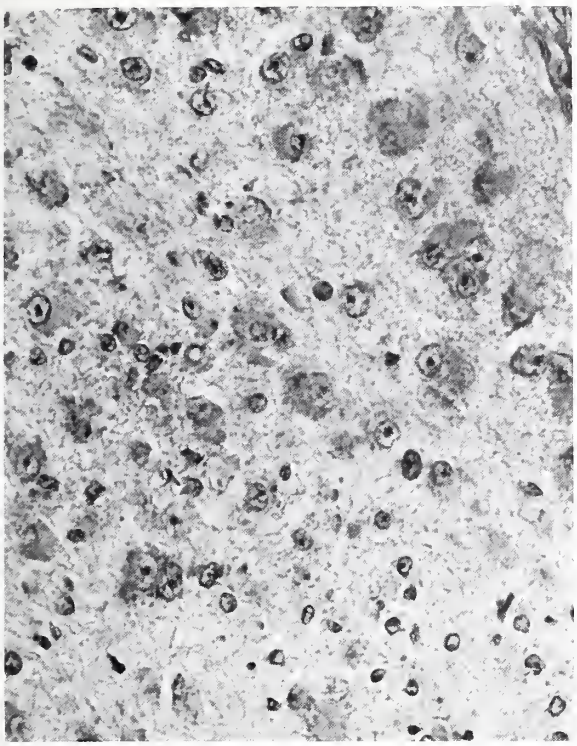

DIFFERENTIATING CEREBRAL NEUROBLASTOMA

(Figures 171 and 172 from same case)

Figure 172. A less densely cellular area from an adjacent field shows differentiation into mature ganglion cells. × 360.

blastoma described on page 143, be particularly abundant when the growth invades the leptomeninges (Miller and Ramsden).

The latter is a frequent event and further spread throughout the cerebrospinal fluid pathways may occur. It has been seen four times in my experience.

TREATMENT. The treatment for these rare tumors is radical surgical excision followed by radiation. Its primitive character and its kinship to the cerebellar medulloblastoma and to the much more common peripheral neuroblastoma make it likely that it is highly radiosensitive.

PROGNOSIS. There is no real information on the prognosis of these tumors. Their primitive cytologic characteristics would lead one to expect them to behave as highly malignant neoplasms. However, differentiation to mature ganglion cells is sometimes seen, and a few cases have been described in which recurrence has been delayed for several years, with maturation of the tumor to a gangliocytoma (Kernohan et al.; Liss).

DIFFERENTIAL DIAGNOSIS. As evident in the preceding description the differential diagnosis of this primitive tumor is often one of great difficulty. In the absence of available material for specific metallic impregnation, or of evidence of maturation to ganglion cells, it often remains somewhat speculative. While several of the features previously described separate it from other forms of malignant glioma, especially those of the astrocytic series, diagnostic difficulties are encountered in distinguishing the neuroblastoma from poorly differentiated forms of oligodendroglioma, and especially from undifferentiated primary sarcomas. The age incidence, the presence of abundant connective tissue fibers, and the behavior of the reactive neuroglia are similar in both tumors. In the absence of other cytologic criteria that may help toward a definitive diagnosis, it is often preferable to leave these rare neoplasms in children unclassified. Where, however, the connective tissue stroma is scanty or obviously related to the blood vessels, the diagnosis of cerebral neuroblastoma may be entertained with greater confidence even in the absence of neuronal differentiation.

References

Kernohan, J. W., Learmonth, J. R., and Doyle, J. B. Neuroblastomas and gangliocytomas of the central nervous system. Brain 55:287–310, 1932.

Liss, L. Neuroblastoma (malignant gangliocytoma) of the parietal lobe. J. Neurosurg. 17:529–536, 1960.

Miller, A. A., and Ramsden, F. A cerebral neuroblastoma with unusual fibrous tissue reaction. J. Neuropath. Exp. Neurol. 25:328–340, 1966.

GANGLIONEUROMA AND GANGLIOGLIOMA

SYNONYMS AND RELATED TERMS: Gangliocytoma; neuroastrocytoma.

DEFINITION AND CYTOGENESIS. This somewhat controversial group includes tumors in which nerve cells showing various stages of differentiation, most of them mature, participate in the neoplastic process. They are rarer than their counterparts originating in the peripheral nervous system and differ essentially from the peripheral ganglioneuromas in that the latter possess a stroma of capsular and Schwann cells. By contrast the central nervous system tumors have a stroma composed of glial cell elements, usually astrocytic, and these may to a variable extent display concomitant neoplastic changes also. In practice, therefore, neoplasms composed of nerve cell elements derived from the central nervous system are frequently mixed tumors, for which the term **ganglioglioma** was first introduced in the neuropathologic literature by Courville. There is a great deal of variation in the participation of the two cell components from case to case, and even in different areas of the same lesion. It is therefore unrealistic to draw too rigid a distinction between ganglioneuroma and ganglioglioma. Moreover both display common features in age incidence, selective localization, and mode of growth. The only meaningful difference lies in their malignant potential. In very rare cases, anaplastic transformation may occur, which is then confined to the glial element.

Since the mature neuron is a postmitotic cell it is likely that, similar to their counterparts in the peripheral nervous system, ganglion cell tumors arise from primitive neuroblastic elements that have undergone progressive maturation concurrently with the growth of the neoplasm. On the other hand, apart from the very rare examples of cerebral neuroblastoma that show differentiation into adult ganglion cells (p. 156), recognizable nerve cell precursors are rare in mature ganglioneuromas and gangliogliomas and if present they are usually difficult to identify.

Since nests of abnormal neurons similar morphologically to ganglioneuromas are occasionally found in ectopic situations, it is often postulated that these tumors are essentially **hamartomatous.** There is some inferential support for this in the frequent heterotopic location of ganglioneuromas and gangliogliomas and in the reported association of focal epilepsy with cellular glial or neuronal malformations in which evidence of neoplastic transformation is lacking (Cavanagh), and which in some circumstances may be heterotopic (Layton). Finally there are examples of extremely diffuse gangliocytoma for which the term **dysplastic** has been coined, and which tend to occur particularly in the cerebellum. Nevertheless, despite the collective evidence that points to a hamartomatous origin of many ganglioneuromas and gangliogliomas, they behave clinically and to some extent pathologically as expanding neoplastic lesions. An informative review of these tumors and of the older cases in the literature will be found in a paper by Courville and Anderson.

NATURAL HISTORY AND CLINICAL DATA. Ganglioneuromas and gangliogliomas are usually slowly growing, circumscribed lesions associated with a clinical history of protracted focal irritative symptoms. Those located in the region of the

third ventricle and hypothalamus may cause signs referable to the latter, such as obesity, diabetes insipidus, or abnormal appetite (bulimia); those situated in the motor cortex or in the temporal lobe may give rise to long-standing focal epilepsy which, in the temporal lobe, is of a characteristic type. An example of their slow growth is illustrated by the case of Steegmann and Winer, in which a cystic, gray-brown, inferior temporal ganglioglioma was found in a 17-year-old boy who had had a 4-year history of temporal seizures, and died of drowning.

INCIDENCE. These tumors are rare and occur most often in children and young adults, about 60 percent presenting under the age of 30.

SITES. Their most frequent site is the floor of the third ventricle and the hypothalamic region; another characteristic site is the temporal lobe, but the frontal lobe and basal ganglia may also be involved. The spinal cord is more rarely affected. Focal forms are exceptional in the cerebellum.

GROSS. The tumor is usually small, firm, and well defined, with finely granular homogeneous, but sometimes highly vascular, cut surfaces (fig. 173). Foci of calcification and small cysts are frequent; occasionally the tumor consists mainly of a single large cyst.

MICROSCOPIC. The histologic appearances are extremely variable, and depend largely on the preponderant cell component. In some cases the nerve cells dominate the picture, and the glial elements are purely stromal. In others neuroglial cells are so numerous that the neoplasm may at first be interpreted as an astrocytoma, and only careful microscopic search reveals isolated abnormal neurons in ectopic situations. In this context, however, it is important to remember the frequency with which normal preexisting neurons may remain identifiable as surviving cell elements in diffusely infiltrating astrocytomas; the diagnostic problems involved in the recognition of ganglion cell tumors have been discussed in detail elsewhere (Russell and Rubinstein, 1971).

In the ganglioneuromatous areas, ganglion cells are recognized as neoplastic because of abnormalities in cytoarchitecture, the loss of normal cellular lamination, the fact that the cell processes are misaligned or randomly oriented, and the inequality of nerve cell size and shape, many of which appear of giant dimension (fig. 174). The nuclei are typically neuronal, that is, they are vesiculated and possess prominent nucleoli; they are often eccentrically situated in the cell body, and occasionally the cytoplasm is binucleated (pl. V-D). The identification of Nissl substance is of obvious diagnostic importance, but it is often unevenly distributed in the perikaryon, and even occasionally absent altogether in the plane of section. Nevertheless it is usually demonstrable at least in some areas of the perikaryon (pl. V-D). Further proof of the ganglionic nature of the neoplastic cells rests on successful silver impregnations with the appropriate methods for nerve cells, both on paraffin and frozen sections, which usually demonstrate to their best advantage the grotesque and bizarre shape of the neurons and the configuration of abnormal tortuous nerve fibers (fig. 175). These technics may also reveal more primitive cell forms with unipolar or bipolar cell processes that may justifiably be interpreted as neuroblastic.

GANGLIOGLIOMA

(Figures 46, 173–178, and Plate V-D from same case)

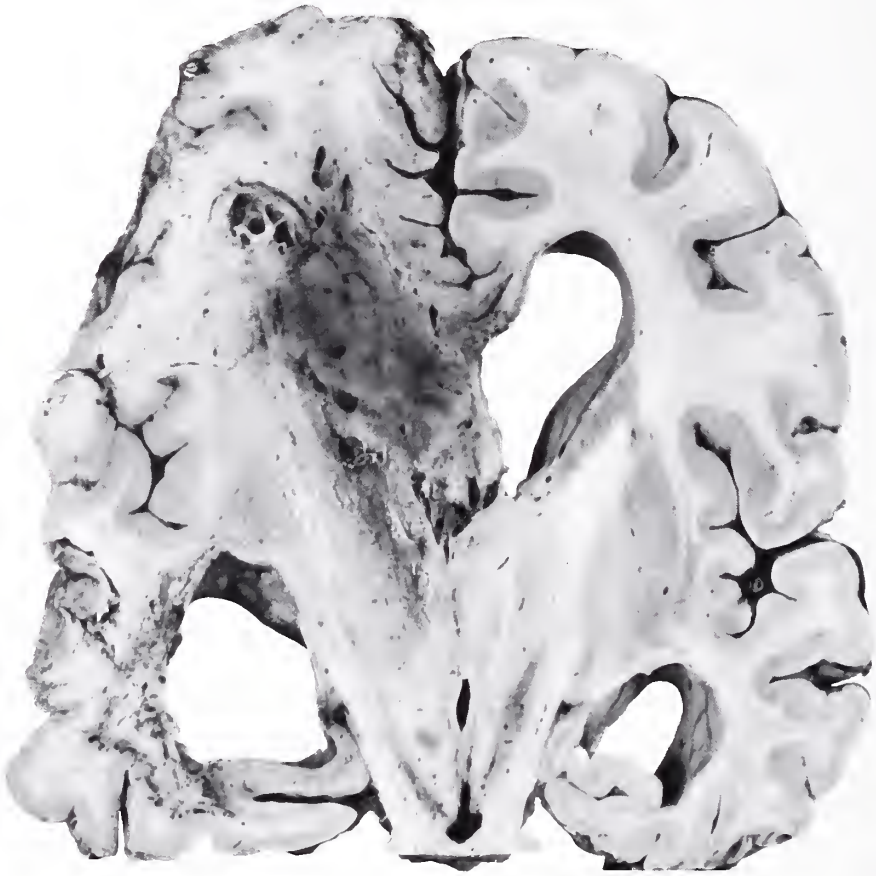

Figure 173. This 49-year-old woman had a left intraventricular ganglioneuroma removed 23 years before death. Postmortem examination revealed massive recurrence of the original growth showing as dark gray intraventricular tumor in the specimen. Adjacent was the extensive glioma that occupies the septum pellucidum and the fornix in this slice, which more posteriorly had dedifferentiated to the picture of glioblastoma multiforme. The cortical atrophy over the left frontal and temporal cortex is presumably due to vascular compromise that occurred at the time of the second operation, approximately four months before death. (Fig. 2a from Russell, D. S., and Rubinstein, L. J. Ganglioglioma: A case with long history and malignant evolution. J. Neuropath. Exp. Neurol. 21:185–193, 1962).

Another relatively unheeded feature is the considerable prominence of the fibrous connective tissue and vascular stroma, a characteristic that strongly contrasts with its absence in those parts of the tumor that consist largely or solely of neuroglial elements. Silver impregnations for reticulin frequently disclose an abundant connective tissue stroma that separates the ganglion cells into nests (fig. 176) or may at times be so intense as to form a thick intersecting intercellular network (fig. 177). Other areas may show a great increase of vascularity and a close packing of small thin-walled capillary blood vessels, producing a marked telangiectatic pattern (fig. 178).

Other cells present are either obviously astrocytic, or in some cases largely oligodendroglial. In addition many elements with small round nuclei, a crisp nuclear membrane, and a delicate chromatin net are found that usually defy identification, but are presumably either ganglion cell precursors or small adult granular neurons. Occasionally a fortunate silver impregnation will demonstrate the neuroblastic nature of these cells.

The cytologic features of the ganglionic areas are almost always benign. Although the nuclei are often hyperchromatic and binucleate forms may be present, mitotic figures are not seen in cells that are easily identified as neuronal. When malignant cytologic features are seen, they are virtually always clearly referable to the neuroglial elements.

GROWTH AND SPREAD. TRANSITIONAL FORMS WITH NEUROBLASTOMAS. MALIGNANT CHANGES. As already noted these tumors grow slowly, usually by expansion only. Transitional forms between the ganglioneuroma or ganglioglioma on the one hand, and the more primitive neuroblastoma on the other are very uncommon, but are occasionally encountered. In these cases, by analogy with the ganglioneuroblastomas of the peripheral nervous system, a mixture of cell elements is found which ranges from highly primitive neuroblasts to well differentiated ganglion cells; essentially these tumors may be regarded as differentiating neuroblastomas (p. 156). Thus there exist a few acceptable ganglion cell tumors in which the anaplastic elements appear solely referable to more primitive neuroblastic forms. Liss described a malignant gangliocytoma (or neuroblastoma) in a man of 31, which recurred 14 years later with a similar histologic appearance. Kernohan and his associates reported a neuroblastoma in a 16-year-old girl, in whom the recurrence six years later had the picture of a gangliocytoma. On the other hand, subsequent malignant transformation in a mature gangliocytoma is extremely uncommon, and when it occurs it is found in the neuroglial portion of the neoplasm. For example, a woman had a ganglioneuroma removed from the left frontal horn at the age of 26, and after a long interval of arrest of the growth, it progressed to the terminal picture of glioblastoma multiforme 23 years later (Russell and Rubinstein, 1962). The glioblastoma (fig. 46) was situated mostly in the caudal portion of the corpus callosum and extended bilaterally into the occipital white matter and the basal ganglia, whereas the more anterior part of the tumor (figs. 173–178; pl. V-D) consisted largely of the benign ganglioneuromatous element.

GANGLIOGLIOMA

(Figures 46, 173–178, and Plate V-D from same case)

Figure 174. This is the ganglioneuromatous portion of the tumor, composed of large ganglion cells with prominent nuclei. Nissl substance is not easily seen in the cells of this photomicrograph, but is well demonstrated in an adjacent field (pl. V-D). × 120. (Fig. 3a from Russell, D. S., and Rubinstein, L. J. Ganglioglioma: A case with long history and malignant evolution. J. Neuropath. Exp. Neurol. 21:185–193, 1962).

Figure 175. Strongly positive silver impregnation of abnormal neurons and tortuous nerve fibers is shown. Bielschowsky stain. × 265. (Fig. 3d from Russell, D. S., and Rubinstein, L. J. Ganglioglioma: A case with long history and malignant evolution. J. Neuropath. Exp. Neurol. 21:185–193, 1962).

Figure 176. An abundant reticulin network separates nests of ganglion cells. Silver stain for reticulin. × 115. (Fig. 3b from Russell, D. S., and Rubinstein, L. J. Ganglioglioma: A case with long history and malignant evolution. J. Neuropath. Exp. Neurol. 21:185–193, 1962)

Figure 177. More abundant connective tissue proliferation is seen in another part of the same tumor. Silver stain for reticulin. × 70.

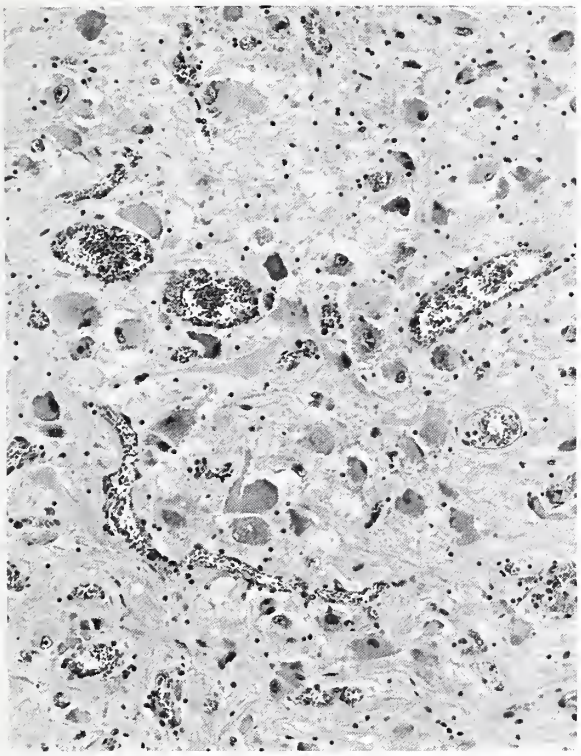

Fig. 174

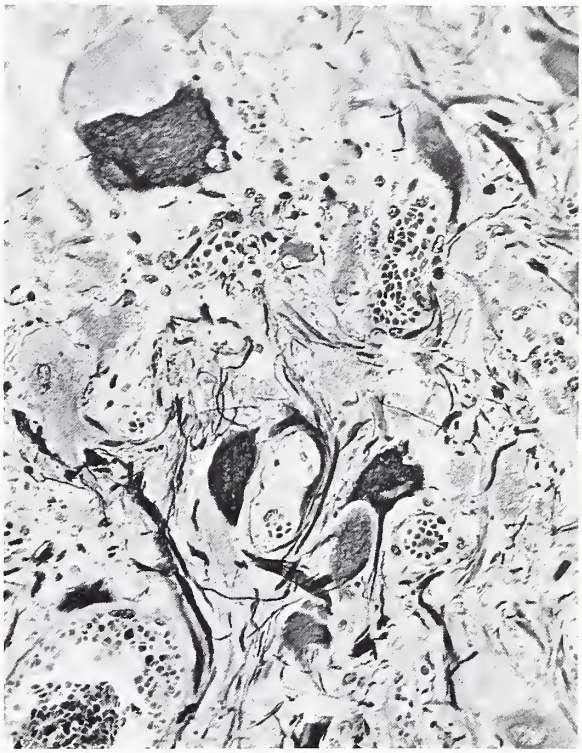

Fig. 175

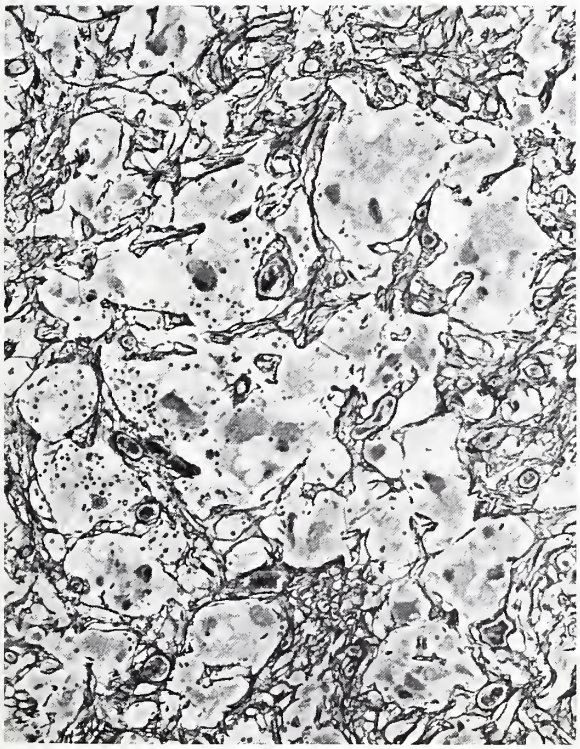

Fig. 176

Fig. 177

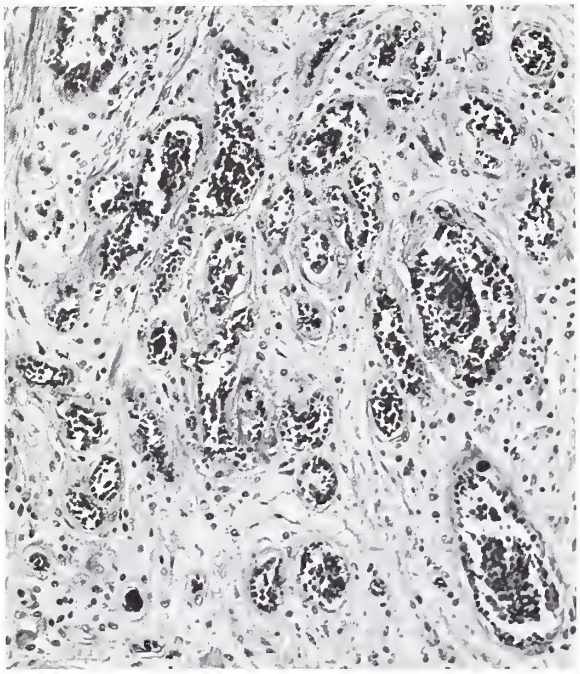

GANGLIOGLIOMA, VASCULAR PATTERN

(Figures 46, 173–178, and Plate V-D from same case)

Figure 178. A telangiectatic pattern of blood vessels is evident in the ganglionic portion of the tumor. PTAH. × 165.

VARIANTS

Dysplastic Gangliocytoma of the Cerebellum

SYNONYMS AND RELATED TERMS: Gangliomatosis of the cerebellum: diffuse hypertrophy of the cerebellar cortex; Purkinjeoma; Lhermitte-Duclos disease.

This curious lesion involves the cerebellar cortex and combines the picture of a congenital malformation and a neoplasm.

GROSS. The cerebellar folia are markedly thickened and enlarged (fig. 179). Usually only a segment of the cortex is involved, but occasionally the lesion may be more extensive (fig. 179). Clinically it makes its appearance in adult life only, and presents as a gradually increasing space-occupying mass in the posterior fossa requiring decompression and surgical extirpation.

DYSPLASTIC GANGLIOCYTOMA OF THE CEREBELLUM

(Figures 179 and 180 from same case)

Figure 179. The gross appearance of the cerebellum shows thickened enlarged cortical folia in a mentally retarded 19-year-old man with internal hydrocephalus and megalencephaly (weight of brain, 2150 gm.), (Courtesy of Dr. L. B. Rorke, Philadelphia, Pa.)

MICROSCOPIC. The abnormal folia are composed of a very thick outer layer of well developed myelinated or unmyelinated nerve fibers (fig. 180) and an inner cellular layer containing many abnormal neurons, some of which bear a superficial resemblance to Purkinje cells (fig. 181). The arrangement of the nerve fibers in the greatly thickened molecular layer corresponds to that of the normal granular neurons. The latter are usually absent or greatly reduced, and the central white matter is often absent. Isolated examples of this disease have repeatedly been reported; the most informative discussions with reviews of previous cases are those by Oppenheimer, by Hallervorden and, more recently, by Ambler and associates. The condition is associated with

DYSPLASTIC GANGLIOCYTOMA OF THE CEREBELLUM

(Figures 179 and 180 from same case)

Figure 180. A low power view of this myelin preparation shows a pale thickened outer layer (unmyelinated nerve fibers) and a slightly darker uneven inner layer (abnormal neurons) in the abnormal segments of the cerebellar cortex. Myelin stain. × 4. (Courtesy of Dr. L. B. Rorke, Philadelphia, Pa.)

other congenital malformations, such as leontiasis ossia, hemihypertrophy, partial gigantism and, in over half the cases, megalencephaly (figs. 179, 180). The cases reported by Ambler and associates, who include a survey of 34 other examples, are of special interest in that they were familial (mother and son). Oppenheimer, Ambler, and others regard the lesion as essentially a hypertrophy of the internal granular neurons, and in agreement with this view Hallervorden has revived an older speculation that this might be an acquired compensatory change in the granular neurons derived from the ventricular matrix layer, resulting from a focal absence or a maldevelopment of parts of the fetal external granular layer.

Dysplastic Gangliocytoma of the Cerebrum

A diffuse form of gangliocytoma affecting the cerebral cortex and characterized by a unilateral megalencephaly has also been reported (Dom and Brucher).

TREATMENT. The treatment for ganglioneuromas and gangliogliomas is surgical excision. These tumors are so rare that no data are available whether postoperative radiation is indicated or not. There is no evidence on cytologic grounds that such a tumor would be radiosensitive; nevertheless postoperative radiation is often given in these cases.

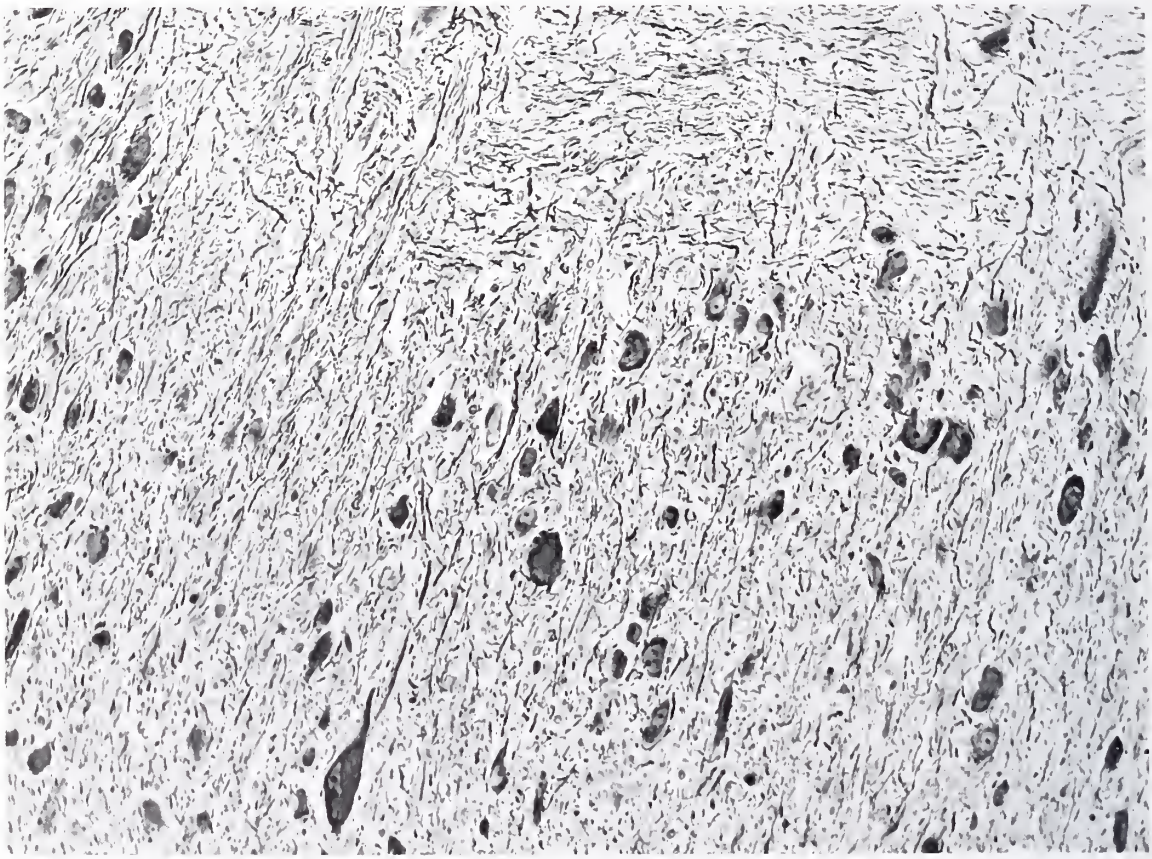

DYSPLASTIC GANGLIOCYTOMA OF THE CEREBELLUM

Figure 181. Large irregularly distributed ganglion cells replace the granular layer and direct their processes toward the greatly thickened molecular layer (above). Luxol fast blue—Bodian silver impregnation. × 175.

PROGNOSIS. As far as information is available, the prognosis is favorable. Recurrence may occur after many years. Occasionally malignant recurrence may take place many years after removal of the original tumor with the terminal picture of a glioblastoma (Russell and Rubinstein, 1962).

DIFFERENTIAL DIAGNOSIS. The most important differential diagnostic problem is centered on the recognition of truly neoplastic ganglion cells as opposed to the inclusion of normal nerve cells in astrocytomas that diffusely infiltrate the gray matter. In the latter the neurons are usually scattered evenly among the infiltrating tumor cells, while in ganglioneuromas the abnormal ganglion cells are often clustered together, with a marked disorientation of their cell processes. Another source of confusion lies in certain types of glial neoplasms with large vesiculated nuclei and prominent nucleoli that may mimic those of ganglion cells, in particular the subependymal giant cell astrocytoma associated with tuberous sclerosis and the giant cell glioblastoma. The demonstration of Nissl substance in the perikaryon and, if possible, of silver positive nerve fibers and cell processes is essential for the diagnosis of a ganglion cell tumor. Circumspection is required if overdiagnosis of this rare neoplasm is to be avoided.

References

Ambler, M., Pogacar, S., and Sidman, R. Lhermitte-Duclos Disease (granule cell hypertrophy of the cerebellum). Pathological analysis of the first familial case. J. Neuropath. Exp. Neurol. 28:622–647, 1969.

Cavanagh, J. B. On certain small tumours encountered in the temporal lobe. Brain 81:389–405, 1958.

Courville, C. B. Ganglioglioma, tumor of the central nervous system; review of the literature and report of two cases. Arch. Neurol. & Psychiat. 24:439–491, 1930.

———, and Anderson, F. M. Neuro-gliogenic tumors of the central nervous system. Report of two additional cases of ganglioglioma of the brain. Bull. Los Angeles Neurol. Soc. 6:154–176, 1941.

Dom, R., and Brucher, J-M. Hamartoblastome (Gangliocytome diffus) unilatéral de l'écore cérébrale associé à une dégénerescence soudanophile de la substance blanche du côté opposé. Rev. Neurol. 120: 307–318, 1969.

Hallervorden, J. Über die Hamartome (ganglioneurome) des Kleinhirns. Deutsch. Z. Nervenheilk. 179:531–563, 1959.

Kernohan, J. W., Learmonth, J. R., and Doyle, J. B. Neuroblastomas and gangliocytomas of the central nervous system. Brain 55:287–310, 1932.

Layton, D. D. Heterotopic cerebral gray matter as an epileptogenic focus. J. Neuropath. Exp. Neurol. 21:244–249, 1962.

Liss, L. Neuroblastoma (malignant gangliocytoma) of the parietal lobe. J. Neurosurg. 17:529–536, 1960.

Oppenheimer, D. R. A benign "tumour" of the cerebellum. Report on two cases of diffuse hypertrophy of the cerebellar cortex with a review of nine previously reported cases. J. Neurol. Neurosurg. Psychiat. 18:199–213, 1955.

Russell, D. S., and Rubinstein, L. J. Ganglioglioma: A case with a long history and malignant evolution. J. Neuropath. Exp. Neurol. 21:185–193, 1962.

———, and Rubinstein, L. J. Pathology of Tumours of the Nervous System, 3d ed. London: Edward Arnold, 1971.

Steegmann, A. T., and Winer, B. Temporal lobe epilepsy resulting from ganglioglioma. Report of an unusual case in an adolescent boy. Neurology 11:406–412, 1961.

TUMORS OF MESODERMAL TISSUES

TUMORS OF THE MENINGES AND THEIR DERIVATIVES

MENINGIOMAS

DEFINITION AND CYTOGENESIS. Meningiomas originate from cell elements that form the meninges and their derivatives in the meningeal spaces. They may arise from dural fibroblasts and pial cells, but most of them stem from arachnoid cells, in particular those packing the **arachnoid villi**, which protrude as finger-like projections into the walls of the dural veins and sinuses (fig. 182). The affinity of these tumors for the arachnoid villi has long been recognized, and accounts for the regularity with which meningiomas are attached to the dura. Moreover, the preferential sites of origin of meningiomas correspond very closely to the points where the villi are normally the most numerous; that is, along the major dural venous sinuses and at the exits of the spinal nerve roots from their meningeal sleeves. Meningiomas may, however, arise from arachnoid cells anywhere along the arachnoid membrane. The rare examples within the cerebral hemispheres are derived from stromal cells in the spaces that surround the perforating blood vessels. The intraventricular examples originate from meningeal cells in the intracerebral infoldings of the leptomeninges as they form the vela interposita and the stroma of the choroid plexuses. The exceptional extracalvarial and ectopic meningiomas presumably arise from ectopic arachnoid cell inclusions.

The embryogenic derivation of the meninges, which are regarded as neuroectodermal, is of no significance with respect to the structure of the meningiomas. The role of the arachnoid cell in the cerebrospinal fluid circulation and its function as part of the brain coverings require both epithelial and mesodermal properties, and this is clearly reflected in the morphologic components of the neoplasms to which it gives rise.

INCIDENCE AND ETIOLOGIC FACTORS. Meningiomas account for 13 to 18 percent of all primary intracranial tumors, and for approximately 25 percent of intraspinal tumors; in the latter group, they are second to the schwannomas (p. 206). They occur at any age, but are mainly neoplasms of adults, most cases occurring between 20 and 60, with a peak incidence around the age of 45. In the cranial cavity there is a preponderant occurrence in females relative to males with a ratio of 2 to 1; the spinal examples show an even greater incidence in females, with a ratio of 4 to 1.

Small symptomless meningiomas are quite often found incidentally postmortem in elderly subjects (fig. 188). They are mostly parasagittal; in contrast to the symptomatic tumors, they show no particular sex dominance (Wood et al.).

Meningiomas are the most frequent and best known intracranial tumors in animals (Lüginbühl et al.). Cats are apparently relatively often affected, with the curious observation that the tela choroidea of the third ventricle is a frequent site of incidence, which is in marked contrast to its exceptional occurrence in man.

NORMAL ARACHNOID VILLUS

Figure 182. This idealized drawing of the arachnoid villus is based on light and electron microscopic data. The inset, upper left, shows the superior sagittal sinus in cross section. The large drawing represents the area within the small rectangle in the inset.

A. Loosely organized subendothelial space in arachnoid villus.
B. Meshwork of arachnoid cells and collagen, forming the core of the villus.
C. Endothelium of the dural sinus reflected over the projecting villus and separating it from the sinus lumen.
D. Lumen of the superior sagittal sinus.
E. Dural wall of the sinus.
F. Arachnoid cells lining the inner aspect of the arachnoid membrane. These cells are indistinguishable from those in the stalk of the villus as it egresses through the dural wall of the sinus, or from the arachnoid cells filling the core of the villus. They are also similar to the cells distributed along the trabeculae of the subarachnoid space.
G. Subarachnoid space containing arachnoid cells, fibrous trabeculae, and a large blood vessel.
H. Pial covering by layer of pial cells.

Drawing by Miss J. Penkhus. Courtesy of Prof. D. S. Maxwell and Dr. A. L. Shabo. (Fig. 1 from Shabo, A. L., and Maxwell, D. S. The morphology of the arachnoid villi: a light and electron microscopic study in the monkey. J. Neurosurg. 29:451–463, 1968).

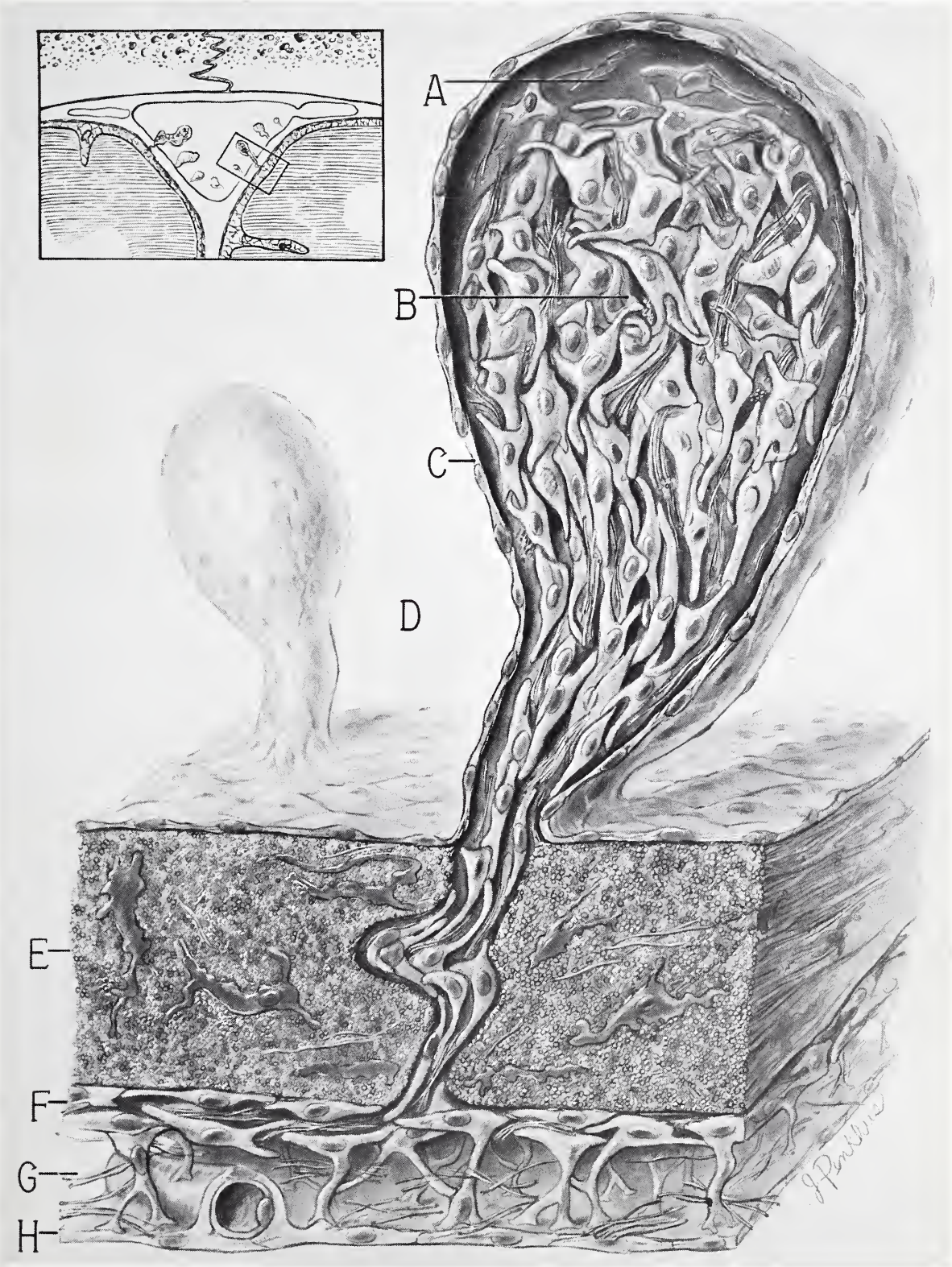

Fig. 182

In some cases previous trauma to the head has been regarded as a significant etiologic factor in intracranial meningiomas. This view was held in particular by Cushing and Eisenhardt, who stated that such a link could be convincingly established in over 30 percent of their cases. This theory has not gained wide acceptance, but is from time to time revived in case reports in which such a relationship, though still inferential, appears to rest on fairly substantive circumstantial evidence (Walsh et al.).

MULTIPLICITY AND ASSOCIATED LESIONS. Meningiomas are occasionally multiple, a feature which is sometimes demonstrated in the incidental finding of small examples postmortem in elderly subjects. Multiple cranial and spinal meningiomas associated with other tumors of the central nervous system are characteristic of the central form of von Recklinghausen's neurofibromatosis. Meningiomas may also occasionally be coincident with other primary intracranial neoplasms, such as gliomas or pituitary adenomas, but the association is almost certainly fortuitous.

CLINICAL DATA. Both the clinical histories, and the postmortem finding of small incidental meningiomas, indicate a slow evolution in the growth of these neoplasms. The fairly large series from the Frazier-Grant collection recently analyzed by Earle and Richany shows the average duration of the earliest symptom to be two and one-half years, with a small number of patients having had symptoms more than six years before the tumor was diagnosed. Headaches, visual impairment, and focal seizures are the most common complaints, in that order, except seizures are usually the first symptom from a meningioma of the convex surface of either cerebral hemisphere.

SITES. The most frequent site of **intracranial** meningiomas originating from the surface coverings is the parasagittal region (fig. 183), followed by the lateral cerebral convexity (figs. 185, 188). A significant number arise from the **falx cerebri**, often extending on both sides of the dura to form a dumbbell-shaped mass that excavates the frontal lobes. Another notable group, which may present a formidable surgical problem, originates at the base of the brain, in particular from the **sphenoid ridge** (fig. 184) and from the tuberculum sellae (pl. VI–A). Other sites include the olfactory grooves, the pontocerebellar angle, and the petrous ridge of the temporal bone; in the latter case the tumor is attached to the **tentorium cerebelli**. Another site in the posterior fossa, fortunately rare, is the region of the foramen magnum. In all these situations the tumor tends to be related to a major dural venous sinus. Those arising over the convexities adjoin the sagittal sinus in about 50 percent of the cases, most of them involving the middle third of the sinus. Generally speaking the anterior half of the cranial cavity is much more often affected than the posterior.

In the **spinal canal** the thoracic region is more frequently implicated than other levels. As in the cranial cavity most examples are firmly attached to the dura. They are usually closely related, or even attached, to a nerve root as it emerges from the subarachnoid space; in this respect the meningioma may mimic a nerve sheath tumor. Rarely the tumor is entirely extradural.

Intraventricular meningiomas (fig. 186; pl. VI-B) are well known, and arise either from the tela choroidea or from the stroma of the choroid plexus (p. 263). As shown in figure 186, there is a distinct preference for the left side to be involved (Abbott and Courville). Examples are also occasionally found in the third or fourth ventricles.

Other rare primary sites of meningioma include the orbit, where these neoplasms arise from the optic nerve sheath; the petrous temporal bone (Nager); the extracalvarial planes (Siegel and Anderson); and the extracranial regions, which usually include the glabella or the pterygopalatine fossa (Suzuki et al.), presumably from included arachnoidal ectopias.

GROSS. Meningiomas are characteristically well circumscribed globular or lobulated tumors, clearly demarcated from the brain (figs. 183, 184, 186), and on cut surface are very firm, tough, grayish or pinkish gray (fig. 186) with a faintly lobular pattern of rather homogeneous tissue. Occasionally they appear more diffuse and may grow *en plaque* over the convexity of the brain

MENINGIOMA

Figure 184. This meningioma arising from the medial portion of the right sphenoidal ridge has produced marked compression of the adjacent medial structures. (Courtesy of Dr. J. W. Hanbery, Stanford, Calif.)

MENINGIOMA

Figure 183. This large right frontal parasagittal meningioma with its irregular and nodular surface is crisply demarcated from the brain. (Fig. 89 from Fascicle 35, First Series).

MENINGIOMA EN PLAQUE

Figure 185. Large meningioma is seen over the right lateral frontal convexity growing *en plaque* over the surface of the brain. (Courtesy of the Armed Forces Institute of Pathology).

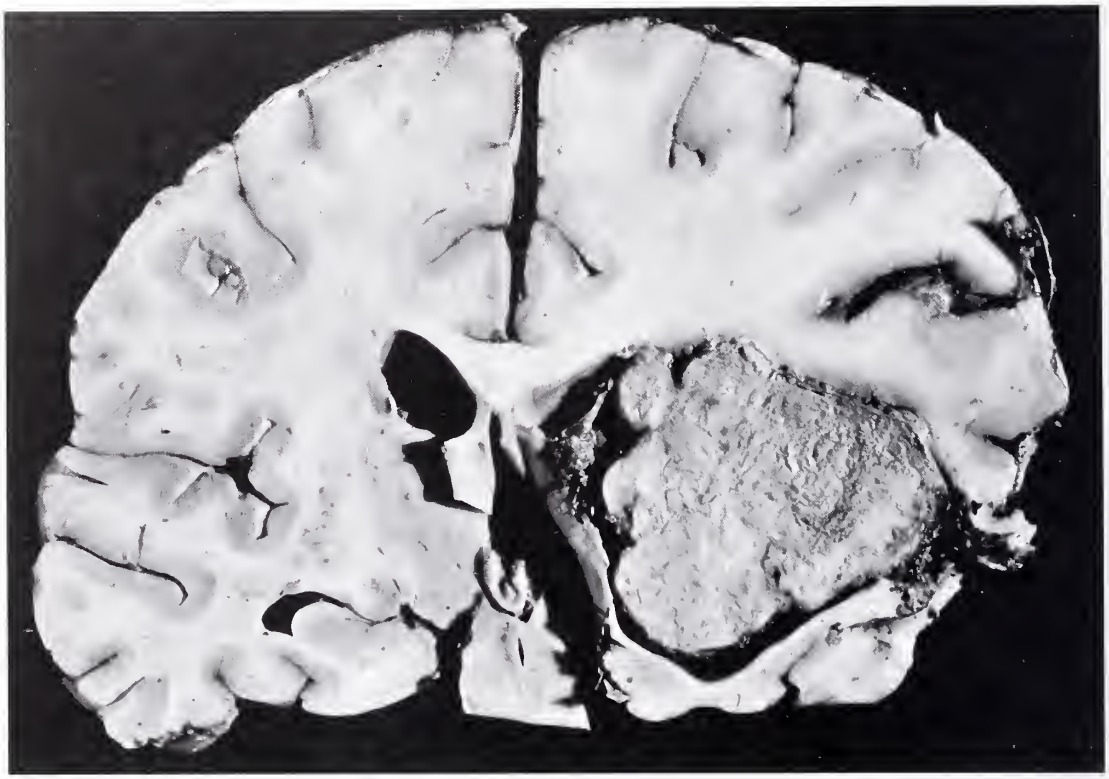

INTRAVENTRICULAR MENINGIOMA

Figure 186. This large left intraventricular meningioma has a lobular pattern of otherwise homogeneous tan granular tissue. (Courtesy of the Armed Forces Institute of Pathology).

(fig. 185), or form a collar-like mass around the spinal cord. They may severely compress the adjacent structures (fig. 184), but aside from the very rare sarcomatous examples they are not infiltrative of neural tissues. Gritty foci of calcification due to the presence of psammoma bodies are sometimes found, especially in the spinal examples. Occasionally bone is formed and even cartilage, but the latter is exceptional. Some meningiomas contain softer foci and have a yellow color due to the presence of xanthomatous elements. Necrosis does not occur except in the rare malignant examples. Spontaneous hemorrhage in a meningioma is also very seldom encountered, and cyst formation is exceptional.

One feature long noted and memorably described in Cushing and Eisenhardt's monograph, and sometimes the presenting sign in these cases, is the presence of **hyperostosis** of the skull overlying the meningioma (fig. 187). This may be found both over the convexity meningiomas and adjacent to those that arise over the base of the brain, such as those from the sphenoidal ridge. The hyperostosis is due to the extensive new bone formation which may or may not be associated with invasion of the marrow spaces by meningioma cells.

HYPEROSTOSIS OF SKULL ASSOCIATED WITH MENINGIOMA

Figure 187. Marked focal thickening of the calvarium is shown at the site which overlaid a meningioma. (Courtesy of the Armed Forces Institute of Pathology).

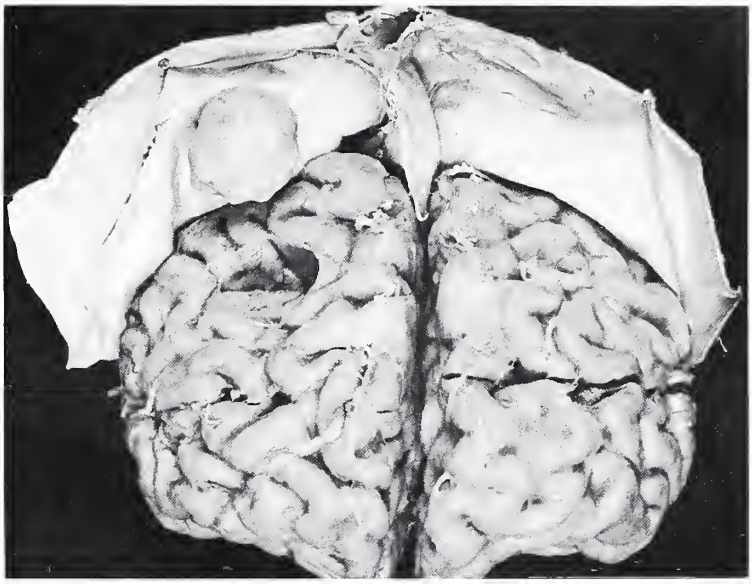

SMALL INCIDENTAL MENINGIOMA

Figure 188. This small meningioma of the right frontal region is attached to the dura. Note the delicate edge of arachnoid from which the meningioma arose, surrounding the cerebral indentation produced by the tumor. (Fig. 96 from Fascicle 35, First Series).

MICROSCOPIC. The microscopic appearance of meningiomas is highly variable. It is customary to divide these tumors into a number of separately designated histologic variants: meningotheliomatous, fibroblastic, transitional, psammomatous, angioblastic, and malignant or sarcomatous. These distinctions do not imply a different cytogenesis for each of these subtypes. On the contrary there is general agreement, on the whole supported by electron microscopic observations, that the fundamental cell of origin for all is the meningothelial arachnoid cell, and that the morphologic diversity of its pattern of neoplasia is but an expression of the adaptive potential of the normal arachnoid cell itself. It is therefore to be anticipated that different areas within the same tumor will not infrequently exhibit two or more of the types to be described, as well as the transitional forms which bridge them. Moreover, except for the rare atypical examples and possibly the angioblastic type of meningioma, no prognostic significance can be attached to these histologic variants. Nevertheless, recognition of the different structural patterns is necessary for diagnostic purposes, and they provide a convenient means for their systematic microscopic description.

The **meningotheliomatous** meningioma (**syncytial; endotheliomatous**) consists of a uniform and moderately lobulated arrangement of solid masses of tumor cells with very ill-defined cell membranes and delicate

regular round and oval nuclei (fig. 189). The detailed cytologic features are especially well appreciated in smears (pl. VI–C), which emphasize the delicate regular nuclear membranes, the pale nucleoplasm, and the frequent presence of one or two small conspicuous nucleoli. The cytologic characteristics are entirely benign. Frequently the nuclei contain a clear, empty-looking vacuole, shown by electron microscopic observations to consist of cytoplasmic invaginations that are incorporated within the folds of the nuclear membrane (Robertson). Stains for connective tissue demonstrate that the fibrous stroma is confined to trabeculae that divide the tumor into distinct lobules (fig. 190). Areas of endotheliomatous meningioma often merge imperceptibly into the next histologic subtype.

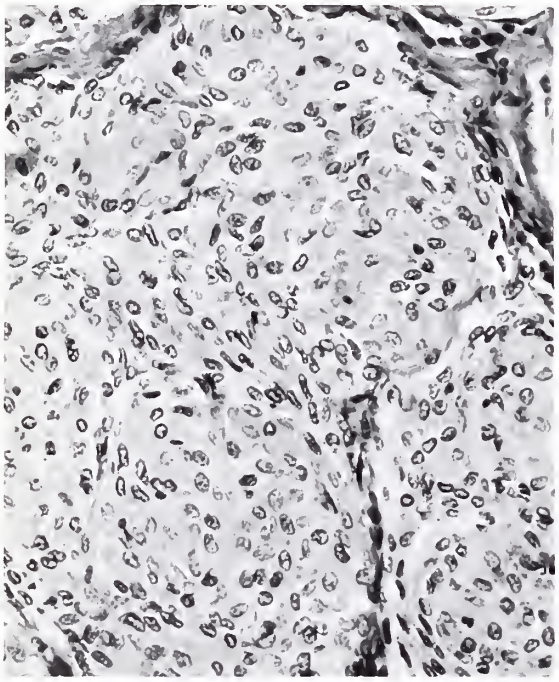

MENINGOTHELIOMATOUS MENINGIOMA

Figure 189. This tumor is characterized by a lobulated arrangement of solid masses of tumor cells with very ill-defined cell outlines and delicate, regular ovoid nuclei. × 265.

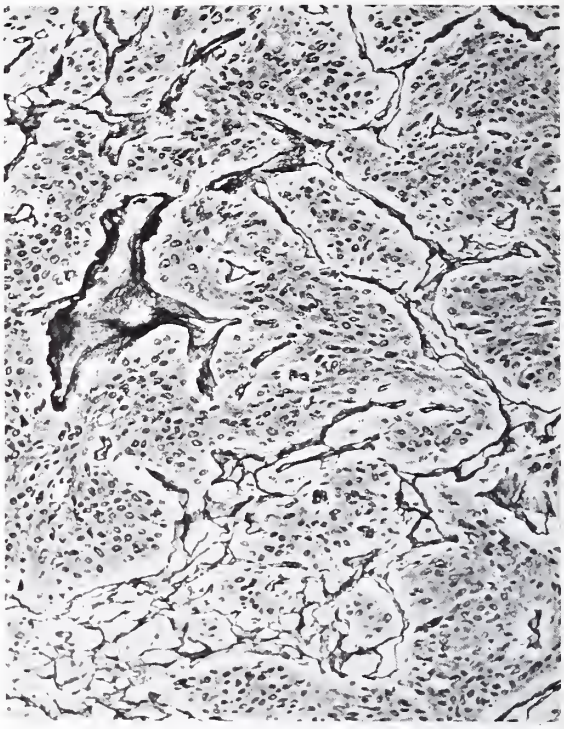

MENINGOTHELIOMATOUS MENINGIOMA

Figure 190. A reticulin preparation of a meningotheliomatous meningioma shows the prominent connective tissue network dividing the tumor into distinct lobules. Gomori silver method for reticulin. × 130.

The **transitional** or **mixed** group of meningioma is intermediate between the syncytial form and the fibrous, or fibroblastic type to be described. The most characteristic feature consists in a conspicuous arrangement of the cells to form concentric whorls. The cells themselves are elongated and crescentic (fig. 191). Sometimes the center of the whorl contains a capillary blood vessel (pl. XV–C). An accentuation of this pattern results in the conversion of the whorls into psammoma bodies, and the tumors in which these abound are sometimes listed under a separate histologic category of **psammomatous** meningiomas (fig. 192). The separation is, however, artificial: all intermediate stages are found between the transitional and the psammoma-

tous forms. The latter are especially common among the intraspinal examples.

Psammoma bodies in meningiomas consist of concentric laminae of calcium salts that have been laid down in degenerating tumor cells, and are of course identical with those normally found in the arachnoid villi and in the stroma of the choroid plexuses. Whereas most psammoma bodies appear to be the end result of the concentric whorls found in transitional meningiomas (figs. 191, 192; pl. VI–B), it is likely that other mechanisms too may play a part in their formation. They could result from calcium deposition in the walls of thickened hyaline blood vessel segments that have become obliterated (fig. 198), or

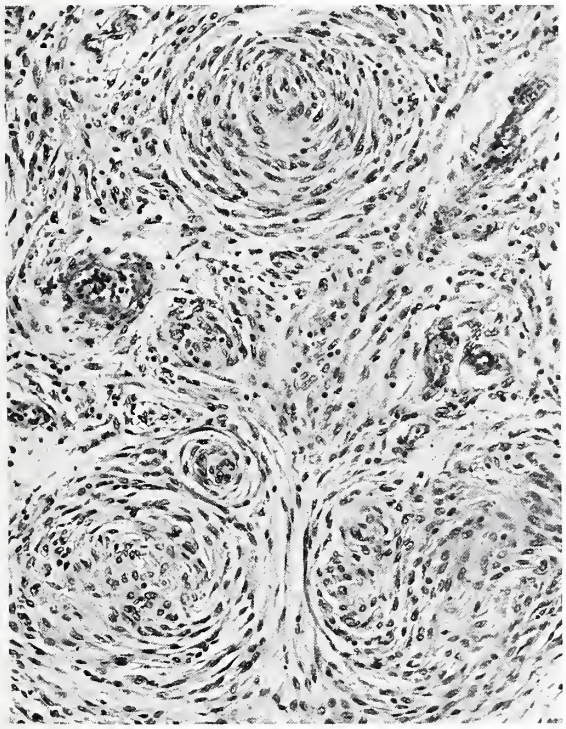

TRANSITIONAL MENINGIOMA

Figure 191. Conspicuous whorl formations of elongated and crescent-shaped meningioma cells are shown. The histologic picture is transitional between that of the meningotheliomatous (fig. 189) and the fibroblastic (fig. 194) forms of meningioma. van Gieson. × 150.

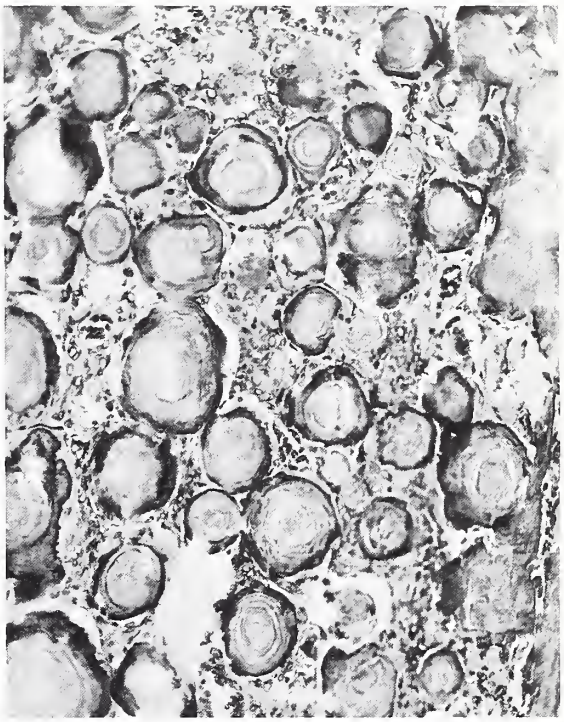

PSAMMOMATOUS MENINGIOMA

Figure 192. Extensive psammoma body formation is shown in a spinal meningioma. × 145.

from the hyalinization and subsequent calcification of thickened fibrous connective tissue septa in the tumor (fig. 193). Intensely eosinophilic, PAS-positive hyaline droplets, termed "pseudopsammoma bodies," have also been described (Kepes, 1961a). Their formation is, however, essentially different from that of classic psammoma bodies, and is believed to result from proteinaceous secretion on the part of meningothelial cells.

The **fibroblastic** meningioma, or fibrous type, consists of elongated spindle cells forming closely interwoven bundles (fig. 194), which sometimes show a tendency toward palisading. Some degree of whorling is almost always found, and psammoma bodies may also be present. Although the cells superficially resemble fibroblasts, the nuclear characteristics as seen in smear preparations (pl. VI–D) are identical with those of the endotheliomatous meningioma

PLATE VI

MENINGIOMA OF THE TUBERCULUM SELLAE

A. This small disklike meningioma is shown arising from the dura over the tuberculum sellae. It was an incidental postmortem finding.

INTRAVENTRICULAR MENINGIOMA

(Plate VI-B and Figures 114, 115, 222, 223, 312, and 314 from same case)

B. A small well defined highly calcified intraventricular meningioma is seen arising from the choroid plexus in a 17-year-old girl with central neurofibromatosis.

SMEAR FROM ENDOTHELIOMATOUS MENINGIOMA

C. This smear is from an endotheliomatous meningioma. The cells show fairly well defined cytoplasmic outlines, and clear delicate nuclei with conspicuous small nucleoli. Whorl formation is evident along the right margin of this photomicrograph. Morris × 350.

SMEAR FROM FIBROBLASTIC MENINGIOMA

D. The tumor cells are more elongated and fusiform than in the previous illustration, but show the same characteristic pale nuclei with small prominent nucleoli. The cytologic appearances are quite different from those of a glial tumor. Morris. × 400.

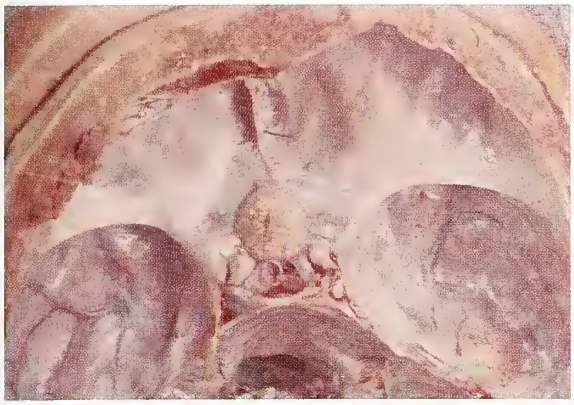

A

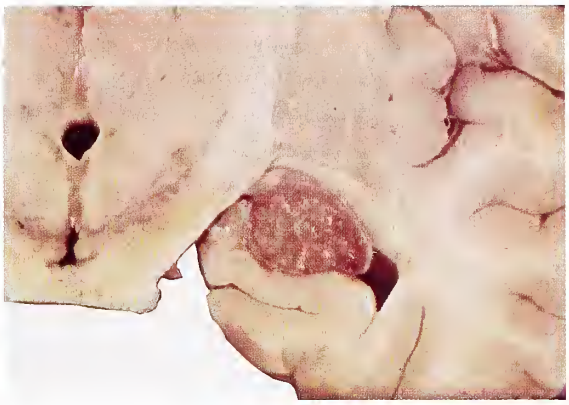

B

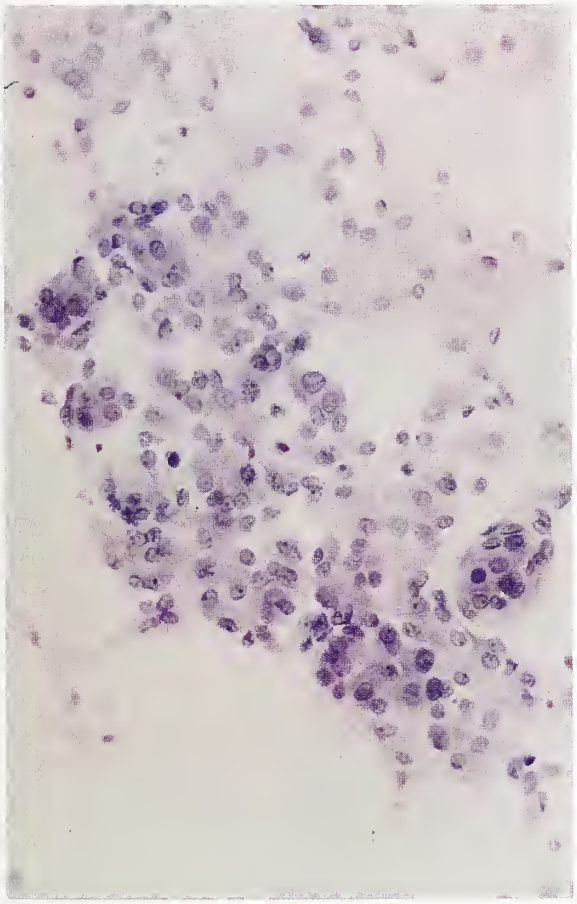

C

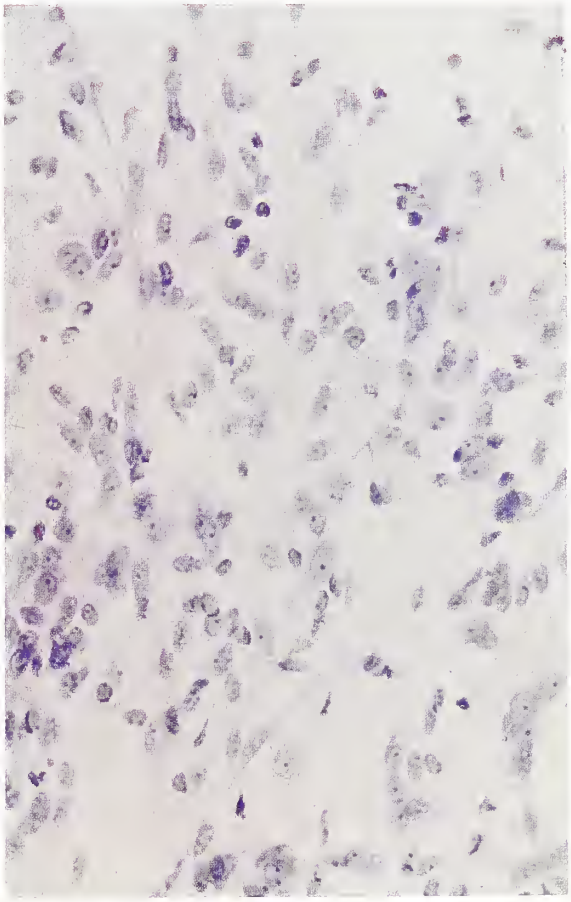

D

PLATE VI

MENINGIOMA
STROMAL DEGENERATION

(Figures 193 and 199 from same case)

Figure 193. There is marked focal thickening of the fibrous connective tissue stroma in a meningioma. These peculiar bodies appear to be a degenerative change, and might conceivably constitute a source of psammoma bodies in some cases. Silver stain for reticulin. × 80.

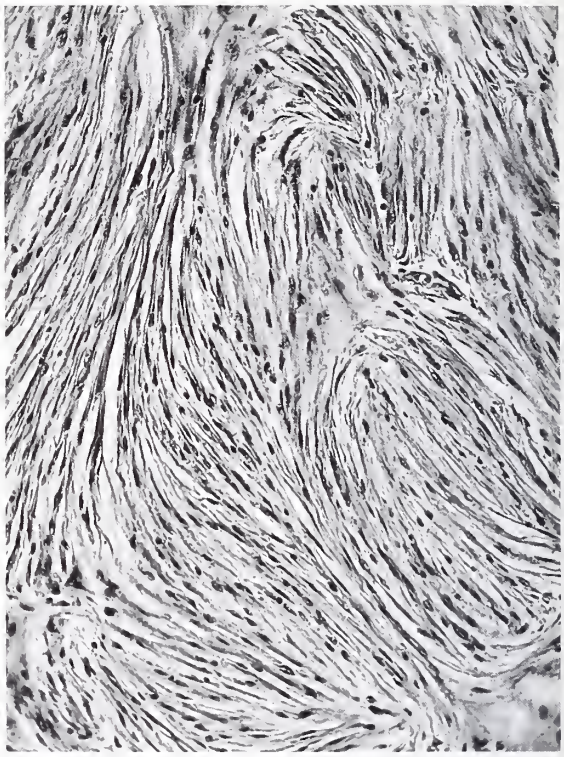

FIBROBLASTIC MENINGIOMA

(Figures 194 and 197 from same case)

Figure 194. These highly elongated meningioma cells resemble fibroblasts and form closely interlacing bundles. × 165.

(compare with pl. VII–C). The most distinctive feature of the fibroblastic meningioma, in contradistinction to the meningotheliomatous type, is the presence of numerous reticulin and collagen fibers that separate the individual cells. Intraventricular meningiomas are said to be usually of this type (Abbott and Courville), but meningotheliomatous, transitional, and psammomatous forms are also seen in that situation.

The **angioblastic** type of meningioma is a highly characteristic histologic group which was separately described by Bailey, Cushing, and Eisenhardt. These tumors are usually highly cellular, the cells having a very ill-defined cytoplasm but closely packed ovoid nuclei. They usually lie immediately adjacent to small capillary blood spaces, which may either be dilated (fig. 195) or, more frequently, compressed and therefore not always instantly identifiable with hematoxylin and eosin staining (fig. 196). The intense vascularity of the tumor is easily revealed in connective tissue stains, which demonstrate an abundant intersecting network of reticulin fibers (fig. 197). In this neoplasm whorl formation is not seen, but mitotic figures are not uncommonly found. Larger cells may also be present with a foamy cytoplasm that in frozen sections can be shown to contain sudanophilic lipid. The tumor cells were

termed "angioblastic" by Bailey and his associates in accordance with their interpretation that they were actually blood-space forming elements, therefore closely related to endothelial cells. As originally stressed by Bailey, Cushing, and Eisenhardt, this type of meningioma must be clearly distinguished from the quite common examples of usual meningioma that happen to be highly vascularized (fig. 198): nests of typical meningotheliomatous or transitional meningioma are easily found in the latter.

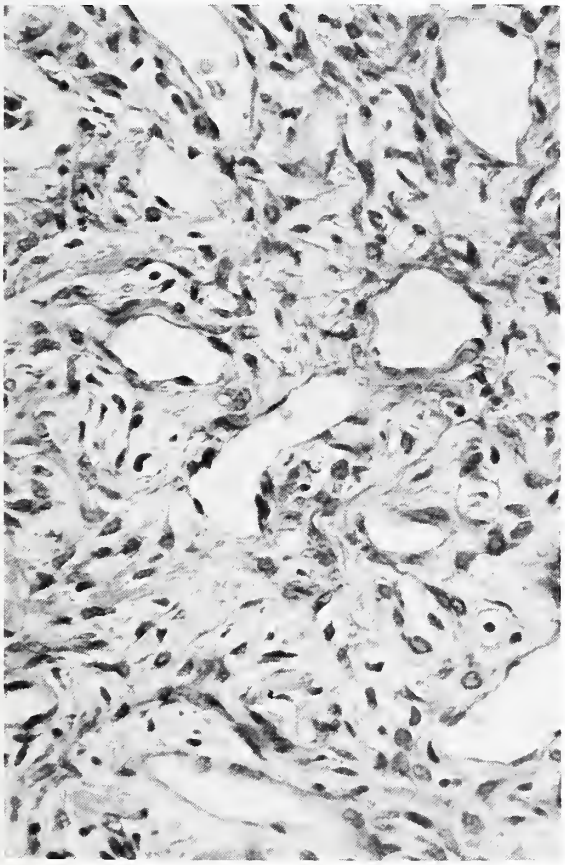

ANGIOBLASTIC MENINGIOMA

Figure 195. This microscopic picture shows a recurrent angioblastic meningioma originating in the peritorcular region. The tumor cells lie adjacent to thin-walled capillary blood vessels. Note the resemblance of the histologic picture to that of the capillary hemangioblastoma in figure 248. × 300.

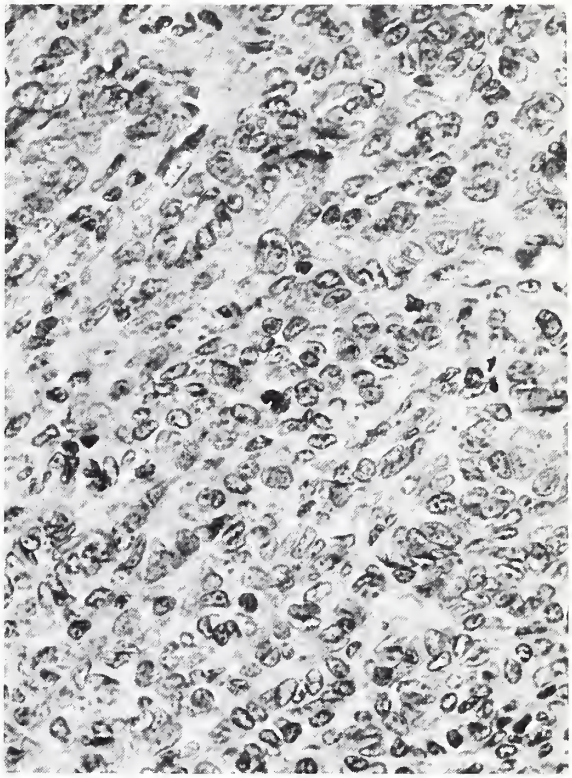

ANGIOBLASTIC MENINGIOMA

Figure 196. This highly cellular, compact tumor with distinct ovoid nuclei, without whorl formation, shows occasional mitotic figures. This neoplasm, in this case a recurrent angioblastic meningioma arising from the tentorium, which eventually metastasized to the liver, is sometimes designated as hemangiopericytoma of the meninges. × 400.

The term "angiomatous" or "hemangiomatous" meningioma is sometimes indiscriminately applied to all these tumor types, but it is misleading and inappropriate.

The fundamental distinction between angioblastic meningioma and the capillary hemangioblastoma (p. 235) is not clear-cut. Microscopically they are often closely similar, but they broadly differ in their localization and gross features, most angioblastic meningiomas being supratentorial, solid, and attached to the dura. Even these criteria are not absolute since angioblastic meningiomas may be unattached to the dura,

while the capillary hemangioblastomas are sometimes solid and may exceptionally arise above the tentorium. Moreover isolated and familial cases have both been reported in which an association of cerebral angioblastic meningioma and cystic cerebellar hemangioblastoma was present, as detailed by Russell and Rubinstein. A relationship that is not entirely morphologic exists therefore between these two types of neoplasms, which are bridged by transitional forms (p. 236).

Some workers have separated the angioblastic type of meningioma from the meningiomas altogether, and renamed it "hemangiopericytoma of the meninges" (Kruse). These tumors indeed tend to recur, and some appear to behave more aggressively than the average meningioma. For these reasons, and also because of their morphologic resemblance to the hemangiopericytomas encountered elsewhere in the body, and their occasional intracerebral localization, Kernohan and Uihlein have grouped these tumors among the cerebral sarcomas. In gross appearance, however, angioblastic meningiomas are virtually indistinguishable from other types of meningioma, and a meningeal attachment, usually dural, is frequently demonstrated. While it is agreed that these tumors have the potential of rapid growth and the prognosis should be guarded in the individual case, little seems to be gained by creating a separate group of "hemangiopericytoma of the meninges" out of an already well described variant of meningioma.

A number of other histologic variants may be demonstrated in individual instances to exemplify the multipotentiality of the arachnoid cells from which these tumors are derived. **Xanthomatous** foci containing sudanophilic lipid may be found in all the



ANGIOBLASTIC MENINGIOMA

(Figures 194 and 197 from same case)

Figure 197. A reticulin preparation shows an abundant intersecting network of reticulin fibers frequently outlining vascular architecture. Silver stain for reticulin. × 190.

types of meningioma previously described. Occasionally foci of **ossification** are found, usually independent from psammoma bodies. There is no relationship between bone formation in a meningioma and the development of calvarial hyperostosis. In fact most osteogenic meningiomas are spinal and, although attached to the dura, are separated from the vertebral body by the epidural space. **Cartilage** is exceptionally found in meningiomas, but must be distinguished from the rare chondromas and osteochondromas that may arise from the falx or the meninges of the cerebral convexity.

HIGHLY VASCULAR MENINGOTHELIOMATOUS MENINGIOMA

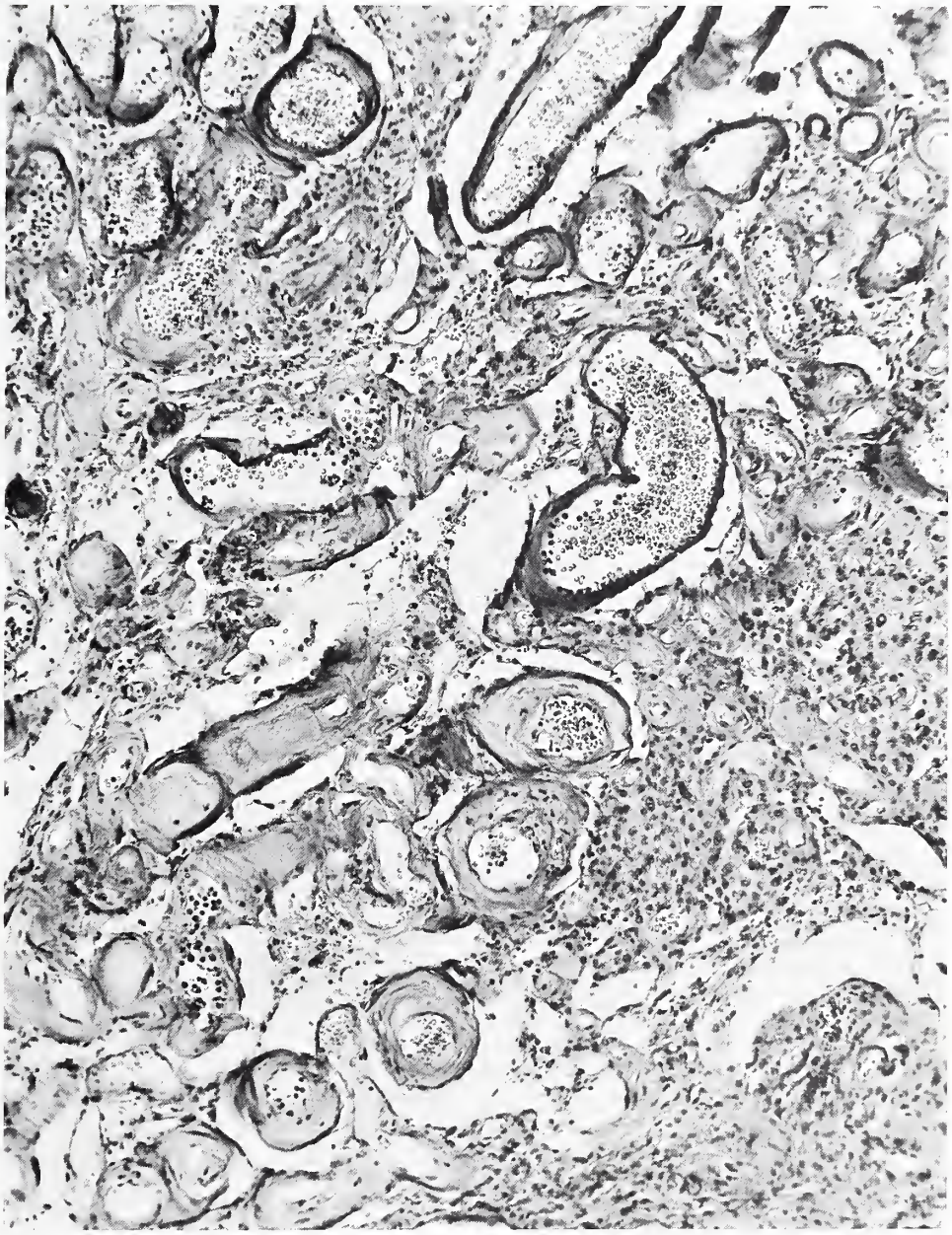

Figure 198. Richly vascular meningioma shows marked fibrous hyaline thickening of vessel walls. Compare this pattern with that in figure 196. This appearance in a meningioma is sometimes erroneously referred to as "angioblastic" or "hemangiomatous." There are obvious nests of typical meningotheliomatous meningioma. van Gieson. × 125.

Occasionally syncytial meningiomas contain bizarre hyperchromatic giant nuclei that may invite suspicion of malignancy (fig. 199). Although their significance is obscure they are usually found in the absence of evidence of rapid growth, such as mitotic figures or invasion of the adjacent brain, and there is no evidence that they are of sinister import.

Another variant of meningioma contains melanin pigment, both within the cytoplasm of the tumor cells and in the macrophages of its stroma. Since pial cells covering the ventral surface of the medulla and the upper cervical cord normally contain melanin pigment, it is not surprising that pigmented meningiomas are occasionally found. Individual cases have been reported by Keegan and Mullan, and by Turnbull and Tom. Care is necessary in distinguishing this variety of meningioma, which is benign, from the rare primary melanoma of the leptomeninges, and from a metastatic deposit from an undiscovered primary melanoma elsewhere in the body.

The fine structure of meningiomas has been studied by several observers. The agreed features (fig. 200) include pronounced interdigitations of the plasmalemma of the adjacent cells, the frequent presence of desmosomes, and the demonstration of fine intracytoplasmic filaments, which sometimes form a conspicuous whorling pattern within the cell (Kepes, 1961b; Napolitano et al.). Most of the ultrastructural features correspond to those of normal arachnoid cells in the villi (Shabo and Maxwell). Cilia and basal bodies have also been found in endotheliomatous and fibroblastic meningiomas (Cérvos-Navarro and Vázquez), but since these organelles have now been disclosed in a variety of cells, including normal arachnoid cells (Shabo and Maxwell), their significance is probably limited.

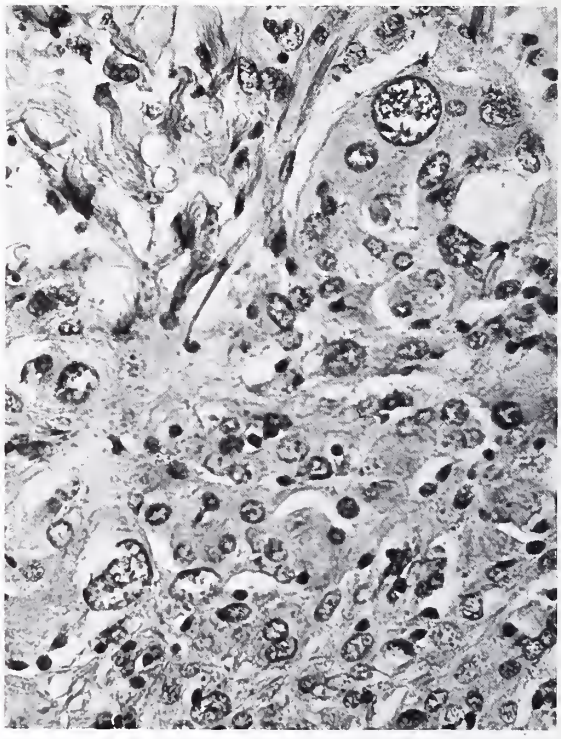

GIANT CELLS IN BENIGN MENINGIOMA

(Figures 193 and 199 from same case)

Figure 199. Bizarre hyperchromatic giant nuclei are sometimes found in endotheliomatous meningiomas. This feature is not indicative of malignant tumor. × 265.

GROWTH AND SPREAD. Meningiomas are characteristically benign: they are slowly growing, circumscribed, and do not invade the compressed brain. However, this absence of invasiveness does not apply to other adjacent tissue elements. Infiltration of mesodermal supportive tissues on the contrary is common, but it is not accompanied by cytologic malignant characteristics. The dura may be infiltrated, sometimes extensively, both along its inner and its outer surfaces, and invasion of the major dural sinuses and their tributaries is frequent. However, unlike the situation in intracranial gliomas, this should not be considered a harbinger of metastatic dissemination.

MENINGIOMA

Figure 200. This electron micrograph of meningioma cells shows pronounced interdigitation of the adjacent cell membranes, with desmosomes. Cytoplasmic filaments are present in the tumor cells. × 23,000. (Courtesy of Dr. Edwin R. Fisher, Pittsburgh, Pa. and Dr. L. Napolitano, Albuquerque, N. Mex.; also fig. 1 from Napolitano, L., Kyle, R., and Fisher, E. R. Ultrastructure of meningiomas and the derivation and nature of their cellular components. Cancer 17:233–241, 1963).

Invasion of the marrow spaces of the skull is common and may stimulate osteoblastic proliferation and hyperostosis. Infiltration of the pericranium may then follow, and over the convexity the temporal muscle may be invaded. Not infrequently inferior frontal meningiomas invade the orbit along the optic nerve sheath and infiltrate the external ocular muscles. The accessory nasal sinuses may also occasionally be invaded, and exceptionally a meningioma from the anterior fossa may present in the maxillary sinus.

Malignant Meningiomas

Malignant meningiomas are quite rare and the more frankly invasive examples, to which the term sarcomatous is applicable, cannot easily be distinguished from the rare primary meningeal sarcomas to be described on page 190. While the distinction is in some cases tenuous, there seems to exist a rare group of meningiomas which, although circumscribed and having many of the clinical and gross features of meningiomas, have somewhat atypical cytologic features and are likely in a few cases to give rise to extracranial metastases. In many cases, however, the future behavior of such a tumor is unpredictable. Histologically the **atypical** meningioma may show somewhat more pleomorphic cell forms than the classic type, with generally poor whorl formation, but the lobular architecture is usually preserved in some places (fig. 201). Mitotic figures may be found; they are exceptional in typical meningiomas and if present in any large numbers are certainly indicative of aggressive growth and may herald future recurrences. Although any of the histologic types already described may occasionally behave in this manner, the angioblastic type is particularly likely to do so. A curious histologic feature usually associated with malignant behavior is the occasional presence of a **papillary** architecture (fig. 202), originally described by Cushing and Eisenhardt in one of their patients who underwent 16 recurrences and finally developed pulmonary metastases (see also figs. 203, 204).

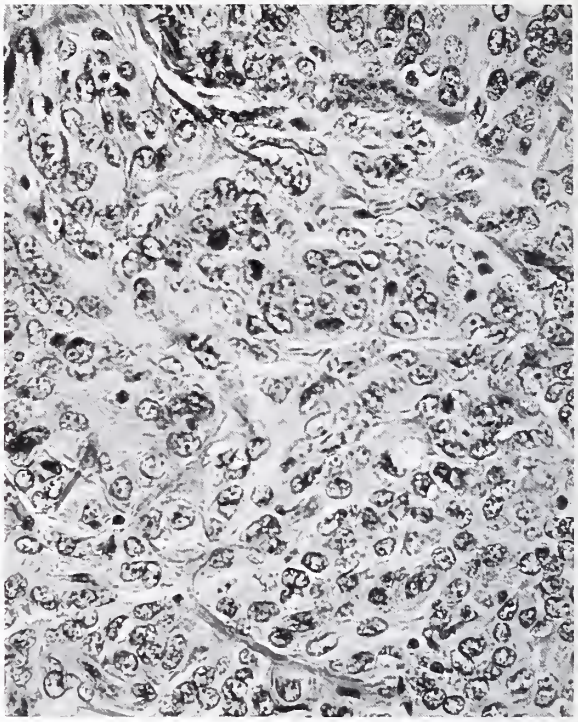

ATYPICAL MENINGIOMA

Figure 201. This atypical meningioma has somewhat pleomorphic cytologic features and occasional mitotic figures, but preserves a lobulated architecture. × 265.

Another feature of meningioma that has become sarcomatous is local **invasion** of the adjacent brain (pl. VIII–A). This may then be accompanied by a marked hyperplastic astroglial reaction. This is in contradistinction to the reaction of the neural tissue adjacent to the usual meningioma; here the brain is compressed, but shows only very limited astrocytic proliferation.

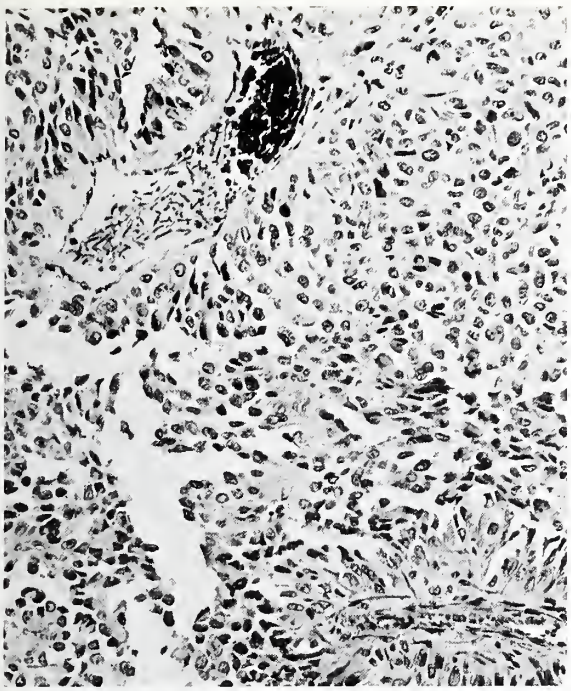

PAPILLARY MALIGNANT MENINGIOMA (METASTATIC)

(Figures 202–204 from same case)

Figure 202. A papillary architecture is shown in this pulmonary metastasis of a recurrent malignant meningioma. PTAH. × 150.

This hyperplastic neuroglial reaction is especially conspicuous near those infiltrative meningeal tumors that are frankly sarcomatous *de novo* (p. 195).

METASTASIS. As indicated above, direct extension in continuity into the adjacent supportive tissues is fairly common, but distant spread is very unusual. A few cases, often histologically malignant, have metastasized through the cerebrospinal fluid pathways (Hoffmann and Earle).

Extracranial metastases have been described more frequently, but remain a rare occurrence (Russell and Rubinstein). Some examples have had previous craniotomy, often repeated, but a number of well authenticated cases are on record in which no previous operation has been performed (Gibbs). In some examples invasion of the superior sagittal sinus was demonstrated, and presumably paved the way to metastatic spread. However, venous permeation is such a frequent finding in the microscopic examination of the dura adjacent to meningiomas removed at surgery that its significance for the remote dissemination of these tumors is slight. In several cases also the histologic appearances of both the primary neoplasm and its metastases were quite benign. In others the cytologic picture was somewhat atypical, and occasional mitotic figures were found (fig. 202). Once metastatic deposits have been demonstrated clinically (fig. 203) their growth may be slow and extend over several years (fig. 204). Finally, although some reported observations suggest that no particular histologic type of meningioma is exempt from this complication, this should be qualified by my experience of three examples submitted in the past five years, all of which were recurrent metastasizing angioblastic meningiomas with cytologic features suggestive of rapid growth (fig. 196).

TREATMENT. The treatment of meningiomas is entirely surgical. Radiation plays no part in therapy.

PROGNOSIS. In most cases the prognosis is favorable, the average postoperative survival ranging from 12 to 15 years (Earle and Richany). The life expectancy of patients with tumors over the convexity of the brain is somewhat better than for those with intracranial meningiomas in other sites, probably due to the easier surgical accessibility of laterally situated examples. Earle and Richany found no significant differences in the length of postoperative survival according to the various histologic subtypes, but the angioblastic meningioma has probably a somewhat less favorable prognosis.

PULMONARY METASTASES IN MALIGNANT MENINGIOMA

(Figures 202–204 from same case)

Figure 203. X-ray of the chest in a 53-year-old man who had a recurrent occipital meningioma 12 years after apparently complete removal of an endotheliomatous meningioma at the same site. Both biopsies showed occasional mitoses and somewhat atypical cytologic features. Well defined radiopaque metastatic nodules are seen in the lung fields.

Recurrence, even in those examples that have apparently been completely extirpated, seems to occur in about 11 percent of the cases, the figures being naturally higher when resection is incomplete (Simpson). The parasagittal tumors are most likely to recur, and it is apparent that this is mostly due to the presence of residual unnoticed nests of growth in the neighboring dural sinus, or to unsuspected spread of tumor across the dura. Recurrences become manifest usually within five years after operation. With the exception of a small group of angioblastic meningiomas noted by Simpson, there was no obvious relationship between the histologic character of the tumor and its tendency to recur.

DIFFERENTIAL DIAGNOSIS. Diagnostic difficulty may sometimes arise between a fibroblastic meningioma in which the close alignment of the cells mimics palisading, and a schwannoma. The reverse

PULMONARY METASTASES IN MALIGNANT MENINGIOMA

(Figures 202–204 from same case)

Figure 204. This x-ray of the chest taken four years later shows that there has been slow but steady growth of the pulmonary deposits, some of which are now massive and measure up to 20 cm. in diameter. Postmortem examination confirmed the presence of numerous large pulmonary metastases, with an extensive local intracranial recurrence that invaded the occipital lobe, and the presence of one small deposit in the liver. Microscopically the metastatic deposits were in most places identical with the previous biopsies, but showed in places a distinct papillary architecture (fig. 202).

may also occur: some schwannomas have a whorled pattern that recalls the formations of a transitional meningioma. Interestingly this interpretative problem is particularly likely to arise, as already noted by Bailey and Herrmann, in cases with the central form of von Recklinghausen's neurofibromatosis, in which multiple meningiomas and schwannomas may both be present. In fibroblastic meningiomas, however, the typical palisading of schwannomas is not found, and more extensive sampling will usually disclose areas of transitional meningioma with whorl formations. In meningiomas the whorls are usually centered around a small blood vessel (pl. XV–C), whereas this is not the case in a schwannoma (fig. 223); a silver impregnation for reticulin will usually clarify this point.

The microscopic picture of an angioblastic meningioma and a capillary hemangioblastoma may in places be indistinguishable. The capillary vasculature is usually more evident in the hemangioblastoma, but more extensive sampling may be necessary to reach a definitive conclusion. Cerebellar hemangioblastomas may often be demonstrated to be attached to the pia, and reasons have been given on page 181 why the distinction between the two tumor types is not decisive.

Difficulty is exceptionally met in distinguishing a syncytial meningioma from a metastatic polygonal cell carcinoma, especially if it has a few suspicious cytologic features such as an occasional mitotic figure. The problem is usually resolved by more extensive sampling to determine whether the brain is infiltrated or not. It is discussed in further detail by Kepes and Kernohan. Finally a diagnostic problem is occasionally posed in differentiating a meningioma from a parasagittal oligodendroglioma that has become tethered to the dura. The glioma may then be unduly firm and circumscribed. It may resemble a meningioma grossly, and some areas may even mimic a meningioma under the microscope. Examination of the deeper parts of the specimen is always advisable.

References

Abbott, K. H., and Courville, C. B. Intraventricular meningiomas; review of literature and report of two cases. Bull. Los Angeles Neurol. Soc. 7:12–28, 1942.

Bailey, P., Cushing, H., and Eisenhardt, L. Angioblastic meningiomas. Arch. Path. 6:953–990, 1928.

———, and Herrmann, J. D. Role of cells of Schwann in formation of tumors of peripheral nerves. Amer. J. Path. 14:1–38, 1938.

Cervós-Navarro, J., and Vázquez, J. Elektronenmikroskopische Untersuchungen über das Vorkommen von Cilien in Meningeomen. Virchow Arch. Path. Anat. 341:280–290, 1966.

Cushing, H., and Eisenhardt, L. The Meningiomas. Springfield, Ill.: Charles C Thomas, 1938.

Earle, K. M., and Richany, S. F. Meningiomas. Med. Ann. D. C. 38:353–358, 1969.

Gibbs, N. M. Meningioma with extracranial metastasis. J. Path. Bact. 76:285–288, 1958.

Hoffmann, G. T., and Earle, K. M. Meningioma with malignant transformation and implantation in the subarachnoid space. J. Neurosurg. 17:486–492, 1960.

Keegan, H. R., and Mullan, S. Pigmented meningiomas: an unusual variant. Report of a case with review of the literature. J. Neurosurg. 19:696–698, 1962.

Kepes, J. Observations on the formation of psammoma bodies and pseudopsammoma bodies in meningiomas. J. Neuropath. Exp. Neurol. 20:255–262, 1961a.

———. Electron microscopic studies of meningiomas. Amer. J. Path. 39:499–510, 1961b.

———, and Kernohan, J. W. Meningiomas: problems of histological differential diagnosis. Cancer 12:364–370, 1959.

Kernohan, J. W., and Uihlein, A. Sarcomas of the Brain. Springfield, Ill.: Charles C Thomas, 1962.

Kruse, F., Jr. Hemangiopericytoma of the meninges (angioblastic meningioma of Cushing and Eisenhardt). Clinicopathologic aspects and follow-up studies in 8 cases. Neurology 11:771–777, 1961.

Lüginbühl, H., Fankhauser, R., and McGrath, J. T. Spontaneous Neoplasms of the Nervous System in Animals, pp. 86–164. In: Progress in Neurological Surgery, Vol. 2. (Eds.) Krayenbühl, H., Maspes, P. E., and Sweet, W. H. Chicago: Year Book Medical Publishers, Inc., 1968.

Nager, G. T. Meningiomas Involving the Temporal Bone: Clinical and Pathological Aspects. Springfield, Ill.: Charles C Thomas, 1964.

Napolitano, L., Kyle, R., and Fisher, E. R. Ultrastructure of meningiomas and the derivation and nature of their cellular components. Cancer 17:233–241, 1963.

Robertson, D. M. Electron microscopic studies of nuclear inclusions in meningiomas. Amer. J. Path. 45:835–848, 1964.

Russell, D. S., and Rubinstein, L. J. Pathology of Tumours of the Nervous System, 3d ed. London: Edward Arnold, 1971.

Shabo, A. L., and Maxwell, D. S. The morphology of the arachnoid villi: a light and electron microscopic study in the monkey. J. Neurosurg. 29:451–463, 1968.

Siegel, G. J., and Anderson, P. J. Extracalvarial meningioma. Case report. J. Neurosurg. 25:83–86, 1966.

Simpson, D. The recurrence of intracranial meningiomas after surgical treatment. J. Neurol. Neurosurg. Psychiat. 20:22–39, 1957.

Suzuki, H., Gilbert, E. F., and Zimmerman, B. Primary extracranial meningioma. Arch. Path. 84:202–206, 1967.

Turnbull, I. M., and Tom, M. I. Pigmented meningioma. J. Neurosurg. 20:76–80, 1963.

Walsh, J., Gye, R., and Connelley, T. J. Meningioma: a late complication of head injury. Med. J. Aust. 1:906–908, 1969.

Wood, M. W., White, R. J., and Kernohan, J. W. One hundred intracranial meningiomas found incidentally at necropsy. J. Neuropath. Exp. Neurol. 16: 337–340, 1957.

SARCOMAS

DEFINITION, CYTOGENESIS, AND CLASSIFICATION. Sarcomas arising in the central nervous system are rare, but form a controversial group for which various classifications have been proposed. While it is agreed that these tumors are malignant neoplasms arising from connective tissue elements present in the meninges and their derivatives, there is considerable disagreement on which tumor types should be included in this general category. On the one hand, as indicated previously, the distinction between meningeal sarcomas and malignant meningiomas may be difficult to define; in some instances it may be academic, and a lack of interpretative consistency is sometimes detected in consecutive accounts from the same sources. On the other hand, some authorities include in this group examples that are derived from the reticuloendothelial elements of the central nervous system and for which the term sarcoma is sometimes qualified by "perivascular," "perithelial," "round cell," or "reticuloendothelial"; these tumors will be treated in the section devoted to neoplasms of the lymphoreticular system on page 215. In addition some workers include in the group of sarcomas tumors that have been classified elsewhere in this fascicle as variants of medulloblastomas (p. 142), of glioblastomas (p. 72), and as mixed gliomas and sarcomas (p. 74).

The controversial problems pertaining to the classification of sarcomas of the nervous system and an analysis of the literature have been detailed elsewhere (Rubinstein, 1971). In brief, primary malignant tumors may take their origin from connective tissue producing elements found within the cranial and spinal cavities such as the periosteum and the nerve sheaths.

Most meningeal and intracerebral sarcomas also arise from connective tissue cells that are situated in the dura (dural fibroblasts), in the leptomeninges, or in their pial intracerebral extensions along the perivascular spaces, the tela choroidea and the stroma of the choroid plexuses (arachnoid cells, fibroblasts, and pial cells). The more primitive cells of the reticular system, which are generally believed to exist both in the meninges and the perivascular sheaths of the cerebral blood vessels, together with the microglia are regarded as the source of origin of tumors of the reticulum cell sarcoma-microglioma group.

INCIDENCE AND PATHOGENETIC FACTORS. After eliminating the above-mentioned examples that are more correctly included in other categories, we are left with a small group of primary intracranial tumors that are truly authentic primary sarcomas. Within this definition they remain very rare. The relatively high percentage of 3 percent of primary intracranial sarcomas recorded by Kernohan and Uihlein is accounted for by their inclusion of reticulum cell sarcomas, hemangiopericytomas, "giant cell fibrosarcomas," and "circumscribed cerebellar sarcomas." When these are eliminated, their adjusted incidence of sarcomas, as defined in this chapter, amounts to 1.2 percent in their large series of 8,070 intracranial tumors.

Unlike meningiomas and tumors of the lymphoreticular system, sarcomas are most frequently found in infants and children, being uncommon in adults. The most malignant and undifferentiated examples tend to occur at an early age, but otherwise there is no obvious correlation between age incidence and cellular differentiation. There is no difference in sex incidence.

Several reports, summarized by Waltz and Brownell, who recorded two further examples, have raised the suspicion that radiation therapy applied to intracerebral tumors may, after an interval of several years, lead to the very occasional development of a malignant mesodermal tumor at the site of radiation. A further example in which this suspicion cannot be dismissed is illustrated in figure 205. Most of these supervening tumors have been fibrosarcomas of the dura. This hazard appears on statistical grounds to be especially associated with the radiotherapy of pituitary adenomas, in which case the sarcoma may be found to arise in the sella turcica. The average interval between the time of initial radiation and the development of sarcoma is from 5 to 10 years, but it may range from 2 to 20 years.

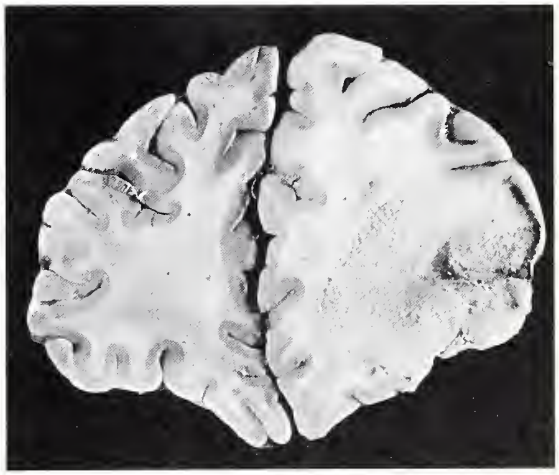

MENINGEAL SARCOMA

Figure 205. This is a fairly well defined but microscopically invasive meningeal fibrosarcoma. The cut surface is homogeneous and finely granular. This 50-year-old woman had a subtotal resection of a pituitary adenoma 18 years before death, followed by local radiation. Seventeen years later she developed an epidural right temporal tumor which apparently arose from the pituitary fossa and invaded the calvarium and the lateral aspect of the frontal lobe. The microscopic picture was that of a fibrosarcoma. (Courtesy of the Armed Forces Institute of Pathology).

CLINICAL DATA. The clinical picture is not distinctive. The usually short course suggests a rapidly growing neoplasm. Occasionally the history may cover several years, suggesting a more slowly growing lesion, such as a meningioma, upon which a recent malignant change has supervened (Rubinstein, 1956, Case 2). Other examples in which the tumor primarily infiltrates the meninges diffusely may present the clinical picture of a meningitis.

SITES. Sarcomas may arise from and be attached to any of the three meningeal layers, or alternatively have their origin within the brain substance and fail to reach the surface. Relatively well differentiated fibrosarcomas tend to originate from the dura. There is no special predilection for any particular area of the central nervous system. Occasional cases originating from the spinal dura have been reported (Tarlov and Keener).

GROSS. Sarcomas usually form large masses that tend to be clearly demarcated from the adjacent brain. Those arising from the meninges, especially the dura, are usually firmer, while those originating in the brain are more often softer and more fleshy. The cut surface is usually quite homogeneous with gray or grayish white finely granular cut surfaces (fig. 205). Although well defined in places they are not encapsulated, and on close examination may be found to infiltrate the brain locally and irregularly for variable distances. Those with more rapid growth may show spontaneous hemorrhages, necrosis, and cyst formation.

Occasionally very diffuse forms of sarcoma, arising either from the dura or from the leptomeninges, are encountered for which the name diffuse meningeal sarcomatosis or meningiomatosis has been coined.

MICROSCOPIC. The histologic features are similar to those of sarcomas arising elsewhere in the body, and exhibit therefore the same range of differentiation of their cell components. The most convenient classification according to their histologic appearances is that of Christensen and Lara, who reasonably arranged them in ascending grades of anaplasia into fibrosarcomas, spindle cell sarcomas, and polymorphic cell sarcomas.

Fibrosarcoma

The fibrosarcomas are characterized by an arrangement of long parallel intersecting bundles of elongated spindle cells (figs. 206, 207). The cytoplasm is ill-defined

FIBROSARCOMA OF THE DURA

(Figures 206 and 207 from same case)

Figure 206. This low power view shows intersecting strands of fibrosarcoma arising in the dura. van Gieson. × 120. (Fig. 1 from Rubinstein, L. J. Sarcomas of the Nervous System. Vol. 2, Pathology of the Nervous System. (Ed.) Minckler, J. New York: McGraw-Hill Book Company, 1971).

and fibrillated, with oval and sometimes slightly notched nuclei, distinct nuclear membranes, a pale nucleoplasm, and a delicate chromatin net. Mitotic figures are usually present (fig. 207). The nuclei may be hyperchromatic, but multinucleation and giant cell formation are rare. Reticulin preparations demonstrate a rich network of parallel intercellular connective tissue fibers aligned along the long axes of the cells. Maturation of reticulin into collagen may occur but is infrequent.

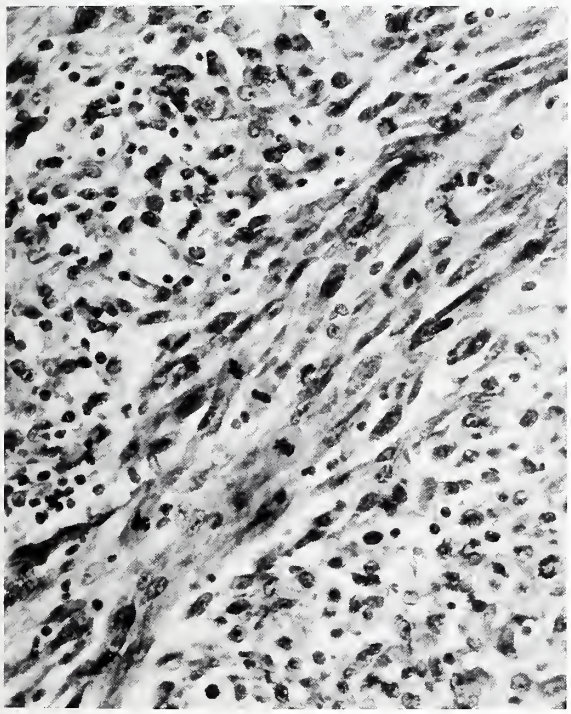

FIBROSARCOMA OF THE DURA

(Figures 206 and 207 from same case)

Figure 207. This high power view shows mitotic figures in a fibrosarcoma. van Gieson. × 285. (Fig. 2 from Rubinstein, L. J. Sarcomas of the Nervous System. Vol. 2, Pathology of the Nervous System. (Ed.) Minckler, J. New York: McGraw-Hill Book Company, 1971).

Spindle Cell Sarcoma

The spindle cell type shows a general preservation of the architecture in streams and parallel bundles, but the cells are generally smaller and plumper, and may exhibit a somewhat greater degree of pleomorphism than the better differentiated fibrosarcomas (fig. 208). At first glance they may even resemble the "spongioblastic" type of glioblastoma, but the distinction can easily be made by examining the growing edge of the tumor, where infiltration of the adjacent brain is evident. Connective tissue stains usually reveal a greater amount of reticulin fibers than might at first be suspected from hematoxylin-eosin preparations. Microscopic foci of necrosis may be present, often infiltrated by acute and chronic small inflammatory cells (fig. 208). The surviving elements may be arranged around them in a manner that resembles the pseudopalisades of a glioblastoma multiforme, but the characteristic polar alignment of the tumor cells is lacking.

In most cases the microscopic picture of meningeal fibrosarcomas and spindle cell sarcomas lacks any feature that might recall the antecedent presence of a more benign meningiomatous phase. Occasionally successive examination of a recurrent meningioma discloses the conversion of a previous meningotheliomatous stage into a tumor that has acquired the features of an invasive fibrosarcoma (Rubinstein, 1956). Again occasionally a history of several years of focal seizures before the excision of a spindle cell sarcoma may inferentially support the view that an anaplastic change took place in an originally more benign meningioma (fig. 208; pl. XIV–A). Plate VII–A illustrates the edge of an infiltrating meningeal sarcoma surrounding islands of reactive neuroglia in a circumscribed meningeal tumor of a 53-year-old woman, which in most areas consisted of a fibroblastic meningioma (Rubinstein, 1956, Case 1). Through the courtesy of Dr. J. A. Wilkerson, we are

illustrating on plate VII–B the exceptional picture of a deep intracerebral spindle and polymorphic cell sarcoma in a 3-year-old girl, which incorporates well defined islands that have the classic cytologic features of a meningotheliomatous meningioma. While they might conceivably be thought to represent encompassed foci of reactive proliferating meningeal cells that have been mobilized by the advancing malignant tumor, this interpretation is unlikely in view of their widespread presence in the section.

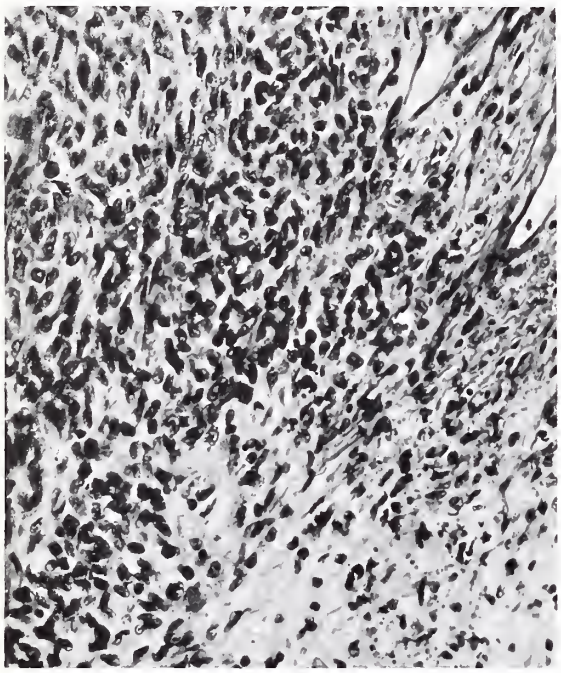

SPINDLE CELL SARCOMA OF THE LEPTOMENINGES

(Figure 208 and Plate XIV-A from same case)

Figure 208. This spindle cell sarcoma arose from the leptomeninges in a 21-year-old woman. The area of cellular rarefaction in the lower end of the picture is due to early necrosis. van Gieson. × 260. (Fig. 3 from Rubinstein, L. J. Sarcomas of the Nervous System. Vol. 2, Pathology of the Nervous System. (Ed.) Minckler, J. New York: McGraw-Hill Book Company, 1971).

The more likely explanation is that they represent more benign foci of meningioma that have now been overtaken by the more rapidly growing sarcomatous elements.

Polymorphic Cell Sarcoma

The polymorphic cell sarcomas are the least differentiated group, and biologically the most malignant, usually occurring in infants. The microscopic picture is characterized by considerable pleomorphism of the cell elements, which may include a number of multinucleated and giant cell forms, although these do not dominate the picture. The cytoplasm is ill-defined, often almost syncytial. The nuclei are irregular, lobulated or dumbbell-shaped, often with single or multiple central nucleoli (fig. 209). The nuclear membranes are well defined, and the nucleoplasm is pale and lightly basophilic. The cellular architecture (fig. 209) is usually not distinctive, but occasionally a distinct arrangement in perivascular pseudorosettes is found (fig. 210), reminiscent of the papillary structures seen in malignant meningiomas (p. 186). The appearances may mimic those of an astroblastoma, but typical footplates are not present and specific staining and impregnation methods for neuroglia are negative. The blood vessels are characteristically thin-walled and devoid of vascular endothelial proliferation.

Reticulin formation varies in the polymorphic cell sarcomas; in some examples it is relatively abundant, in others it is scanty and focal. It may be absent altogether, which is not surprising in view of the anaplastic character of the tumor elements. This feature deserves emphasis because the demonstration of reticulin fibers is of little diagnostic help in the recognition of these poorly differentiating tumors.

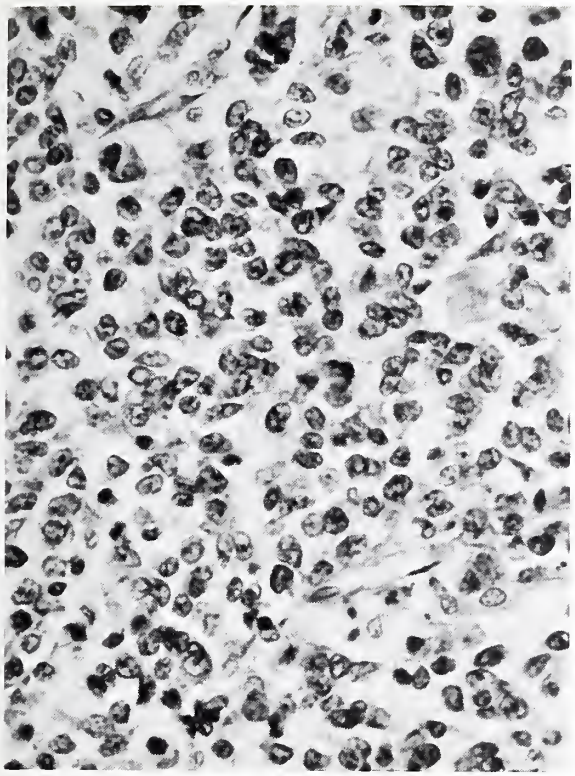

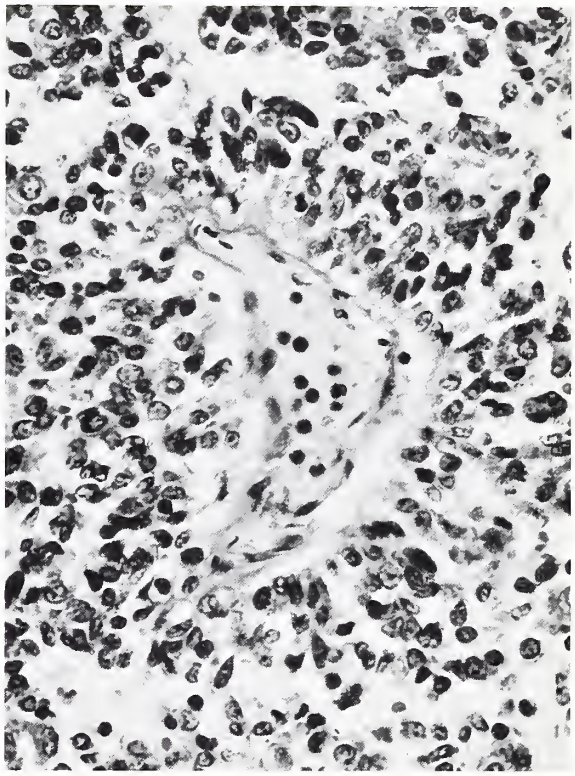

POLYMORPHIC CELL SARCOMA

(Figures 209 and 210 from same case)

Figure 209. This polymorphic cell sarcoma arose in the posterior fossa of a 5-month-old infant. van Gieson. × 400.

Figure 210. This illustrates focal perivascular arrangement of the tumor cells. × 350.

GROWTH AND SPREAD. An important diagnostic aspect of cerebral sarcomas is the way in which they infiltrate the brain. Some of the more differentiated examples, usually fibrosarcomas arising from the dura or the leptomeninges, may demonstrate relatively little invasion. Most show characteristic peripheral tongues of growth which penetrate irregularly the surrounding parenchyma. The sarcoma cells may sometimes form thin collars around apparently newly formed blood vessels in the neural tissues. Characteristically, however, distinct islands of neuroglia are encompassed by the advancing sarcoma (pl. VII–A, C, D), a feature which greatly helps in distinguishing invasive sarcomas from anaplastic gliomas. While these islands can usually easily be recognized in hematoxylin-eosin preparations, they are much more evident with special staining technics, especially the van Gieson and PTAH stains (pl. VII–C, D). These stains moreover permit the immediate identification of surviving preexisting neuroglial elements that have remained segregated intact for considerable distances within the confines of the growing tumor. They also demonstrate the considerable hypertrophy that may characterize the astrocytic elements, a change that in some cases may progress to actual neoplastic transformation.

PLATE VII

MENINGEAL SARCOMA

(Plate VII-B, C, and D from same case)

A. An infiltrating meningeal sarcoma forms tongues of advancing mesodermal tissue (stained blue) among reactive neuroglial parenchyma (pale orange areas). This area is from the edge of an invasive meningeal sarcoma in a 53-year-old woman. Azocarmine. × 100.

B. Distinct and in places circumscribed islands of endotheliomatous meningioma contain dark red-staining psammoma bodies and are surrounded by less well differentiated fibrosarcoma. The section is from a deep primary cerebral sarcoma probably arising from the meninges in a 3-year-old girl. van Gieson. × 150.

C. Conspicuous islands of large hypertrophic astrocytes (stained greenish yellow) are surrounded by more darkly staining, poorly differentiated sarcoma cells. van Gieson. × 250.

D. With this stain the islands of reactive hypertrophic astrocytes stain intensely blue and show conspicuous neuroglial fibers. The intervening fibrous connective tissue stains tan. PTAH. × 265.

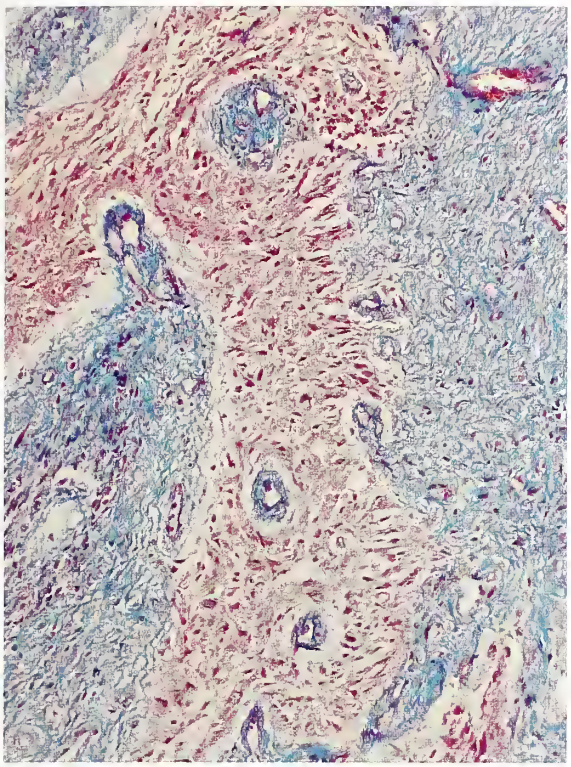

A

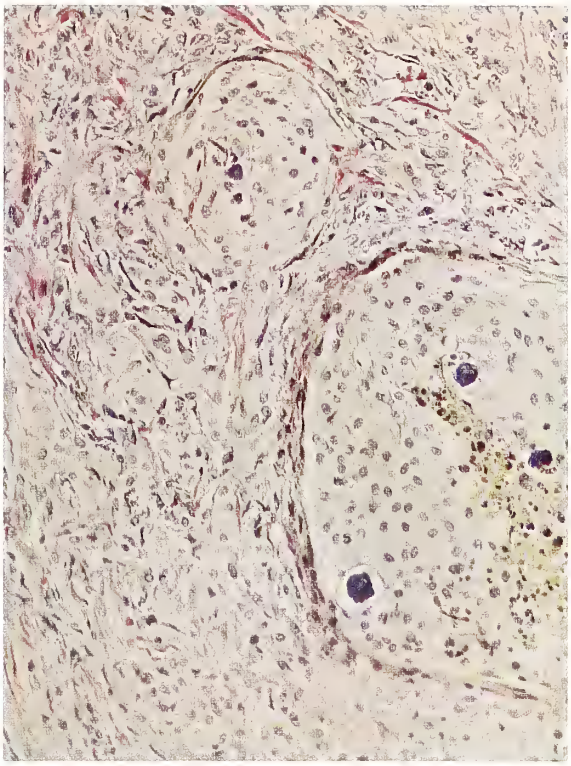

B

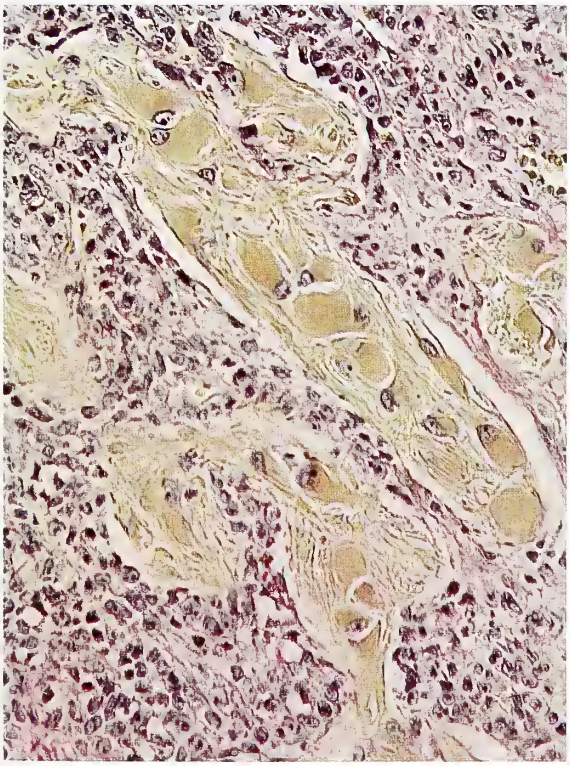

C

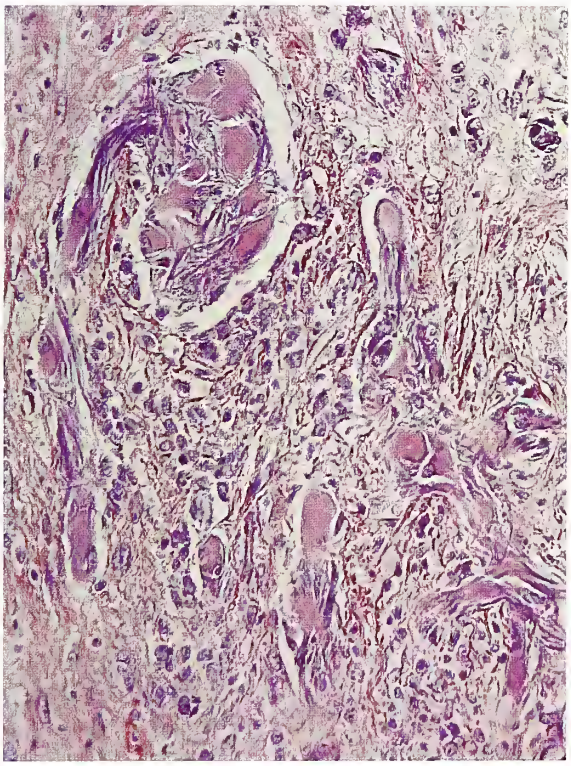

D

PLATE VII

MALIGNANT GLIOMATOUS REACTION. MIXED SARCOMAS AND GLIOMAS. Malignant transformation in reactive gliosis is extremely uncommon, but has been reported in six examples (Rubinstein, 1956; Kernohan and Uihlein; Rubinstein, 1964; Henry and Leestma). The cytologic picture of the neuroglia adjacent to the sarcoma or of the encompassed neuroglial islands acquires features indicative of cytologic malignancy including: increased cellularity, hyperchromatism, nuclear irregularity, giant cell formation, and multinucleation (figs. 211–213; pl. XIII–A, B, C). This malignant neuroglial reaction, which is therefore the source of a form of mixed glioma and sarcoma whose origin is quite distinct from the type of sarcoma arising in a glioblastoma described on page 74, is best demonstrated with special staining and impregnation technics, including those for reticulin and for neuroglial elements. The zones of neoplastic neuroglia stand out as reticulin-free islands among the tongues of invasive sarcoma (fig. 211). All stages may be seen between atypical reactive hyperplasia and frank neoplasm formation. The neuroglial nature of the malignant cell islands demonstrated with routine stains in figure 212 is confirmed with appropriate silver carbonate impregnations shown in plate XIV–B and C. The silver positivity of the cells in the islands contrasts with the lack of metallic affinity of the surrounding sarcomatous elements. In places the gliomatous element has acquired the classic microscopic features of a glioblastoma (fig. 213). A similar development has been reported by Kernohan and Uihlein in a mixed fibrous chondrosarcoma and malignant astrocytoma in a 56-year-old woman (their Case 6). It should be noted that this malignant glial reaction may remain localized to the gross margin of the sarcoma. The patient in the case illustrated in plate XIV–A was known to be alive and well 12 years after removal of the tumor.

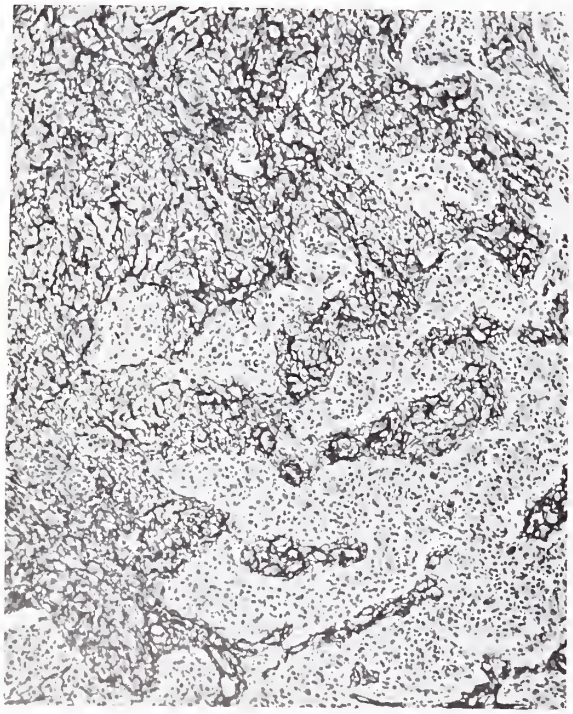

Fig. 211

MALIGNANT GLIOMATOUS REACTION SECONDARY TO INVASIVE SARCOMA

(Figures 211–213 and Plate XIV-C from same case)

Figure 211. In this low power view the edge of an invasive fibrosarcoma (dark areas) in a 60-year-old woman encompasses pale areas of neoplastic astrocytic reaction. Silver stain for reticulin. × 59. (Fig. 2 from Rubinstein, L. J. Morphological problems of brain tumors with mixed cell population. Acta Neurochir. Supp. X:141–158, 1964).

MALIGNANT GLIOMATOUS REACTION SECONDARY TO INVASIVE SARCOMA

(Figures 211–213 and Plate XIV-C from same case)

Figure 212. A high power view shows islands of malignant astrocytoma surrounded by sheaths of sarcoma cells. See the silver carbonate impregnation of this area in plate XIV-C. van Gieson. × 270. (Fig. 20 from Rubinstein, L. J. Sarcomas of the Nervous System. Vol. 2, Pathology of the Nervous System. (Ed.) Minckler, J. New York: McGraw-Hill Book Company, 1971).

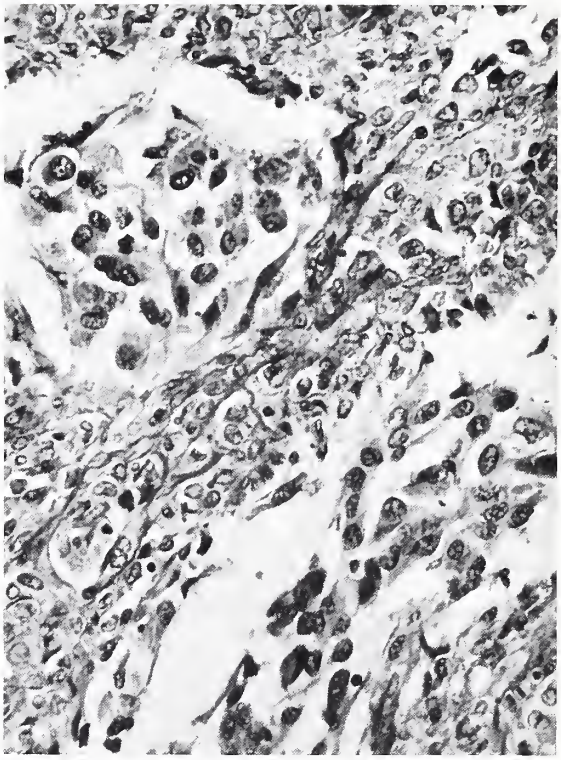

Fig. 212

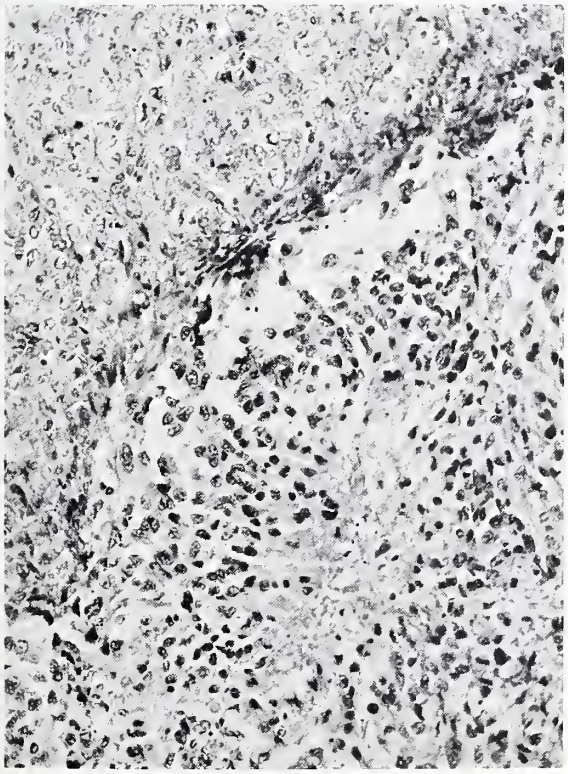

Fig. 213

MALIGNANT GLIOMATOUS REACTION SECONDARY TO INVASIVE SARCOMA

(Figures 211–213 and Plate XIV-C from same case)

Figure 213. An edge of sarcomatous tumor is shown (upper left) with an adjacent rim of malignant glioma (lower right). Note the early pseudopalisade formation of glioblastoma multiforme. van Gieson. × 180.

VARIANTS

Meningeal Meningiomatosis (Primary Sarcomatosis)

This rare form is a variant of sarcoma in which multifocal neoplastic disease involves the leptomeninges diffusely without the presence of a definite mass. Although adults are occasionally affected, it has been recorded especially in infants and children (Black and Kernohan; Willis, 1962). In a few cases the clinical course resembles that of a meningoencephalitis.

The gross picture is that of generalized infiltration of the leptomeninges by a grayish or milky exudate, which may be accompanied by small nodules of subarachnoid tumor at various sites along the cerebrospinal axis. In extreme cases the greater part of the spinal cord may be encased by tumor, with the production of a "bamboo stick" appearance (Brown and Kernohan). Internal hydrocephalus may result in some cases (Kernohan and Uihlein). The microscopic picture may be that of a spindle cell sarcoma with numerous reticulin fibers, or more commonly one that is indistinguishable from the polymorphic type of intracranial sarcoma (figs. 209, 210).

Myxosarcomas and Chondrosarcomas

Rare examples, usually arising from and attached to the meninges, have been recorded (Kernohan and Uihlein).

Mesenchymal Chondrosarcoma

This rare neoplasm, originally described in bone, has occasionally been reported to arise intracranially, attached to the dura in one instance (Kernohan and Uihlein, Case 9; Raskind and Grant). An example that arose as an intradural extramedullary tumor in the lower thoracic region of a 16-year-old girl is shown in Figure 214. It was attached to the dura and intimately related to the nerve roots. The histologic picture is distinctive and characterized by compact areas composed of sheaths or whorls of fusiform cells, often in mitosis, that alternate with less densely cellular zones in which chondroblastic, osteoid, and osseous differentiation is present (fig. 214). Many areas also show considerable vascularity, the vessel spaces being lined by a single layer of flattened endothelial cells. This may account for the spontaneous hemorrhage that was the presenting sign in the case reported by Raskind and Grant.

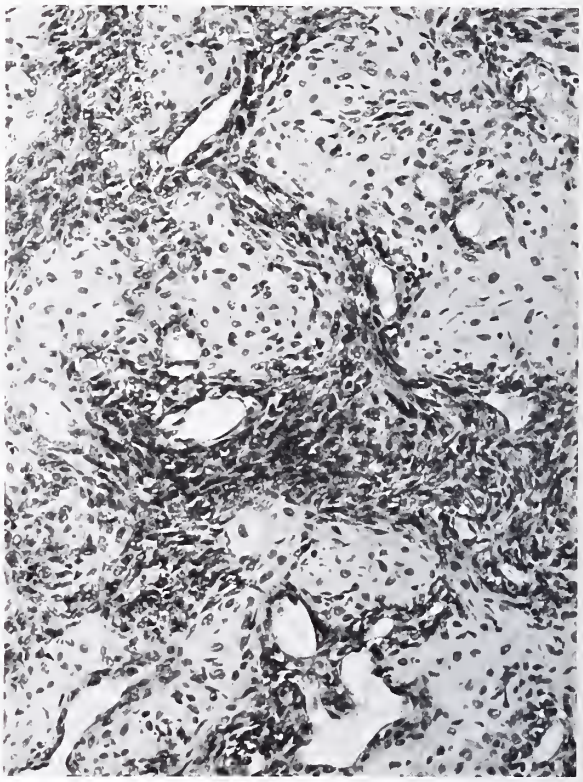

MESENCHYMAL CHONDROSARCOMA

Figure 214. A chondroid appearance is illustrated in a case of mesenchymal chondrosarcoma arising from the spinal dura in a 16-year-old girl. × 150. (Fig. 14 from Rubinstein, L. J. Sarcomas of the Nervous System. Vol. 2, Pathology of the Nervous System. (Ed.) Minckler, J. New York: McGraw-Hill Book Company, 1971).

Embryonal Sarcoma

SYNONYMS AND RELATED TERMS: Rhabdomyosarcoma; mixed malignant mesenchymal tumor.

Rhabdomyosarcomas have occasionally been recorded in the central nervous system (O'Connell; Lopes de Faria; Shuangshoti et al.). The presence of striated muscle fibers when associated with neuroepithelial elements (see pp. 142 and 287) might be interpreted as evidence for the teratomatous nature of these tumors. When this association is lacking, an alternative interpretation is that they are the expression of a multipotential divergent differentiation on the part of a highly plastic embryonic type of mesenchymal tissue (Willis, 1960). Supporting this view in some instances is the finding in these tumors of other metaplastic changes including cartilage, osteoid, bony, and adipose tissue (figs. 215, 216). Figure 215 is taken from a tumor arising in the pontocerebellar angle of a woman of 45 years, which had seeded extensively in the spinal leptomeninges, and to a lesser degree over the cerebrum. Chondroblastic differentiation is illustrated. Rhabdomyoblastic differentiation was also present in the subarachnoid metastases. Figure 216 is taken from another case of tumor arising from the parietal dura in a 41-year-old man, in which the neoplasm had the gross appearance of a large, well demarcated meningioma. Both rhabdomyoblastic differentiation and foci of mature cartilage were found in this tumor.

METASTASIS. The more malignant forms of sarcoma, especially the polymorphic cell sarcomas, are apt to metastasize widely in the cerebrospinal fluid pathways, as recorded by Christensen and Lara, by Tarlov and Keener, and in four cases I have

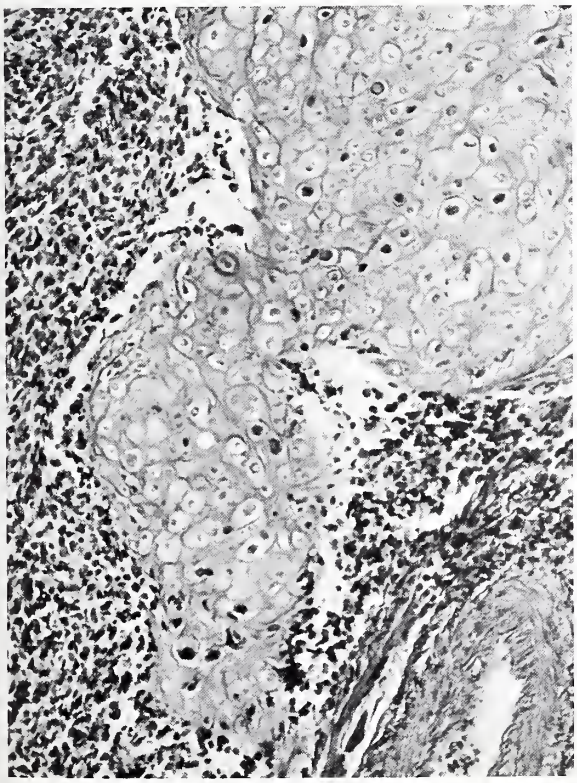

Fig. 215

EMBRYONAL SARCOMA (MIXED MALIGNANT MESENCHYMOMA)

Figure 215. This is a focus of chondroblastic differentiation in a mixed malignant mesenchymoma that disseminated in the subarachnoid space. × 115. (Fig. 17 from Rubinstein, L. J. Sarcomas of the Nervous System. Vol. 2, Pathology of the Nervous System. (Ed.) Minckler, J. New York: McGraw-Hill Book Company, 1971).

EMBRYONAL SARCOMA (MIXED MALIGNANT MESENCHYMOMA)

Figure 216. Cross striations are seen in elongated straplike rhabdomyoblasts in another case of embryonal sarcoma arising in the brain. PTAH. × 770. (Fig. 16 from Rubinstein, L. J. Sarcomas of the Nervous System. Vol. 2, Pathology of the Nervous System. (Ed.) Minckler, J. New York: McGraw-Hill Book Company, 1971).

examined. Extraneural metastases are exceptional, but have been reported by Bennington and Jones in a polymorphic cell sarcoma that arose in the vermis of a 4½-year-old boy and metastasized in the leptomeninges, to liver, lung, and bone marrow; this was accompanied by massive local recurrence of the primary growth, with invasion of the muscle and fascia. Through the courtesy of Dr. Ivan Herzog, I have examined another example arising in the basal ganglia of a 15½-month-old girl, in which distant metastasis through the cerebrospinal axis and to the lungs, pleurae, and mediastinal lymph nodes had taken place two and one-half months after exploratory craniotomy.

TREATMENT. Where the tumor is circumscribed and surgically removable, extirpation is the only hopeful method of treatment. It is very doubtful whether radiation plays any part in therapy, but it is sometimes administered to the less differentiated examples without evidence that it has any beneficial effect.

PROGNOSIS. Most sarcomas, especially the polymorphocellular type, have a very unfavorable prognosis. However, some examples of well differentiated fibrosarcoma and spindle cell sarcoma, in which complete enucleation has been performed are known to have had a long postoperative survival. One patient with a localized fibrosarcoma of the dura reported by Bailey and

Ingraham is known to have been in good health and gainfully employed 26 years later (Dr. O. T. Bailey, personal communication). Instances of long survival up to 14 years have been reported by Christensen and Lara. A 21-year-old woman with a spindle cell sarcoma arising from the temporal leptomeninges was known to be alive and gainfully employed 12 years after surgery (fig. 208; pl. XIV–A).

DIFFERENTIAL DIAGNOSIS. The more differentiated collagen-forming tumors pose no problem. The fusiform outline of the cells may give rise to confusion with the spongioblastic form of glioblastoma. The presence of reticulin fibers and the typical pattern of infiltration of the neighboring brain at the periphery of the growth usually make the distinction easy. The demonstration of reticulin fibers alone, however, is inadequate for the diagnosis of sarcoma, owing to the propensity of gliomas to invade the leptomeninges and consequently to stimulate a vigorous fibrous connective tissue reaction. This is particularly evident in the case of superficial glioblastomas that have become tethered to the dura (pp. 70 and 83), and of the desmoplastic variant of medulloblastoma described on pages 143 and 146 and illustrated in Figures 151–159. The differential diagnosis of polymorphic cell sarcoma may be the source of considerable difficulty. Its high cellularity and the lack of differentiating neuroglial features may invite a resemblance to both the neuroblastoma of the cerebral hemispheres and, in some cases, to cerebellar medulloblastoma. However, the cells of the primitive sarcoma are usually more pleomorphic than those of the other two. In both polymorphic cell sarcoma and cerebral neuroblastoma, the tumor may be intersected by a very abundant connective tissue network (fig. 170). This feature therefore is of little help in differential diagnosis. The occasional formation in polymorphic cell sarcomas of perivascular pseudorosettes (fig. 210) may also call to mind an ependymoma or an astroblastoma. The diagnosis of polymorphic cell sarcoma rests usually on the recognition of its pattern of infiltration in the adjacent brain, the characteristic features of the individual cell elements, and the absence of features suggestive of a neuroectodermal neoplasm.

CONTROVERSIAL ENTITIES. For the sake of completeness, a short note is appended on those tumors that have been claimed in the literature to be a form of sarcoma, but are discussed under different headings in this fascicle.

The so-called "circumscribed arachnoidal cerebellar sarcoma" is not regarded here as a distinct histologic entity, and is interpreted as a variant of medulloblastoma with extensive infiltration of the leptomeninges. It is discussed in detail on pages 142 through 146.

The "monstrocellular sarcoma" of Zülch or "giant cell fibrosarcoma" of Kernohan and Uihlein are interpreted as a form of giant cell glioblastoma in which the presence of abundant reticulin network is due to the intense vascularity of the tumor (p. 72). Some of the cases illustrated by Zülch are interpreted as mixed glioblastomas and fibrosarcomas (p. 74).

The "hemangiopericytoma of the leptomeninges" classified by Kernohan and Uihlein as a form of cerebral sarcoma is identical with the angioblastic meningioma as originally defined by Bailey, Cushing, and Eisenhardt, and is discussed on page 180.

References

Bailey, O. T., and Ingraham, F. D. Intracranial fibrosarcomas of the dura mater in childhood: pathological characteristics and surgical management. J. Neurosurg. 2:1–15, 1945.

Bailey, P., Cushing, H., and Eisenhardt, L. Angioblastic meningiomas. Arch. Path. 6:953-990, 1928.

Bennington, J. L., and Jones, R. E., Jr. Primary sarcoma of the cerebellum (cerebellar sarcoma) with extracranial metastases. J. Neurosurg. 19:685–690, 1962.

Black, B. K., and Kernohan, J. W. Primary diffuse tumors of the meninges (so-called meningeal meningiomatosis). Cancer 3:805–819, 1950.

Brown, M. H., and Kernohan, J. W. Diffuse meningiomatosis. Arch. Path. 32:651–658, 1941.

Christensen, E., and Lara, D. E. Intracranial sarcomas. J. Neuropath. Exp. Neurol. 12:41–56, 1953.

Henry, J. M., and Leestma, J. E. Astrocytoma arising in meningeal fibrosarcoma. Acta Neuropath., in press, 1971.

Kernohan, J. W., and Uihlein, A. Sarcomas of the Brain. Springfield, Ill.: Charles C Thomas, 1962.

Lopes de Faria, J. Rhabdomyosarcoma of cerebellum. Arch. Path. 63:234–238, 1957.

O'Connell, J. E. A. The subarachnoid dissemination of spinal tumours. J. Neurol. Neurosurg. Psychiat. 9:55–62, 1946.

Raskind, R., and Grant, S. Primary mesenchymal chondrosarcoma of the cerebrum. Report of a case. J. Neurosurg. 24:676–678, 1966.

Rubinstein, L. J. The development of contiguous sarcomatous and gliomatous tissue in intracranial tumours. J. Path. Bact. 71:441–459, 1956.

_____. Morphological problems of brain tumors with mixed cell population. Acta Neurochir., Supp. X:141–158, 1964.

_____. Sarcomas of the Nervous System, pp. 2144–2164. Pathology of the Nervous System, Vol. 2. (Ed.) Minckler, J. New York: McGraw-Hill Book Company, 1971.

Shuangshoti, S., Piyaratn, P., and Viriyapanich, P. L. Primary rhabdomyosarcoma of cerebellum—necropsy report. Cancer 22:367–371, 1968.

Tarlov, I. M., and Keener, E. B. Subarachnoid hemorrhage and tumor implants from spinal sarcoma in an infant. Neurology 3:384–390, 1953.

Waltz, T. A., and Brownell, B. Sarcoma: a possible late result of effective radiation therapy for pituitary adenoma. Report of two cases. J. Neurosurg. 24:901–907, 1966.

Willis, R. A. Pathology of Tumours. 3d. Ed. London: Butterworth & Co., Ltd., 1960.

_____. The Pathology of the Tumours of Children. Edinburgh: Oliver & Boyd, Ltd., 1962.

Zülch, K. J. Biologie und Pathologie der Hirngeschwulste. In: Handbuch der Neurochirurgie, Vol. 3. (Eds.) Olivecrona, H., and Tonnis, W. Berlin: Springer, 1956.

TUMORS OF THE CRANIAL AND SPINAL NERVE ROOTS

DEFINITION. The tumors to be described are derived from and composed of some of the cell elements that ensheathe the axons of the peripheral nerves as they leave the central nervous system.

HISTOGENESIS AND NOMENCLATURE. The cells that surround the axons of the nerve roots include the Schwann cells; the fibroblasts (or fibrocytes) that form part of the epineurium and of the endoneurium; and the special cells that constitute the sheath of the perineurium and have often in the past been designated as "perineurial fibroblasts," but for which the term "perineurial cell" or "perineurothelial cell" is probably more appropriate (Waggener et al.; Cravioto, 1966). The histogenesis and nomenclature of these neoplasms remain a matter of much debate that essentially revolves around two issues. The first concerns the cell of origin, for which two candidates have long been proposed by the opposing schools: the Schwann cell on the one hand, and the fibroblast, especially the perineurial fibroblast, on the other. Inherent to this aspect of the controversy are the presence of connective tissue fibers (collagen and reticulin) in these tumors and the question whether the Schwann cell, as well as the fibroblast, is capable of synthesizing collagen. The second point at issue is whether the nerve sheath tumors constitute a single entity or should be divided into two separate morphologic groups; namely, schwannomas or perineurial fibroblastomas on the one hand and neurofibromas on the other.

The advent of the electron microscope has complicated rather than simplified the problem, and has to some extent shifted the ground of the controversy. The identification of the normal Schwann cell with its basement membrane following the contour of the plasmalemma has given decisive weight to the view that the nerve sheath tumors are composed of Schwann cells or cells that are morphologically identical with them. Ordinary fibroblasts, such as those found in the endoneurium, have no basement membrane and can now be ruled out as the cells of origin. However, the perineurial cell has morphologic characters that are virtually indistinguishable from those of the Schwann cell, except that it lacks the normal intimate relationship of the latter to the axons. Harkin and Reed consider this cell as a form of Schwann cell, and consequently adhere to the single term of schwannoma for the common form of benign nerve sheath tumor of that name, postulating that it may arise from either or both cell types. This equation of the Schwann cell with the perineurial cell has still to meet with general acceptance. Most electron microscopists at this time favor the view that the nerve sheath tumors are derived from the Schwann cells in the conventional sense, and several accept with considerable reserve only the alternative possibility that perineurial cells could be the cells of origin of these tumors.

The problem of connective tissue fiber formation has also shifted, as the result of electron microscopic observations, to two major issues that are still unresolved: the first is whether the Schwann cell and, by the same token, its alternative candidate, the perineurial cell, are capable of synthesizing collagen; the second revolves on the identification of the argyrophilic fibers that

are found in unusual abundance in schwannomas. The first question can only be resolved by autoradiographic technics using labeled amino-acid precursors of collagen. As to the second, there is mounting evidence that the presence of polysaccharide-rich basement membrane material may play an important role in determining, in certain circumstances, the staining affinities of argyrophilic reticulin fibers as seen under the light microscope. Of course the finding of collagen fibrils in schwannomas, as identified by their characteristic fine structural periodicity, is not in question.

Most electron microscopists also support the distinction seen by light microscopy between the structure of the schwannoma on the one hand and of the neurofibroma on the other. In both cases, however, the principal cell is the same, namely the Schwann cell (Luse; Waggener; Poirier et al.). In this fascicle as in the fascicle "Tumors of the Peripheral Nervous System" by Harkin and Reed, the major division of nerve sheath tumors into **schwannomas** and **neurofibromas** is therefore maintained.

SCHWANNOMAS

SYNONYMS AND RELATED TERMS: Neurinoma; perineurial fibroblastoma; neurilemoma. The term "acoustic neuroma" is frequently, and the term "acoustic neurofibroma" sometimes, employed for acoustic schwannoma.

DEFINITION. These tumors are composed of Schwann cells that envelop the axons of the peripheral nerve roots as they leave the central nervous system. Arguments that point to the neuroectodermal origin of these cells or to their equivalence to the "peripheral glia" are of very limited value in the understanding of the histogenesis and development of these neoplasms.

SITES AND INCIDENCE. Within the cranial cavity and spinal canal, schwannomas may arise from both the cranial and the spinal nerve roots. In both situations the sensory nerves are much more frequently affected than the motor. Schwannomas account for about 8 percent of all primary tumors in the intracranial cavity; the overwhelming majority originate from the acoustic nerve, particularly its vestibular branch (Skinner). Considerably rarer in the intracranial cavity are those that arise from the trigeminal nerve (Olive and Svien; Schisano and Olivecrona). The other cranial nerves are involved only exceptionally, but multiple tumors of the cranial nerve roots are a characteristic finding in the central form of von Recklinghausen's disease.

In the **spinal canal**, schwannomas account for the largest proportion of spinal tumors, 29 percent according to the extensive material analyzed by Slooff and associates, being followed closely by the meningiomas. They predominate in the lumbar region (40 percent). Both the intracranial and spinal tumors are found in the middle decades of life, usually the fifth. The intracranial examples show a preponderance in females; those in the spinal canal show a preponderance in males.

CLINICAL DATA. The clinical presentation of acoustic nerve tumors is usually that of a pontocerebellar lesion with cerebellar dysfunction and symptoms of deafness and other cranial nerve compromise, especially involving the sensory distribution of the trigeminal nerve with early loss of the corneal reflex. The spinal examples present as intradural extramedullary neoplasms, often with local nerve root symptoms and signs.

MULTIPLICITY. ASSOCIATED LESIONS. Multiple schwannomas of the cranial and peripheral nerve roots, histologically indistinguishable from the solitary examples, are typical of the central form of von Recklinghausen's neurofibromatosis. They are then very frequently associated with multiple cranial and spinal meningiomas and with gliomas of the central neuraxis, especially astrocytomas and ependymomas (p. 303). Bilateral acoustic schwannomas are especially characteristic, but very occasionally bilateral tumors are found in the absence of von Recklinghausen's disease; a few families have also been reported in which these were transmitted as a mendelian dominant over several generations (Gardner and Turner; Moyes).

GROSS. Schwannomas are well defined and encapsulated, and compress the adjacent tissue without invading it. Those that arise from the acoustic nerve present as a pontocerebellar angle mass that may cause severe excavation of the pons and the medulla (fig. 217). On section the tumor is firm, occasionally lobulated, with grayish cut surfaces often flecked with hemorrhage and frequently showing creamy yellow areas that contain large amounts of lipid (fig. 218). Occasionally cysts are found. The overwhelming majority of acoustic schwannomas take their origin at the site of entrance of the acoustic nerve in the internal auditory meatus (fig. 218). This is the point where the nerve root acquires its sheath of Schwann cells. Enlargement of the internal auditory meatus is therefore an early feature and a well known radiologic diagnostic sign. Small examples that are found incidentally postmortem are almost always closely related to the internal auditory meatus, which on careful measurement is found to be enlarged. In cases in which the tumor has been allowed to grow, considerable distortion and compression of the brainstem occurs, especially the middle cerebellar peduncle, with marked displacement and flattening of the fourth ventricle (fig. 218). The acoustic nerve is usually incorporated in the capsule of the tumor.

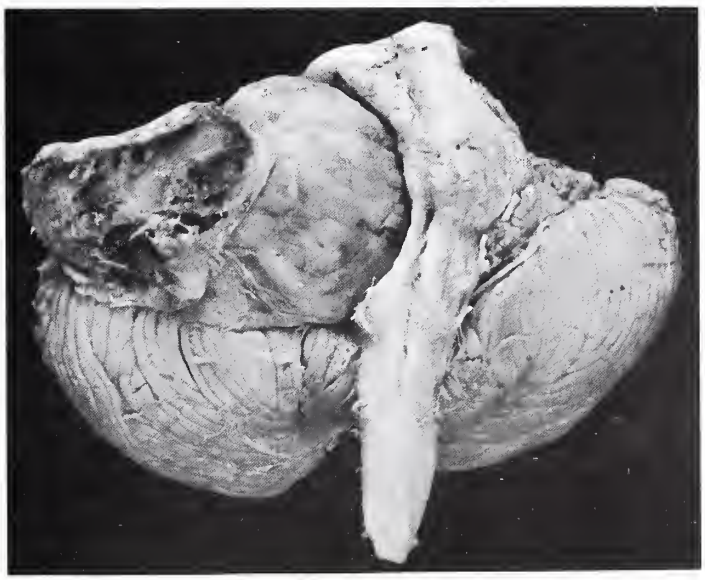

ACOUSTIC SCHWANNOMA

(Figures 217 and 218 from same case)

Figure 217. This acoustic schwannoma occupies the right pontocerebellar angle. Note the marked excavation of the pons and medulla by the tumor. Part of the petrous temporal bone is attached to the growth. (Fig. 68 from Fascicle 35, First Series.)

ACOUSTIC SCHWANNOMA

(Figures 217 and 218 from same case)

Figure 218. Transverse section reveals numerous small areas of hemorrhage in this fibrous-looking tumor. The petrous temporal bone has been sectioned and shows clearly (lower left) that the tumor occupies the internal auditory meatus. The large majority of acoustic schwannomas take their origin at this site, and enlargement of the acoustic foramen is therefore an early feature frequently seen radiologically. The reason for this is that the Schwann cells from which the tumor arises generally make their appearance only at the site where the acoustic nerve penetrates the internal auditory meatus. Note the marked deformity and compression of the pons and middle cerebellar peduncle. The fourth ventricle is considerably compressed and reduced to a narrow slit. (Fig. 69 from Fascicle 35, First Series).

Fig. 218

The schwannomas arising from the trigeminal nerve, especially from its ganglion, may occupy either the middle fossa or the cerebellopontine angle. Some examples are dumbbell-shaped and occupy both the middle and posterior fossae. Considerable erosion of the petrous temporal bone is a frequent accompaniment, but this feature may also be present in the case of schwannomas that originate from the acoustic nerve, especially when the neoplasm arises from the intraosseous portion of the nerve (Best).

Intraspinal schwannomas have the same characteristic gross features as the intracranial examples, forming smooth encapsulated ovoid masses which may cause cord compression (fig. 219). The tendency to cyst formation is greater in the spinal than in the intracranial examples.

INTRASPINAL SCHWANNOMA

Figure 219. A well demarcated, nodular extramedullary tumor compresses the ventral surface of the upper cervical segment. It arose from the first right anterior cervical nerve root. This is a very unusual site for a spinal schwannoma; most originate from a dorsal nerve root. (Courtesy of Dr. J. E. Olvera-Rabiela, Mexico City, Mexico; also fig. 4 from Rubinstein, L. J. Seminario de Neuropatologia, Mérida, Yucatán, Bol. Asoc. Mex. Patol., A. C. 7:13–59, 1969).

Occasionally an intraspinal nerve root schwannoma extends in a dumbbell manner through the intervertebral foramen to form a larger mass outside the spinal canal. Considerable erosion of the bone is then usually detected radiologically.

MICROSCOPIC. The microscopic aspects of schwannomas are described and illustrated in detail in the fascicle by Harkin and Reed; only the principal histologic features will therefore be reviewed here.

It is generally recognized that the histologic pattern can be divided into two types. In the **Antoni A type,** the tumor cells form compact interlacing bundles of elongated bipolar spindle elements with small darkly staining spindle nuclei and numerous delicate fibers that are parallel to the long axis of the cells (fig. 220). These fibers are strongly argyrophilic with silver stains for reticulin (fig. 221) and only seldom stain positively for collagen. Whether these fibers represent a form of collagen or possibly condensations of basement membrane material with or without an admixture of fibrils is yet undecided. The arrangement of the tumor cells in regular bundles often suggests a palisading effect (fig. 220), but the classic arrangement of Schwann cell nuclei aligned in periodic rows separated by pale bands of eosinophilic material (fig. 222) is only exceptionally found in acoustic schwannomas; it is most often seen in the spinal examples.

A less frequent arrangement is that of whorls of various sizes that may mimic those of transitional meningiomas (fig. 223). These formations are more usually found in schwannomas associated with von Recklinghausen's neurofibromatosis.

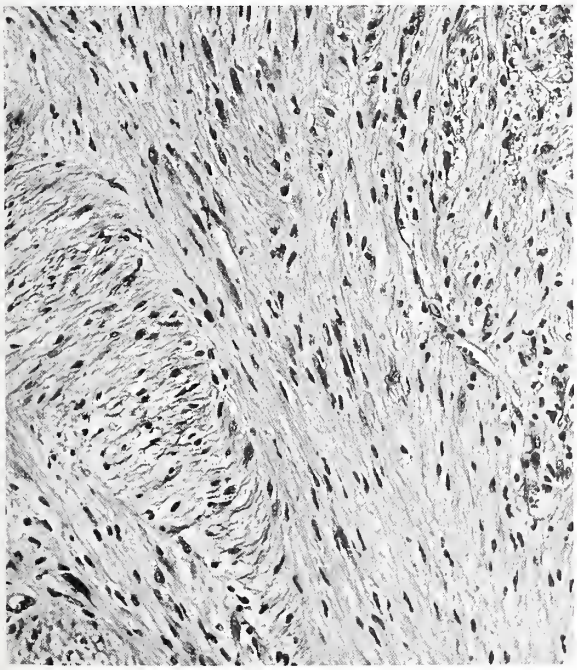

ACOUSTIC SCHWANNOMA

(Figures 220, 221, and 225 from same case)

Figure 220. Compact bundles of thin elongated, finely fibrillated cells form the Antoni A type of tissue in an acoustic schwannoma. × 165.

Figure 221. Fine argyrophilic fibrils in Antoni A tissue are seen in an acoustic schwannoma. Silver stain for reticulin. × 180.

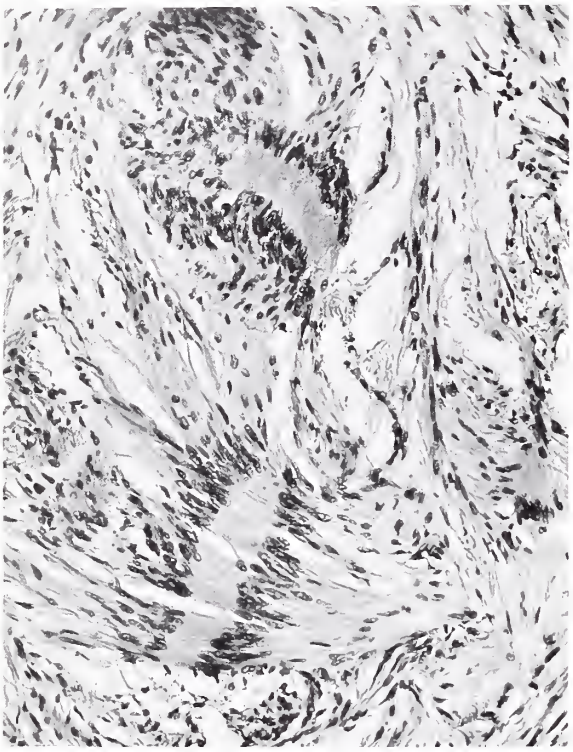

SPINAL SCHWANNOMA

(Figures 114, 115, 222, 223, 312, 314, and Plate VI-B from same case)

Figure 222. The marked palisading of nuclei is typical in this schwannoma arising in a lumbar dorsal root ganglion. This tumor is from a case of central neurofibromatosis. × 165.

SCHWANNOMA

(Figures 114, 115, 222, 223, 312, 314, and Plate VI-B from same case)

Figure 223. This illustrates the whorled pattern in a schwannoma originating in the cauda equina in a case of central neurofibromatosis with multiple schwannomas, meningiomas, and ependymomas. × 130.

The **Antoni B type** of tissue is found in contiguity with the Antoni A type, and consists in a much looser pattern of more pleomorphic cells that lack the arrangement in bundles and palisades found in the Antoni A type. The cells are often stellate with long irregular, coarsely staining eosinophilic processes. Microcystic degeneration is frequent (fig. 224). These areas may also undergo mucinous change. It is often stated that the Antoni B type of tissue is a degenerated form of Antoni A, but there is little evidence in support of this view. On the contrary, electron microscopic and histochemical observations suggest a high degree of metabolic activity in these cells, probably related to their capacity for storage and digestion. The Antoni A and B tissues show also distinct characters on tissue culture (Murray and Stout).

Secondary changes are frequent and consist in focal aggregations of foam cells containing sudanophilic lipid, iron pigment in macrophages resulting from old hemorrhage, and notable vascular alterations that include dilatation of the blood vessels, focal fibrinoid necrosis of the vessel walls, vascular thromboses of various ages, and hyaline thickening. Another feature especially common in Antoni B areas is the presence of large hyperchromatic, occasionally multinucleated giant cells (fig. 225).

This may sometimes evoke the suspicion of malignant change, but there is no evidence that it has any adverse significance. Although schwannomas arising from peripheral nerves have been reported to undergo malignant transformation in exceptional instances, no well documented example of a malignant change in an intracranial or intraspinal schwannoma has yet been reported. The presence of large atypical hyperchromatic nuclei irregularly scattered throughout the tumor has been illustrated by Harkin and Reed as a feature of so-called "ancient schwannomas."

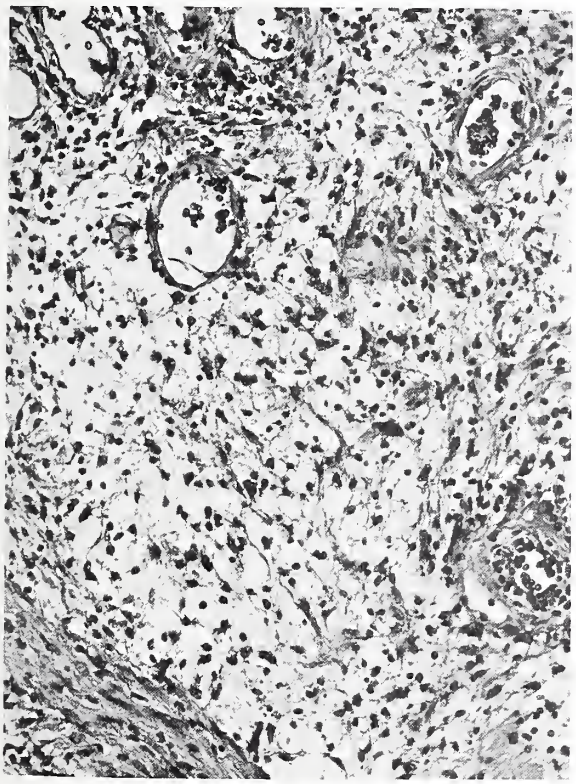

SPINAL SCHWANNOMA

Figure 224. A predominantly loose textured pattern of the Antoni B type is shown in a cystic spinal schwannoma. Antoni B tissue as shown here can be mistaken for astrocytoma by the unwary. Note the Antoni A type of tissue in left lower corner. × 180.

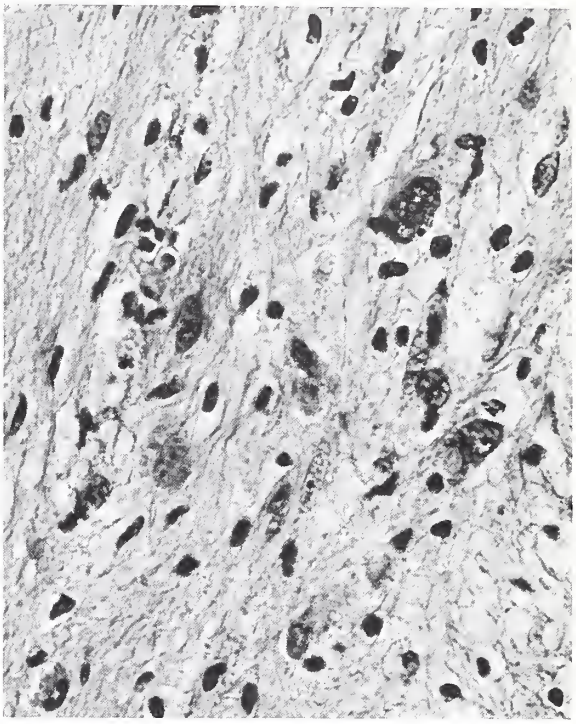

ACOUSTIC SCHWANNOMA

(Figures 220, 221, and 225 from same case)

Figure 225. Occasionally hyperchromatic giant cells are seen in an otherwise benign schwannoma. × 400.

Numerous electron microscopic observations on schwannomas have been performed, especially by Luse, Waggener, Poirier and Escourolle, Cervós-Navarro and associates, and Cravioto (1969). All these observers concur in describing the tumor elements as elongated cells with the morphologic features of Schwann cells, forming extremely thin interdigitating cell processes, with constant basement membrane material coating and separating the plasmalemmas. The morphologic findings in the Antoni B areas again recall those of Schwann cells, except that mitochondria, lysosomes, and nonmembrane bound osmiophilic bodies are a conspicuous feature in their cytoplasm. A characteristic finding in these tumors, but not restricted to them (Ramsey), is the presence of banded fusiform fibers with a

periodicity of 1200 to 1500 angstroms, which constitute a special form of long-spacing fibrous collagen (Luse; Cravioto and Lockwood).

Nerve fibers are very seldom found by light microscopy in nerve root schwannomas, except in the very early examples. Electron microscopy, too, occasionally discloses the presence of a myelinated nerve fiber in these neoplasms (Cravioto, 1969).

Intramedullary Schwannoma

Most cases of so-called "central schwannoma" are pilocytic gliomas, often associated with the central form of von Recklinghausen's disease. Very occasionally, however, true intramedullary schwannomas are recorded; they are presumably to be attributed to peripheral nerve sheath elements that accompany the intraspinal branches of the anterior spinal artery (Riggs and Clary; Scott and Bentz).

TREATMENT AND PROGNOSIS. The treatment is surgical; radiation plays no part. The surgical mortality rate in acoustic schwannomas appears directly related to the size of the tumor, being 4.5 percent for those measuring no more than 2 cm. in diameter, 16.5 percent for those up to 4 cm., and 22.5 percent in the larger examples. The overall mortality rate is between 15 and 20 percent (Olivecrona). In the overwhelming majority of cases operative mortality is due to pontine infarction, presumably following ligation of the anterior inferior cerebellar artery or one of its branches (Atkinson). This artery supplies in particular the middle cerebellar peduncle and the lateral angle of the fourth ventricle at the level of the midpons and upper medulla. According to Olivecrona the mortality rate within five years is almost twice as great after partial than after complete excision; this apparently results from the liability of recurrence after partial removal, which may occur in 25 percent of cases and will naturally increase the technical difficulties of subsequent operation. Of those patients surviving total removal, approximately 40 to 50 percent, depending on the size of the tumor, show normal working capacity. A well known operative risk is damage to or severance of the facial nerve. It can be preserved in about 50 percent of the cases when the tumor is small or medium sized, but in only one third of the cases when it is large.

DIFFERENTIAL DIAGNOSIS. The most frequent tumors with which a schwannoma may occasionally be confused are a meningioma and an astrocytoma. The palisading pattern occasionally seen in fibroblastic meningiomas may resemble that of a schwannoma, and conversely the whorling pattern of a schwannoma may recall the whorls of a transitional meningeal tumor. In the fibroblastic meningioma, however, the connective tissue is much coarser and often stains positively for collagen; it lacks the delicate fibrillary structure of the schwannoma or its pattern of palisading. The nuclei of the fibroblastic meningioma are also different in that they are broader with a pale nucleoplasm and distinct small nucleoli; they are thinner and stain darker in schwannomas. In the transitional meningioma the whorls tend to surround a central capillary blood vessel (pl. XV–C), whereas this is not the case in the whorling pattern of a schwannoma; the distinction is usually easily made by performing a silver stain for reticulin.

In cases when a cerebellopontine angle tumor is not suspected, the stellate appearance of the cells and the presence of coarse cellular processes in the Antoni B type of

pattern may trap the unwary into a diagnosis of astrocytoma (fig. 224). This mistake is unlikely if information is available on the site of the tumor and the age of the patient; in cases of doubt a reticulin preparation makes the distinction obvious, but confusion on a frozen section may occasionally be a source of humiliation for the pathologist.

NEUROFIBROMAS

These are tumors that are derived from and composed of both Schwann cells and fibroblasts, and often include nerve fibers which may or may not be myelinated. The Schwann cell is regarded by electron microscopists as the "principal cell" in this tumor (Waggener; Pineda; Poirier et al.) and is frequently found to be wrapped around an axon. Collagen fibers are numerous.

As solitary neoplasms of the cranial and the spinal nerve roots, they are almost unknown in the absence of von Recklinghausen's neurofibromatosis. In the latter condition they may involve the cranial or the spinal nerve roots, or both. Frequently they grow as dumbbell-shaped tumors through the intervertebral foramina. **Grossly** they are much less well defined than schwannomas, and often form masses that merge insensibly with a thickened nerve root. **Microscopically** (fig. 226) they form a loose textured pattern of moderate cellularity consisting in a wavy arrangement of elongated tapering cells that form bundles separated by a matrix which is often positive for mucin. The typical arrangement of compact bundles of the Antoni A type is not found. The nuclei are darkly staining and elongated. The fibrous strands that course in an irregular fashion in a plane parallel to the nuclei give a positive reaction both for reticulin and for collagen.

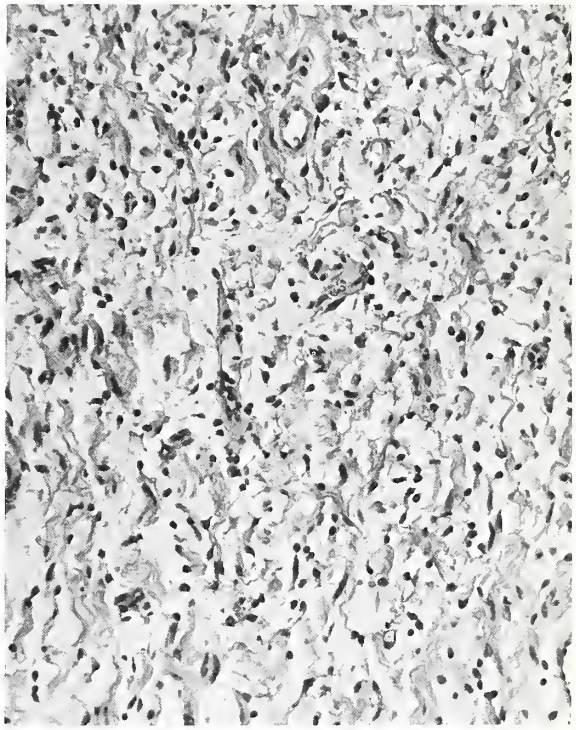

NEUROFIBROMA

Figure 226. This is the microscopic appearance of a typical neurofibroma arising in the cervical region in a case of von Recklinghausen's disease. × 185.

Nerve fibers, both myelinated and unmyelinated, are frequently found running in the substance of the neoplasm.

Unlike the schwannomas, and like the neurofibromas that arise in the peripheral or autonomic nervous system, those that originate in a nerve root may undergo malignant change with the development of a neurofibrosarcoma.

Further details on the histologic features and the biologic behavior of these tumors, as well as their association with von Recklinghausen's neurofibromatosis, are found in "Tumors of the Peripheral Nervous System" by Harkin and Reed. The manifestations of the central form of von Recklinghausen's disease are described in this

fascicle in the section on dysgenetic condition associated with tumors and tumor-like formations of the central nervous system on page 302.

References

Atkinson, W. J. Anterior inferior cerebellar artery; its variations, pontine distribution, and significance in surgery of cerebello-pontine angle tumours. J. Neurol. Neurosurg. Psychiat. 12:137–151, 1949.

Best, P. V. Erosion of the petrous temporal bone by neurilemmoma. J. Neurosurg. 28:445–451, 1968.

Cervós-Navarro, J., Matakas, F., and Lazaro, M. C. Das Bauprinzip der Neurinome. Ein Beitrag zur Histogenese der Nerventumoren. Virchow Arch. Path. Anat. 345:276–291, 1968.

Cravioto, H. The perineurium as a diffusion barrier—ultrastructural correlates. Bull. Los Angeles Neurol. Soc. 31:196–208, 1966.

———. The ultrastructure of acoustic nerve tumors. Acta Neuropath. 12:116–140, 1969.

———, and Lockwood, R. Long-spacing fibrous collagen in human acoustic nerve tumors. In vivo and in vitro observations. J. Ultrastruct. Res. 24:70–85, 1968.

Gardner, W. J., and Turner, O. Bilateral acoustic neurofibromas: further clinical and pathological data on hereditary deafness and Recklinghausen's dissease. Arch. Neurol. 44:76–99, 1940.

Harkin, J. C., and Reed, R. J. Tumors of the Peripheral Nervous System. Fascicle 3, 2d Series, Atlas of Tumor Pathology. Washington: Armed Forces Institute of Pathology, 1969.

Luse, S. A. Electron microscopic studies of brain tumors. Neurology 10:881–905, 1960.

Moyes, P. D. Familial bilateral acoustic neuroma affecting 14 members from four generations. Case report. J. Neurosurg. 29:78–82, 1968.

Murray, M. R., and Stout, A. P. Schwann cell versus fibroblast as origin of specific nerve sheath tumor; observations upon normal nerve sheaths and neurilemomas in vitro. Amer. J. Path. 16:41–60, 1940.

Olive, I., and Svien, H. J. Neurofibromas of the fifth cranial nerve. J. Neurosurg. 14:484–505, 1957.

Olivecrona, H. Acoustic tumors. J. Neurosurg. 26:6–13, 1967.

Pineda, A. Electron microscopy of the lemmocyte in peripheral nerve tumors (neurolemmomas). J. Neurosurg. 25:35–44, 1966.

Poirier, J., and Escourolle, R. Ultrastructure des neurinomes de l'acoustique. Z. Mikr. Anat. Forsch. 76:509–529, 1967.

———, Escourolle, R., and Castaigne, P. Les neurofibromes de la maladie de Recklinghausen. Etude ultrastructurale et place nosologique par rapport aux neurinomes. Acta Neuropath. 10:279–294, 1968.

Ramsey, H. J. Fibrous long-spacing collagen in tumors of the nervous system. J. Neuropath. Exp. Neurol. 24:40–48, 1965.

Riggs, H. E., and Clary, W. U. A case of intramedullary sheath cell tumor of the spinal cord. Consideration of vascular nerves as a source of origin. J. Neuropath. Exp. Neurol. 16:332–336, 1957.

Schisano, G., and Olivecrona, H. Neurinomas of the gasserian ganglion and trigeminal root. J. Neurosurg. 17:306–322, 1960.

Scott, M., and Bentz, R. Intramedullary neurilemmoma (neurinoma) of the thoracic cord. A case report. J. Neuropath. Exp. Neurol. 21:194–200, 1962.

Skinner, H. A. The origin of acoustic nerve tumours. Brit. J. Surg. 16:440–463, 1929.

Slooff, J. L., Kernohan, J. W., and MacCarty, C. S. Primary Intramedullary Tumors of the Spinal Cord and Filum Terminale. Philadelphia: W. B. Saunders Company, 1964.

Waggener, J. D. Ultrastructure of benign peripheral nerve sheath tumors. Cancer 19:699–709, 1966.

———, Bunn, S. M., and Beggs, J. The diffusion of ferritin within the peripheral nerve sheath; an electron microscopic study. J. Neuropath. Exp. Neurol. 24:430–443, 1965.

TUMORS OF THE LYMPHORETICULAR SYSTEM

In the following section the tumors of the lymphoreticular system are divided into two groups; those that involve solely or principally the central nervous system, and those that implicate the central nervous system and its coverings secondarily to visceral disease. Since the cells from which the tumors originate are present throughout the body and since these neoplastic proliferations often arise multicentrically, the distinction might admittedly be regarded as unsound. It is true that some overlapping occurs. Lymphomatous foci are present in the viscera in a proportion of cases of reticulum cell sarcoma-microglioma arising in the brain. On the other hand, local involvement of the central nervous system parenchyma and the leptomeninges is not infrequent in visceral lymphosarcoma, reticulum cell sarcoma, and even Hodgkin's disease. The distinction is also blurred by the experience of cases in which a lymphoma appears at first to be restricted to the central nervous system or its meninges, but after several years manifests itself in other parts of the body. This problem is of course well recognized in the evolution of lymphomas in general. But in practice a repeated topographic pattern of neoplastic proliferation is found which justifies the somewhat arbitrary division adopted here.

PRIMARY TUMORS OF THE LYMPHORETICULAR SYSTEM

RETICULUM CELL SARCOMA-MICROGLIOMA

SYNONYMS AND RELATED TERMS: Reticulum cell sarcoma; microgliomatosis; perivascular sarcoma; periadventitial sarcoma, adventitial sarcoma; perithelial sarcoma; reticuloendothelial sarcoma; sarcoma of the reticuloendothelial system; malignant lymphoma; malignant reticulosis; malignant reticuloendotheliosis; reticulohistocytic encephalitis; and atypical granulomatous encephalitis.

DEFINITION AND CYTOGENESIS. If we adhere to the useful, but admittedly artificial separation of the lymphoreticular system into a **lymphoid** and a **reticuloendothelial** system, then clearly only cells of the latter are found intrinsic to the central nervous system. These consist of the **microglia** and their presumed precursors, **the reticulum cells**, which are believed to be distributed in the perivascular and meningeal spaces. Proliferations from the lymphoid system would be expected to occur only in those sites in which this tissue is normally present, namely the spinal epidural space, or lymphoid cells may gain access to the central nervous system from remote foci, presumably through hematogenous dissemination.

Theoretically, therefore, the primary neoplastic proliferations of the reticuloendothelial system within the brain must be derived either from the microglia or from the primitive reticulum cells, or both. In 1948 Russell, Marshall, and Smith described such proliferations under the term **microgliomatosis;** similar neoplasms had been described before and since, and called mostly **reticulum cell sarcomas** or equivalent designations. Because of reluctance to accept the concept that microglia were capable of neoplastic transformation, their presence is often interpreted as simply reactive. Reticulum cells and microglial cells may be difficult to distinguish cytologically when routine histologic stains are employed. Their fundamental difference can only be appreciated with

the help of specific silver impregnations. According to the simple definition of Marshall, these methods divide the cells of the reticuloendothelial system into a mature, metalophilic (**argyrophilic**) type—to which the microglia belong—and an immature, nonmetalophilic (**nonargyrophilic**) type—from which the microglia have evolved.

On the basis of their observations with the Hortega and the Weil-Davenport silver carbonate methods for microglia, Russell and associates expressed the view that the more primitive cell elements in these tumors probably arose from dedifferentiation of the more mature forms. However, the alternative possibility clearly exists; namely, that these neoplasms originate from the more primitive elements, and that the mature microglial forms represent their differentiated descendants. The perivascular and meningeal cells would be suitable candidates in this regard, and illustrations which are perhaps suggestive of a perivascular derivation are found in the report by Peison and Voris, and in the monograph by Kernohan and Uihlein (see also fig. 230). Numerous descriptions and reviews have recently been published on these tumors, all discussing the problems of classification and nomenclature which they have generated (Kernohan and Uihlein; Burstein et al.; Miller and Ramsden; Ostertag; Adams and Jackson). There seems to be general agreement that the neoplasms consist of a mixture of both primitive reticulum cells and more differentiated microglia with various degrees of affinity for silver impregnation, depending on the maturity of the predominant cell element. This view is supported by the electron microscopic study of one case (Horvat et al.) in which the fine structure of the microglioma cell was found to resemble both that of cells in extracerebral reticulum cell sarcomas and that of the activated microglia that appear following experimental intracerebral trauma.

One further feature, to which little attention has so far been paid, is the occasional presence in these neoplasms of widespread secondary subpial structures, in the meaning of Scherer (p. 11). It cannot be argued that these have resulted from the migration of primitive reticulum cells from the leptomeninges since the latter are usually free of tumor. By analogy with the diffusely infiltrating gliomas, this favors an origin from parenchymatous cell elements, namely the microglia. This, combined with the characteristic perivascular distribution of the tumor cells in other fields suggesting a source outside the blood vessel walls, and the great variation in the frequency and number of argyrophilic cells, would support a concomitant origin from both microglia and their primitive cell precursors as the most reasonable hypothesis.

Accordingly the term **reticulum cell sarcoma-microglioma** would seem an acceptable compromise that satisfies the two alternative cytogenetic points of view. At the same time, it is not incompatible with the theoretical existence in the brain of fixed cells with unrestricted polyblastic mesenchymal potential (Feigin). The latter concept would account for the cytologic variations found in this group of neoplasms, and for the presence not only of microglial cells but also of lymphocytes, plasma cells, and fibroblasts, which may form an important component of the reticulum cell sarcoma-microglioma.

NATURAL HISTORY. VISCERAL INVOLVEMENT. ASSOCIATED CONDITIONS. In most cases, reticulum cell sarcoma-microglioma presents as a rapidly growing

space-occupying lesion. In some there is a long history of insidious or indolent proliferation of the lymphoreticular system elsewhere in the body, upon which an intracranial tumor clinically supervenes. For example these intracerebral proliferations have been seen in association with mycosis fungoides. In other instances there is clinical or radiologic evidence of visceral involvement of the lymphoreticular system. In an unknown proportion of cases lymphomatous proliferations are found at autopsy in extracranial sites; in many reported instances, however, this was not ascertained because postmortem examination was restricted to the head. In the series of Burstein and associates, in whom 22 of their 41 patients had complete autopsies, 2 had extracranial disease; of the 7 patients originally reported by Russell and associates, 3 had extracranial involvement.

Considerable interest has recently been generated in the coexistence of various forms of **dysglobulinemia** with lymphomas, including those involving primarily the central nervous system. An association has been described with Waldenström's macroglobulinemia (Edgar and Dutcher), with β-globulinemia (Horvat et al.), and with Wiskott-Aldrich syndrome, in which a cellular depletion in the follicles of the lymphoid system is accompanied by an abnormal profile in the immunoglobulins (Brand and Marinkovich). More diffuse involvement of the central and peripheral nervous systems by lymphoreticular infiltrations that fall short of the focal neoplastic picture of reticulum cell sarcoma-microglioma has also been reported with dysglobulinemias (Bing and Neel; Bichel et al.; Kakulas and Finlay-Jones). In this context, attention has recently been drawn to the incidence of neoplasms of the reticuloendothelial system as a complication following human renal transplantation. Some of these cases were restricted to the central nervous system (Schneck and Penn).

INCIDENCE. Reticulum cell sarcoma-microglioma is not uncommon. Kernohan and Uihlein found 40 cases among 8,070 intracranial tumors. Numerous cases submitted for reference suggest that it may even be more prevalent than these figures suggest. A recent review of 103 cases in the literature indicates a male preponderance of approximately 2 to 1. All ages may be affected, but maximal involvement occurs in the fifth and sixth decades with a large separate group apparently arising in the first decade (Samuelsson et al.).

SITES. MULTICENTRICITY. The cerebral hemispheres are most frequently involved with perhaps some predilection for the temporoparietal region. Other sites include the cerebellum and the brainstem. The spinal cord may be affected. Occasionally the tumor is almost entirely restricted to the leptomeninges with only minimal encroachment on the parenchyma. Multicentricity is frequent and affects either different hemispheres, or concurrently the cerebral hemispheres and the cerebellum or brainstem. Extracerebral involvement including the lymph nodes, bone marrow, spleen, lungs, or other organs is found in some cases. When present the tumor cells often show an affinity for silver carbonate impregnation in both the intracerebral and extracerebral sites. In one case reported by Adams and Jackson, only the intracerebral cells were strongly argyrophilic, which would be in support of a multifocal process.

GROSS. In many examples the macroscopic picture is that of a definite space-occupying mass with somewhat ill-defined outlines occupying the cerebral

white matter (fig. 227). In some cases it is fairly circumscribed; in others (fig. 227) the adjacent areas of the brain may be replaced by softer, darker brownish tissue that merges imperceptibly with the remainder of the parenchyma. In other examples the latter is more diffusely involved without the presence of a definite mass (fig. 228). The cut surfaces of the neoplastic area are homogeneous, dark or pale gray, and characteristically granular (fig. 228). Foci of softening are also present, often at the periphery of the main mass (figs. 227, 228). In addition, careful examination often reveals multiple foci of discoloration and granularity in other areas of the brain due to multicentric neoplastic transformation.

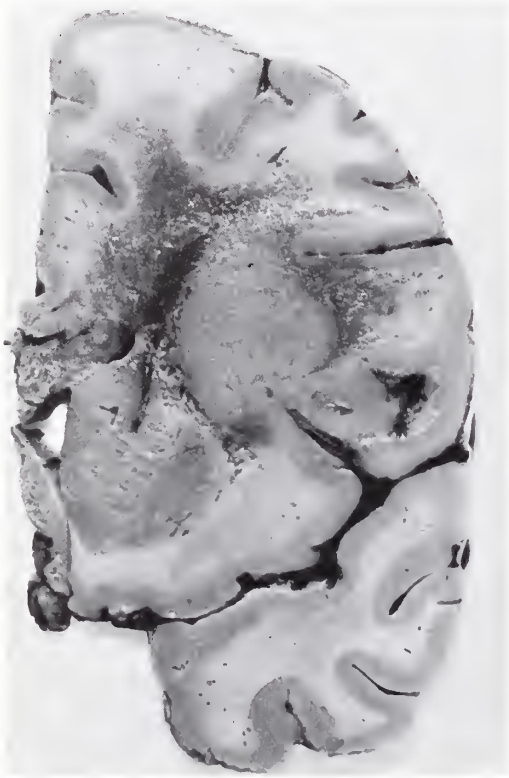

Fig. 227

MICROGLIOMATOSIS

(Figures 227, 232–234, and 237 from same case)

Figure 227. A homogeneous tumor mass is seen in the right frontal centrum ovale with a darker softer band of infiltration in the remainder of the white matter and in the corpus callosum. The dark hemorrhagic streak extending from the corona radiata into the basal ganglia is due to surgical exploratory needling. This tumor arose in a 57-year-old woman with a 3-week history of headaches, drowsiness, and progressive mental changes. (Fig. 1 from Rubinstein, L. J. Microgliomatosis. Acta Neurochir., Supp. X:201–212, 1964).

RETICULUM CELL SARCOMA-MICROGLIOMA

(Figures 228, 231, and 235 from same case)

Figure 228. There is diffuse infiltration of the corpus callosum by homogeneous granular ill-defined neoplastic tissue extending bilaterally into the corona radiata in a 44-year-old man. (Courtesy of Dr. J. E. Olvera-Rabiela, Mexico City, Mexico; also fig. 6 from Rubinstein, L. J. Seminario de Neuropatologia, Mérida, Yucatán, Bol. Asoc. Mex. Patol., A. C. 7:13–59, 1969).

In some cases the cut surface is more variegated, with foci of yellow necrosis and hemorrhage that may mimic the appearances of a glioblastoma. In others the picture may be that of a very ill-defined thickening and a suspicious looking infiltration of the periventricular white matter, often affecting selectively the walls of the third ventricle. Some forms of reticulum cell sarcoma-microglioma, which may possibly belong to one of the variants to be described, tend to involve especially the hypothalamic and infundibular regions. Finally there are cases in which the brain appears virtually normal grossly, but in which microscopic examination discloses the presence of a diffuse neoplastic proliferation of microglial and more primitive elements. The macroscopic picture is therefore extremely variable.

MICROSCOPIC. The microscopic appearances vary from case to case, as well as from field to field within the same case, yet the salient features are to some extent recapitulated in all instances, giving them a family resemblance that makes them immediately recognizable once the group is identified.

In the more central part of the neoplasm the picture is usually that of intense cellularity with a dense aggregate of tumor cells that not only replace the neural parenchyma but also fill the distended Virchow-Robin spaces. At the periphery the cellularity is generally much reduced, but tumor cells are found infiltrating the surrounding parenchyma for considerable distances further afield. Their arrangement at the periphery may be strikingly perivascular (fig. 229), with the formation of thick collars around the blood vessels that may mimic an encephalitis.

Under high power various cell elements are demonstrable, and those of the reticuloendothelial system are preponderant. In some areas the cells are fairly uniform, with ill-defined cytoplasmic outlines

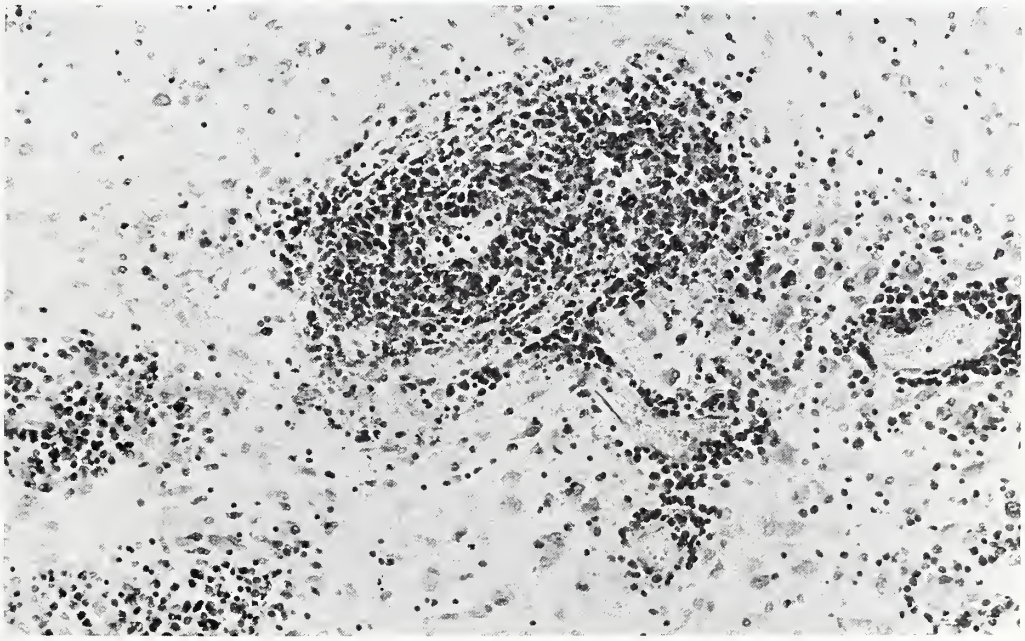

RETICULUM CELL SARCOMA

Figure 229. There is diffuse infiltration of the brain with tumor cells forming collars around the blood vessels. The general pattern mimics that of encephalitis. The case is that of a 3-year-old child with primary malignant reticulosis of the brain associated with Wiskott-Aldrich syndrome. Nissl stain. × 180.

and prominent nuclei which have distinct nuclear membranes, a pale nucleoplasm, and frequently conspicuous nucleoli. An arrangement around or an attachment to the blood vessels is occasionally seen (fig. 230). In other areas the cellular characteristics are considerably more pleomorphic. Again, cells of the reticuloendothelial system of various sizes and shapes are found admixed with more mature elements that have elongated or notched darkly staining nuclei; the appearance is that of microglia. Other cell elements such as lymphocytes and plasma cells are frequent (fig. 231). The lymphocytes tend to be particularly numerous around the blood vessels and may form an inner collar that appears quite distinct from the more diffuse infiltrations by primitive reticulum cells and microglia further afield in the neural parenchyma. Mitotic figures may be frequent. Some tumor cells are obviously phagocytic and contain two or more engulfed nuclei from other cell elements (fig. 231, right lower corner). Rarely (twice in the material I have examined) plasma cells and their precursors may be unusually numerous, producing in places the picture of a plasmacytoma (Miller and Ramsden, Case 3). Small multinucleated giant cells are occasionally present, some of which are said to resemble Sternberg-Reed cells; presumably these are the cases classified by Kernohan and Uihlein as the Hodgkin's subtype in their group of sarcomas of the reticuloendothelial system.

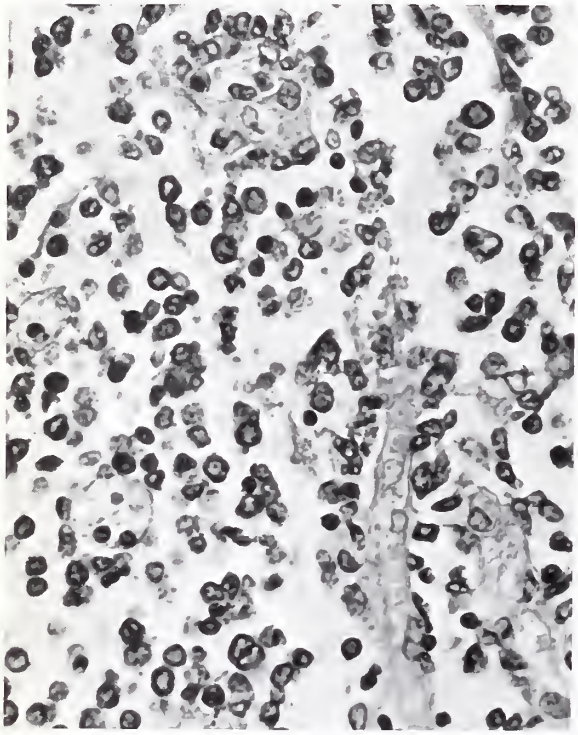

RETICULUM CELL SARCOMA-MICROGLIOMA

Figure 230. There is a suggestion of perivascular arrangement of the tumor cells. With the usual staining methods these cells have a very ill-defined cytoplasm and pleomorphic nuclei with distinct nuclear membranes, a pale nucleoplasm, and occasional prominent nucleoli. × 440. (Fig. 16 from Rubinstein, L. J. Seminario de Neuropatologia, Mérida, Yucatán, Bol. Asoc. Mex. Patol., A. C. 7:13–59, 1969).

In some examples necrosis is a prominent microscopic as well as macroscopic feature. Reticulin preparations characteristically reveal an increase of perivascular connective tissue fibers, which is almost diagnostic of the neoplasm (fig. 232). The pattern illustrated results from the concentric increase in the perivascular reticulin, with the production of a lacy pattern of broken fibers that are most abundant near the outer wall of the perforating blood vessel and gradually diminish in amount as they approach the well defined pial membrane; the Virchow-Robin space is distended due to infiltration by tumor. In some cases there is an unusually abundant and dense fibrous connective tissue network consisting of collagen as well as reticulin, and often separating the tumor into islands of various sizes (Rubinstein, Case 2; Miller and Ramsden). This connective tissue proliferation could be the result of an unusual response

RETICULUM CELL SARCOMA-MICROGLIOMA

(Figures 228, 231, and 235 from same case)

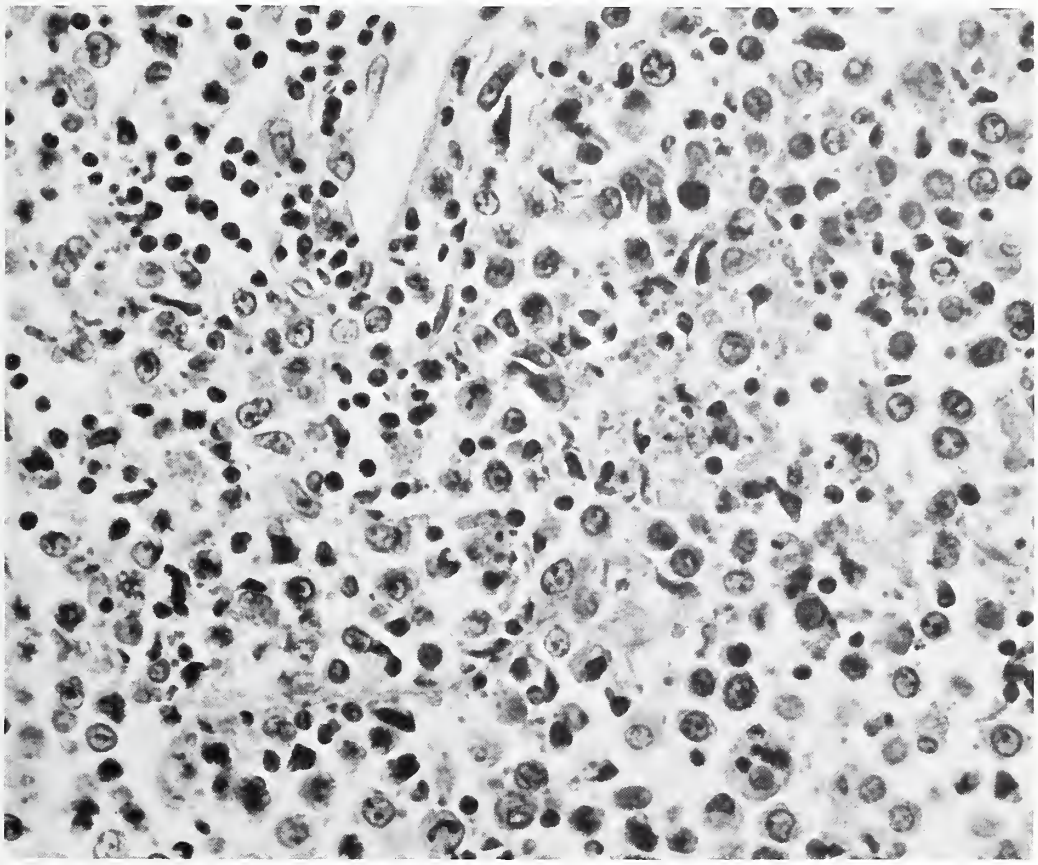

Figure 231. Pleomorphic malignant cells of the reticuloendothelial system are mixed with smaller cell elements, mostly lymphocytic. The latter are especially numerous around the thin-walled blood vessel in the upper portion of the photomicrograph. Note also the large phagocytic cell in lower right. × 600. (Fig. 7 from Rubinstein, L. J. Seminario de Neuropatologia, Mérida, Yucatán, Bol. Asoc. Mex. Patol., A. C. 7:13–59, 1969).

RETICULUM CELL SARCOMA-MICROGLIOMA

Figure 232. This characteristic pattern of increased perivascular reticulin fibers is found in the greatly dilated Virchow-Robin space. Gomori's silver method for reticulin. × 115. (Fig. 5 from Rubinstein, L. J. Microgliomatosis. Acta Neurochir., Supp. X:201–212, 1964).

of the brain to this particular form of neoplasm, or arise from a metaplastic change in the primitive reticulum cells with the formation of fibroblasts.

A characteristic feature is the frequency with which the cell elements show a positive affinity for silver carbonate methods specific for microglia (figs. 233, 234). This varies, however, from case to case and also from area to area. Some examples are undoubtedly refractory to silver impregnation and are therefore classified as reticulum cell sarcomas. But in many there is extensive argyrophilia, and it is reasonable to regard them as microgliomas (figs. 233, 234). It is difficult, if not impossible, to state what percentage of cells are argyrophilic; clearly there is a good deal of variation within the group as a whole. While it is to be anticipated that the examples which in routine preparations consist mostly of cells with the appearance of microglia will be the most apt to show argyrophilia in frozen preparations, the converse is not necessarily true. Intense argyrophilia may be demonstrated in many of the tumor cells in cases which by hematoxylin and eosin consist mostly of elements that, at first glance, one would be tempted to classify as reticulum cell sarcoma.

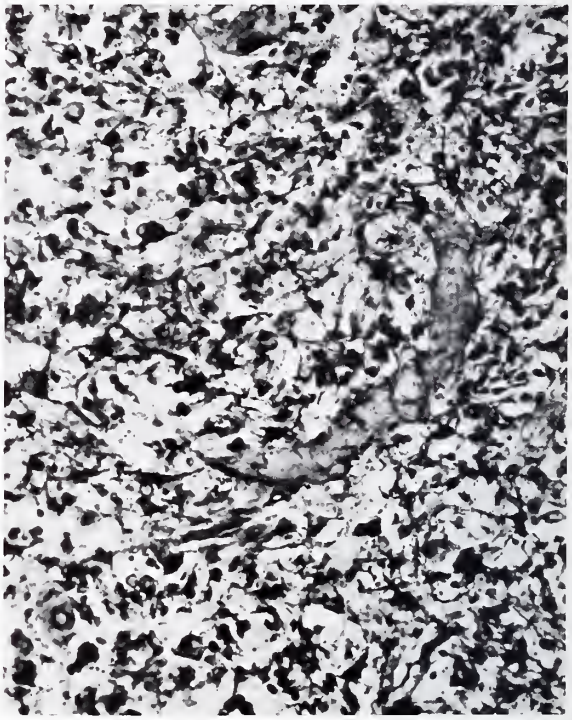

MICROGLIOMATOSIS

(Figures 227, 232–234, and 237 from same case)

Figure 233. Positive silver impregnation of the cytoplasm is seen in many tumor cells. Penfield's modification of Hortega's silver carbonate method for microglia. × 200. (Fig. 6 from Rubinstein, L. J. Microgliomatosis. Acta Neurochir., Supp. X:201–212, 1964).

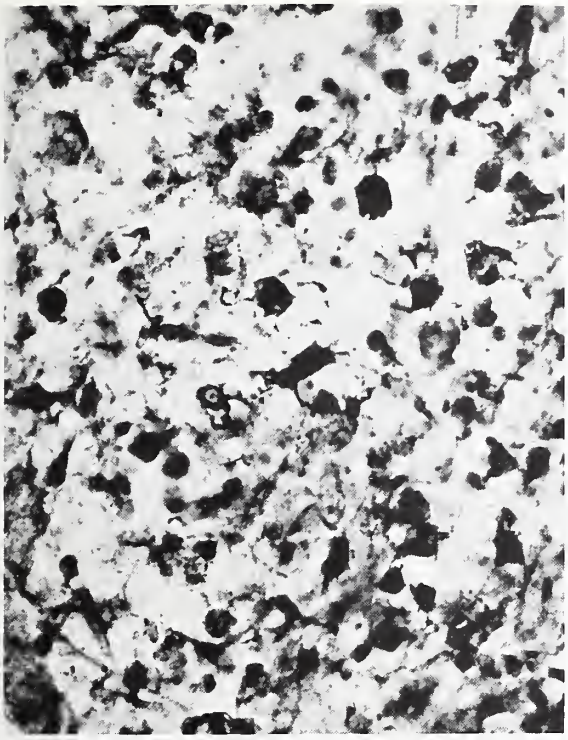

MICROGLIOMATOSIS

(Figures 227, 232–234, and 237 from same case)

Figure 234. A high power view shows the morphologic detail of silver impregnated cells that are microglial in character. Penfield's modification of Hortega's silver carbonate method for microglia. × 400. (Fig. 7 from Rubinstein, L. J. Microgliomatosis. Acta Neurochir., Supp. X:201–212, 1964).

GROWTH AND SPREAD. Aside from its tendency to multifocality already referred to, the tumor frequently infiltrates the leptomeninges (fig. 235). More extensive spread throughout the cerebrospinal subarachnoid space is sometimes found. Even in the meningeal infiltrate, a positive impregnation of some of the tumor cells is often demonstrated (fig. 236). Indeed some cases of microgliomatosis seem to infiltrate the meningeal and perivascular spaces almost exclusively. Another conspicuous feature is the marked hypertrophy of the reactive astrocytes that may be present both in the peripheral parts of the tumor and in its more central portions (fig. 237).

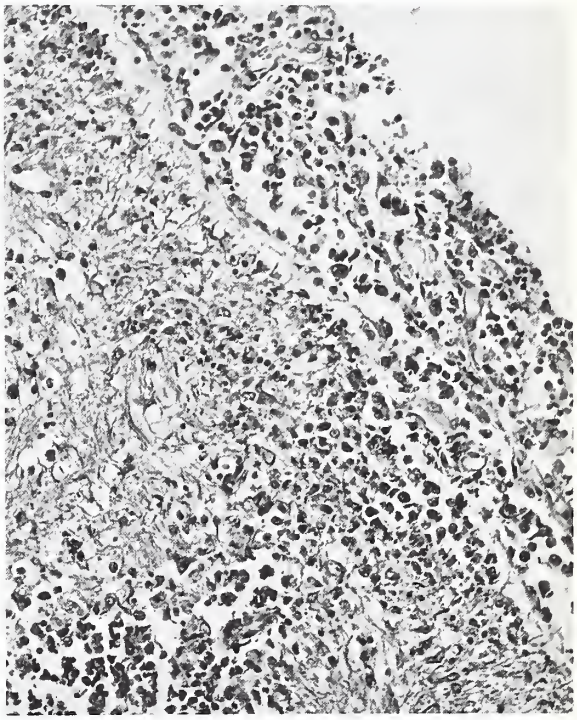

MICROGLIOMATOSIS
LEPTOMENINGEAL INVASION

(Figures 228, 231, and 235 from same case)

Figure 235. Note the leptomeningeal invasion by microglioma (upper right). × 160.

TREATMENT. Relatively little is known about treatment since most cases have been diagnosed at autopsy. However, in a few instances reticulum cell sarcoma-microglioma has been identified following biopsy procedures and has been treated with radiation. From personal experience of a few individual cases, the writer has the impression, independently confirmed by others (Fisher et al.), that the tumor, like other proliferations of the lymphoreticular system, may be radiosensitive. Although the evidence is not yet well documented it is sufficiently suggestive to make radiation advisable.

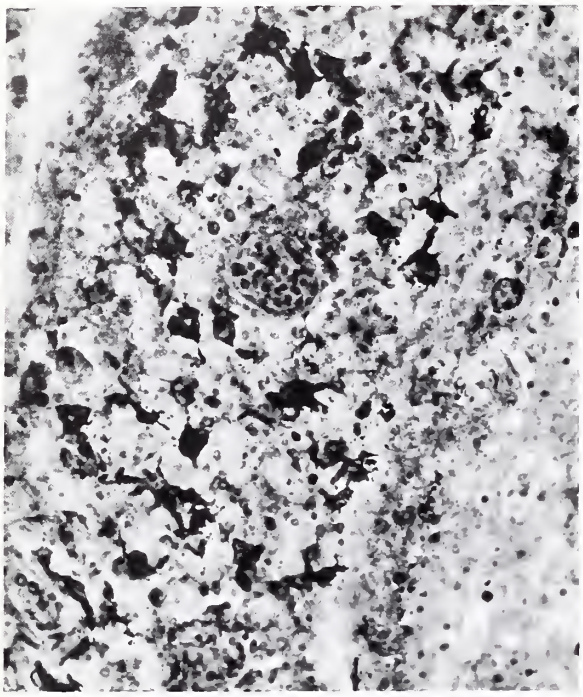

Fig. 236

MICROGLIOMATOSIS LEPTOMENINGEAL INVASION

Figure 236. Positive silver impregnation of the cytoplasm is shown in a number of tumor cells infiltrating the cerebellar subarachnoid space in another case of microgliomatosis. Penfield's modification of Hortega's silver carbonate method for microglia. × 265.

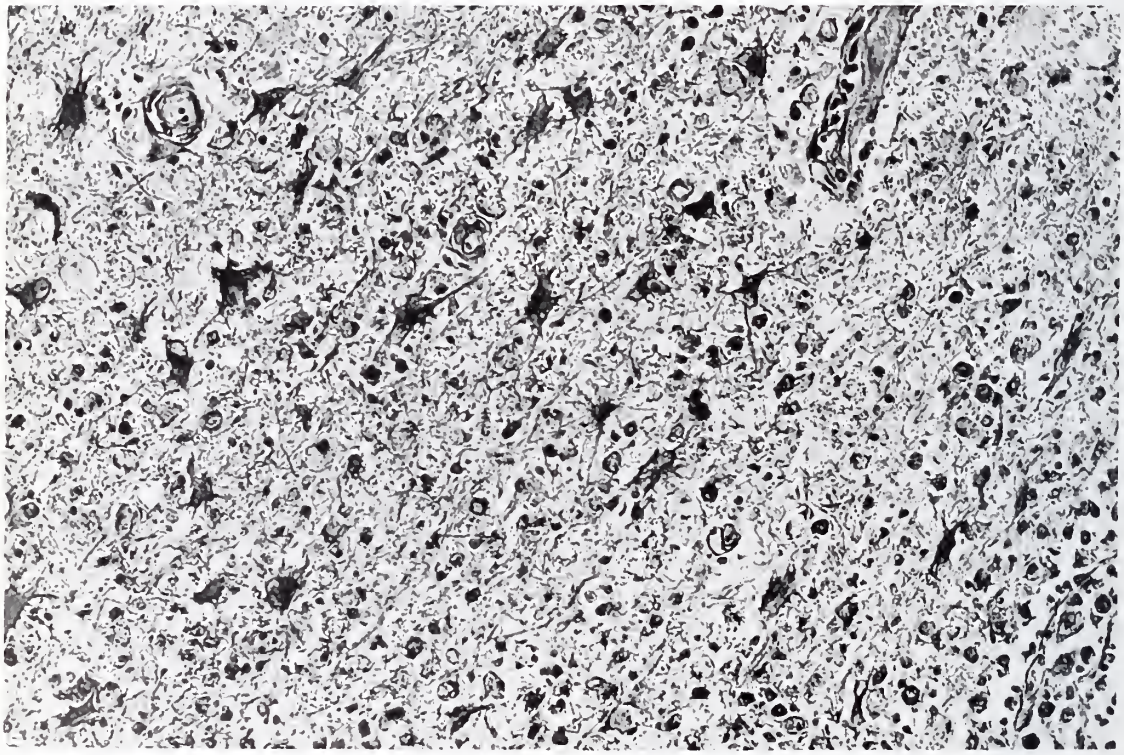

MICROGLIOMATOSIS-MICROGLIOMA. ASTROCYTIC REACTION

(Figures 227, 232–234, and 237 from same case)

Figure 237. There is marked hypertrophy of the reactive astrocytes adjacent to an infiltrating microglioma (lower right). PTAH. × 270.

PROGNOSIS. This again is not known, although a few patients are alive and well with no evidence of recurrence several years after operation or biopsy followed by radiotherapy (Kernohan and Uihlein). Most cases, however, pursue a fulminating course with a survival of approximately three to five months after the appearance of the first symptoms.

DIFFERENTIAL DIAGNOSIS. Usually the microscopic picture is distinctive. From the cytologic point of view, however, a distinction between a very uniform reticulum cell sarcoma and a polymorphic cell sarcoma may be difficult (fig. 209) and sometimes impossible. Curiously, confusion may occasionally arise between an oligodendroglioma and a reticulum cell sarcoma, but this is unlikely if enough material is available for sampling. A more frequent source of confusion lies in the occasional resemblance of the cellular picture of the reticulum cell sarcoma-microglioma with that of the pineal or suprasellar germinoma. In the latter, however, no transitions are seen between the small lymphocyte-like cells and the large germinoma cells (fig. 274). Silver carbonate preparations for microglia may be necessary to establish the diagnosis, but their presence does not necessarily exclude a germinoma in view of the granulomatous reaction which may accompany the latter (p. 274). There is a great difference in the peak age incidence between the germinoma and the reticulum cell sarcoma-microglioma.

"Hodgkin's Disease"

Whether Hodgkin's disease as such ever occurs as a primary neoplastic proliferation restricted to the central nervous system is highly debatable. Kernohan and Uihlein have included 8 cases which they designate as the sarcomatous form of Hodgkin's disease among their 40 examples of sarcomas of the reticuloendothelial system. It is true that occasionally small multinucleated giant cells perhaps distantly akin to Sternberg-Reed cells may be found in microgliomatosis, but whether this justifies a separate entity of Hodgkin's disease primarily involving the central nervous system is dubious. Cases reported in the literature as primary intracerebral Hodgkin's granuloma have usually not been verified at autopsy. Involvement of the central nervous system, especially its coverings, may occur as part of the picture of generalized Hodgkin's disease (p. 232).

Hypothalamic Granuloma or Cerebral Form of Histiocytosis X

Examples have been described in which localized masses consisting of granulomatous tissue resembling histiocytosis X occupied, and were limited to, the infundibular region (Den Hartog et al.: Bernard and Aguilar; Kepes and Kepes). These cases usually have a history of hypothalamic disorder, such as obesity, hypogonadism, and especially diabetes insipidus, often of considerable duration. Microscopically a granulomatous reaction is seen composed of masses of large pale cells with a foamy cytoplasm that resemble the histiocytes of Hand-Schüller-Christian disease and frequently phagocytose plasma cells (fig. 238). It is accompanied by a pronounced reactive hyperplasia of astrocytes and fibrillary gliosis, which is intimately admixed with a thick network of reticulin fibers (fig. 239). Sometimes considerable diagnostic difficulty arises in deciding whether the lesion represents primarily an astrocytoma with a marked inflammatory reaction, or a primary reticulohistiocytic proliferative disease. The separation of this condition, which is also

referred to as Ayala's disease or Gagel's granuloma (Kepes and Kepes), from a slowly evolving neoplastic reticulosis is not easy, especially since microgliomatosis is sometimes localized to the same area. Moreover it appears that forms occur which bridge this condition with the neoplastic proliferations of the reticuloendothelial system in the brain on the one hand and disseminated visceral histiocytosis X (Hand-Schüller-Christian and Letterer-Siwe's disease) on the other. Castaigne and associates have described an example of circumscribed hypothalamic granuloma with an 8-year history of diabetes insipidus associated with the more recent development of a separate focus of similar proliferative reticulosis in the middle cerebellar peduncle. In one of

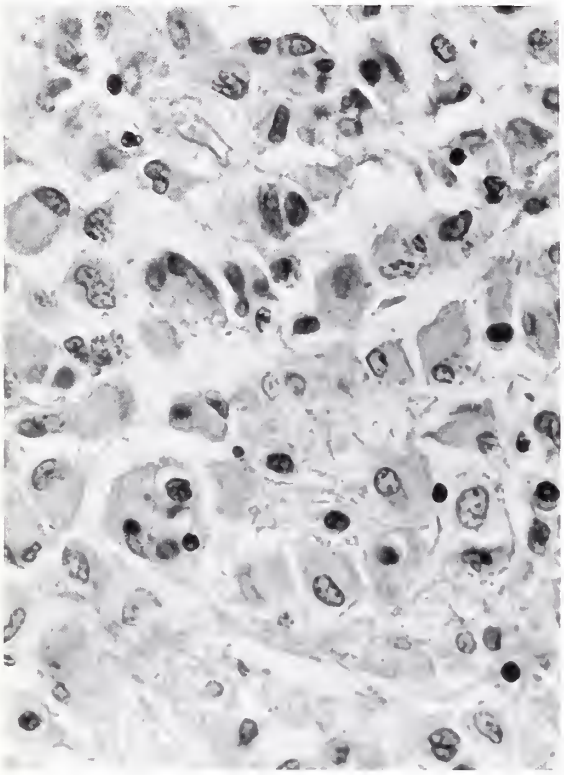

CEREBRAL HISTIOCYTOSIS X

(Figures 238 and 239 from same case)

Figure 238. Large histiocytes with eccentric nuclei and eosinophilic, occasionally foamy cytoplasm are shown, in places ingesting plasma cells. This section is from a 63-year-old woman with a firm, ill-defined, gray mass occupying the hypothalamic region. No other lesions were found in the skeletal or reticuloendothelial system. × 545. (Case 1 from Kepes, J. J., and Kepes, M. Predominantly cerebral forms of histiocytosis X. A reappraisal of "Gagel's hypothalamic granuloma," "granuloma infiltrans of the hypothalamus" and "Ayala's disease" with a report of 4 cases. Acta Neuropath. 14:77–97, 1969).

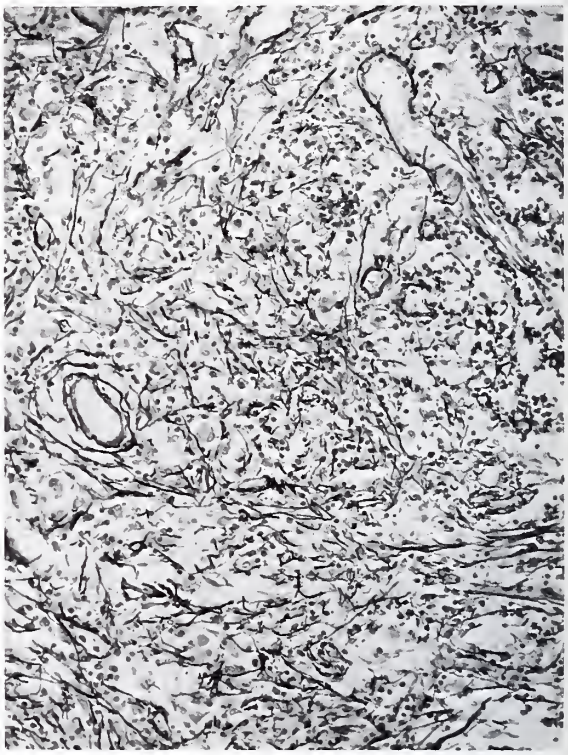

CEREBRAL HISTIOCYTOSIS X

(Figures 238 and 239 from same case)

Figure 239. A reticulin preparation from another area of the same lesion shows a dense network of connective tissue fibers. Wilder's reticulin stain. × 135. (Case 1 from Kepes, J. J., and Kepes, M. Predominantly cerebral forms of histiocytosis X. A reappraisal of "Gagel's hypothalamic granuloma," "granuloma infiltrans of the hypothalamus" and "Ayala's disease" with a report of 4 cases. Acta Neuropath. 14:77–97, 1969).

the cases reported by Kepes and Kepes, with masses in the basal ganglia, hypothalamus, brainstem, and cerebellum, there was also multiple bone involvement by Hand-Schüller-Christian disease, but the clinical history strongly suggests that the presenting lesion for a long time was confined to the hypothalamus. Finally there are cases of Letterer-Siwe's disease in which diffuse involvement of the brain of a meningoencephalitic character has been described (Batson et al.; Rubé et al.). The nosologic place of this enigmatic entity, like that of histiocytosis X in general, remains to be determined.

PRIMARY MENINGEAL LYMPHOSARCOMA

The validity may be questioned of separating a primary lymphosarcoma arising in the meninges from those that not uncommonly involve the central nervous system as a part of the generalized picture of lymphosarcoma. The distinction seems justified by the occasional reports in which lymphosarcomas have apparently remained localized to the coverings of the central nervous system for many years. It would also appear that they may carry an unusually favorable prognosis when treated by radiation.

Examples in which lymphosarcoma has remained restricted for a considerable time to the spinal epidural space have been documented by Bucy and Jerva. These tumors usually affect individuals over the age of 40 and tend to involve the thoracic portion of the spinal canal. Complete recovery for many years has been reported after surgical decompression, extensive removal, and radiation therapy. In one of the cases described by Bucy and Jerva, involvement of the cervical lymph node occurred 10 years after the initial removal of the spinal tumor.

It is apparent that lymphosarcoma may first present as an intracranial mass, extradural, subdural, or even subarachnoid (Jernstrom et al.; Lehrer and McGarry), but no documentation is available on whether such lesions remain solitary. However, in a case I recently examined in a 66-year-old man with a 30-year history of recurrent peripheral neuropathy, there was at autopsy a diffuse infiltration of the leptomeninges, the perivascular spaces, and the cranial and spinal nerve roots by lymphosarcoma which was unassociated with any lymphomatous proliferation in the rest of the body (Borit and Altrocchi).

PLASMACYTOMA

In contrast to the involvement of the meninges secondary to multiple myeloma, occasional examples of plasmacytoma are encountered which seem to arise primarily within the central nervous system. Such solitary plasmacytomas may either be attached to the frontal dura and falx (Moossy and Wilson) or confined to the hypothalamus (French). The case of Moossy and Wilson showed no development of plasmacytoma elsewhere five years after removal of the original intracranial neoplasm. In this instance there was no obvious involvement of the adjacent calvarium.

SECONDARY LYMPHOMATOUS PROLIFERTIONS

Secondary involvement of the central nervous system or its coverings as part of a widely disseminated lymphoma is common. In the majority of cases the meninges are involved, and most often those in the spinal canal. Here the epidural space is the most frequently affected. Another somewhat less frequent but still characteristic

site is the dura of the base of the brain with encroachment onto the adjacent neurohypophysis. Not infrequently microscopic examination discloses a diffuse infiltration of the subarachnoid spaces and of the cranial and spinal nerve roots. In these cases the clinical picture sometimes points to meningeal involvement, with pleocytosis and increase of protein in the cerebrospinal fluid. Infiltration of the parenchyma is much less common, but has been seen increasingly more often in recent years as the result of a more systematic examination of the central nervous system.

LYMPHOSARCOMA AND RETICULUM CELL SARCOMA

In both lymphosarcoma and reticulum cell sarcoma infiltration of the dura, especially the epidural space, is frequent and causes local compression of the spinal cord. Infiltration of the basal dura may sometimes extend locally into the brain substance, usually in the region of the tuber cinereum, but occasionally in the temporal lobe (fig. 240).

The frequency with which microscopic involvement of the cranial and spinal leptomeninges, their nerve roots, and even the adjacent parenchyma may be demonstrated in cases of generalized lymphosarcoma and reticulum cell sarcoma, and the relative lack of documentation of this observation in the literature suggest that little attention has been paid to this important phenomenon. In recent years I have seen subarachnoid infiltration by lymphosarcoma in 8 cases, with involvement of the nerve roots in 4. The example illustrated in figure 241 demonstrates the obvious gross thickening of the spinal nerve roots resulting from this infiltration (fig. 242). In 4 cases, the parenchyma of the brain or cord was infiltrated, mostly along the perivascular spaces (fig. 243) but also more diffusely (fig. 244). A further instance of central nervous system involvement by lymphosarcoma which originally began as a giant follicular cell lym-

SECONDARY INFILTRATION BY LYMPHOSARCOMA

Figure 240. This picture illustrates focal infiltration of the inferior surface of the left temporal lobe by secondary lymphosarcoma of the dura.

phoma is reported by Russell and Rubinstein. I have also noted infiltration of the subarachnoid spaces in 10 cases of generalized reticulum cell sarcoma, with involvement of the cranial or spinal nerve roots in 6, and of the parenchyma of the brain and cord in 5. In one further instance there was microscopic infiltration of the optic chiasm, tuber cinereum, and corpus callosum only.

INFILTRATION OF SPINAL NERVE ROOTS BY MALIGNANT LYMPHOMA

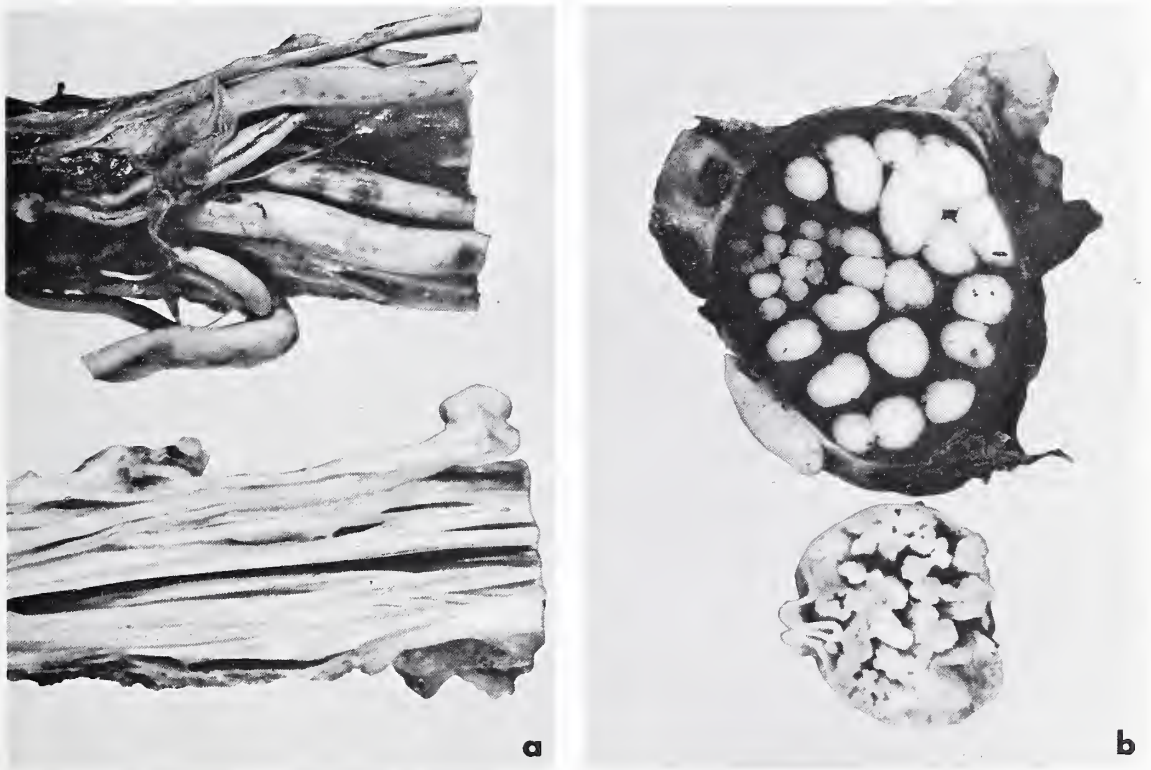

(Figures 241–243 from same case)

Figure 241. This shows diffuse thickening of the roots of the cauda equina in a 55-year-old woman with widespread visceral lymphoma (histiocytic lymphoma dedifferentiating to undifferentiated lymphoma). This patient presented with a right submandibular mass approximately three years before death. Two and one-half years later she developed paresthesiae and weakness of both arms, and examination of the cerebrospinal fluid was repeatedly positive for malignant cells. Postmortem examination showed extensive visceral lymphoma, mostly undifferentiated, and grossly thickened dorsal and ventral nerve roots below T-1 with extensive microscopic infiltration of the nerve roots, spinal subarachnoid space, and spinal cord by tumor. (a) longitudinal aspect; (b) transverse section of cauda equina. The cauda equina of a normal adult is shown beneath each specimen.

SECONDARY INFILTRATION OF NERVOUS SYSTEM BY MALIGNANT LYMPHOMA

(Figures 241–243 from same case)

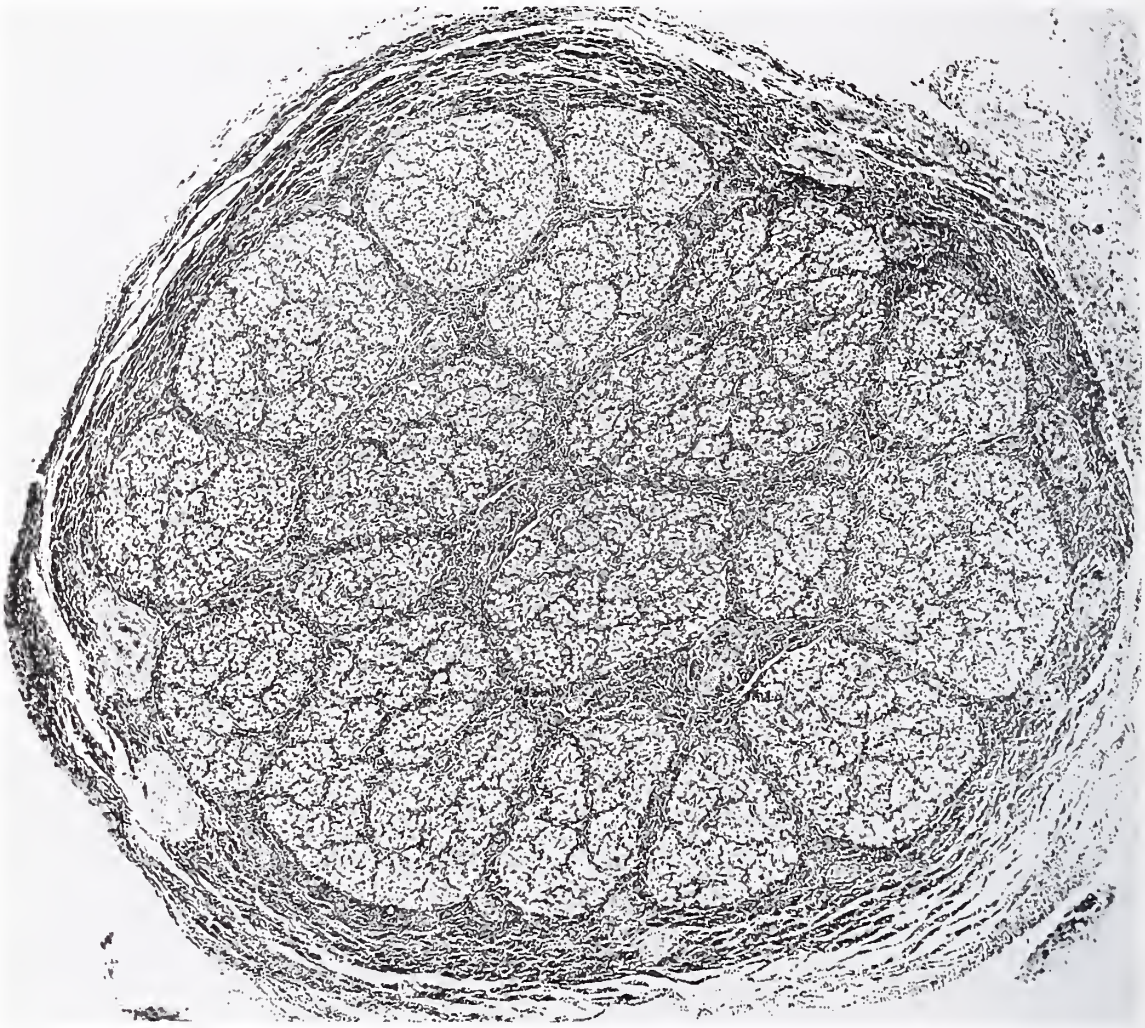

Figure 242. This shows extensive infiltration of a nerve root of the cauda equina. Tumor is present within the nerve bundles, but it is accentuated beneath the epineurium and in the connective tissue septa that separate the individual nerve bundles. × 56.

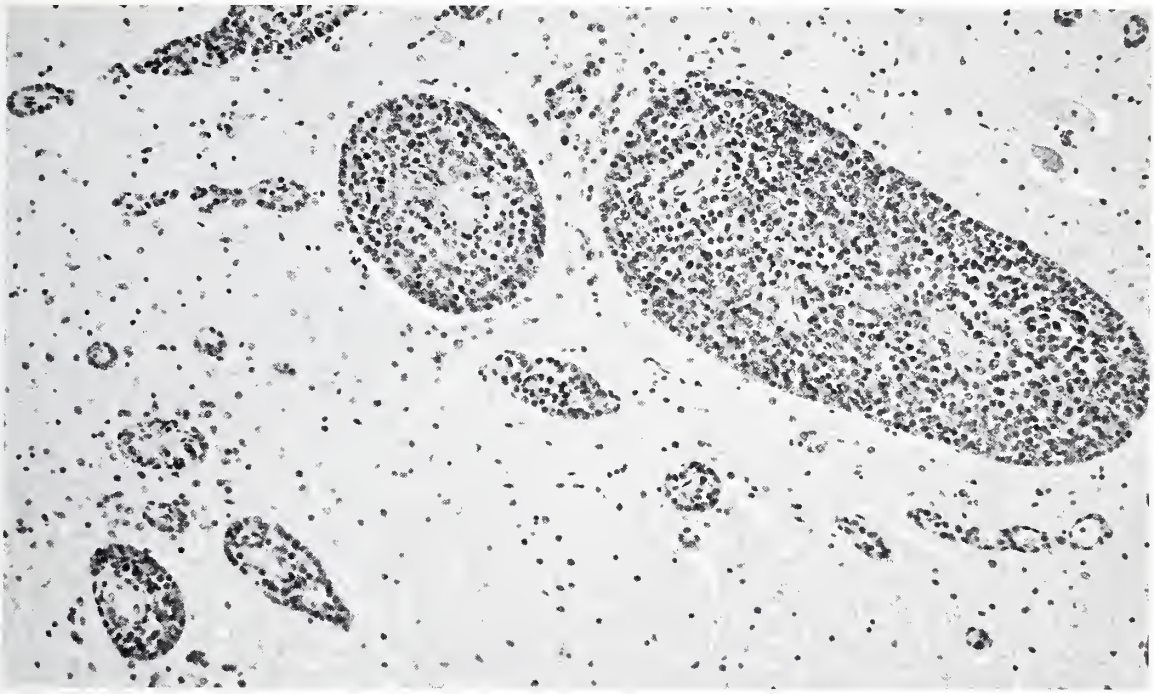

INTRAMEDULLARY INFILTRATION IN MALIGNANT LYMPHOMA

(Figures 241–243 from same case)

Figure 243. Infiltration is seen in the spinal cord, maximal in the perivascular spaces. × 180.

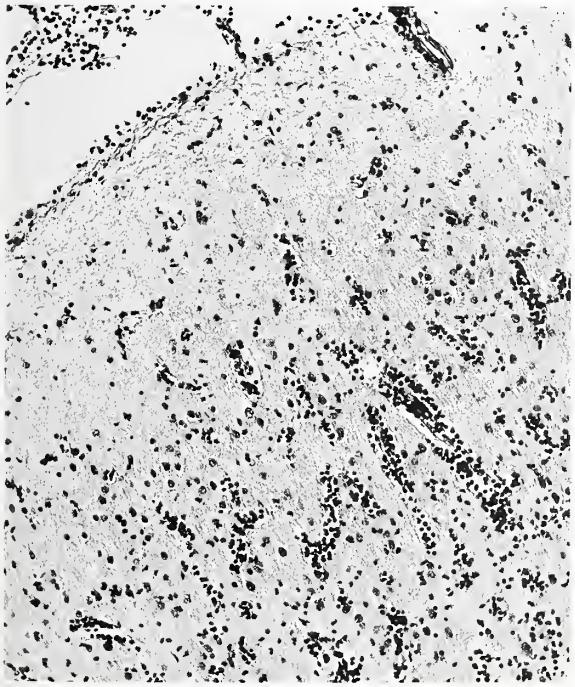

Fig. 244

INTRACEREBRAL INFILTRATION IN GENERALIZED LYMPHOSARCOMA

Figure 244. This reveals meningeal (upper left), perivascular, and diffuse parenchymatous infiltration of the motor cortex by lymphosarcoma. × 115.

HODGKIN'S DISEASE

Secondary involvement of the nervous system in Hodgkin's disease is well known and is frequently found in the dura, especially in the spinal canal. However, as in lymphosarcoma and reticulum cell sarcoma, infiltration of the leptomeninges and the spinal nerve roots is probably more common than is usually believed. I have seen extensive subarachnoid infiltration by Hodgkin's granuloma in two instances; in one of these the leptomeninges were grossly opaque and milky and there was severe gross enlargement of the spinal nerve roots due to infiltration with fibrosis. But in contrast to lymphosarcoma and reticulum cell sarcoma, parenchymatous involvement of the central nervous system by Hodgkin's disease is quite rare (Marshall et al.). Most reports stress that only the sarcomatous form may invade the brain, but the cases reported by Marshall and his associates were stated to have both Hodgkin's granuloma and sarcoma, and occasionally Hodgkin's granuloma may focally invade the brain from the adjacent bone and meninges (fig. 245).

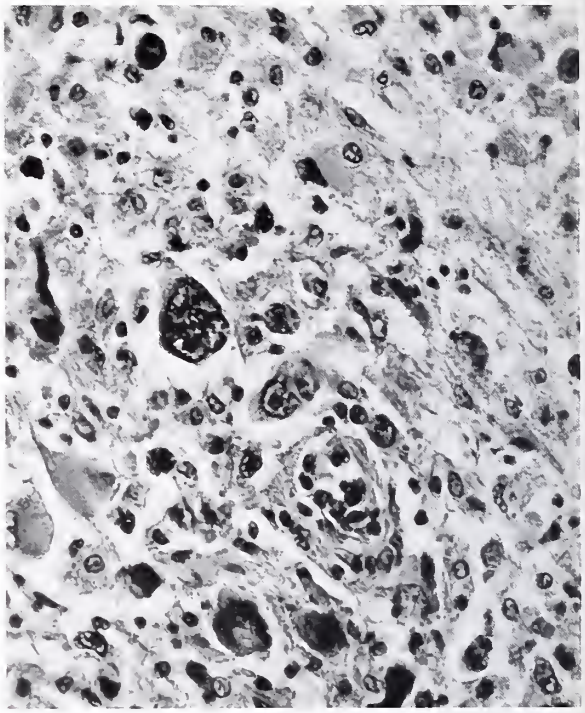

INTRACEREBRAL INFILTRATION IN HODGKIN'S DISEASE

Figure 245. Focal infiltration of the temporal cortex by tumor is seen in a classic example of Hodgkin's disease. Sternberg-Reed cells are present. Although epidural, subarachnoid, and nerve root infiltration by Hodgkin's disease is not uncommon, actual invasion of central nervous system parenchyma is very seldom found. × 350.

PLASMACYTOMA

Secondary involvement may affect the spinal cord and the brain, and is seen in both solitary and multiple myelomas. About 6 percent of cases with multiple myelomatosis develop symptoms of cord compression (Clarke). The midthoracic region is the most common site. Occasionally the tumor seems to have arisen primarily in the epidural space.

Multiple myelomas may also present as circumscribed extradural intracranial tumors without gross invasion of the meninges. Occasionally the subjacent dura is infiltrated, but usually the brain is not. Rarely in multiple myelomatosis, when the base of the skull as well as the vault is affected, tumor may extend diffusely along the cranial nerves into the cavernous sinuses and into the gasserian ganglia.

LEUKEMIAS

The clinical picture of meningeal irritation is a frequent presentation in acute leukemia, estimated by Shaw and his associates to occur in over 15 percent of cases. The spinal fluid shows increased pressure, with pleocytosis and occasionally raised protein content and decreased sugar con-

centration. Leukemic infiltration of the dura was noted by Moore and his associates in 70 percent of patients with acute lymphocytic leukemia and 59 percent of patients with acute myelocytic leukemia. Infiltration of the arachnoid was found in 30 percent of their cases, and more frequently in the lymphocytic than in the myelocytic form; it was also more common in children than adults. The infiltration also extends along the perivascular spaces into the brain or spinal cord parenchyma. In some cases leptomeningeal invasion leads to the production of internal hydrocephalus.

Diffuse intracerebral involvement was found in only 5 cases by Moore and his associates, but I have seen it in 8 of 24 consecutive examples of acute leukemia with central nervous system lesions. In this series infiltration of the subarachnoid spaces was found in 14 cases and of the cranial or spinal nerve roots in 7.

The most frequent terminal lesion in acute leukemia is intracranial hemorrhage, either intracerebral or subarachnoid, which is responsible for death in 20 percent of these cases (Moore et al.). Terminal hemorrhagic intracranial lesions, often multiple, were found in 11 of 24 cases with central nervous system involvement in the personally examined series already mentioned. These fatal intracerebral hemorrhages are associated with intracerebral leukostasis and the development of leukemic nodules that are directly related to the height of the preterminal leukocyte count; the critical level appears to be 300,000 leukocytes per cubic millimeter (Freireich et al.). The hemorrhage primarily involves the white matter of the brain and appears to be the result of destruction of the vessel wall. By contrast fatal subarachnoid hemorrhages are apparently not associated with these "blastic crises" and seem to be related to severe thrombocytopenia (Moore et al.).

References

Adams, J. H., and Jackson, J. M. Intracerebral tumours of reticular tissue: the problem of microgliomatosis and reticulo-endothelial sarcomas of the brain. J. Path. Bact. 91:369–381, 1966.

Batson, R., Shapiro, J., Christie, A., and Riley, H. D. Acute nonlipid disseminated reticuloendotheliosis. Amer. J. Dis. Child. 90:323–343, 1955.

Bernard, J. D., and Aguilar, M. J. Localized hypothalamic histiocytosis X. Report of a case. Arch. Neurol. 20:368–372, 1969.

Bichel, J., Bing, J., and Harboe, N. Another case of hyperglobulinemia and affection of the central nervous system. Acta Med. Scand. 138:1–14, 1950.

Bing, J., and Neel, A. V. Two cases of hyperglobulinaemia with affection of the central nervous system on a toxi-infectious basis (myelitis, polyradieulitis, spinal-fluid changes). Acta. Med. Scand. 88:492–506, 1936.

Borit, A., and Altrocchi, P. Recurrent polyneuropathy and neurolymphomatosis. Arch. Neurol. 24:40–49, 1971.

Brand, M. M., and Marinkovich, V. A. Primary malignant reticulosis of the brain in Wiskott-Aldrich syndrome. Arch. Dis. Child. 44:536–542, 1969.

Bucy, P. C., and Jerva, M. J. Primary epidural spinal lymphosarcoma. J. Neurosurg. 19:142–152, 1962.

Burstein, S. D., Kernohan, J. W., and Uihlein, A. Neoplasms of the reticuloendothelial system of the brain. Cancer 16:289–305, 1963.

Castaigne, P., Cambier, J., Escourolle, R., and Masson, M. Réticulose cérébrale circonscrite à double localisation hypothalamique et protubérantielle. Presse Méd. 76:1213–1216, 1968.

Clarke, E. Cranial and intracranial myelomas. Brain 77:61–81, 1954.

Den Hartog, B. J. C., Guazzi, G. C., and Nunes Vicente, A. Réticulo-endothéliose cérébrale primitive (dite encéphalite granulomateuse) et granulome infundibulo-tubérien. Rev. Neurol. 102:20–43, 1960.

Edgar, R., and Dutcher, T. F. Histopathology of the Bing-Neel syndrome. Neurology 11:239–245, 1961.

Feigin, I. Mesenchymal tissues of the nervous system. The indigenous origin of brain macrophages in hypoxic states and in multiple sclerosis. J. Neuropath. Exp. Neurol. 28:6–24, 1969.

Fisher, D., Mantell, B. S., and Urich, H. The clinical diagnosis and treatment of microgliomatosis: report of a case. J. Neurol. Neurosurg. Psychiat. 32:474–478, 1969.

Freireich, E. J., Thomas, L. B., Frei, E., III, Fritz, R. D., and Forkner, C. E., Jr. A distinctive type of intracerebral hemorrhage associated with "blastic crisis" in patients with leukemia. Cancer 13:146–154, 1960.

French, J. D. Plasmacytoma of the hypothalamus: clinical-pathological report of a case. J. Neuropath. Exp. Neurol. 6:265–270, 1947.

Horvat, B., Pena, C., and Fisher, E. R. Primary reticulum cell sarcoma (microglioma) of brain. Arch. Path. 87:609–616, 1969.

Jernstrom, P., Crockett, H. G., and Bachhuber, R. G. Primary lymphosarcoma of cerebral meninges. J. Neurosurg. 24:679–683, 1966.

Nakulas, B. A., and Finlay-Jones, L. R. A lymphoma with central nervous system involvement. Case report. Neurology 12:495–500, 1962.

Kepes, J. J., and Kepes, M. Predominantly cerebral forms of histiocytosis-X. A reappraisal of "Gagel's hypothalamic granuloma," "granuloma infiltrans of the hypothalamus" and "Ayala's disease" with a report of four cases. Acta Neuropath. 14:77–97, 1969.

Kernohan, J. W., and Uihlein, A. Sarcomas of the Brain. Springfield, Ill.: Charles C Thomas, 1962.

Lehrer, H., and McGarry, P. Meningeal lymphosarcoma as a primary intracranial lesion. Southern Med. J. 61:155–159, 1968.

Marshall, A. H. E. An Outline of the Cytology and Pathology of the Reticular Tissue. Edinburgh: Oliver & Boyd, Ltd., 1956.

Marshall, G., Roessmann, U., and van Den Noort, S. Invasive Hodgkin's disease of brain. Report of two new cases and review of American and European literature with clinical-pathologic correlations. Cancer 22:621–630, 1968.

Miller, A. A., and Ramsden, F. Primary reticulosis of the central nervous system "microgliomatosis." Acta Neurochir. 11:439–478, 1963.

Moore, E. W., Thomas, L. B., Shaw, R. K., and Freireich, E. J. The central nervous system in acute leukemia. A postmortem study of 117 consecutive cases, with particular reference to hemorrhages, leukemic infiltrations, and the syndrome of meningeal leukemia. Arch. Intern. Med. 105:451-468, 1960.

Moossy, J., and Wilson, C. B. Solitary intracranial plasmacytoma. Arch. Neurol. 16:212–216, 1967.

Ostertag, B. Primäre zentrale Reticulose und Mikroglia (Reticulo-Mikrogliomatose). Arch. Psychiat. Nervenkr. 206:662-676, 1965.

Peison, B., and Voris, D. Primary sarcoma of the reticuloendothelial system of the brain. Report of a case. J. Neurosurg. 23:630-634, 1965.

Rubé, J., de La Pava, S., and Pickren, J. W. Histiocytosis X with involvement of brain. Cancer 20: 486-492, 1967.

Rubinstein, L. J. Microgliomatosis. Acta Neurochir., Supp. X:201-217, 1964.

Russell, D. S., Marshall, A. H. E., and Smith, F. B. Microgliomatosis. A form of reticulosis affecting the brain. Brain 71:1-15, 1948.

———, and Rubinstein, L. J. Pathology of Tumours of the Nervous System, 3d ed. London: Edward Arnold, 1971.

Samuelsson, S-M., Werner, I., Pontén, J., Nathorst-Windahl, G., and Thorell, J. Reticuloendothelial (perivascular) sarcoma of the brain. Acta Neurol. Scand. 42:567-580, 1966.

Scherer, H. J., Structural development in gliomas. Amer. J. Cancer 34:333-351, 1938.

Schneck, S. A., and Penn, I. De-novo brain tumours in renal-transplant recipients. Lancet 1:983–986, 1971.

Shaw, R. K., Moore, E. W., Freireich, E. J., and Thomas, L. B. Meningeal leukemia. A syndrome resulting from increased intracranial pressure in patients with acute leukemia. Neurology 10:823-833, 1960.

TUMORS AND MALFORMATIONS OF THE BLOOD VESSELS

NEOPLASMS

CAPILLARY HEMANGIOBLASTOMA

SYNONYMS AND RELATED TERMS: Hemangioblastoma; capillary hemangioendothelioma; hemangioendothelioma; angioreticuloma; Lindau's tumor.

DEFINITION AND CYTOGENESIS. This neoplasm, as originally defined by Lindau and by Cushing and Bailey, is widely regarded as being of vascular origin. It is composed of vascular space-forming endothelial elements that are separated by larger cells, termed "stromal cells," whose origin and nature are obscure. For practical diagnostic purposes it is a definite tumor entity, but on histologic grounds many authorities regard the hemangioblastoma and the angioblastic meningioma as fundamentally the same neoplasm (Bailey and Ford; Castaigne et al.). The problem is complex; the microscopic features of both tumors are often closely similar, but they generally differ in their gross appearance and anatomic location (p. 181). Even in these respects they are bridged by transitional forms. Attempts have been made to explain the relationship by suggesting that many hemangioblastomas actually originate from the pia (Russell and Rubinstein) and therefore constitute a variant of meningeal neoplasm. The alternative view has been to separate the angioblastic meningioma from the category of meningiomas altogether, and to include it with the hemangioblastoma as a single group, either as a meningeal form of hemangioma (Bailey and Ford) or without clarifying the actual cell of origin (Castaigne et al.). Much of the problem hinges on the difficulty of determining the nature of the "stromal" cell, and on whether it or the endothelial elements constitute the primary neoplastic cell in this tumor. It could be resolved if it were shown that pial and endothelial cells are interconvertible, but this assumption is so far unsupported on cytologic and electron microscopic evidence. An attempt has been made by electron microscopy to distinguish the structure of the hemangioblastoma from that of the "hemangiopericytoma" (or angioblastic meningioma) (Ramsey), but whether the differences illustrated are really significant must await confirmation.

INCIDENCE AND CLINICAL DATA. Hemangioblastomas are relatively uncommon; their incidence ranges from 1 to 2.5 percent of all intracranial neoplasms. They may occur at any age, but young and middle-aged adults are more frequently affected. In that age group, according to Olivecrona, they account for 7.3 percent of the primary tumors of the posterior fossa, where they are nearly as common as meningiomas. The average age of onset of symptoms is 33, and these are present for an average of 10 months before the diagnosis is made (Pool and Kamrin). There is a preponderance of incidence in males.

ASSOCIATED LESIONS. VON HIPPEL-LINDAU DISEASE. FAMILIAL INCIDENCE. MULTIPLICITY. Capillary hemangioblastomas are classically associated with the condition of **von Hippel-Lindau disease**, which consists in the coexistence of hemangioblastomas of the central nervous system, frequently multiple, angiomatosis of the

retinae, multiple cysts in the kidneys and pancreas, and renal cell carcinomas. The latter may occasionally metastasize (Tonning et al.; Olivecrona; Hoff and Ray). Capillary nevi may also be present in the skin.

The genetic basis of the syndrome is well established (Nicol); a familial incidence has been observed in at least 20 percent of the cases. Only a minority of capillary hemangioblastomas are associated with the Lindau syndrome (figures vary from 10 to 20 percent), and cases of Lindau's disease occurring in the same family often lack several of the stigmata that make up the condition (Raney and Courville). The existence of these **incomplete forms** is recognized in the family histories of patients with capillary hemangioblastomas, and this is especially the case with patients in whom the tumors are multiple. All gradations therefore exist between the full syndrome and its incomplete manifestations within the same family. Finally, solitary hemangioblastomas of the cerebellum occasionally occur as a familial condition, and it may be that this too represents an incomplete form of Lindau's syndrome (Bonebrake and Siqueira).

The association of cerebellar hemangioblastoma and **pheochromocytoma** has also been reported, sometimes on a familial basis (Nibbelink et al.). Another well known association is that of **syringomyelia** and hemangioblastoma, especially when the latter is intramedullary (fig. 247). Although it has been argued, especially by Lindau, that the syringomyelic cavity might be due to transudation of plasma from the tumor vessels, other authors believe that the syringomyelia constitutes a separate congenital anomaly. The latter view is supported by the fact that in some cases the syringomyelia is separate from the tumor (Wyburn-Mason; Poser). Since both syringomyelia and suprarenal tumors have been reported as part of the picture of von Hippel-Lindau disease, it is therefore possible to argue that these separate associations represent either incomplete forms of the condition, or alternatively, a dysgenetic syndrome (or phacomatosis) that is closely allied to it.

Another well known association with capillary hemangioblastomas, especially those that arise in the cerebellum, is that of **erythrocythemia** (Waldmann et al.). After resection of the neoplasm the blood picture often returns to normal, but the erythrocythemia characteristically reappears with recurrence of the tumor (Hoff and Ray). Waldmann and associates were able to identify an erythropoietic substance from the cyst fluid withdrawn from the cerebellar tumor in one example of Lindau's disease.

SITES. The most frequent site of capillary hemangioblastomas is the **cerebellum** (fig. 246). All areas of the cerebellum may be involved, but the paramedian hemispheric area is especially favored. Second in frequency is the spinal cord (fig. 247). A rare but characteristic site is the medulla, where the tumor arises from its floor, presumably from the area postrema (pl. VIII–A). Supratentorial examples are exceptional (Morello and Bianchi); most of these have been reported without accompanying Lindau's syndrome, and when they are attached to the dura the alternative interpretation of angioblastic meningioma is difficut to exclude. However, cerebral hemangioblastomas unattached to the dura have also been described as part of the picture of familial von Hippel-Lindau disease (Rochat; Hoff and Ray).

GROSS. The tumors are almost always well circumscribed and may be either solid (fig. 247) or partly solid and cystic (fig. 246). Forty percent are said to be solid, and about 60 percent cystic with a mural nodule (Cramer and Kimsey; Silver and Hennigar). In these cases they consist mostly of a large well defined cyst with a small intensely hemorrhagic tumor in the wall. The cut surface of the hemangioblastoma is spongy and the smaller cystic areas disclosed on section may consist of dilated blood spaces (fig. 246). Another characteristic feature is the presence of opaque golden yellow foci due to large amounts of sudanophilic lipid (pl. VIII–A). Sometimes areas are found with a rusty brown color due to old hemorrhage.

CEREBELLAR CAPILLARY HEMANGIOBLASTOMA

Figure 246. A large, partly cystic, partly solid, circumscribed capillary hemangioblastoma is seen in a cerebellar hemisphere. (Fig. 79 from Fascicle 35, First Series).

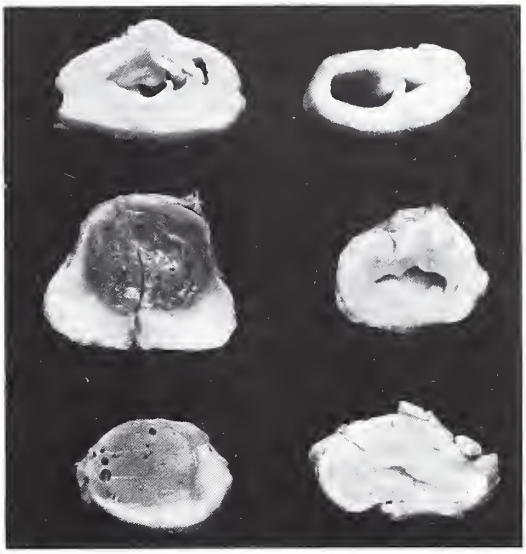

INTRAMEDULLARY CAPILLARY HEMANGIOBLASTOMA ASSOCIATED WITH SYRINGOMYELIA

Figure 247. An intramedullary capillary hemangioblastoma of the spinal cord is associated with syringomyelia above and below the tumor. (Fig. 81 from Fascicle 35, First Series).

MICROSCOPIC. The histologic appearances are quite distinctive. The most striking feature consists in the presence of large numbers of thin-walled, fairly closely packed blood vessels, lined by plump endothelial cells, and separated by larger pale cells with either central or eccentric nuclei (fig. 248). Connective tissue preparations demonstrate an abundant network of reticulin fibers that intersects the tumor cells and delineates clearly the outlines of the vascular architecture (fig. 249).

Under higher power the cells separating the endothelial cells are large, oval or somewhat polygonal, and often display a foamy cytoplasm (fig. 250). In frozen sections stained for fat, large numbers of intracellular sudanophilic lipid droplets can be demonstrated in these cells (pl. VIII–B). The cytologic features of both the endothelial and stromal cells are usually benign, and

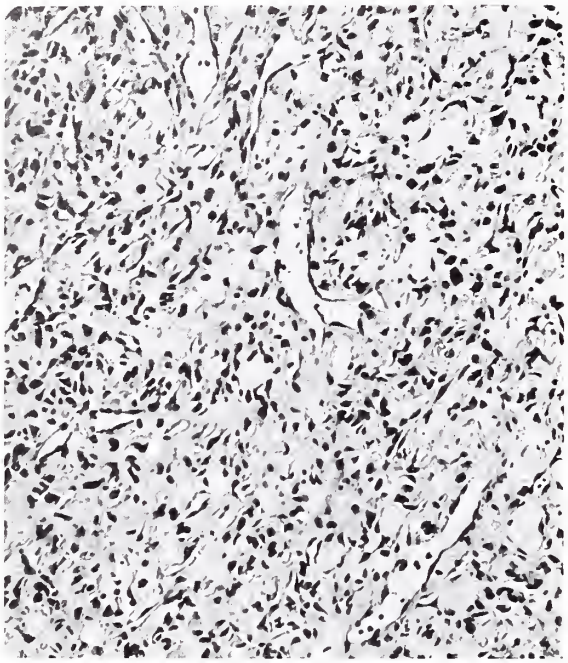

Fig. 248

RETICULIN FIBERS

Figure 249. A reticulin preparation from a capillary hemangioblastoma arising from the floor of the medulla shows an abundant intersecting connective tissue network. × 300.

mitotic figures are not seen. Occasionally, however, the nuclei of the stromal cells are large or hyperchromatic (fig. 250), and the cells are sometimes multinucleated. This may suggest malignancy, but there is no evidence in these cases that these cytologic features have any sinister meaning.

CAPILLARY HEMANGIOBLASTOMA

(Figures 248, 250, and Plate VIII-B from same case)

Figure 248. A low power view shows the general architecture of a spinal capillary hemangioblastoma. × 115.

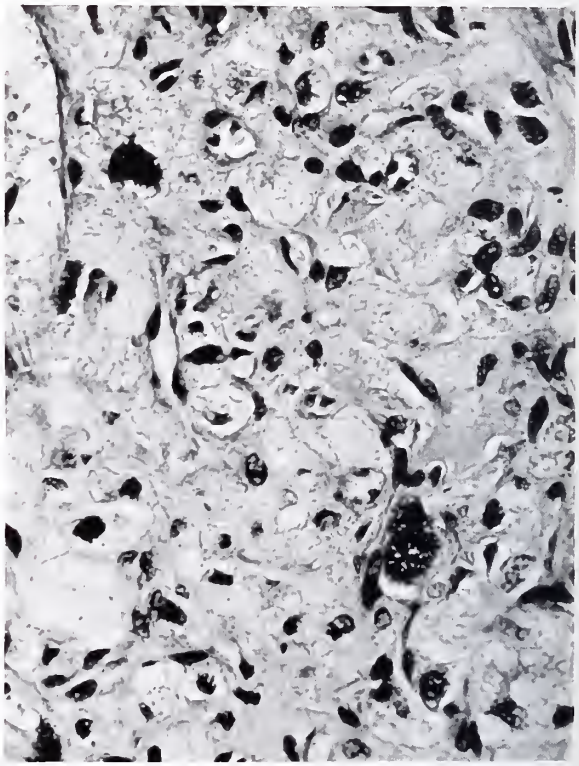

CAPILLARY HEMANGIOBLASTOMA

(Figures 248, 250, and Plate VIII-B from same case)

Figure 250. A high power view shows large stromal cells with foamy cytoplasm. This is due to the presence of large numbers of intracellular sudanophilic lipid droplets. Note also the occasional giant hyperchromatic nuclei. × 350.

The exact nature of these stromal cells is unclear. They resemble the xanthomatous cells found in meningiomas (p. 182). Identical cells may be found in angioblastic meningiomas. They are unlikely to be macrophages or akin to microglia since they are never impregnated with silver carbonate methods specific for the macrophage system. Electron microscopy discloses an abundant cytoplasm with numerous expansions, a smooth endoplasmic reticulum, a wealth of intracytoplasmic microfilaments measuring 70 angstroms in diameter often arranged in closely packed whorls, glycogen granules, and numerous lipid dense bodies. These stromal cells do not possess a basement membrane (Castaigne et al.). On the basis of these features, these workers have excluded a neuroglial, arachnoid, endothelial, or pericytic origin. The presence of dense microfilaments forming intracytoplasmic whorls is also found in some meningiomas (p. 184), but the characteristic interdigitations of the plasma membranes and the frequent desmosomes found in meningiomas, which betoken their kinship to the normal arachnoid cell, are not a feature of the stromal cells in hemangioblastomas. Electron microscopy has therefore not yet resolved the problem of their identification.

GROWTH AND SPREAD. Although grossly well defined, hemangioblastomas have no capsule. The neoplasm is always found to reach the pia, and frequently the capillaries appear to sprout in a somewhat irregular fashion into the adjacent brain. Incomplete removal will therefore lead to recurrence, and the latter may be repeated. However, this is not accompanied by cytologic malignant transformation and, allowing for the confusion between this tumor and the angioblastic meningiomas that are known to have recurred and metastasized, distant dissemination of a capillary hemangioblastoma does not occur.

Within the definition set above a true malignant hemangioblastoma or angiosarcoma arising in the brain cannot be identified. The only other type of growth that might acceptably fit into this category is the mixed glioma and sarcoma (p. 74) in which the sarcomatous element has originated from a malignant proliferation of the blood vessels in conjunction with a glioblastoma. There is no connection between the tumor under discussion and the "monstrocellular" type of neoplasm, which in most cases seems to be a giant cell glioblastoma with intense vascularization.

TREATMENT. The treatment of capillary hemangioblastoma is surgical. Extirpation must be complete if recurrence is to be avoided, and it is usually possible. If not, it is agreed that these tumors should be treated postoperatively with radiation because they are regarded as fairly radiosensitive (Schulz et al.).

PROGNOSIS. RECURRENCE. Since surgical treatment is usually effective, the prognosis is good. Eighty-five percent of patients have been reported alive and well from 5 to 20 years after surgery (Horrax). Recurrence is a well known hazard, especially with tumors that have been incompletely removed (Pennybacker). This may also occur because of the multiplicity of the tumors, and it should be anticipated in cases with Lindau's syndrome (Olivecrona; Hoff and Ray).

DIFFERENTIAL DIAGNOSIS. The problem of differential diagnosis between capillary hemangioblastoma and angioblastic meningioma has already been discussed. Difficulties may also arise with certain highly vascular gliomas, either astrocytomas or oligodendrogliomas, which may

contain a very abundant supply of thin-walled blood vessels closely clustered together, and for which the term "angioglioma" has occasionally been employed. Most tumors of this type fall into the category of gliomas (p. 49). The stromal cells in some cases may resemble large astrocytic or oligodendroglial cells, but the demonstration of large numbers of lipid droplets in frozen sections should help to rule out that diagnosis. Further exclusion of a primary glial tumor will also depend upon the lack of affinity of these cells for appropriate silver impregnations.

Another diagnostic difficulty occasionally arises in distinguishing a capillary hemangioblastoma from a metastatic clear-cell renal carcinoma. The resemblances may be striking, especially with those examples of renal cell carcinoma that have abundant thin-walled vessels. Since Lindau's syndrome is sometimes characterized by the coexistence of capillary hemangioblastoma and renal cell tumors, there may be no easy solution for this differential problem unless more extensive examination of other areas permits a clarification of the diagnosis.

References

Bailey, O. T., and Ford, R. Sclerosing hemangiomas of the central nervous system. Progressive tissue changes in hemangioblastomas of the brain and in so-called angioblastic meningiomas. Amer. J. Path. 18:1-27, 1942.

Bonebrake, R. A., and Siqueira, E. B. The familial occurrence of solitary hemangioblastoma of the cerebellum. Neurology 14:733-743, 1964.

Castaigne, P., David, M., Pertuiset, B., Escourolle, R., and Poirier, J. L'ultrastructure des hémangioblastomes du système nerveux central. Rev. Neurol. 118:5-26, 1968.

Cramer, F., and Kimsey, W. Cerebellar hemangioblastomas. Review of 53 cases, with special reference to cerebellar cysts and the association of polycythemia. Arch. Neurol. Psychiat. 67:237-252, 1952.

Cushing, H., and Bailey, P. Tumors Arising from the Blood Vessels of the Brain. Springfield, Ill.: Charles C Thomas, 1928.

Hoff, J. T., and Ray, B. S. Cerebral hemangioblastoma occurring in a patient with von Hippel-Lindau disease. Case report. J. Neurosurg. 28:365-368, 1968.

Horrax, G. Benign (favourable) types of brain tumor; end results (up to 20 years) with statistics of mortality and useful survival. New Eng. J. Med. 250:981-984, 1954.

Lindau, A. Cysts in the cerebellum; structure, pathogenesis and relations to angiomatosis of the retina. Acta Path. Microbiol. Scand., Supp. 1:1-128, 1926.

Morello, G., and Bianchi, M. Cerebral hemangioblastomas. Review of literature and report of two personal cases. J. Neurosurg. 20:254-264, 1963.

Nibbelink, D. W., Peters, B. H., and McCormick, W. F. On the association of pheochromocytoma and cerebellar hemangioblastoma. Neurology 19:455-460, 1969.

Nicol, A. A. M. Lindau's disease in five generations. Ann. Hum. Genet. 22:7–15, 1957.

Olivecrona, H. The cerebellar angioreticulomas. J. Neurosurg. 9:317-330, 1952.

Pennybacker, J. Recurrence in cerebellar haemangiomas. Zbl. Neurochir. 14:63-73, 1954.

Pool, J. L., and Kamrin, R. P. The Treatment of Intracranial Gliomas by Surgery and Radiation, pp. 258-299. In: Progress in Neurological Surgery, Vol. 1. (Eds.) Krayenbühl, H., Maspes, P. E., and Sweet, W. H. Chicago: Year Book Medical Publishers, Inc., 1966.

Poser, C. M. The Relationship Between Syringomyelia and Neoplasm. Springfield, Ill.: Charles C Thomas, 1956.

Ramsey, H. J. Fine structure of hemangiopericytoma and hemangioendothelioma. Cancer 19:2005-2018, 1966.

Raney, R. B., and Courville, C. B. Multiple hemangioblastomas of the central nervous system; review of the literature and report of a case. Bull. Los Angeles Neurol. Soc. 2:104-114, 1937.

Rochat, G. F. Grosshirnangiom bei der Lindauschen (von Hippelscher) Erkrankung. Klin. Mbl. Augenheilk. 86:23–27, 1931.

Russell, D. S., and Rubinstein, L. J. Pathology of Tumours of the Nervous System, 3d ed. London: Edward Arnold, 1971.

Schulz, M. D., Wang, C-C., Zinninger, G. F., and Tefft, M. Radiotherapy of Intracranial Neoplasms, pp. 318-370. In: Progress in Neurological Surgery, Vol. 2. (Eds.) Krayenbühl, H., Maspes, P. E., and Sweet, W. H. Chicago: Year Book Medical Publishers, Inc., 1968.

Silver, M. L., and Hennigar, G. Cerebellar hemangioma (hemangioblastoma). A clinicopathological review of 40 cases. J. Neurosurg. 9:484-494, 1952.

Tonning, H. O., Warren, R. F., and Barrie, H. J. Familial haemangiomata of the cerebellum. Report of three cases in a family of four. J. Neurosurg. 9:124-132, 1952.

Waldmann, T. A., Levin, E. H., and Baldwin, M. The association of polycythemia with a cerebellar hemangioblastoma. The production of an erythropoiesis stimulating factor by the tumor. Amer. J. Med. 31:318-324, 1961.

Wyburn-Mason, R. The Vascular Abnormalities and Tumours of the Spinal Cord and Its Membranes. London: Kimpton, 1943.

MALFORMATIONS

CAPILLARY TELANGIECTASES

DEFINITION. Capillary telangiectases are malformations composed of dilated capillary blood vessels.

INCIDENCE AND CLINICAL DATA. Most of them are clinically silent, and found incidentally at autopsy, but an exception to this rule is demonstrated in figure 251 and has been reported (Farrell and Forno). Fatal hemorrhage from such a lesion in the pons has also occurred (Teilmann).

The majority of these lesions are seen in middle-aged and elderly people. There is no obvious difference in incidence between the sexes.

MULTIPLICITY. ASSOCIATED LESIONS. In most instances these lesions are solitary, but they may be multiple (figs. 251, 252), often coexisting with multiple cavernous hemangiomas, which may dominate the picture. The distinction between telangiectases and cavernous angiomas is sometimes blurred, and transitional forms are seen. Multiple telangiectases are usually not familial; most examples regarded as such are probably cavernous angiomas rather than telangiectases (Michael and Levin). Exceptionally, hereditary hemorrhagic telangiectasis, or Rendu-Osler-Weber disease, in which multiple cutaneous and mucosal lesions are present, is accompanied by similar lesions in the central nervous system (Heffner and Solitare). However, most cases of this hereditary disease that have neurologic symptoms appear to be secondary to arteriovenous malformations in the lung and result from either cerebral suppuration or cerebral vascular insufficiency. In a few such cases an arteriovenous malformation has been demonstrated in the central nervous system (Boczko).

SITES. The most common site of capillary telangiectasis is the pons, usually in or near the midline. Other sites include the cerebral cortex and the subcortical white matter. Occasionally the cerebellar white matter or the basal ganglia are involved.

GROSS. Telangiectases are usually poorly defined, pink or grayish pink foci. When the vessels are engorged they resemble groups of petechial hemorrhages. Occasionally they may be massive with widespread hemorrhagic discoloration of the affected area (fig. 251).

MICROSCOPIC. The histologic picture is that of a poorly defined group of dilated capillaries which vary greatly in caliber (fig. 252). The capillary vessel wall is usually thin (pl. VIII–C), but occasionally shows slight fibrous thickening. Even when lesions are present in large numbers and form confluent areas (fig. 252), the vessel wall remains thin and the individual capillaries are everywhere separated by normal neural tissue. This is especially well demonstrated in plate VIII–C, which illustrates a small telangiectatic malformation in the anterior horn of the spinal cord. This feature distinguishes these lesions from the cavernous angiomas (pl. VIII–D, E).

Spontaneous hemorrhage is very uncommon, and microscopic examination usually fails to reveal evidence of previous bleeding.

PLATE VIII

CAPILLARY HEMANGIOBLASTOMA OF THE MEDULLA

A. This partly cystic but mostly solid circumscribed capillary hemangioblastoma arose from the floor of the medulla, probably from the area postrema. The yellow areas are due to the presence of large amounts of lipid in the tumor.

SUDANOPHILIC LIPID IN CAPILLARY HEMANGIOBLASTOMA

(Plate VIII-B and Figures 248 and 250 from same case)

B. Numerous small and large sudanophilic lipid droplets are shown in a spinal capillary hemangioblastoma. Frozen section, Sudan IV. × 180.

CAPILLARY TELANGIECTASES

(Plate VIII-C, D, and E from same case)

C. These dilated thin-walled telangiectatic capillary vessels were found in the anterior horn of the spinal cord in a patient with multiple cavernous hemangiomas and capillary telangiectases. van Gieson. × 55.

CAVERNOUS ANGIOMA

D. These are the closely packed, usually thin-walled vascular spaces of a cavernous angioma in a patient with multiple cavernous hemangiomas and capillary telangiectases. van Gieson. × 72.

E. Another cavernous angioma demonstrates marked degenerative changes in its vessel walls, some of which are obliterated and show considerable fibrous hyaline thickening. Note also the empty spaces due to the presence of cholesterol crystals (lower left), and foci of iron pigment in adjacent parenchyma due to old hemorrhage. van Gieson. × 72.

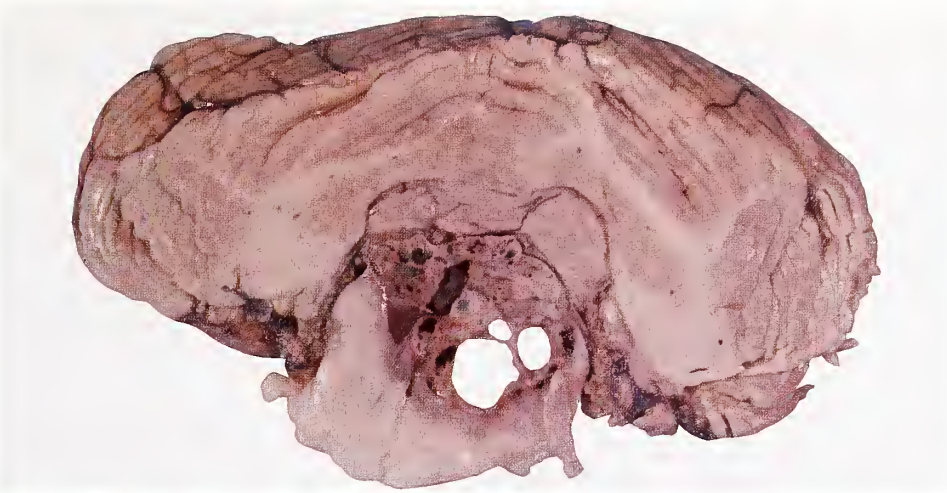

A

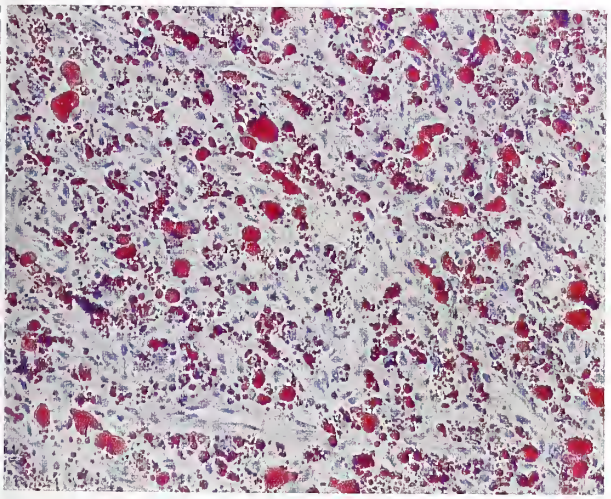

B

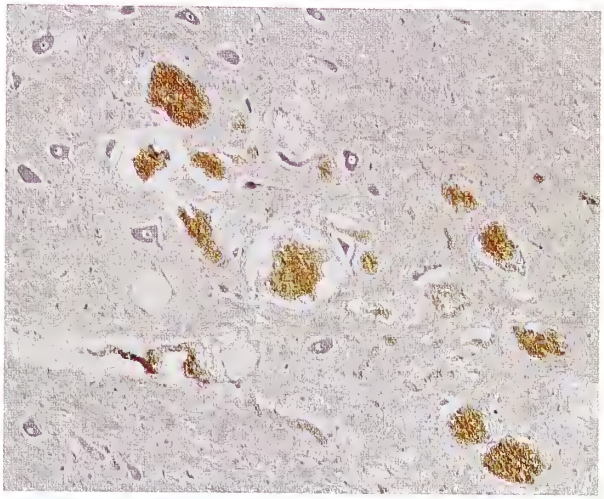

C

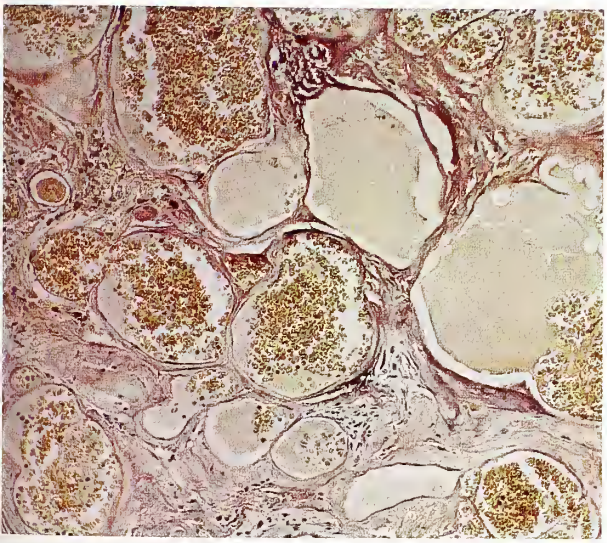

D

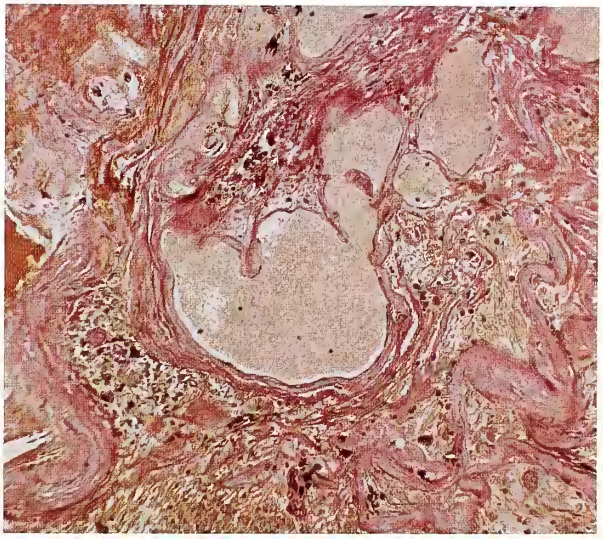

E

PLATE VIII

MULTIPLE CAPILLARY TELANGIECTASES OCCUPYING THE MEDULLA

(Figures 251 and 252 from same case)

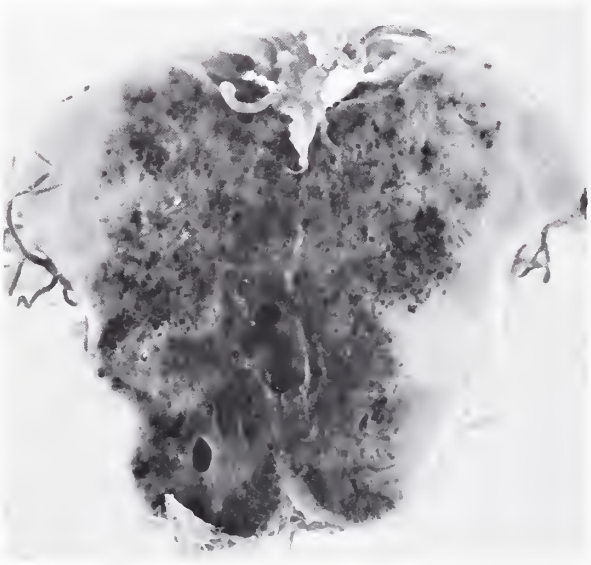

Fig. 251

Figure 251. Massive involvement of the medulla by innumerable adjacent capillary telangiectases is demonstrated. This 63-year-old man, who died of a lymphosarcoma, had had progressive weakness of both legs for eight years, with slurring of speech over the last three years. At necropsy this massive telangiectatic lesion was found involving the medulla and the caudal portion of the pons. A much smaller vascular malformation of similar type was found in the right parietal white matter. (Courtesy of Dr. L. S. Forno, Stanford, Calif.; also fig. 1 from Farrell, D. F., and Forno, L. S. Symptomatic capillary telangiectases of the brainstem without hemorrhage. Report of an unusual case. Neurology 20:341–346, 1970).

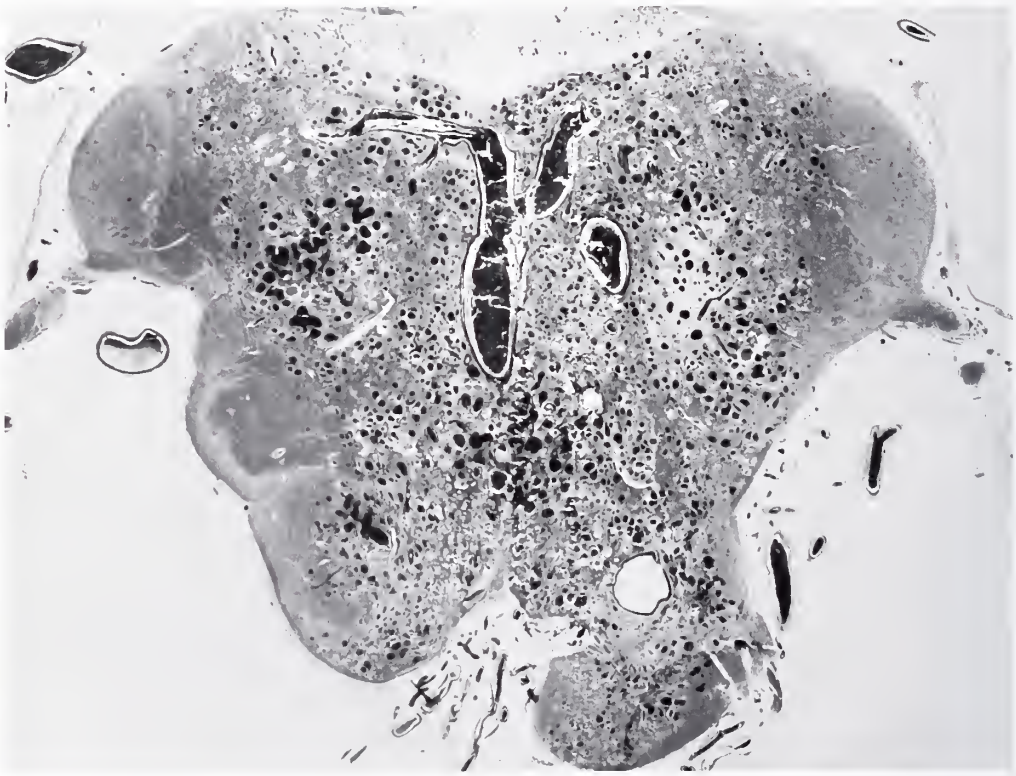

Figure 252. This low power view shows numerous isolated and confluent telangiectatic lesions present throughout the medulla. In places they are confluent and closely clustered together, thus forming transitional stages to cavernous angiomas. × 4. (Courtesy of Dr. L. S. Forno, Stanford, Calif.; also fig. 2 from Farrell, D. F., and Forno, L. S. Symptomatic capillary telangiectases of the brainstem without hemorrhage. Report of an unusual case. Neurology 20:341–346, 1970).

CAVERNOUS ANGIOMA

SYNONYMS AND RELATED TERMS: Cavernous hemangioma; cavernoma.

DEFINITION. The cavernous angioma is a vascular malformation in which abnormal dilated blood vessels are closely clustered together so that they are not separated by normal neural tissue.

INCIDENCE AND CLINICAL DATA. The incidence is difficult to determine, but small incidental lesions are not uncommonly found postmortem. Occasionally a long history of focal seizures may be due to the presence of such a lesion in the region of the rolandic fissure. Some examples with considerable calcification demonstrable radiographically are found in the temporal lobe near the sylvian fissure and are associated with temporal lobe epilepsy (Penfield and Ward). Those situated in the areas of the third and fourth ventricles may produce internal hydrocephalus. Those located in the pons may cause multiple cranial nerve palsies and occasionally a fatal hemorrhage. In the spinal cord they sometimes give rise to transitory symptoms clinically suggestive of a transverse myelitis, or bleed massively causing a massive hematomyelia with rapidly progressive quadriplegia.

They are identified in all age groups, but most often occur between the ages of 30 and 50, and are predominately found in men.

SITES. MULTIPLICITY. ASSOCIATED LESIONS. The most frequent site is the cerebral hemispheres, particularly in the subcortical region (fig. 254). Other favored locations include the pons and the basal ganglia, especially the region of the external capsule (fig. 253). Rarer sites are the spinal cord and the cerebellar white matter.

Multiple lesions are quite common and occur in approximately one third of the cases found incidentally postmortem. Occasionally very large numbers are seen, but usually multiplicity is represented by four or five foci. Multiple cavernous angiomas coexist with multiple capillary telangiectases (pl. VIII–C, D, E). Exceptionally, multiple cavernous angiomas have been reported on a familial basis (Michael and Levin).

Occasionally multiple cavernous angiomas in the central nervous system are accompanied by congenital anomalies elsewhere, such as multiple telangiectases and small cavernous hemangiomas in the skin and liver, renal or hepatic cysts, or horseshoe kidney.

GROSS. Cavernous angiomas vary in size, and range from pinpoint lesions to foci measuring up to several centimeters across. Typically they are well defined, intensely dark red and slightly lobulated, resembling

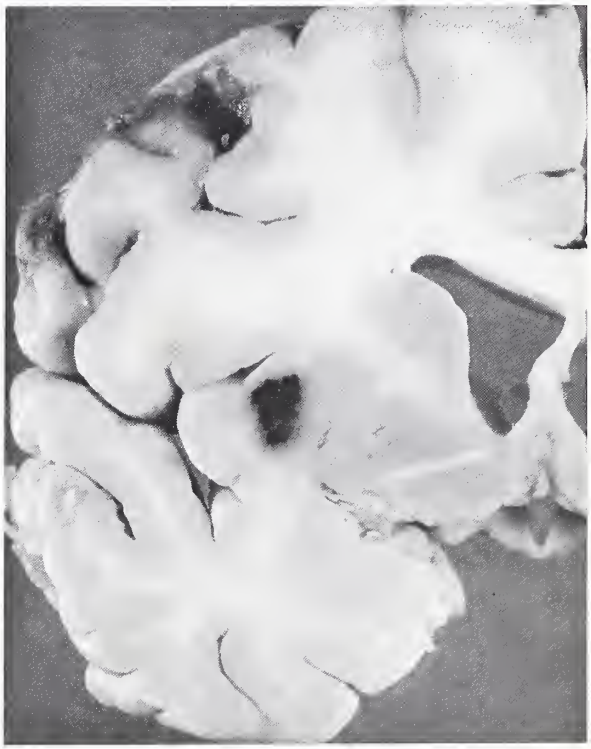

CAVERNOUS ANGIOMA IN BASAL GANGLIA

Figure 253. A well defined, intensely hemorrhagic, and slightly lobulated mulberry-like lesion occupies the external capsule; this lesion was found incidentally at autopsy.

a mulberry (fig. 253). Others are less circumscribed and consist of pinkish areas in which small dilated blood spaces are seen grossly (fig. 254). Not infrequently they are rusty brown due to old hemorrhage, or gritty due to calcification and even bone formation; this is especially likely in the larger examples. The surrounding tissues may be tough due to gliosis, or discolored yellow; brown or yellow staining may similarly color the adjacent meninges or ventricle.

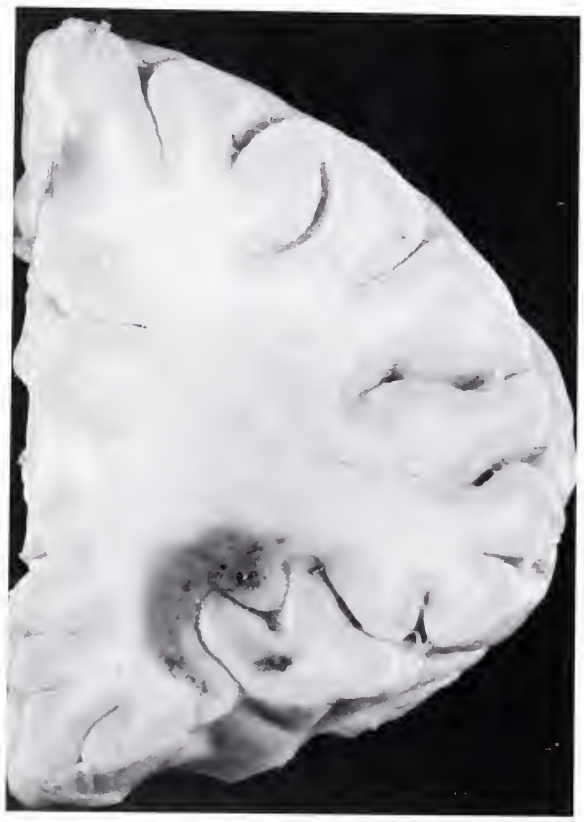

CAVERNOUS HEMANGIOMA IN CORTEX AND SUBOCCIPITAL WHITE MATTER

Figure 254. Discrete and confluent cavernous angiomas are present in the cortex and subcortical white matter of the lateral orbital region; these were found incidentally at autopsy.

MICROSCOPIC. The histologic appearances are those of closely clustered dilated vascular spaces of various sizes. The vessel walls in the early examples are either normal or slightly thickened (pl. VIII–D), but in the older lesions considerable irregular fibrous hyaline thickening of the walls is usually present (pl. VIII–E). In addition various stages of recent and old thrombosis with lamination and subsequent organization may be seen. Other features include cholesterol crystals and golden yellow or dark brown blood pigment from old hemorrhage; these are found mostly in the adjacent neural tissue (pl. VIII–E). Focal calcification is frequent, and occasionally bone formation. The neighboring brain is usually the seat of a variable degree of reactive fibrillary gliosis. In all these features the angiomas differ from the capillary telangiectases, previously described on page 241.

ARTERIOVENOUS MALFORMATIONS

SYNONYMS AND RELATED TERMS: Arteriovenous angioma; arteriovenous aneurysm; cirsoid or serpentine angioma.

DEFINITION. These are vascular malformations in which there is an intimate topographic admixture of arteries and veins.

INCIDENCE AND NATURAL HISTORY. The incidence varies in different neurosurgical series from 0.5 to 3.7 percent. There is a preponderance of males over females to a ratio of 2 to 1. They are seen at any age, but usually present clinically in the second decade. Most cases that are examined postmortem are seen in middle age, especially in the fifth and sixth decades. A small group also affects infants and may be responsible for intracranial hemorrhage at or around the time of birth; some of these cases may then develop porencephaly with the clinical picture of cerebral palsy.

These malformations may produce transient but repeated episodes of intracranial hemorrhage, either subarachnoid or intracerebral. Unlike intracranial hemorrhages resulting from ruptured berry aneurysms, they are seldom fatal. The incidence and severity of the hemorrhages bear no relationship to the size of the aneurysm. The larger examples often cause a variety of symptoms due to progressive gliosis and atrophy of the adjacent cortex, either irritative, such as focal epilepsy, or paralytic. Hemianopsia may also be present. Temporal lobe epilepsy has been reported (Edgar and Baldwin). Headaches may be prominent, and a bruit may be heard on auscultation of the neck, orbit, or temple. Cases with a considerable degree of arteriovenous fistula formation may have severe focal impairment of the cerebral circulation with consequent hypoxia. In extreme examples the fistulous malformation may lead to cardiac hypertrophy and sometimes death from congestive heart failure.

On the other hand some of the small examples, especially in the posterior fossa, have been linked with spontaneous cerebral hemorrhage in the younger age groups in whom the cause of bleeding is undetected by clinical examination and special investigation. In fatal cases small arteriovenous and venous malformations have been found that were difficult to locate grossly on account of their situation and small size. The term "cryptic" has been coined for these vascular lesions (Crawford and Russell). The 20 patients whose cases were described by these authors were all under 40 years of age; 15 were below the age of 20.

ASSOCIATED LESIONS. Aside from the rare variant of mesencephalo-oculofacial angiomatosis (p. 250), an association of arteriovenous malformations has been reported with single or multiple congenital berry aneurysms of the intracranial arteries (Anderson and Blackwood). Although in most cases the separate aneurysms arose on arteries that fed the malformations, it is probable that the two types of lesion are independent.

A number of examples, including those characterized by an aneurysm of the vein of Galen, have been associated with multiple congenital cardiac defects, especially Fallot's tetralogy and patent ductus arteriosus (figs. 256, 257). I have examined two such cases from patients aged five days and 15 months respectively. Other cardiac anomalies include transposition of the great vessels with patent foramen ovale (Hirano and Solomon).

SITES. The distribution of the middle cerebral artery is the most frequently affected (figs. 255, 256; pl. IX–A). In many cases the leptomeninges are principally involved. In some examples the malformation is restricted to the subarachnoid space and in others there is a variable degree of cortical and subcortical involvement that may be extensive, with encroachment of the malformation into the center of the brain. In such centrally located lesions, the vein of Galen and its tributaries may be implicated; the extensive dilatation that may specifically affect the vein of Galen leads to the development of a characteristic picture to be described. Some cases of arteriovenous malformation also involve the choroid plexuses, which have occasionally been reported as the specific site of an arteriovenous malformation responsible for fatal intraventricular hemorrhage (McConnell and Leonard).

The cerebellum and spinal cord are less often affected, but the former appears to be a site of predilection for the smaller or "cryptic" examples.

GROSS. In the larger malformations, the macroscopic appearances are quite characteristic, but they are best demonstrated in specimens that have been injected postmortem (fig. 256). During life the extent of the malformation is often strikingly revealed by angiography. Figure 255 illustrates a massive arteriovenous malformation in the distribution of the right middle cerebral artery in a 25-year-old woman who had a weak left arm and hand all her life. In this patient the vascular malformation affected also the vein of Galen, the aneurysmal dilatation of which is demonstrable in the arteriogram. In the large leptomeningeal examples situated over the convexity of the brain, the markedly fibrosed and frequently rusty brown arachnoid covers and obscures irregular leashes of highly abnormal tortuous thickened arteries and veins, as strikingly illustrated in the case described by Brihaye and Blackwood (fig. 256). The underlying cortex and cerebral white matter frequently show atrophy and gliosis. On section, irregular vascular cavities formed by arteries and veins of all sizes are found closely clustered and replacing the neural parenchyma. The adjacent brain is toughened, gliotic, and discolored yellowish or light brown from old hemorrhage. Large arteriovenous fistulas may be seen, as illustrated in plate IX–A, which was taken from the postmortem specimen of the same case whose arteriogram is reproduced in figure

CAROTID ARTERIOGRAM OF ARTERIOVENOUS MALFORMATION

(Figure 255 and Plate IX-A from same case)

Figure 255. A large arteriovenous malformation in the distribution of the right middle cerebral arterial supply is demonstrated in this carotid arteriogram. This 25-year-old woman was known to have had a weak left arm and hand all her life. Death was due to massive intraventricular hemorrhage. The gross postmortem appearance of this arteriovenous malformation is shown in plate IX-A. (Courtesy of Dr. L. M. Zatz, Stanford, Calif.)

255. The venous channels draining the malformation usually show considerable dilatation; aneurysmal sacs of various sizes resembling grossly those of the common congenital berry aneurysms may be seen within the mass of blood vessels. Frequently calcification is felt in the vascular walls.

The malformation may eventually lead to fatal bleeding (pl. IX–A). In the "cryptic" examples the gross appearance is unrewarding; only massive hemorrhage is found. The disclosure of these small arteriovenous malformations is dependent on a careful and exhaustive selection of samples for microscopic examination.

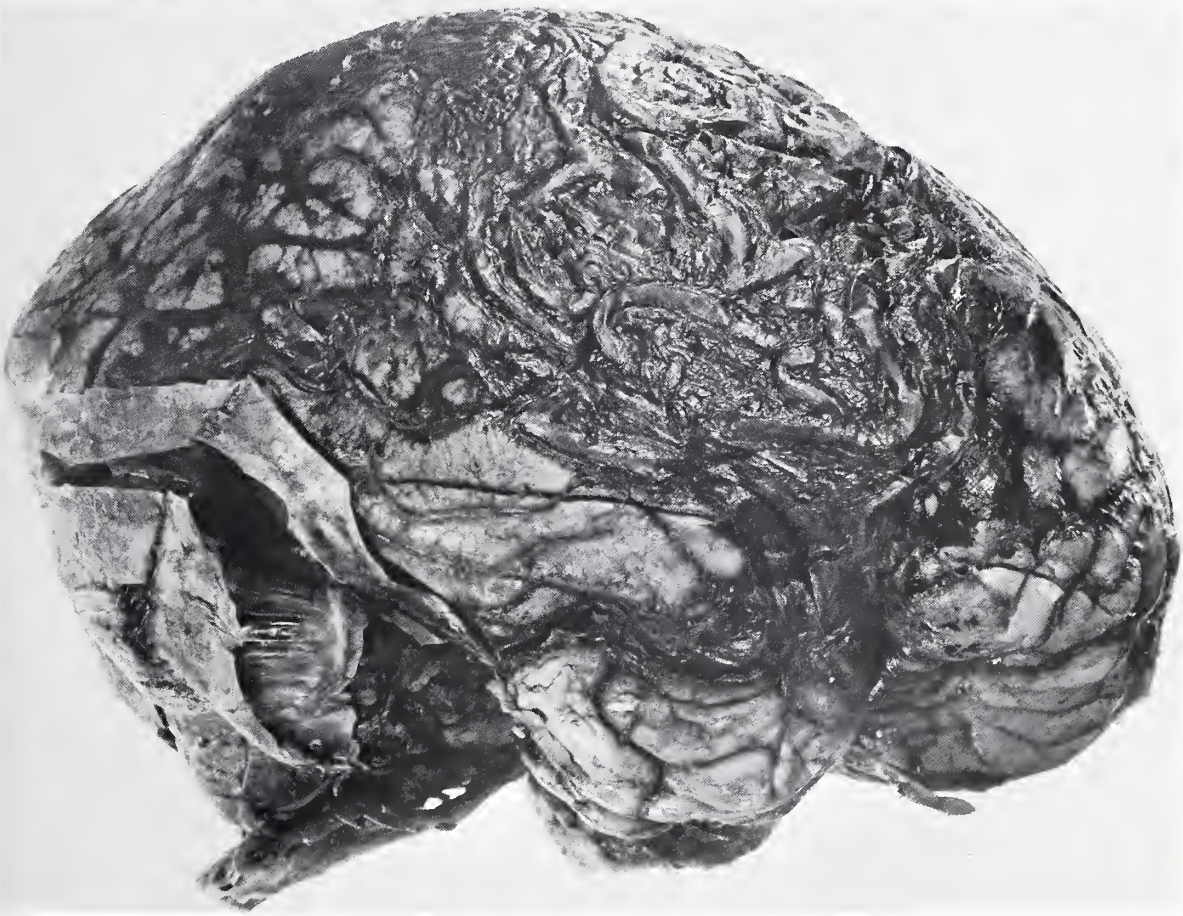

ARTERIOVENOUS MALFORMATION

Figure 256. An extensive arteriovenous malformation occupies the subarachnoid space over the right cerebral convexity. This 53-year-old man had suffered since childhood from attacks of twitching of the left limbs, sometimes followed by unconsciousness. He developed progressive hemiplegia in the last four years of his life, and mental deterioration in the last two years.

The blood vessels have been injected postmortem with a colored celloidin solution. The dura on either side of the right lateral venous dural sinus is still attached to the specimen. (Courtesy of Professor W. B. Blackwood, London, England; also fig. 2 from Brihaye, J., and Blackwood, W. Arteriovenous aneurysm of the cerebral hemispheres. J. Path. Bact. 73:25–31, 1957).

MICROSCOPIC. The histologic picture usually presents no problem and is easily recognizable from the presence of large numbers of abnormal arteries and veins in close proximity, often showing fistulous communications. The blood vessels are generally easily identified in hematoxylin and eosin preparations, but their exact recognition is often helped with special stains, such as the van Gieson-elastic stain (pl. IX–B). Aside from their obvious increase in number and size, the structure of the blood vessels is usually quite abnormal. In arteries, various alterations in the normal structure of the elastic lamellae and muscle fibers are seen. The internal elastic lamella may either be duplicated, interrupted, or lost. The media varies in thickness; it is often considerably reduced or altogether absent in places. It may show focal thickenings with the formation of small leiomyomatous nodules that project into the lumen. It is sometimes difficult to decide whether the pathologic vessels are abnormal or degenerated arteries, or veins that have become partly arterialized. The same vascular space may show a wall that is suggestive of an artery along one segment and a venous structure along another; it probably represents an arteriovenous fistulous communication (pl. IX–B). Secondary changes may also occur, including fibrous hyaline thickening of the venous walls, atheromatous plaques, thromboses in various stages of organization and endothelialization, and finally calcification of the vessel walls and occasionally even bone formation. The calcifications are highly irregular and different from the regular pattern seen in Sturge-Weber disease.

The surrounding brain usually shows cortical atrophy, fibrillary gliosis of the white matter, various amounts of iron pigment either free or in macrophages, and in some cases variable degrees of inflammatory cellular reaction.

VARIANTS

Mesencephalo-Oculo-Facial Angiomatosis

A characteristic but very rare form of arteriovenous malformation has been described in the midbrain associated with homolateral angiomatosis of the retina and the presence of a cutaneous nevus in the distribution of the trigeminal nerve (Wyburn-Mason, 1943a).

Aneurysm of the Vein of Galen

This well known variety of arteriovenous malformation consists largely in an impressive aneurysmal dilatation, or strictly speaking a varix, of the great vein of Galen (fig. 257), which may cause compression of the midbrain and aqueduct. In the example illustrated, in a 5-day-old infant with Fallot's tetralogy and a patent ductus arteriosus, the arteriovenous malformation involved the posterior, middle, and anterior cerebral arteries as well as the great vein of Galen. Considerable cerebral damage resulted, with extensive atrophy of the cortex and gliosis of the subcortical and central white matter (figs. 257, 258). Other examples have been recorded and reviewed by Hirano and Terry, and by Hirano and Solomon.

PROGNOSIS. This is most difficult to determine. The first episode of subarachnoid hemorrhage from a large arteriovenous malformation is seldom fatal. The subsequent history is often punctuated by repeated episodes of bleeding, and progressive motor and sensory impairment usually occurs, depending on the progressive alterations that take place in the vascular malformation itself and the secondary degenerative and atrophic changes that occur in the neural parenchyma. The ultimate prognosis is poor.

ARTERIOVENOUS MALFORMATION INVOLVING THE VEIN OF GALEN

(Figures 257 and 258 from same case)

Figure 257. This massive aneurysmal dilatation of the vein of Galen was found in a 5-day-old infant with Fallot's tetralogy and patent ductus arteriosus. There is severe atrophy of both inferior occipital cortices from old infarction.

EFFECTS UPON THE CEREBRAL CORTEX

Figure 258. There is extensive infarction with cortical atrophy over the territories supplied by the middle and posterior cerebral arteries, and gliosis of the subcortical and deep white matter. The dilated ventricular system contains fresh blood clot due to terminal intraventricular hemorrhage.

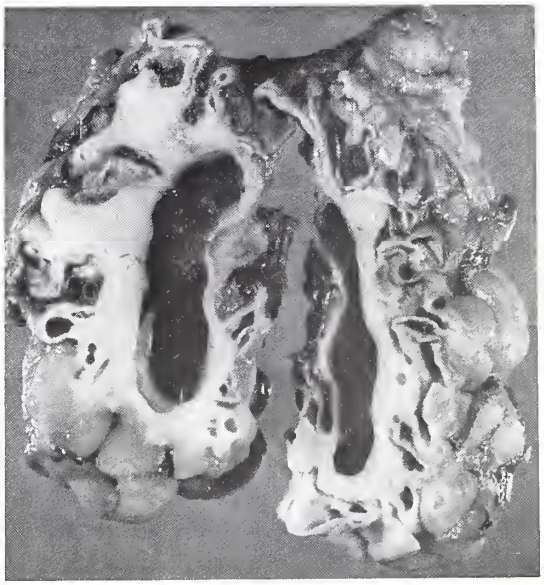

Fig. 258

PLATE IX

ARTERIOVENOUS MALFORMATION

(Plate IX-A and Figure 255 from same case)

A. This massive arteriovenous malformation in the right basal ganglia was found in a 25-year-old woman. The malformation was fed by branches of the middle cerebral and basilar arteries, and drained mainly by the vein of Galen which measured almost 1 cm. in diameter. Death was due to massive intraventricular hemorrhage. This patient was known to have had a weak left arm and hand all her life. The lateral angiogram of this patient is seen in figure 255.

LEPTOMENINGEAL ARTERIOVENOUS MALFORMATION

B. This is a low power view of abnormal arteries and veins in a leptomeningeal arteriovenous malformation. Elastic-van Gieson. × 35.

VENOUS MALFORMATIONS OF THE SPINAL CORD (FOIX-ALAJOUANINE DISEASE, OR ANGIODYSGENETIC MYELOMALACIA)

(Plate IX-C and D from same case)

C. This lumbar segment of the spinal cord is from a 55-year-old man with a 2-year history of ingravescent weakness of his lower limbs progressing to flaccid paraplegia and an ascending sensory deficit reaching the upper thoracic levels. There is varicosity and redundancy of the leptomeningeal veins, especially over the dorsal aspect of the cord, but involving also the anterior spinal vein. There is cavitation of the central aspect of the dorsal half of the cord, mostly on the right, but with smaller incipient lesions on the left. There is marked fibrosis of the posterior nerve roots. van Gieson stain on celloidin section. × 12.

D. This enlargement of part of the previous figure demonstrates considerable dilatation of the spinal leptomeningeal veins. Numerous bundles of regenerating peripheral nerves (staining light brown) are infiltrating the center of the cord, presumably arising from a dorsal nerve root. Axons were easily demonstrable with appropriate silver preparations. van Gieson stain on celloidin section. × 30.

STURGE-WEBER DISEASE

E. This superior view reveals the cerebral hemispheres covered by an extensive subarachnoid angiomatous malformation in a case of Sturge-Weber disease. (Courtesy of the Armed Forces Institute of Pathology).

MENINGIO-ANGIOMATOSIS

F. Irregular proliferation of thick-walled blood vessels, hyalinized fibrous connective tissue, and scattered psammoma bodies are seen in the cortex of a 17-year-old girl who had generalized seizures since the age of nine. This lesion was removed surgically from the temporal lobe. Other areas in the same specimen showed an arteriovenous malformation in the leptomeninges and ectopic ependymal cells scattered throughout the abnormal cortex. This lesion is characteristic of the central form of von Recklinghausen's neurofibromatosis. The close intermingling of vascular, meningeal, and intervening (golden yellow) neuroglial tissue is well demonstrated with this stain. van Gieson. × 140.

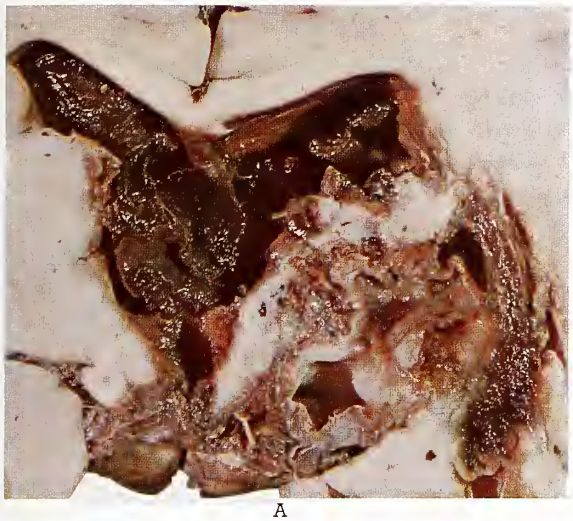

A

B

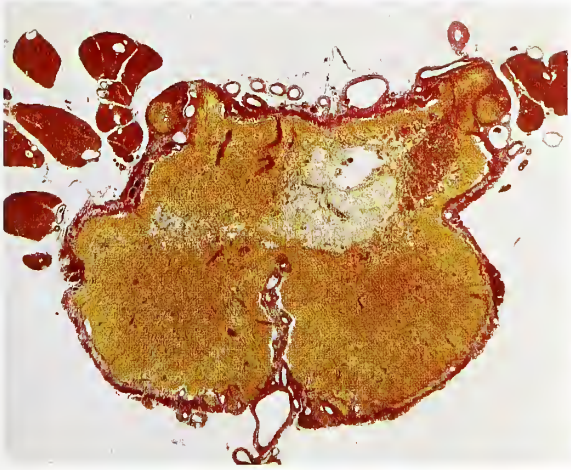

C

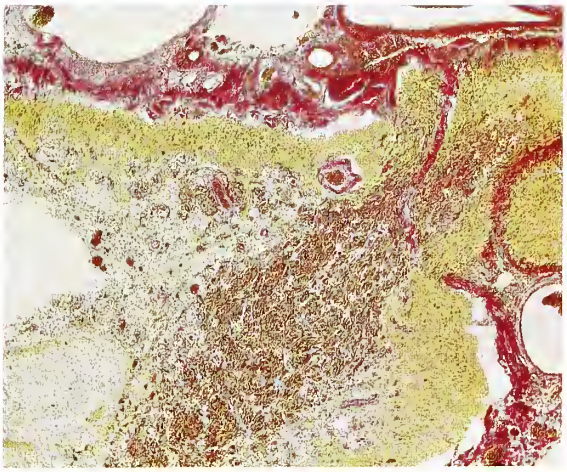

D

E

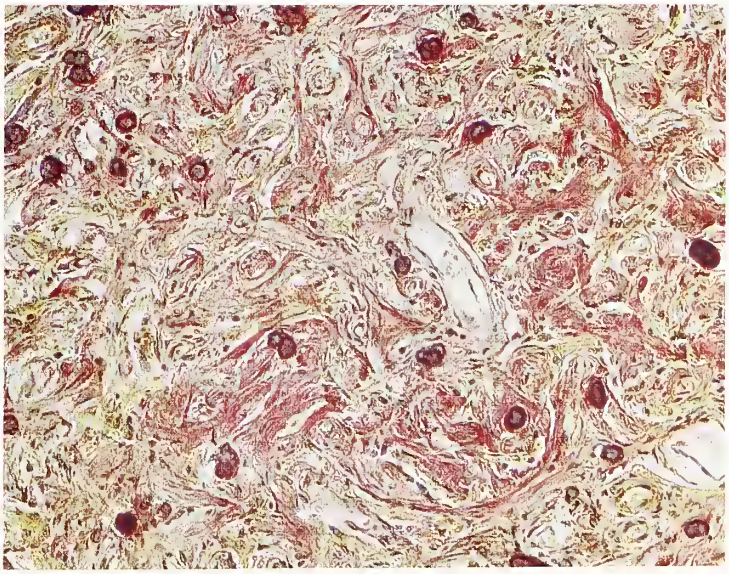

F

PLATE IX

VENOUS MALFORMATIONS

SYNONYMS AND RELATED TERMS: Venous angioma; cirsoid or racemose varices.

DEFINITION. This vascular malformation is composed solely of veins. The abnormality may consist either of an enlarged single vein with many tributaries (fig. 259) or of a compact group of such veins.

INCIDENCE AND SITES. The most frequent site of involvement is the spinal cord and its meninges (Wyburn-Mason, 1943b), where they form 3 to 4 percent of the spinal tumors. Most cases occur between the ages of 20 and 60. There is a predominance of men to women in the ratio of 3 to 1. The brain is much less often affected; most examples involve the parietal region.

In the spinal cord the invariable site is the part of the cord below the middle thoracic segments (Wyburn-Mason). The dorsal surface is more often involved than the ventral (fig. 259).

GROSS. The gross appearance is highly variable. In some cases there is only slight varicosity of the veins over the posterior surface of the cord. In others a large distended vein with impressive tributaries is seen (fig. 259). In others still the venous malformation is more extensive and consists of a highly tortuous conglomeration of grossly dilated and engorged blood vessels. In long-standing cases atrophy of the cord and gliosis may be conspicuous.

Over the cerebral hemispheres the appearances are nondistinctive, and the diagnosis of venous malformation is usually made on microscopic examination.

MICROSCOPIC. The microscopic appearance consists of numerous veins, usually in the subarachnoid space, varying greatly in caliber (pl. IX–C, D) and often showing marked hyaline collagenous thickening. Thrombosis and secondary inflammation are likely to occur in the vessel walls.

VENOUS MALFORMATION OF THE SPINAL CORD

Figure 259. These enormously dilated veins represent a massive venous malformation over the posterior aspect of the spinal cord that was disclosed at operation. (Courtesy of Medical Illustration Department, Veterans Administration Hospital, San Francisco, Calif.)

VARIANTS

"Angiodysgenetic Myelomalacia"

SYNONYMS AND RELATED TERMS: "Subacute necrotic myelitis"; Foix-Alajouanine disease.

This is a rather uncommon but well known disease characterized clinically by a progressive paraplegia, at first spastic then flaccid, followed by ascending sensory loss and accompanied by albumin-cytologic disassociation in the cerebrospinal fluid. It presents pathologically as predominantly central necrosis of the lower part of the spinal cord, usually beginning in the lower thoracic and lumbar levels and ending in the midthoracic region. Middle-aged or older men are usually affected. The disease generally progresses over a period of 2 to 6 years. Because of the cellular inflammatory element which is sometimes found in the intramedullary vessels and more frequently in the redundant and hyalinized extramedullary and radicular veins in the subarachnoid space, the condition has been regarded either as a subacute necrotic myelitis by its original observers, or as a primary subacute spinal thrombophlebitis (Mair and Folkerts). The microscopic picture is highly characteristic and illustrated in plate IX–C and D. There is considerable thickening and redundancy of the veins in the subarachnoid space, especially over the dorsal aspect of the cord, with necrosis of the spinal cord parenchyma that may be extensive. There is considerable fibrosis of the spinal nerve roots. Secondary degenerative changes also occur, especially Wallerian degeneration of the dorsal columns. Attempts at nerve fiber regeneration by sprouting peripheral nerves into the necrotic parenchyma may be conspicuous (pl. IX–D). These nerve fibers usually penetrate the cord; they originate from the perivascular nerves lying in the subarachnoid space, and grow along the anterior spinal artery in the ventral fissure and subsequently along its intraspinal branches in the central gray commissure. In other cases the regenerative sprouting of these nerves seems to have originated from residual posterior nerve roots (pl. IX–D).

The etiology of this disease is somewhat controversial, but it is regarded by many authorities as the result of a venous malformation in the spinal leptomeningeal veins and their radicular branches (Wyburn-Mason, 1943b; Brion et al.). The condition is referred to as "angiodysgenetic myelomalacia" or "angiodysgenetic necrotizing myelopathy" in the German literature, where its basic vascular pathogenesis is generally endorsed (Jellinger et al.).

Sturge-Weber Disease

SYNONYMS AND RELATED TERMS: Encephalotrigeminal angiomatosis; encephalofacial angiomatosis.

DEFINITION AND CHARACTERISTICS. This rare condition consists in the association of an extensive capillary-venous malformation affecting one cerebral hemisphere with a homolateral cutaneous nevus or "port wine" stain in the trigeminal nerve region together with contralateral hemiparesis and Jacksonian epilepsy. Glaucoma may also be present on the affected side. A characteristic feature of the skin nevus is that the distribution of the ophthalmic branch is always involved to some degree.

A well known feature of this condition is the demonstration of a characteristic "tramline" or "railroad track" type of calcification radiologically, due to the presence of numerous small foci of calcification in the cortical gyri (fig. 260).

The affected brain is atrophied. The overlying leptomeninges are thickened and contain large numbers of thin-walled small blood vessels (pl. IX–E). Histologically, innumerable small veins and capillaries are found in the subarachnoid space, frequently showing hyaline thickening of their walls. These vessels are also present in abundance in the underlying cortex, and may show progressive calcification that may become

STURGE-WEBER DISEASE

Figure 260. Unilateral intracerebral "railroad track" calcifications shown in a case of Sturge-Weber disease. (Courtesy of the Armed Forces Institute of Pathology).

confluent and laminated. In the more severely affected areas, these irregular masses occupy the outer part of the cortex but spare the subpial zone (Alexander and Norman). Secondary changes such as atrophy and reactive gliosis are found in the adjacent parenchyma with a patchy loss of nerve cells.

Incomplete manifestations of the disease have been reported, such as the presence of the syndrome without x-ray evidence of calcification. A few familial examples have also been recorded, suggesting that the disease may occasionally have a genetic basis.

The condition has also been associated with other malformative conditions, especially angiomatosis of the choroid plexuses, of the pituitary stalk, and of the choroid of the eye, as well as with angiomatous malformations in the lung, intestine, and ovary (Wohlwill and Yakovlev).

References

Alexander, G. L., and Norman, R. M. The Sturge-Weber Syndrome. Bristol: Wright, 1960.

Anderson, R. M., and Blackwood, W. The association of arteriovenous angioma and saccular aneurysm of the arteries of the brain. J. Path. Bact. 77:101-110, 1959.

Boczko, M. L. Neurological implications of hereditary hemorrhagic telangiectasis. J. Nerv. Ment. Dis. 139:525-536, 1964.

Brihaye, J., and Blackwood, W. Arterio-venous aneurysm of the cerebral hemispheres. J. Path. Bact. 73:25-31, 1957.

Brion, S., Netsky, M. G., and Zimmerman, H. M. Vascular malformations of the spinal cord. Arch. Neurol. 68:339-361, 1952.

Crawford, J. V., and Russell, D. S. Cryptic arteriovenous and venous hamartomas of the brain. J. Neurol. Neurosurg. Psychiat. 19:1-11, 1956.

Edgar, R., and Baldwin, M. Vascular malformation associated with temporal lobe epilepsy. J. Neurosurg. 17:638-656, 1960.

Farrell, D. F., and Forno, L. S. Symptomatic capillary telangiectasis of the brainstem without hemorrhage. Report of an unusual case. Neurology 20:341–346, 1970.

Heffner, R. R., Jr., and Solitare, G. B. Hereditary haemorrhagic telangiectasia; neuropathological observations. J. Neurol. Neurosurg. Psychiat. 32: 604–608, 1969.

Hirano, A., and Solomon, S. Arteriovenous aneurysm of the vein of Galen. Arch. Neurol. 3:589-593, 1960.

_____, and Terry, R. D. Aneurysm of the vein of Galen. J. Neuropath. Exp. Neurol. 17:424–429, 1958.

Jellinger, K., Minauf, M., Garzuly, F., and Neumayer, E. Angiodysgenetische nekrotisierende Myelopathie. Arch. Psychiat. Nervenkr. 211:377–404, 1968.

Mair, W. G. P., and Folkerts, J. F. Necrosis of the spinal cord due to thrombophlebitis (subacute necrotic myelitis). Brain 76:563–575, 1953.

McConnell, T. H., and Leonard, J. S. Microangiomatous malformations with intraventricular hemorrhage. Report of two unusual cases. Neurology 17:618–620, 1967.

Michael, J. C., and Levin, P. M. Multiple telangiectases of the brain (discussion of the hereditary factors in their development). Arch. Neurol. 36:514–529, 1936.

Penfield, W., and Ward, A. Calcifying epileptogenic lesions. Hemangioma calcificans; report of a case. Arch. Neurol. 60:20–36, 1948.

Teilmann, K. Hemangiomas of the pons. Arch. Neurol. 69:208–223, 1953.

Wohlwill, F. J., and Yakovlev, P. I. Histopathology of meningo-facial angiomatosis (Sturge-Weber's disease). Report of four cases. J. Neuropath. Exp. Neurol. 16:341–364, 1957.

Wyburn-Mason, R. Arteriovenous aneurysm of midbrain and retina, facial naevi and mental changes. Brain 66:163–203, 1943a.

_____. The Vascular Abnormalities and Tumours of the Spinal Cord and Its Membranes. London: Kimpton, 1943b.

TUMORS OF THE CHOROID PLEXUS AND RELATED STRUCTURES

CHOROID PLEXUS PAPILLOMAS

SYNONYMS AND RELATED TERMS: Papilloma choroideum.

DEFINITION AND HISTOGENESIS. These neoplasms are composed of adult epithelial cells that cover the ventricular choroid plexuses. The choroid plexus epithelium originates from a differentiation of the primitive medullary epithelium, and is related embryologically to the ependyma. Strictly speaking therefore, it would be logical to include the tumors derived therefrom with those of the ependymal group. However, little is gained by adopting too rigid an embryogenetic view on this aspect of oncology. In both structure and function, the choroid plexus epithelium is very different from ependymal cells, and is closely akin morphologically to the surface epithelia that form the mucosal linings in other parts of the body. The resemblance is even more pronounced in the tumors that originate from the choroid plexus, both the benign and the rare malignant varieties. They have the features of papilloma and carcinoma respectively. Because of these distinctive characters and the presence of a vascular collagenous stroma derived from the foldings of the leptomeninges that form the vela interposita, it is felt that these neoplasms should be treated separately from the tumors of the glioma group.

NATURAL HISTORY AND CLINICAL EFFECTS. Choroid plexus papillomas are usually slowly growing and because of their intraventricular location they may remain symptomless for a relatively considerable time. One consequence of their growth is the production of **internal hydrocephalus**, attributable to an excessive formation of cerebrospinal fluid by the papilloma (Smith; Ray and Peck), with the corollary that surgical removal of the tumor may be followed by regression of the hydrocephalus (Matson). Another well known complication of these neoplasms is their liability to spontaneous bleeding. This may result in a low grade basal meningitis with consequent fibrosis, which may constitute an additional etiologic factor for the production of internal hydrocephalus.

INCIDENCE. Choroid plexus papillomas are rare, accounting for less than one percent of all primary intracranial tumors. Although they occur at any age the majority are found in young subjects, especially in the first decade. Congenital examples have been reported (Matson). The sex incidence shows a marked preponderance in males.

SITES. The most frequent site is the cavity and lateral recesses of the fourth ventricle, accounting for at least 50 percent of all cases. Next in frequency is the lateral ventricle, the left side being more commonly involved than the right (fig. 261). The third ventricle is seldom involved. A classic site is the pontocerebellar angle, where the tumor presumably arises from tufts of choroid plexus that project into the lateral recess (fig. 262).

CHOROID PLEXUS PAPILLOMA OF LATERAL VENTRICLE

Figure 261. This papillary tumor arose in the left lateral ventricle in a 7-year-old boy. There is considerable generalized ventricular dilatation due to hydrocephalus. (Courtesy of the Armed Forces Institute of Pathology).

CHOROID PLEXUS PAPILLOMA OF PONTOCEREBELLAR ANGLE

Figure 262. This choroid plexus papilloma arises from the right lateral recess and presents as a pontocerebellar angle tumor. (Fig. 37 from Fascicle 35, First Series; also fig. 6 from Kernohan, J. W., Woltman, H. W., and Adson, A. W. Gliomas of the cerebellopontine angle. J. Neuropath. Exp. Neurol. 7:349–367, 1948).

In adults choroid plexus papillomas are much more likely to be situated below the tentorium than above.

GROSS. The tumor is readily recognizable as a dark pink or red globular mass with an irregular papillary surface resembling a cauliflower (figs. 261, 262). When present in a ventricle it may cause considerable enlargement of the ventricular cavity on that side. When arising from the lateral recess it may compress the adjacent cerebellum, pons, and medulla and cause the same local distortions as other angle tumors. Except for the rare malignant examples, papillomas are well defined and quite separate from the brain. On cut surface their texture is somewhat granular, and occasionally small gritty foci of calcification are found; in a few cases calcification may be extensive. Small foci of hemorrhage may also be present.

MICROSCOPIC. The distinctive histologic picture closely resembles that of the normal choroid plexus. It consists in an arrangement of delicate papillary formations composed of usually single layers of columnar or cuboidal epithelium that rest upon a delicate vascular connective tissue stroma (fig. 263). Occasionally there is some piling up of the epithelium. Cilia and blepharoplasts are found only in some infantile examples. Their presence probably recapitulates an early stage of fetal life in which the choroid plexus epithelium passes through a transitory ciliated phase. Except in the rare malignant tumors the cytologic features are entirely benign. Although the nuclei may show a slight degree of hyperchromatism, cytologic anaplasia, multinucleation, and giant cell formation are not seen. Mitotic figures are virtually absent. There are no foci of necrosis or invasive features.

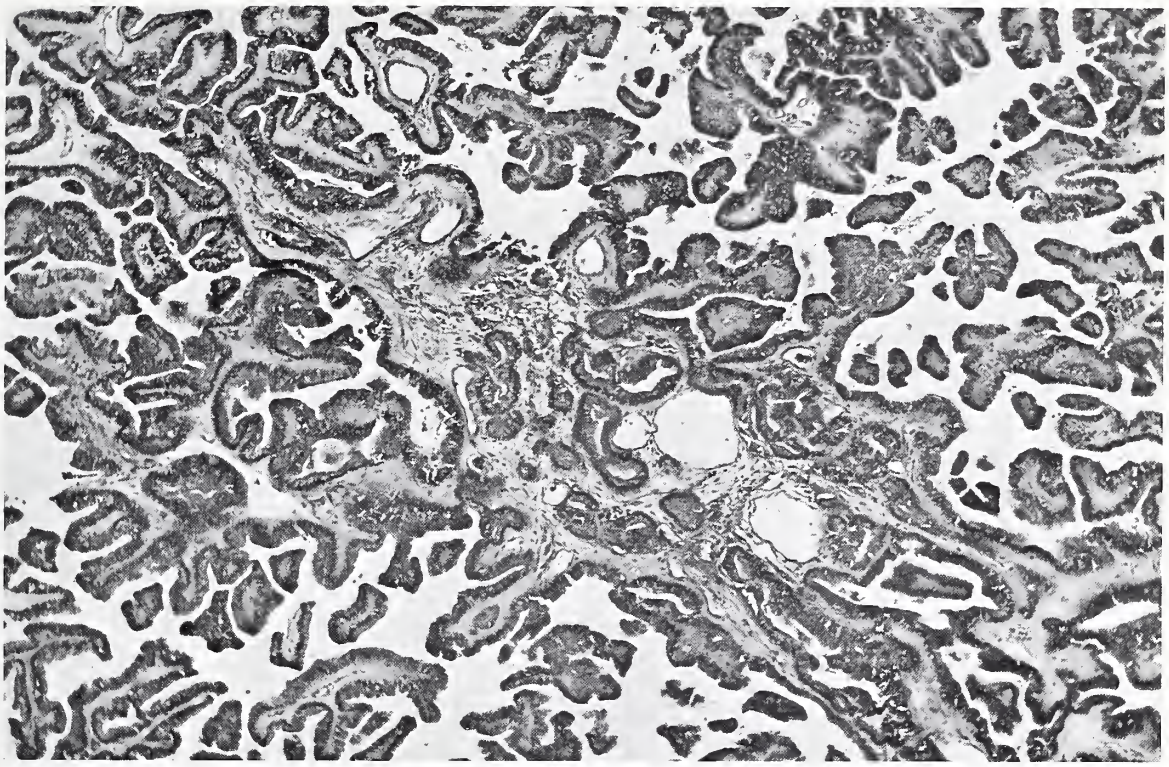

CHOROID PLEXUS PAPILLOMA

Figure 263. This typical papillary pattern of a choroid plexus papilloma shows a single layer of columnar cells resting on a scanty vascular connective tissue stroma. × 60.

VARIANT

Papillary and Acinar Mucus-Secreting Adenomas

Very occasionally mucus-secreting columnar cells containing PAS positive material may be seen in otherwise typical choroid plexus papillomas. This is not surprising since these cells are sometimes found in the normal choroid plexus epithelium. An interesting papillary multiloculated cystic tumor lined by tall columnar epithelium and filling the fourth ventricle and the lateral recess in a 68-year-old woman was described by Hoenig and associates, and its origin from the choroid plexus was demonstrated. Another exceptional example is illustrated in plate X–A and B and reported elsewhere in greater detail by Davis and Fox. This tumor was a well circumscribed gelatinous, partly cystic mass that occupied the right lateral ventricle in a 22-year-old man. It consisted entirely of a regular acinar arrangement of tall columnar and mucus-secreting cells that were intensely PAS positive and showed no cytologic malignant features. No other neoplasm was found in the rest of the body on complete postmortem examination. Figure 264 illustrates a field from the choroid plexus in this patient adjacent to the tumor area and demonstrates rows of cells along the epithelial lining similar to those found in the tumor, thus establishing the origin of the neoplasm from choroid plexus epithelium. The terms "papillary and acinar mucus-secreting adenomas" of the choroid plexus perhaps best fit these remarkable neoplasms.

MUCUS-SECRETING CELLS IN CHOROID PLEXUS

(Figure 264 and Plate X-A and B from same case)

Figure 264. A row of clear mucus-secreting cells resembling goblet cells is seen in the choroid plexus adjacent to the tumor illustrated in plate X-A and B (see text). × 280. (Courtesy of Dr. R. L. Davis, Los Angeles, Calif.; also fig. 3 from Davis, R. L., and Fox, G. E. Acinar choroid plexus adenoma. Report of a case. J. Neurosurg. 33:587–590, 1970)

MALIGNANT CHANGES. CARCINOMA OF THE CHOROID PLEXUS. Very seldom a choroid plexus papilloma shows evidence, both grossly and microscopically, of malignant change. This is manifested by invasion of the adjacent brain, loss of its differentiated papillary architecture, and the acquisition of cytologic anaplastic features. The term "carcinoma" seems therefore appropriate for this stage (Lewis). I have examined microscopically six examples found in young children, ranging from 2 to 4 years of age; one is illustrated in plate X–C.

Microscopically the tumor shows the features of a malignant neoplasm composed of solid and ill-defined papillary and tubular structures, but the general glandular arrangement is retained (fig. 265). Under high power the tumor cells show obvious anaplastic characters, such as pleomorphism,

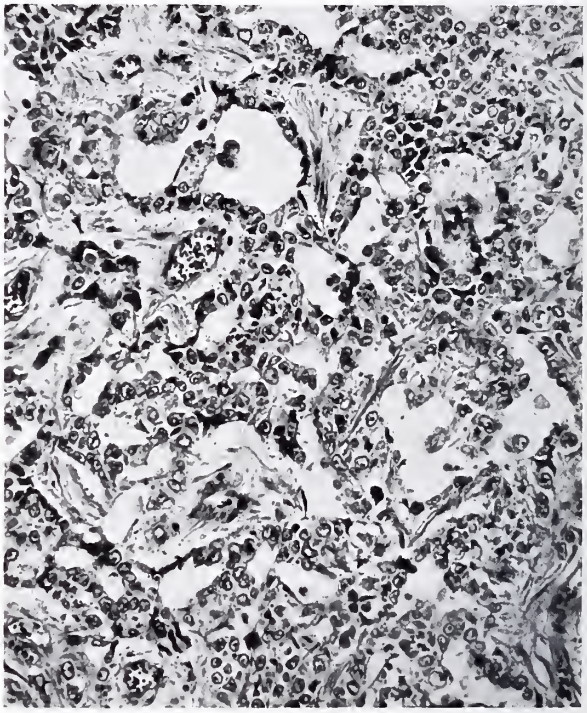

MALIGNANT CHOROID PLEXUS PAPILLOMA (CARCINOMA OF THE CHOROID PLEXUS)

(Figures 265, 266, and Plate X-C from same case)

Figure 265. This low power view shows a disorderly arrangement of pleomorphic cuboidal cells, but the papillary and tubular structure of the tumor is still recognizable. PTAH. × 145. (Fig. 25 from Rubinstein, L. J. Seminario de Neuropatologia, Mérida, Yucatán, Bol. Asoc. Mex. Patol., A. C. 7:13–59, 1969).

nuclear atypicality, hyperchromatism, multinucleation, and giant cell formation (fig. 266). Mitotic figures are often numerous and foci of necrosis may also be present.

GROWTH AND SPREAD. METASTASIS. Both gross and microscopic spread in the leptomeninges from a benign choroid plexus papilloma is not infrequently found at postmortem examination, but it is seldom of sufficient size to cause clinical symptoms. In these cases the histologic character of the distant foci remains benign.

By contrast the rare malignant examples show a marked propensity to metastasize widely throughout the cerebrospinal fluid pathways. Three of the 4 cases that I examined postmortem showed this complication, with the formation of large subarachnoid masses that compressed the brainstem.

Exceptionally a choroid plexus papilloma has metastasized outside the central nervous system. This unusual development reported by Vraa-Jensen took place four years after removal of the original papilloma, and cytologic anaplastic changes were found both in the local recurrence and in the pleural deposits.

TREATMENT. The treatment for choroid plexus papilloma is surgical excision. Postoperative radiation would seem advisable only in the rare malignant examples. Aside from the latter, little is known of the prognosis of these rare tumors. As noted, operative removal has been followed by regression of the hydrocephalus.

DIFFERENTIAL DIAGNOSIS. Normal choroid plexus with degenerative changes often appears grossly enlarged and may be erroneously diagnosed as papilloma. At times also, the fruitless operative search for a deep-seated neoplasm, especially in the region of the fourth ventricle, culminates disconcertingly in the sampling of an exiguous piece of normal choroid plexus.

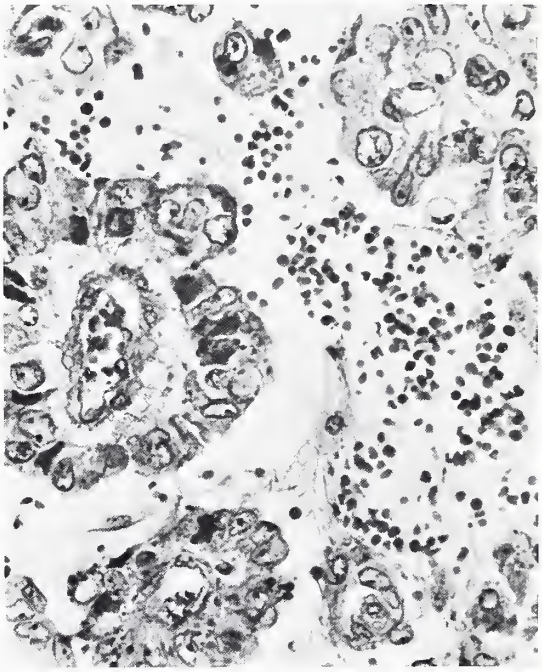

MALIGNANT CHOROID PLEXUS PAPILLOMA (CARCINOMA OF THE CHOROID PLEXUS)

(Figures 265, 266, and Plate X-C from same case)

Figure 266. The cytologic features of the tumor cells include pleomorphism with hyperchromatic nuclei and mitotic figures. PTAH. × 330. (Fig. 26 from Rubinstein, L. J. Seminario de Neuropatologia, Mérida, Yucatán, Bol. Asoc. Mex. Patol., A. C. 7:13–59, 1969).

Occasional doubt arises concerning the differential diagnosis between choroid plexus papilloma and papillary ependymoma. The former, consonant with its origin from choroid plexus epithelium, possesses a delicate vascular connective tissue stroma, and its covering consists in a single layer of columnar cells. In papillary ependymoma cells may be piled up in multiple layers and the stromal support is neuroglial. Cilia and blepharoplasts are demonstrable in ependymomas and, aside from early infantile examples, usually are not found in choroid plexus papillomas.

The diagnosis of malignant choroid plexus papilloma must be made with great circumspection on biopsy specimens, especially in adults. Although mucus-secreting cells are exceptionally encountered in genuine choroid plexus papillomas, their presence in a papillary intracerebral neoplasm in an adult is strongly in favor of a metastatic adenocarcinoma, most probably from the bronchus. The diagnosis of choroid plexus carcinoma must therefore rest on the discovery of more differentiated areas that have the classic appearances of choroid plexus papilloma.

XANTHOGRANULOMA OF THE CHOROID PLEXUS

SYNONYMS AND RELATED TERMS: Xanthoma of choroid plexus; cholesterol granuloma; cholesteatomatous endothelioma; cholesteatoma; xanthosis; cholesterinosis.

It is doubtful whether these small lesions, which are frequently found incidentally in the choroid plexuses of the lateral ventricles, should be considered true neoplasms or granulomatous proliferations in response to the deposition of cholesterol in their stroma. They may either be microscopic or present as yellowish rubbery nodular masses in the choroid plexus glomus, measuring from 1 to 2 cm. in diameter (fig. 267). They are often bilateral.

Microscopically the subepithelial portion of the choroid plexus is filled by aggregates of large pale foamy cells with small eccentric nuclei, among which empty clefts produced by acicular cholesterol crystals surrounded by foreign body giant cells may be conspicuous (fig. 268). In addition hemosiderin granules may be present, either free or in macrophages, indicative of previous bleeding. The source of the foam cells has been a matter of some controversy. Some authors believe they originate from local macrophages, and others from arachnoidal cells derived from the leptomeningeal extensions that form the stroma of the choroid plexus glomus (Ayres and Haymaker). Shuangshoti and Netsky are of the view that they arise from desquamated choroidal epithelial cells that have detached themselves from the surface and entered the stroma at sites of disruption of the epithelial basement membrane.

Fig. 267

XANTHOGRANULOMA OF CHOROID PLEXUS

Figure 267. This nodule about 1 cm. in diameter is a xanthogranuloma in the choroid plexus of the lateral ventricle. (Courtesy of Dr. M. G. Netsky, Charlottesville, Va.)

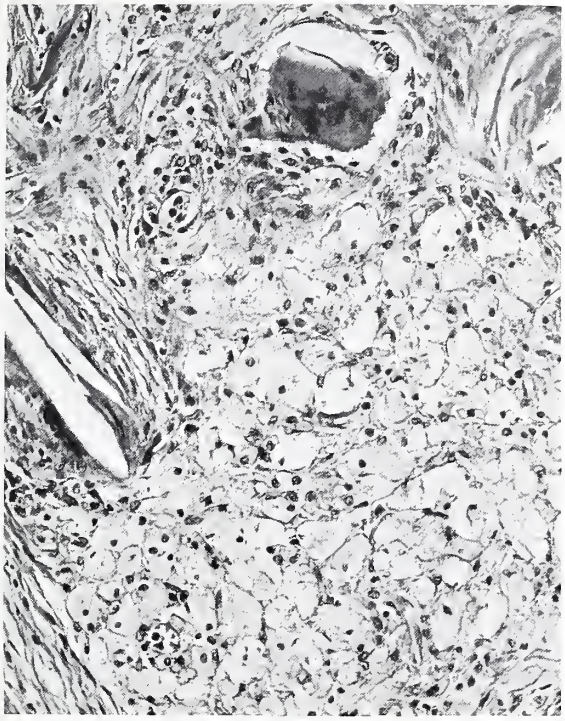

XANTHOGRANULOMA OF CHOROID PLEXUS

Figure 268. Aggregates of large foam cells are associated with empty clefts due to the presence of acicular cholesterol crystals. Note the foreign body giant cell reaction. × 165.

These small lesions are characteristically associated with hypercholesteremia and have been produced experimentally in animals given a high lipid diet.

CHOROID PLEXUS MENINGIOMA

Since the stroma of the choroid plexus originates from extensions of the pia-arachnoid into the interior of the brain that form the vela interposita, it may occasionally be the source of intraventricular meningiomas. Microscopic examination of any number of specimens of normal choroid plexus will easily demonstrate nests of arachnoidal cell in its stroma, frequently forming whorls and psammoma bodies. Progressive degenerative changes take place in this stroma with increasing age (Dunn and Kernohan). The intraventricular meningiomas may arise, therefore, either from the velum interpositum, or from the stroma itself in the region of the glomus. The lateral ventricles are the most frequent sites, the left showing a marked predominance compared to the right. The fourth and third ventricles are more exceptional sites.

These tumors are discussed in greater detail in the section on Meningiomas (p. 169; fig. 186; pl. VI–B).

COLLOID CYSTS OF THE THIRD VENTRICLE

SYNONYMS AND RELATED TERMS: Paraphyseal cysts; neuroepithelial cysts.

DEFINITION AND CYTOGENESIS. These lesions are invariably situated in the anterior part of the third ventricle and are more in the nature of a malformation than of a true neoplasm. Clinically, however, they almost always make their appearance in adult life, and by their situation produce obstruction to the flow of cerebrospinal fluid.

The source of these cysts is still a matter of considerable debate. One long entertained theory is that they originate from the paraphysis, a vestigial structure that normally develops in the embryo at the 17 to 100 mm. stage as a pouch of the telencephalon just in front of its boundary with the diencephalon (Ariëns Kappers). The paraphysis has a racemose glandular architecture with low columnar or cuboidal cells, devoid of cilia and blepharoplasts. According to Ariëns Kappers, very few colloid cysts actually arise from the paraphysis. Most are regarded by him as originating from ependymal pouches from the diencephalon. An alternative site of origin is the epithelium of the choroid plexus (Shuangshoti et al.). These workers consider

the paraphysis as essentially an extraventricular choroid plexus derived from the primitive neuroepithelium of the diencephalic roof. Microscopic examination of the cells lining colloid cysts does not help to resolve the issue, since some resemble those that cover the choroid plexus, while others appear ependymal. Electron microscopic examination of one case has supported the latter view, with the demonstration of numerous cilia, some of them abnormal (Coxe and Luse).

SITE, INCIDENCE, AND CLINICAL DATA. As already indicated these tumors arise exclusively in the third ventricle; those reported from other locations are open to question. They are rare. Although congenital they almost always cause symptoms in adult life only, when they give rise to characteristic sudden episodes of excruciating headache, sometimes associated with changes in the position of the head. The symptoms are attributed to bursts of obstructive hydrocephalus produced by the sudden blocking of one of the foramina of Monro by the mobile pendulous cyst. In some cases small and symptomless cysts are found incidentally postmortem in adults. Males and females are equally affected.

GROSS. The tumor usually forms a thin-walled, pendulous spherical cyst that may be attached to the anterior extremity of the velum interpositum or to the choroid plexus of the third ventricle. Frequently it may be tethered to the adjacent brain, that is, the edges of the foramina of Monro, the pillars of the fornix, or the septum pellucidum (fig. 269). Occasionally it may be large enough to become adherent to the lateral wall of the third ventricle. Rarely more than one cyst is present and the gross appearance resembles a bunch of grapes.

The cysts vary in size from less than 1 cm. to 3 to 4 cm. in diameter. The wall forms a thin membrane that encloses gelatinous or denser hyaline material with the consistency of soft cartilage.

MICROSCOPIC. The cyst wall consists of an epithelial layer of cells resting upon a collagenous capsule of variable vascularity. The lining of the cyst varies from case to case, and also in different parts of the same specimen. In some areas it may be absent due to destruction. The cells are mostly cuboidal or low columnar,

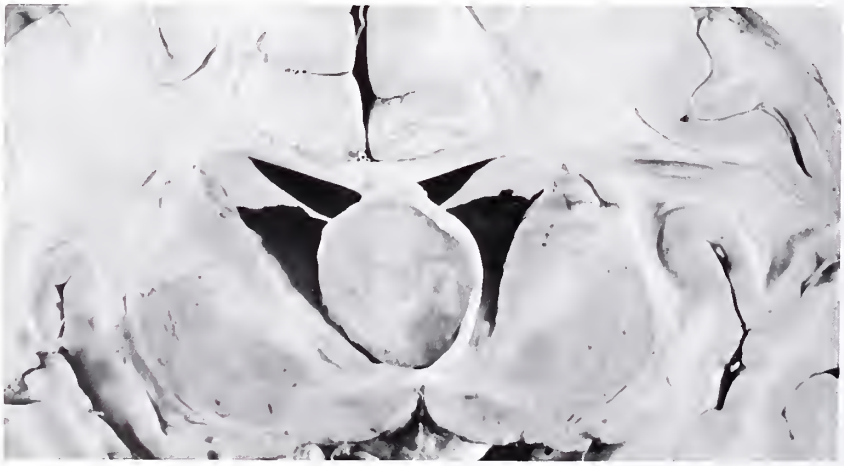

NEUROEPITHELIAL (COLLOID) CYST

Figure 269. A large neuroepithelial cyst was found in the anterior part of the third ventricle, displacing the septum pellucidum to the left. (Courtesy of the Armed Forces Institute of Pathology).

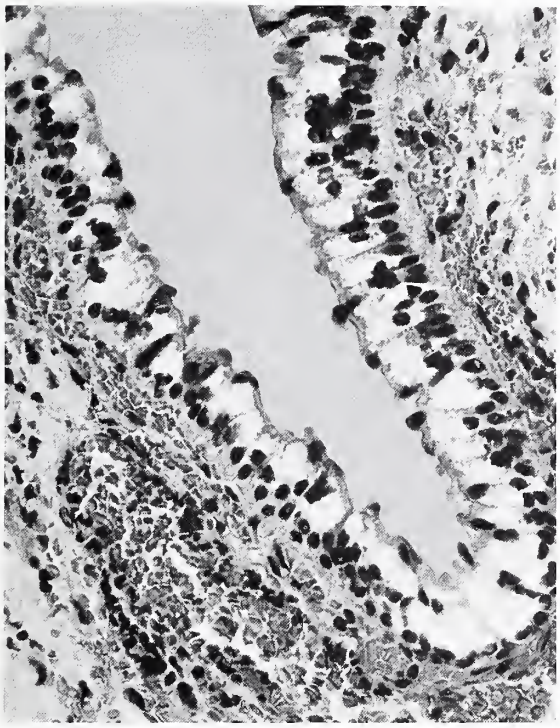

NEUROEPITHELIAL (COLLOID) CYST

Figure 270. This is the microscopic appearance of the lining of a colloid cyst of the third ventricle. Tall ciliated columnar epithelium rests upon a delicate vascular collagenous capsule. × 300.

occasionally high columnar, and cilia may be demonstrated (fig. 270). Mucus goblet cells are commonly present, and a positive reaction for mucin is often obtained with mucicarmine and with PAS. The contents of the cyst are formed by amorphous PAS positive debris.

Occasionally the epithelium is not ciliated and more complex, being composed of several cell layers including tubular formations; it is possible these represent cysts that are truly derived from the paraphysis (Ariëns Kappers).

TREATMENT AND PROGNOSIS. These structures are entirely benign histologically, and their excision results in an excellent prognosis. However, difficulties may sometimes be encountered at operation with large cysts that have become secondarily attached to neighboring structures.

References

Ariëns Kappers, J. A. The development of the paraphysis cerebri in man with comments on its relationship to the intercolumnar tubercle and its significance for the origin of cystic tumors in the third ventricle. J. Comp. Neurol. 102:425–509, 1955.

Ayres, W. W., and Haymaker, W. Xanthoma and cholesterol granuloma of the choroid plexus. Report of the pathological aspects in 29 cases. J. Neuropath. Exp. Neurol. 19:280–295, 1960.

Coxe, W. S., and Luse, S. A. Colloid cyst of third ventricle. An electron microscopic study. J. Neuropath. Exp. Neurol. 23:431–445, 1964.

Davis, R. L., and Fox, G. E. Acinar choroid plexus adenoma. Report of a case. J. Neurosurg. 33:587–590, 1970.

Dunn, J., Jr., and Kernohan, J. W. Histologic changes within the choroid plexus of the lateral ventricle: their relation to age. Mayo Clin. Proc. 30:607–616, 1955.

Hoenig, E. M., Ghatak, N. R., Hirano, A., and Zimmerman, H. M. Multiloculated cystic tumor of the choroid plexus of the fourth ventricle. Case report. J. Neurosurg. 27:574–579, 1967.

Lewis, P. Carcinoma of the choroid plexus. Brain 90: 177–186, 1967.

Matson, D. D. Hydrocephalus in a premature infant caused by papilloma of the choroid plexus, with report of surgical treatment. J. Neurosurg. 10:416–420, 1953.

Ray, B. S., and Peck, F. C., Jr. Papilloma of choroid plexus of lateral ventricles causing hydrocephalus in infant. J. Neurosurg. 13:405–412, 1956.

Shuangshoti, S., and Netsky, M. G. Xanthogranuloma (xanthoma) of choroid plexus. The origin of foamy (xanthoma) cells. Amer. J. Path. 48:503–533, 1966.

———, Roberts, M. P., and Netsky, M. G. Neuroepithelial (colloid) cysts. Arch. Path. 80:214–224, 1965.

Smith, J. F. Hydrocephalus associated with choroid plexus papillomas. J. Neuropath. Exp. Neurol. 14:442–449, 1955.

Vraa-Jensen, G. Papilloma of choroid plexus with pulmonary metastases. Acta Psychiat. Scand. 25:299–306, 1950.

PLATE X

MUCUS-SECRETING CHOROID PLEXUS TUMOR (ACINAR CHOROID PLEXUS ADENOMA)

(Plate X-A and B and Figure 264 from same case)

A. This section is from a well encapsulated lobulated intraventricular tumor in the right lateral ventricle of a 22-year-old man. The pattern is that of irregular acinar formations composed of small columnar cells reminiscent of a salivary gland tumor. The epithelium of the choroid plexus adjacent to the tumor contained several cells with identical cytologic appearances. This remarkable tumor is therefore regarded as having arisen from mucus-secreting elements in the normal choroid plexus. H & E. × 165. (Courtesy of Dr. R. L. Davis, Los Angeles, Calif.)

B. The intense PAS positive reaction in many of the epithelial cells is well shown in this field. PAS. × 165.

MALIGNANT CHOROID PLEXUS PAPILLOMA

(Plate X-C and Figures 265 and 266 from same case)

C. Massive, partly hemorrhagic tumor distends the right lateral ventricle in a 3-year-old girl. Extensive distant dissemination had taken place in the cerebrospinal leptomeninges. The histologic appearance of the tumor was highly malignant and reminiscent of a papillary and tubular adenocarcinoma. (Courtesy of Dr. J. E. Olvera-Rabiela, Mexico City, Mexico; also fig. 24 from Rubinstein, L. J. Seminario de Neuropatologia, Mérida, Yucatán, Bol. Asoc. Mex. Patol., A. C. 7:13–59, 1969).

SPINAL ENTEROGENOUS CYST

D. This area is from the wall of a loculated intraspinal extramedullary cyst lying to the right and anterior to the cord at the level of the fourth to the sixth cervical segments. This 21-year-old man had a history of pain in the right shoulder and loss of fine movements in the right arm of five months duration. The cyst wall is lined by tall columnar, nonciliated epithelium containing mucus, resembling intestinal epithelium. PAS. × 100.

PINEAL TERATOMA

E. This is a closeup view of a teratoma arising in the pineal region in a 20-year-old man with a 4-year history of seizures. Microscopically this tumor contained various well differentiated elements from several germ layers and included squamous epithelial and glandular elements.

CRANIOPHARYNGIOMA

(Plate X-F and Figure 311 from same case)

F. This large, partly solid, partly cystic craniopharyngioma occupied the third ventricle in a 53-year-old man. (Fig. 5 from Belza, J. Double midline intracranial tumors of vestigial origin: contiguous intrasellar chordoma and suprasellar craniopharyngioma. J. Neurosurg. 25:199–204, 1966).

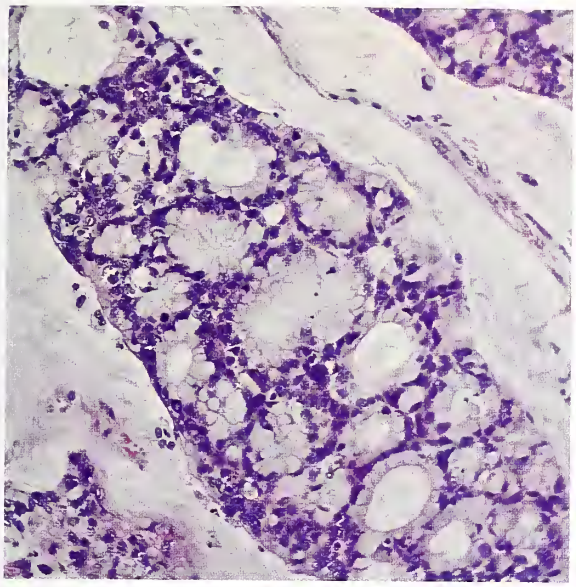

A

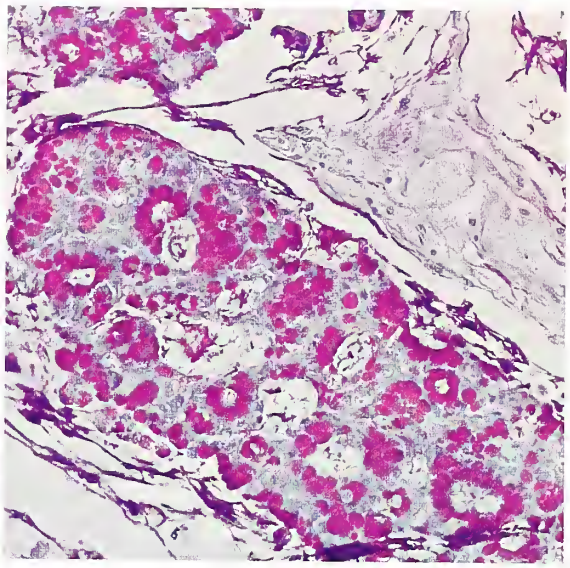

B

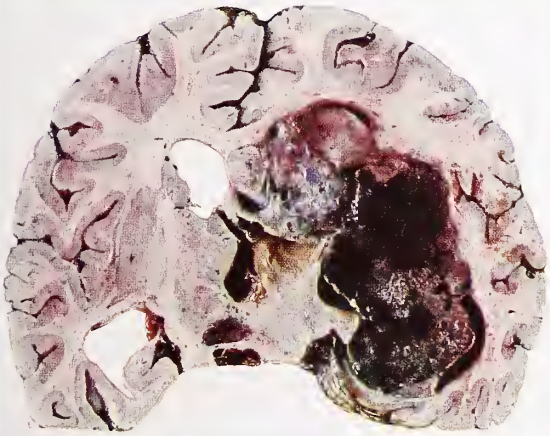

C

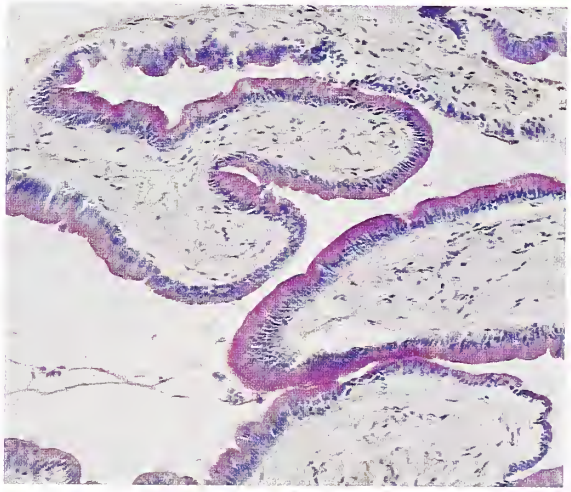

D

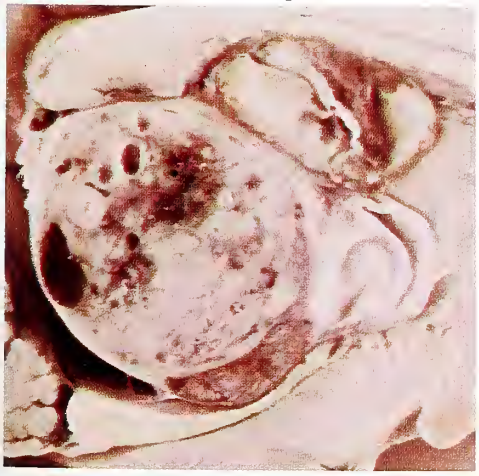

E

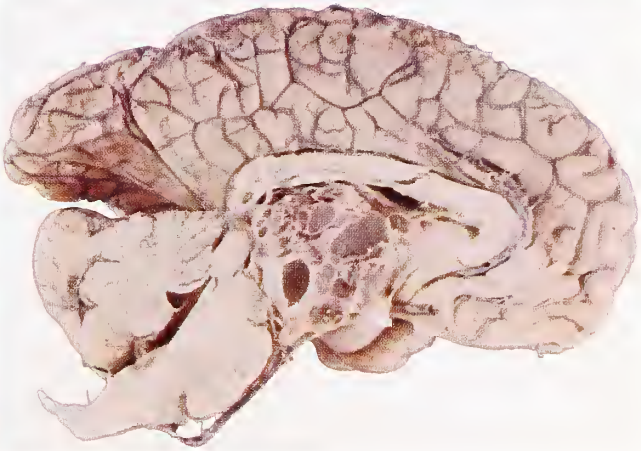

F

PLATE X

TUMORS OF THE PINEAL REGION

TUMORS OF GERM CELL ORIGIN (INCLUDING THOSE ARISING IN THE SUPRASELLAR REGION)

GERMINOMA

SYNONYMS AND RELATED TERMS: Atypical pineal teratoma; pinealoma.

DEFINITION, CYTOGENESIS, AND NOMENCLATURE. The definition and taxonomy of this tumor have had a long and confused history. The term **pinealoma,** originally coined by Krabbe, has long been applied to this neoplasm, partly on the basis of its alleged resemblance to the pattern of the fetal pineal body (Globus and Silbert). Its morphologic similarity to the testicular seminoma was first pointed out by Dorothy Russell in a report for a case published by Harris and Cairns. Its interpretation as an **atypical form of teratoma** was subsequently proposed by Russell (1944) on the following grounds: the frequent inclusion of other tissue elements in this tumor, giving it a teratoid character; the observation of germinomatous areas in otherwise typical teratomas; and the negative results with silver impregnation of the tumor cells by methods specific for pineal parenchymal elements. These arguments apply equally to the so-called "ectopic pinealoma" (Russell, 1954), designated below as a suprasellar germinoma. The teratoid nature of this tumor has now received wide acceptance. The term **germinoma,** originally introduced by Friedman, appears to be gaining ground and has much to recommend it. It is short, descriptive, and harmonious. It clearly separates this group of neoplasms from those which arise from pineal parenchymal cells and brings it into line with its analogues originating in the gonads. It can be suitably qualified according to the location of the tumor, such as pineal, suprasellar, intrasellar, mediastinal, retroperitoneal, testicular, and ovarian germinomas.

The source of this tumor is ascribed to primitive germ cells, which are said to migrate over wide areas of the embryo during early fetal life. Very occasionally such cells have been observed within the developing brain of the embryo. However, the almost exclusively midline origin of ectopic germinal tumors remains unexplained.

INCIDENCE AND SITES OF ORIGIN. MULTIFOCALITY. The germinomas are the most common form of growth in the region of the pineal body, accounting for over 50 percent of all neoplasms in this area. The pineal is also the most frequent site of intracranial germinomas, but occasionally they may be parapineal and the adjacent pineal body may be intact, although compressed. A sizable group arise in the midline hypothalamic region and are frequently designated as "ectopic pinealomas," but the term **suprasellar germinoma** (Simson et al.), in keeping with the current concept referred to above, will henceforth be used. To avoid repetition it is proposed to deal in this section with the suprasellar as well as the pineal germinomas, since both tumors share many common clinical and pathologic features and since difficulty is sometimes encountered at necropsy in ascribing a definite site of origin to these midline neoplasms.

The great majority of germinomas appear in the second and third decades of life, the peak of incidence occurring in the latter half of the second decade (Dayan et al.). The pineal examples show an overwhelming preponderance of males over females. There is a somewhat lesser preponderance of males in those originating in the suprasellar region.

Aside from the now well established association of typical teratoma and germinoma that has been shown to occur in both the pineal and the suprasellar examples (Russell and Rubinstein; Dayan et al.), the precise locus of origin of these tumors may be difficult to establish at the time of postmortem examination, as illustrated in figures 272 and 273. This man had a pineal germinoma verified histologically three years before the development of a large suprasellar and intrasellar tumor that filled the third ventricle and included both typical teratomatous and germinomatous elements. Evidence as to its site of origin is therefore only inferential. Similar interpretative problems are encountered in the following cases: a large intraventricular teratoma that was thought to arise from the pineal and was associated with independent foci of germinoma which infiltrated the infundibulum and optic chiasm (James and Dudley); and a large pituitary teratoma with choriocarcinomatous elements, associated with separate foci of germinoma infiltrating the pituitary stalk and tuber cinereum (Kageyama and Belsky, Case 4); similar cells were found on microscopic examination of the pineal body, which appeared grossly normal. These remarks should be viewed in the context of the observation that the majority of germinomas of the pineal region that come to necropsy cannot be shown to have originated in the pineal or in its immediate vicinity. In 60 percent of the cases reviewed by Dayan and his associates, spread had taken place along the anterior part of the third ventricle and its walls; metastatic dissemination from a primary tumor in the pineal is clearly the most likely explanation in these cases (fig. 271). As noted by Dayan and associates, it is not always stated whether this extension was in continuity or by metastasis, but both modes have been described. However, metastatic spread from a small pineal primary tumor has been excluded in a few examples in which the pineal was examined by serial sections (Løken; Dayan et al., Case 1). The possibility therefore of **multifocality** in intracranial germinomas and teratomas cannot be dismissed. Furthermore the association of a hypothalamic germinoma with a malignant teratoma of the anterior mediastinum has been reported (Dayan et al.), as well as the simultaneous presence of an "ectopic pinealoma" and a small dermoid cyst in the pineal (Russell, 1954). I have examined the case of a 16-year-old boy with Klinefelter syndrome who, three years after the removal of a typical teratoma from the pineal region, presented with a dermoid cyst in the testis and an independent malignant choriocarcinoma of the anterior mediastinum that metastasized widely.

CLINICAL EFFECTS. The clinical presentation often provides little help in elucidating the site of origin of germinomas, or their nature. It may be that of a mass in the pineal region with a characteristic visual symptomatology (Parinaud's syndrome), but frequently the symptoms are also indicative of hypothalamic involvement, such as diabetes insipidus, emaciation, or pubertas praecox. In some cases (fig. 271) this is presumably due to metastatic encroachment

by tumor on the hypothalamic region, but it has long been thought that **pubertas praecox** was particularly associated with this form of neoplasm. It has been argued that destruction of the normal pineal tissue might remove the inhibitory effect of the gland, now believed to contain melatonin, which exerts an inhibitory effect on sexual development. However, pubertas praecox has been especially associated with teratomas, and not specifically with neoplasms arising from pineal parenchymal cells. Moreover in many cases it is also linked with pathologic lesions arising primarily in the hypothalamic region. This suggests that the disturbance may be of purely mechanical origin, but the problem is far from resolved: the characteristic age and sex incidence of germinomas, their preponderance soon after the onset of puberty, and the recent claims that both melatonin and its synthesizing enzyme, hydroxyindole-O-methyl transferase (HIOMT), have been isolated from germinomas ("pinealomas") require further elucidation (Wurtman and Kammer).

GROSS. In the small examples the tumor may appear well defined and restricted to the pineal (fig. 271). The cut surface is usually soft, friable, grayish or grayish red, with a granular consistency and a somewhat opalescent appearance. Usually by the time the case comes to necropsy the neoplasm is no longer localized to the pineal, and there is extensive infiltration of the adjacent structures, especially the corpora quadrigemina and the walls of the third ventricle.

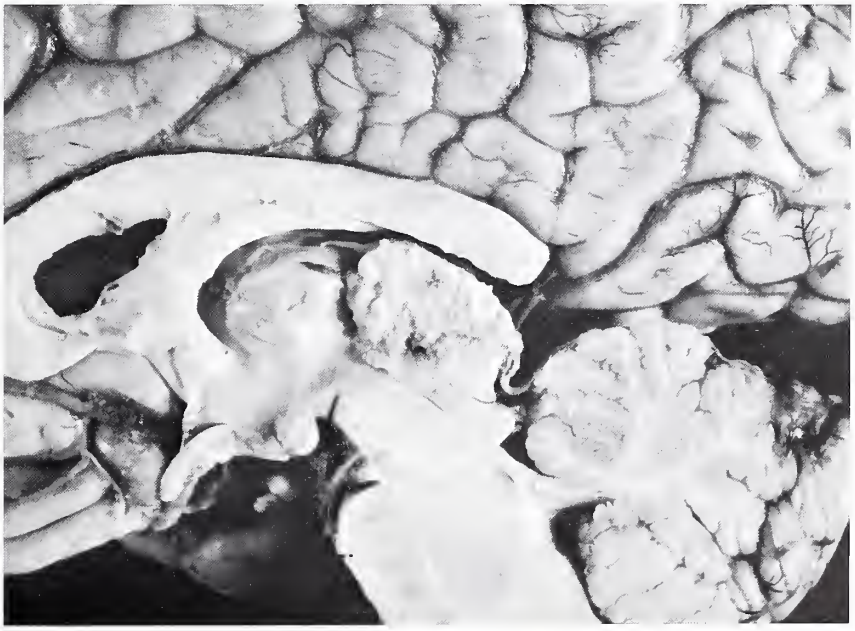

PINEAL GERMINOMA

Figure 271. Midsagittal section of a brain shows replacement of the pineal body by a homogeneous granular tumor. This 21-year-old man had a history of polydypsia and polyuria of 10 months duration. At postmortem examination there was extensive infiltration of the floor of the third ventricle, hypothalamus, and pituitary fossa with encroachment onto the adjacent cranial nerves. Microscopically both the tumor occupying the pineal region and the suprasellar neoplastic tissue consisted of typical germinoma. This case is regarded as a primary pineal germinoma with metastatic involvement of the suprasellar region. (Courtesy of the Armed Forces Institute of Pathology).

The suprasellar tumors present as round or lobulated masses projecting from the floor of the third ventricle, compressing the optic chiasm and surrounding the pituitary stalk (fig. 272). They may extend upward to fill the third ventricle and compress the adjacent basal ganglia (fig. 273). In some cases there is marked diffuse infiltration of the lamina terminalis, the optic chiasm, and the adjacent hypothalamic structures, which are grossly thickened and homogeneous; the appearances may mimic an infiltrating glioma.

Occasionally the tumor extends in continuity into the sella turcica, which may become markedly expanded. These cases may present with the clinical picture of hypopituitarism, and have been termed "intrasellar germinomas" (Ghatak et al.).

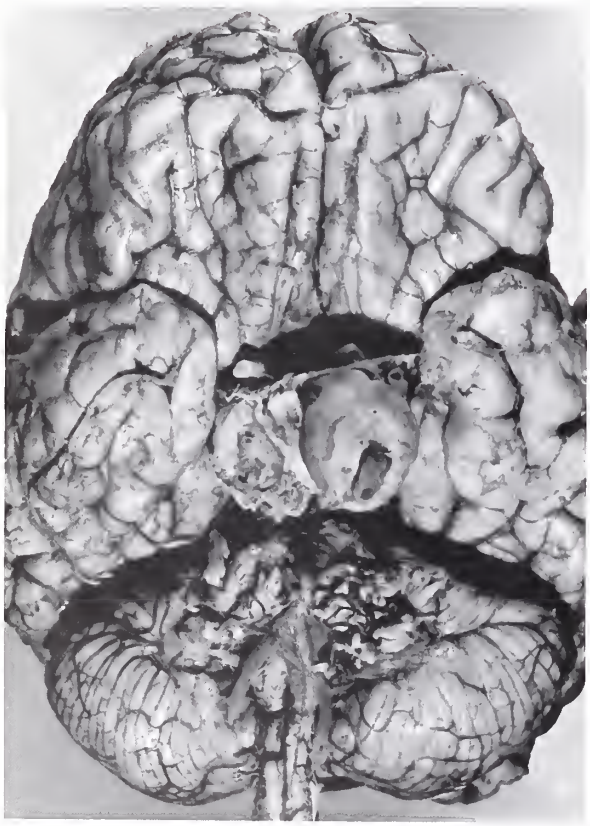

Fig. 272

MICROSCOPIC. The histologic picture is highly distinctive; the tumor is composed of two clearly distinguishable cell types: large polygonal or spheroidal cells with well defined cell membranes, a pale eosinophilic or rather clear cytoplasm, and conspicuous central spherical nuclei with a pale vesiculated nucleoplasm and large nucleoli; and groups of small darkly staining cells presumably lymphocytes, usually distributed along the vascular connective tissue stroma of the tumor (fig. 274). No transitional forms are seen between these two cell types. Mitotic figures are frequently found in the larger cells. They do not resemble neuroglial elements, and react negatively with silver impregnations specific for pineal parenchymal cells.

MIXED PINEAL AND SUPRASELLAR GERMINOMA AND TERATOMA

(Figures 272 and 273 from same case)

Figure 272. This is the ventral view of a large suprasellar tumor which invaded the pituitary fossa, broke into its floor, and invaded the cavernous sinuses. The tumor occupies the interpeduncular fossa, forming a pendulous mass that incorporates the tuber cinereum. The proximal portion of the pituitary stalk is seen in the middle of this mass.

This tumor was found in a 22-year-old man who was admitted three years previously with a history of diplopia and polyuria. A ventriculogram demonstrated a tumor in the pineal region. This was biopsied and histologically verified as an atypical teratoma (germinoma). A Torkildsen operation was performed, and diabetes insipidus developed, which later subsided. Three years later he presented with bitemporal hemianopsia and lethargy, and a large suprasellar prechiasmatic tumor was found that also filled the third ventricle (fig. 273). No definite pineal tissue was identified. Microscopically the neoplasm was a typical teratoma with areas of cartilage and of glandular and tubular epithelium composed of tall columnar cells; foci of germinomatous tissue identical with the original biopsy were also present. (Courtesy of Dr. K. M. Earle, Washington, D. C.)

MIXED PINEAL AND SUPRASELLAR GERMINOMA AND TERATOMA

(Figures 272 and 273 from same case)

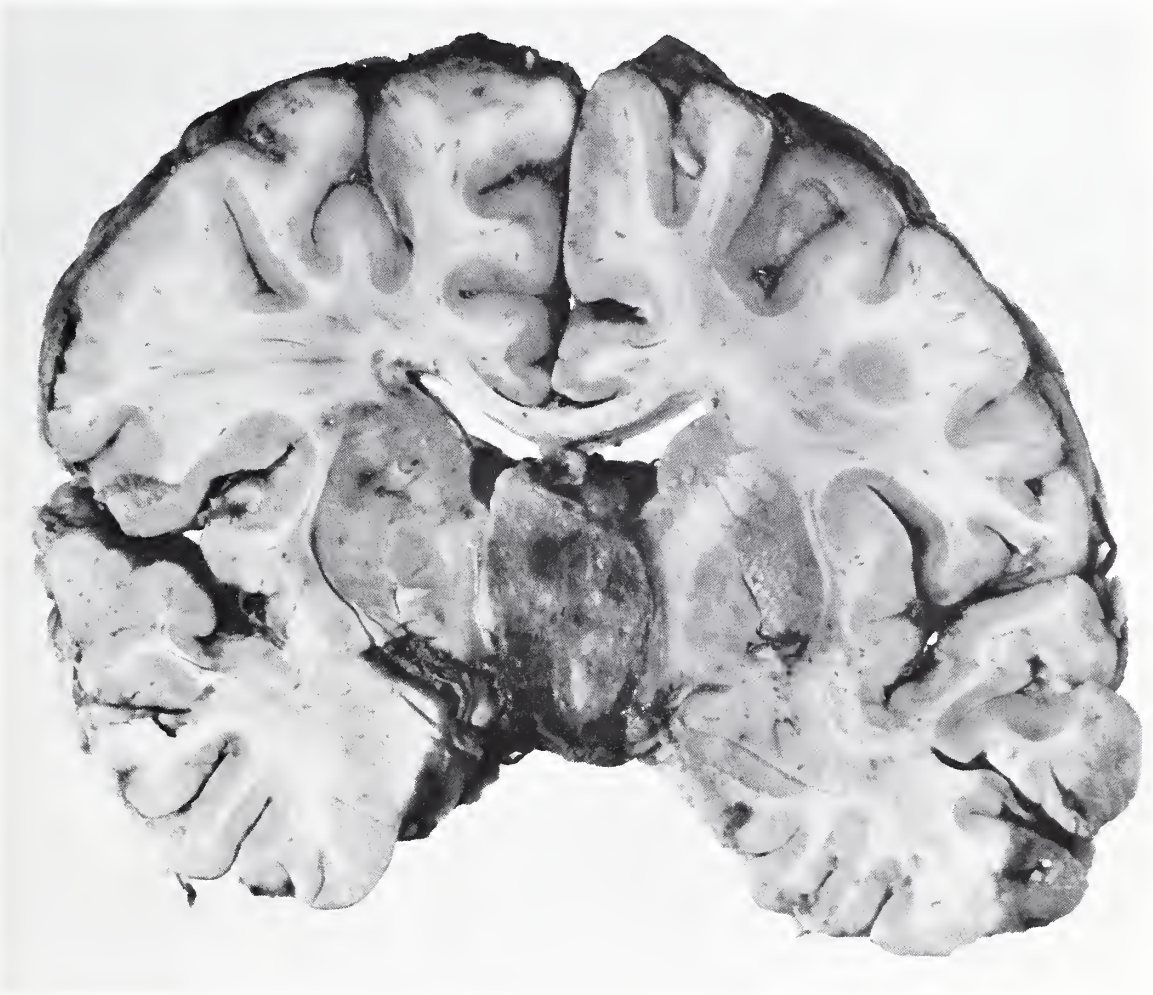

Figure 273. This coronal section of brain shows massive suprasellar tumor occupying the third ventricle. Note that the tumor appears to extend up to the epithalamic region. It is reasonable to assume that it may have originated from the pineal, but the evidence is inferential only (see legend for fig. 272). (Courtesy of Dr. K. M. Earle, Washington, D. C.)

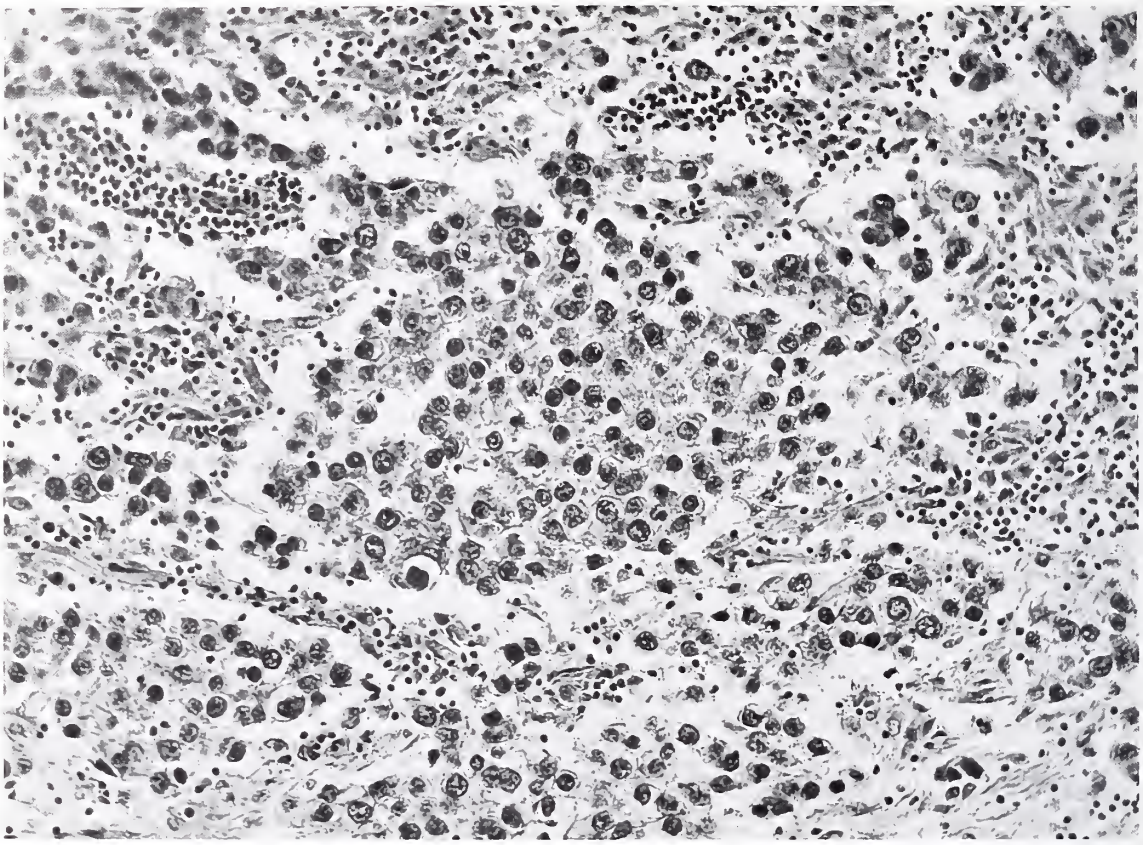

GERMINOMA

Figure 274. Typical microscopic appearance of a germinoma infiltrating the hypothalamic region of a 19-year-old man with a 4-year history of diabetes insipidus, followed one year later by panhypopituitarism. The tumor consists of two distinct cell types: large spheroidal cells with central and vesiculated nuclei and occasional prominent nucleoli resembling those of the testicular seminoma and ovarian dysgerminoma, and lymphocytes. No transitional forms are seen between the two cell types. × 200.

In a high percentage of cases further areas reveal other tissue elements that are clearly indicative of their teratomatous character: they include glandular foci composed of cuboidal or columnar epithelium, mucus-secreting cells, smooth muscle fibers, and occasionally islands of squamous epithelium, cartilage, and areas suggesting trophoblastic elements.

Another feature of these tumors, especially those arising in the hypothalamic region, is the marked hyperplastic neuroglial reaction that may surround the advancing tumor, as well as the conspicuous microglial proliferation that sometimes accompanies it. In addition some cases show a conspicuous granulomatous reaction that includes multinucleated giant cells mixed with an infiltrate of lymphocytes, plasma cells, histiocytes, and epithelioid cells, analogous to the granulomatous reaction found in testicular seminomas and ovarian dysgerminomas. It has been suggested that these may possibly represent an immunologic reaction specific to this group of tumors (Marshall and Dayan).

Electron microscopic examination of one case has shown that the tumor elements bear no resemblance to epithelial, ependymal, or pineal parenchymal cells (Ramsey). The fine structural features of the pineal germinoma are similar to those of the testicular seminoma (Pierce).

GROWTH AND SPREAD. Germinomas are histologically malignant and infiltrative. Spread is especially likely to occur along the floor and walls of the third ventricle. Extensive deposits may line the remainder of the ventricular system and occupy the spinal leptomeninges (Dayan et al.). Local extension into the extradural lumbar fat and adjacent bone has also been reported by these workers. Distant metastatic spread to the lungs following craniotomy has been recorded in two cases, in one of which the tumor had invaded the straight sinus (Tompkins et al.).

TREATMENT. These tumors are generally regarded as highly radiosensitive, and arrest of the growth for several years has been reported following deep x-ray therapy or the insertion of radioactive gold seeds (Rubin and Kramer; Dayan et al.). In this respect too it resembles the testicular seminoma. However, the diagnosis of tumors in the pineal region is often uncertain because of the absence of histologic verification. Consequently a precise assessment of their radiosensitivity is difficult to obtain on clinical grounds alone. The consensus of opinion is that the best treatment for brain tumors with the presumptive diagnosis of "pinealoma" is radiotherapy after a shunting procedure (Schulz et al.).

PROGNOSIS. It would appear that the prognosis for pineal germinomas may resemble that for the testicular seminoma, that is, a histologically malignant but radiosensitive tumor that in a number of cases may have a more benign clinical course than its microscopic appearance would foretell. A number of patients are apparently alive and well several years after the original diagnosis has been established histologically. However, as with the testicular seminomas, the pathologic picture presented at autopsy is often the terminal one of a highly malignant and widely spreading neoplasm.

DIFFERENTIAL DIAGNOSIS. The most important differential diagnosis, applicable to the suprasellar germinomas in particular, is that of a lymphomatous proliferation of the reticulum cell sarcoma-microglioma group, since the latter often selectively involves the hypothalamus and the neurohypophysis. The large cells with clear vesiculated nuclei and prominent nucleoli and the adjacent masses of lymphocytes of the germinoma may mimic the picture of a reticulum cell sarcoma or microglioma. Silver impregnation for microglia may help in establishing the latter diagnosis, but even then a careful examination is necessary to arrive at a definite conclusion since germinomas are sometimes accompanied by a conspicuous granulomatous reaction in which microglia may actively participate.

TERATOMAS

The pineal region is the most common site of intracranial teratomas (Soas). Like the germinomas they may be situated in a parapineal location (Walton) and, again by analogy with the hypothalamic germinomas, another frequent intracranial site is the suprasellar region.

INCIDENCE AND CLINICAL EFFECTS. The incidence of teratomas is very similar to that of germinomas; they are almost entirely confined to males and are usually identified in the first two decades of life.

The peak of incidence is in the second decade. Aside from signs indicative of a midline space-replacing lesion occupying the third ventricle and the region of the pineal, hypothalamic symptoms such as pubertas praecox, diabetes insipidus, and obesity have been especially associated with this form of neoplasm.

GROSS. The tumor is well defined with a rounded or irregular lobulated outline. The cut surface is often variegated and may show solid opaque whitish or yellowish areas with adjacent foci of hemorrhage (pl. X–E). Dark brown cystic areas and recognizable teratomatous elements such as cartilage, bone, and hair are often seen. In these tumors, in contradistinction to the other forms of teratomatous neoplasms in this group, invasive features are not present.

MICROSCOPIC. The microscopic picture is similar to that of well differentiated teratomas elsewhere in the body with a wide range in microscopic appearances, depending on the types of tissue elements derived from the three germinative layers. Foci of squamous epithelium, cartilage, and glandular elements composed of tall columnar mucus-secreting cells are often found. Occasionally neuroectodermal tissue may be found, including areas containing ganglion cells, choroid plexus epithelium, and more primitive elements suggesting primitive medullary epithelium (Zeitlin, Case 1). Not infrequently typical teratomas have been found to contain areas with the classic microscopic features of germinoma.

CHORIOCARCINOMA

SYNONYMS AND RELATED TERMS: Chorioepithelioma.

One rare but well known form of teratoma arising in the pineal region has the microscopic features of a choriocarcinoma. These tumors are notoriously malignant and invade the adjacent structures. The development of extracranial metastases, especially in the lungs, has been reported, in particular by Stowell and his associates, in whose case the tumor was found to invade the superior longitudinal sinus. Other more briefly recorded examples include one by Nishiyama and associates, and a tumor arising in the pituitary region reported by Kageyama and Belsky.

EMBRYONAL CARCINOMA

SYNONYMS AND RELATED TERMS: Endodermal sinus tumor (Teilum); teratocarcinoma(?).

Another rare variant of teratoid tumor has been reported independently by Borit and by Bestle. These neoplasms essentially resemble the embryonal carcinoma found in the testis, and display a number of histologic features that mimic different stages of embryonic development (figs. 275, 276). Borit's case included layers of cuboidal cells resembling the visceral yolk sac (fig. 275), foci of tall vacuolated columnar cells forming glandlike structures (fig. 276), embryoid bodies mimicking the primitive ectoderm merging with the amnion, areas resembling immature placental villi, and a few Schiller-Duval bodies similar to those found in the germ cell tumors originating in the testis and ovary. The latter features were particularly emphasized by Bestle, whose second case incorporated a typical dermoid cyst separated from the main tumor mass. Two of the three tumors reported were invasive and malignant, one of them metastasizing widely through the spinal leptomeninges. It is possible that some of the malignant pineal teratoid tumors designated in the past as "teratocarcinomas" belong to this group, but their documentation is too inadequate to be assured of this. More recently, Jellinger and colleagues described another case, in which an embryonal carcinoma included areas with the histologic features of germinoma.

The definitive taxonomy of pineal tumors of germ cell origin still remains *sub judice*. Whereas considerable progress has been made in the formulation of a more correct classification of testicular neoplasms since World War II, when an extensive material could be scrutinized by a small group of investigators, tumors of the pineal region are too infrequent for anyone to be able to accumulate a large personal experience. A classification that would correspond more exactly to the concepts developed from the study of testicular neoplasms must therefore await more comprehensive analysis.

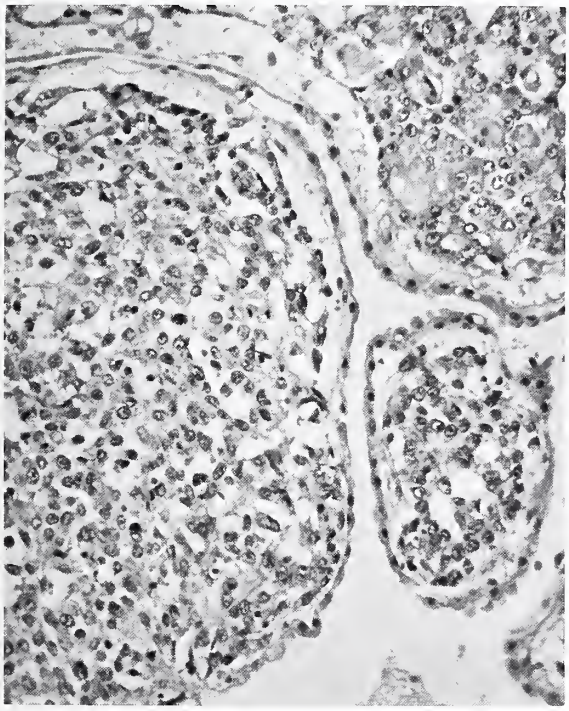

EMBRYONAL CARCINOMA OF THE PINEAL

(Figures 275 and 276 from same case)

Figure 275. This section is from a malignant, widely metastasizing tumor arising in the pineal region of a 16-year-old boy. An outer layer of cuboidal cells resembling the visceral yolk sac encloses solid sheets of embryonal carcinoma cells. × 128. (Fig. 4 from Borit, A. Embryonal carcinoma of the pineal region. J. Path. 97:165–168, 1969).

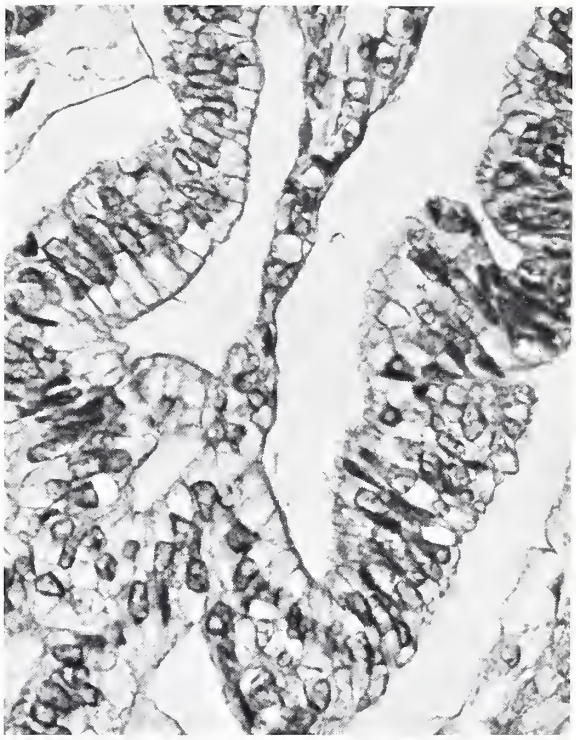

EMBRYONAL CARCINOMA OF THE PINEAL

(Figures 275 and 276 from same case)

Figure 276. Tall vacuolated columnar cells form gland-like structures. × 280. (Fig. 6 from Borit, A. Embryonal carcinoma of the pineal region. J. Path. 97:165–168, 1969).

TUMORS OF THE PINEAL PARENCHYMA

DEFINITION, CYTOGENESIS, AND NOMENCLATURE. NORMAL PINEAL GLAND. Tumors arising from pineal parenchymal cells are considerably less common than the germinomas and teratomas originating in the pineal region, described previously. Pineal parenchymal cells are elements of a specific type, neither neuronal nor neuroglial. According to Rio-Hortega they possess cytoplasmic granules which to him were suggestive of secretory activity, but from recent electron microscopic observations it is uncertain whether the osmiophilic granular inclusions seen in

these cells are secretory vesicles or related to the lysosome system (Wurtman et al.). While the pineal parenchymal cells to some extent may be considered the cytogenic equivalents of nerve cells in the brain, they do not possess axons, nor can they be regarded as neurocytes in an arrested stage of evolution. They are characterized by single and branching cytoplasmic argyrophilic processes with typical club-shaped expansions that closely surround the interlobular blood vessels. Rio-Hortega regarded pineal parenchymal cells as falling within a group of amacrine nerve cells, i.e., modified nerve cells without long processes, and the pineal body as an endocrine gland. This view has been given fresh impetus in recent years with the observation that it is rich in serotonin and other monoamines, including melatonin, and contains the enzyme responsible for the synthesis of melatonin, hydroxyindole-O-methyl transferase. Typical ganglion cells are not found in the pineal body, but it is penetrated by a rich plexus of nerve fibers that are generally accepted to be of sympathetic origin, and arise in the superior cervical ganglia. Recent work has shown that the sympathetic plexuses are adrenergic. There is therefore mounting evidence in support of the old belief that, whereas in lower vertebrates the pineal body acts as a photoreceptor organ, in mammals it exerts a secretory function (Ariëns Kappers), as has long been suggested by its histologic architecture (fig. 277). A morphologic affinity between the pineal and organs of the chemoreceptor system has also been proposed (Smith et al.).

The term "pinealoma" would therefore, strictly speaking, be appropriate for the tumors originating from pineal parenchymal cells. Unfortunately the name has

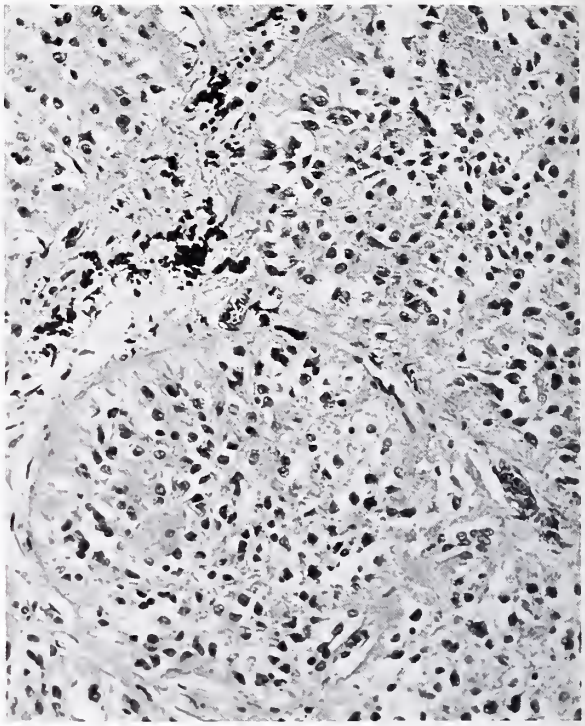

NORMAL PINEAL GLAND

Figure 277. The normal pineal gland shows a lobulated architecture and a suggestion of vascular orientation of its cells. Small darkly staining calcium concretions are present in the interstitial stroma. × 195.

often been used in the past to designate the group now regarded as germinomas. Neoplasms derived from the pineal parenchyma are traditionally divided into a more mature type, the **pineocytoma**, and a more primitive type, the **pineoblastoma**. In view of the special cellular and functional features of the pineal parenchyma noted above, it is not surprising that these neoplasms should possess distinct microscopic characteristics of their own. At the same time, in conformity with the cytologic vagaries that are normally found in tumors in general, they may show morphologic appearances that sometimes align them with gliogenous tumors, sometimes with ganglionic tumors,

and sometimes with tumors of the chemoreceptor system.

In addition to its parenchymal elements, the pineal body also includes much lesser numbers of widely dispersed fibrillary astrocytes that may be the seat of considerable gliosis, especially in the walls of pineal cysts.

PINEOCYTOMA

SYNONYMS AND RELATED TERMS: Pinealocytoma.

This tumor is derived from and composed of relatively mature cells of the pineal parenchyma. It is usually circumscribed and noninvasive, slowly growing, and may be found at any age with both sexes equally affected. The natural history of these tumors is not known. Some behave as malignant neoplasms, but occasional examples are found with a clinical history of several years, suggesting a slow evolution.

The **microscopic** picture resembles the pattern of the normal pineal gland. The tumor is divided by a delicate connective tissue stroma into nests and groups in which cells show a certain vascular orientation (fig. 278). The cytologic features are usually quite regular: the cells are small, with darkly staining nuclei, rather coarse chromatin nodes, and an eosinophilic cytoplasm that is frequently polar (fig. 279). This cell process is often directed toward a blood vessel. With the appropriate silver impregnation for the pineal parenchyma, it is strongly argyro-

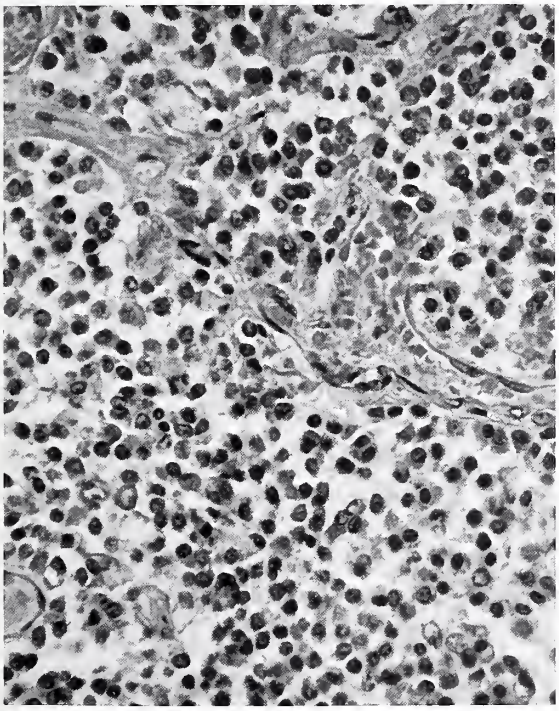

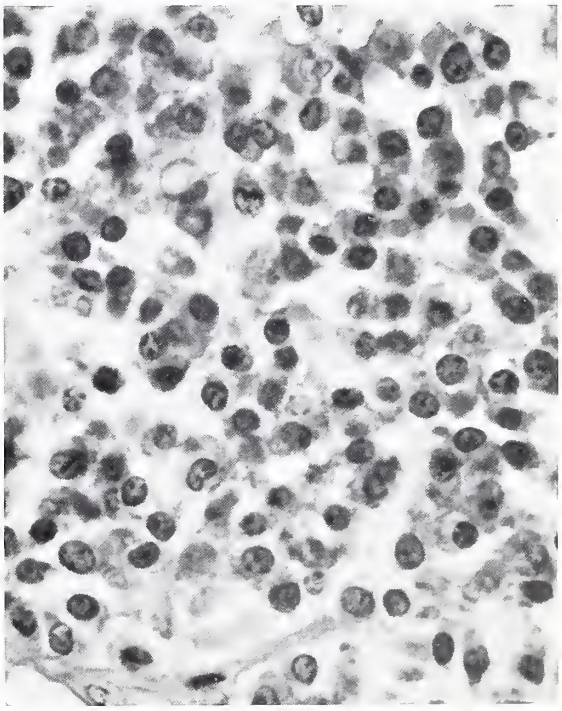

PINEOCYTOMA

Figure 278. This low power view shows the lobulated pattern of a widely metastasizing pineocytoma arising in a 10-year-old boy. × 360. (Fig. 34 from Rubinstein, L. J. Seminario de Neuropatologia, Mérida, Yucatán, Bol. Asoc. Mex. Patol., A. C. 7:13–59, 1969).

(Figures 278 and 279 from same case)

Figure 279. This high power view reveals the uniform cytologic pattern of small cells with regular spheroidal nuclei and a rather ill-defined cytoplasm, with a suggestion of polar cytoplasmic processes. × 700.

philic, and may show the characteristic club-shaped expansion described by Rio-Hortega. Mitotic figures are usually not found.

A characteristic and intriguing histologic picture is provided by an arrangement of regular spheroidal nuclei around central areas occupied by pale eosinophilic material, producing definite rosettes (fig. 280). With silver impregnations including both the modified silver carbonate technic for pineal parenchyma and the Bielschowsky method for nerve fibers, the center of the rosettes often demonstrates a very delicate tangle of fine argyrophilic processes with small clublike terminations (fig. 281).

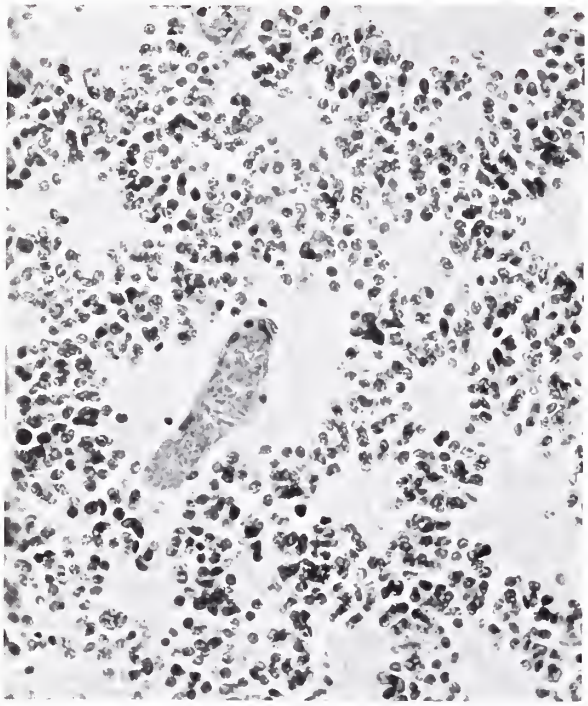

PINEOCYTOMA. ROSETTES

(Figures 280 and 281 from same case)

Figure 280. A distinct arrangement of cells with small uniform nuclei is seen around central areas occupied by pale eosinophilic slightly fibrillated material. This field was typical of a large pineal tumor discovered postmortem in a 78-year-old woman. × 230.

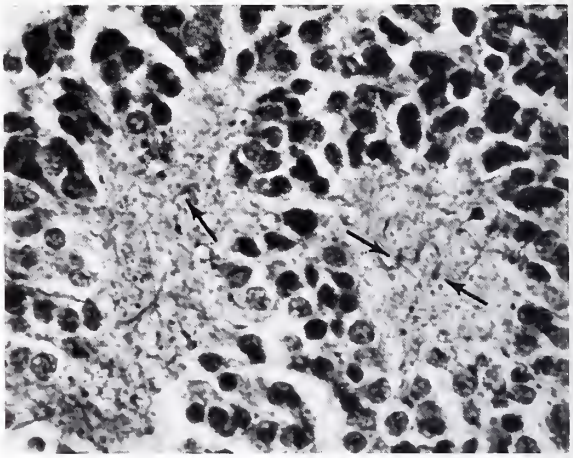

PINEOCYTOMA. ROSETTES WITH CENTRAL ARGYROPHILIC FIBERS

(Figures 280 and 281 from same case)

Figure 281. A silver impregnation shows delicate fibrillary tangles and occasional club-shaped expansions (arrows) in the centers of the rosettes. Bielschowsky method. × 485.

The significance of these rosettes is somewhat enigmatic. In some ways they are reminiscent of neuroblastic rosettes. They may conceivably be a morphologic expression of the kinship of pineal parenchymal cells to neurons, an interpretation that fits with the occasional observation of ganglioneuroma and ganglioglioma in this region (p. 282).

GROWTH AND SPREAD. Little is known about the behavior of these tumors. Some remain circumscribed and noninvasive, as shown by occasional examples disclosed postmortem. Others metastasize extensively through the cerebrospinal fluid pathways and behave like the more primitive tumors of this group, the pineoblastomas (figs. 278, 279). Whether this represents an anaplastic change from a more benign stage cannot be answered until sufficient documentation is available on these rare neoplasms.

DIFFERENTIAL DIAGNOSIS. In a small biopsy the differential diagnosis may

be extremely difficult, and includes oligodendroglioma, neuroblastoma—when rosette formation is present—and, in view of the tendency of the tumor cells to direct their processes toward the blood vessels, astroblastoma. Precise information on the location of the neoplasm and exclusion of alternative sites are usually necessary to substantiate the diagnosis.

PINEOBLASTOMA

SYNONYMS AND RELATED TERMS: Pinealoblastoma; medulloblastoma pinealis.

This rare tumor is a more primitive form of the pineocytoma, that is, a highly cellular neoplasm composed of primitive cells rich in chromatin and with a very ill-defined scanty cytoplasm. The lobular architecture seen in the pineocytoma is preserved in some areas but not in others. The histologic picture resembles that of a medulloblastoma, and may include the formation of rosettes identical with those of a medulloblastoma (fig. 282). Usually specific silver impregnation for pineal parenchymal cells is negative, but occasionally a few cells have an affinity for silver, thus confirming the kinship of this tumor with the pineocytoma. Probably transitional forms exist between the more primitive and the more mature neoplasms.

Occasionally the tumor has a mosaic pattern that recalls the fetal pineal gland; the central part of the lobules contains the larger cells, while the more peripheral part is largely composed of primitive pineoblasts. Although a superficial resemblance to the germinoma is thus produced, all transitional forms between the less and the more mature forms are seen and, unlike the germinomas, the supporting vessels are situated in the center of the lobules and not at their periphery.

GROWTH AND SPREAD. These tumors are highly malignant and behave like medulloblastomas. They may be found both in children and adults. They show a marked tendency to spread in the cerebrospinal axis, thus conforming with medulloblastomas in their biologic behavior.

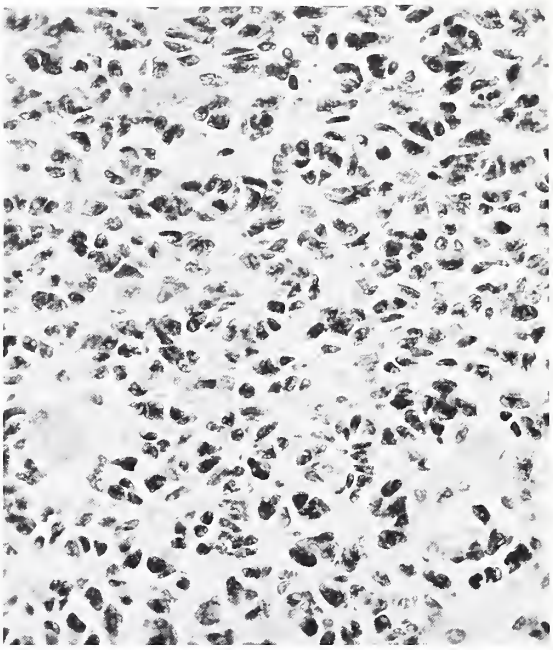

PINEOBLASTOMA

Figure 282. Malignant, poorly differentiated, darkly staining, carrot-shaped cells form an ill-defined arrangement of rosettes resembling medulloblastoma. This section is from a widely metastasizing pineoblastoma arising in a 29-year-old man. × 290.

DIFFERENTIAL DIAGNOSIS. The differential diagnosis from a medulloblastoma is virtually impossible unless precise information on the site of the tumor is available. Difficulties may arise even with careful postmortem examination, since some tumors grow so extensively that their origin from the pineal can only be conjectured. Confusion is particularly likely to occur with a medulloblastoma arising from the superior and rostral part of the vermis.

GANGLIONEUROMA AND GANGLIOGLIOMA

A circumscribed ganglioneuroma occupying the pineal in a 40-year-old man was reported by Horrax and Bailey. Bipolar and astrocytic neuroglial cells with numerous glial fibrils were also present, and although the tumor was interpreted as a ganglioneuroma the alternative diagnosis of ganglioglioma cannot be dismissed. An example of **ganglioglioma** that arose in the pineal region in a 58-year-old man is illustrated in figures 283 through 285. Of interest in this case was the presence of foci of pineocytoma with rosette formation indistinguishable from those seen in figures 280 and 281. Club-shaped cytoplasmic expansions sometimes ending on blood vessel walls were demonstrated with the Bielschowsky silver method, as well as numerous coarse tangled neuronal cell processes with bulbous expansions resembling the multidendritic neurons found in sympathetic ganglia (fig. 284). Astrocytic cells with somewhat pleomorphic cytologic features were also present (fig. 285). This example, interpreted as an instance of gangliogliomatous differentiation in a pineocytoma, is described in greater detail elsewhere (Rubinstein and Okazaki).

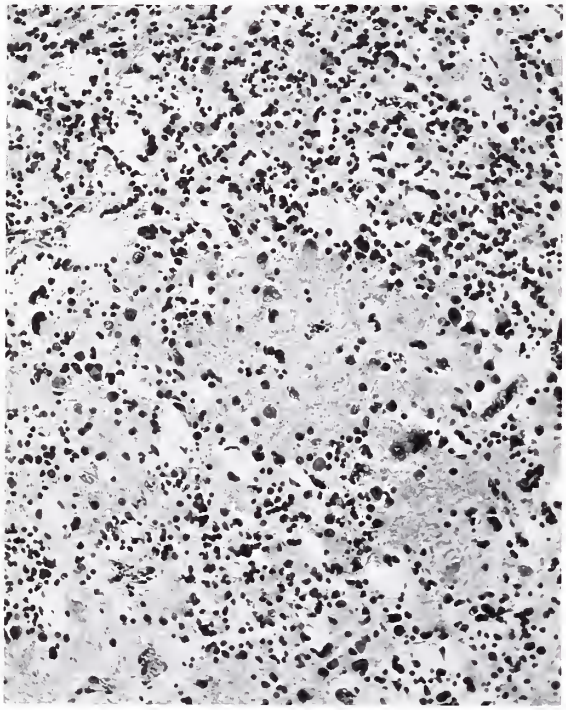

GANGLIOGLIOMA OF THE PINEAL

(Figures 283–285 from same case)

Figure 283. This is the low power view of a ganglionic area in a pineal tumor in a 58-year-old man. In places it had the features of a pineocytoma identical with those in figures 280 and 281. The central field shows a number of ganglion cells scattered on a delicately fibrillated neuropil. × 115.

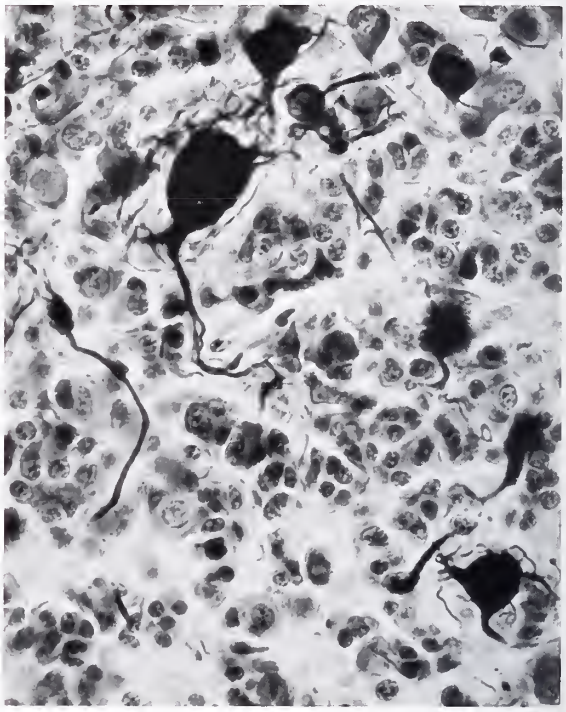

GANGLIOGLIOMA OF THE PINEAL. NEOPLASTIC GANGLION CELLS

Figure 284. A silver impregnation of the ganglionic area shows tortuous nerve fibers arising from large multidendritic neoplastic ganglion cells. The smaller unstained cells are nuclei from the pineocytomatous portion of the tumor. Bielschowsky silver method on frozen section. × 400.

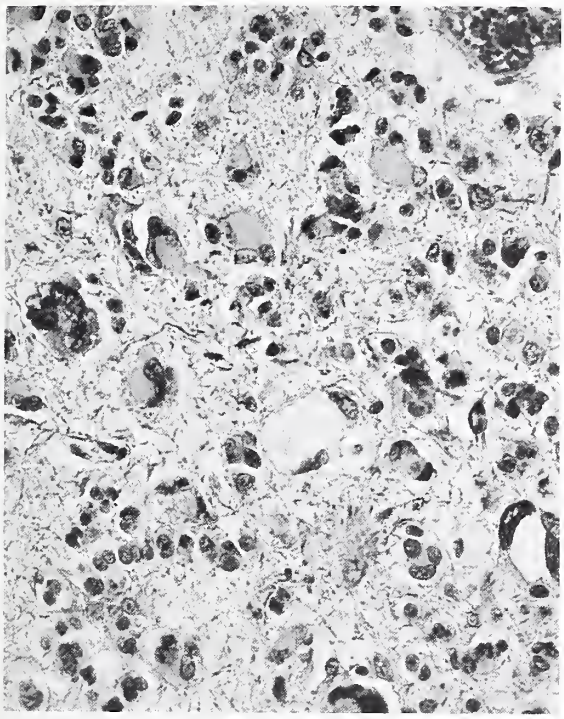

GANGLIOGLIOMA OF THE PINEAL. NEOPLASTIC ASTROCYTIC CELLS

(Figures 283–285 from same case)

Figure 285. The astrocytic area shows irregular pleomorphic neuroglial tumor cells, some of which are multinucleated and have hyperchromatic nuclei. Neuroglial fibers are present throughout this field. PTAH. × 300.

CHEMODECTOMA

In view of the recent emphasis on the presence of biogenic amines and their synthesizing enzymes in the normal pineal, the case of Smith and associates of a chemodectoma in the pineal of a 17-year-old girl is of special interest. Morphologically the tumor cells resembled a typical pineocytoma, but the neoplasm had an abundant sinusoidal structure that divided it into well defined lobules. The resemblance of this tumor to the normal pineal gland on the one hand, and to classic chemodectomas arising in other sites on the other is undeniable.

GLIOMAS

Since the normal pineal gland includes fibrillary astrocytes, the possibility exists that it may be the site of origin of glial tumors, such as astrocytomas and glioblastomas. However, by the time these cases come to examination, the neoplasms are so extensive that their precise source can only be surmised. Many of them probably arise from the corpora quadrigemina or from the wall of the third ventricle. Detailed reports on gliomas arising from and restricted to the pineal body are usually not available, but Zeitlin's Case 2, an astroblastoma, seems acceptable.

OTHER NEOPLASMS OF THE PINEAL REGION

MENINGIOMA

Meningiomas have occasionally been known to arise in the pineal region, having presumably originated from folds of the leptomeninges to form the velum interpositum (Zeitlin, Case 3).

PINEAL CYSTS

Epidermoid and Dermoid Cysts

Epidermoid and dermoid cysts of the pineal region are usually part of a well differentiated teratoma. Occasional microscopic dermoid or epidermoid cysts have been described.

Glial Cysts

Small nonneoplastic glial cysts of the pineal are a frequent incidental finding in autopsy material, especially of elderly people. Marked degenerative changes are usually found, including many Rosenthal fibers. Occasionally large cysts may be present which may cause symptoms due to compression of the corpora quadrigemina and the production of internal hydrocephalus. The histologic picture is benign and does not suggest a true neoplasm.

References

Ariëns Kappers, J. Survey of the Innervation of the Epiphysis Cerebri and the Accessory Pineal Organs of Vertebrates, pp. 87–151. In: Progress in Brain Research, Vol. 10. (Eds.) Ariëns Kappers, J., and Schadé, J. P. Amsterdam: Elsevier Publishing Company, 1965.

Bestle, J. Extragonadal endodermal sinus tumours originating in the region of the pineal gland. Acta Path. Microbiol. Scand. 74:214–222, 1968.

Borit, A. Embryonal carcinoma of the pineal region. J. Path. 97:165–168, 1969.

Dayan, A. D., Marshall, A. H. E., Miller, A. A., Pick, F. J., and Rankin, N. E. Atypical teratomas of the pineal and hypothalamus. J. Path. Bact. 92:1–28, 1966.

Friedman, N. B. Germinoma of the pineal: its identity with germinoma ("seminoma") of the testis. Cancer Res. 7:363–368, 1947.

Ghatak, N. R., Hirano, A., and Zimmerman, H. M. Intrasellar germinomas: a form of ectopic pinealoma. J. Neurosurg. 31:670–675, 1969.

Globus, J. H., and Silbert, S. Pinealomas. Arch. Neurol. 25:937–984, 1931.

Harris, W., and Cairns, H. Diagnosis and treatment of pineal tumours: with report of a case. Lancet 1:3–9, 1932.

Horrax, G., and Bailey, P. Pineal pathology. Further studies. Arch. Neurol. 19:394–414, 1928.

James, W., and Dudley, H. R. Teratoma in region of the pineal body. Report of a case. J. Neurosurg. 14:235–241, 1957.

Jellinger, K., Minauf, M., Kraus, H., and Sunder-Plassmann, M. Embryonales Carcinom der Epiphysenregion. Acta Neuropath. 15:176–182, 1970.

Kageyama, N., and Belsky, R. Ectopic pinealoma in the chiasma region. Neurology 11:318–327, 1961.

Krabbe, K. H. Pineal gland, especially in relation to problem on its supposed significance in sexual development. Endocrinology 7:379–414, 1923.

Løken, A. C. On the relation of atypical pinealomas to teratoid tumours. Acta Path. Microbiol. Scand. 40:417–424, 1957.

Marshall, A. H. E., and Dayan, A. D. An immune reaction in man against seminomas, dysgerminomas, pinealomas, and the mediastinal tumours of similar histological appearance? Lancet 2:1102–1104, 1964.

Nishiyama, R. H., Batsakis, J. G., Weaver, D. K., and Simrall, J. H. Germinal neoplasms of the central nervous system. Arch. Surg. 93:342–347, 1966.

Pierce, G. B., Jr. Ultrastructure of human testicular tumors. Cancer 19:1963–1983, 1966.

Ramsey, H. J. Ultrastructure of a pineal tumor. Cancer 18:1014–1025, 1965.

Rio-Hortega, P. del. Pineal Gland. In: Cytology and Cellular Pathology of the Nervous System, Vol. II, pp. 637–703, 1932. (Ed.) Penfield, W. New York: Hafner Publishing Co., Inc., 1965.

Rubin, P., and Kramer, S. Ectopic pinealoma: a radiocurable neuroendocrinologic entity. Radiology 85: 512–523, 1965.

Rubinstein, L. J., and Okazaki, H. Ganglioglioma tous differentiation in a pineocytoma. J. Path. 102:27–32, 1970.

Russell, D. S. The pinealoma: its relationship to teratoma. J. Path. Bact. 56:145–150, 1944.

———. "Ectopic pinealoma": its kinship to atypical teratoma of the pineal gland. Report of a case. J. Path. Bact. 68:125–129, 1954.

———, and Rubinstein, L. J. Pathology of Tumours of the Nervous System, 3d ed. London: Edward Arnold, 1971.

Schulz, M. D., Wang, C-C., Zinninger, G. F., and Tefft, M. Radiotherapy of Intracranial Neoplasms, pp. 318–370. In: Progress in Neurological Surgery, Vol. 2. (Eds.) Krayenbühl, H., Maspes, P. E., and Sweet, W. H. Chicago: Year Book Medical Publishers, Inc., 1968.

Simson, L. R., Lampe, I., and Abell, M. R. Suprasellar germinomas. Cancer 22:533–544, 1968.

Smith, W. T., Hughes, B., and Ermocilla, R. Chemodectoma of the pineal region, with observations on the pineal body and chemoreceptor tissue. J. Path. Bact. 92:69–76, 1966.

Soas, J. M. Contribution à l'étude anatomique et clinique des tératomes de l'épiphyse. Minerva Neurochir. 10:1–19, 1966.

Stowell, R. E., Sachs, E., and Russell, W. O. Primary intracranial chorionepithelioma with metastases to the lungs. Amer. J. Path. 21:787–801, 1945.

Tompkins, V. N., Haymaker, W., and Campbell, E. H. Metastatic pineal tumors. A clinicopathologic report of two cases. J. Neurosurg. 7:159–168, 1950.

Walton, K. Teratomas of the pineal region and their relationship to pinealomas. J. Path. Bact. 61:11–21, 1949.

Wurtman, R. J., and Kammer, H. Melatonin synthesis by an ectopic pinealoma. New Eng. J. Med. 274:1233–1237, 1966.

———, Axelrod, J., and Kelly, D. E. The Pineal, p. 199. New York: Academic Press, 1968.

Zeitlin, H. Tumors in the region of the pineal body. A clinicopathologic report of three cases. Arch. Neurol. 34:567–586, 1935.

TUMORS AND TUMOR-LIKE LESIONS OF MALDEVELOPMENTAL ORIGIN

NONNEUROGENIC NEOPLASMS

TERATOMAS

DEFINITION. These are tumors that originate primarily within the central nervous system or from its coverings and are composed of tissues that are alien to these structures; the definition excludes tumors in which the abnormal tissue has arisen as the result of metaplasia. On the other hand, dermoid cysts, epidermoid cysts, and craniopharyngiomas should logically be included, but since they form distinct and well defined entities they will be treated separately.

INCIDENCE, SITES. ASSOCIATED CONDITIONS. Intracranial teratomas are rare, forming about 0.5 percent of primary intracranial neoplasms, but accounting for an incidence of 2 percent in subjects below the age of 15 (Ingraham and Bailey). They markedly favor the midline with the pineal or the parapineal regions the most frequent site (Soas); second in frequency is the region of the third ventricle, especially its floor, followed by the pituitary fossa. The posterior fossa, again in the midline, is a rarer but well documented site (Sweet; Müller and Wohlfart). Aside from the relatively frequent sacrococcygeal teratomas, spinal teratomas are even less common than in the intracranial cavity, but have been reported by Ingraham and Bailey, and by Furtado and Marques. They may occur at any level; spina bifida, usually occulta, is often associated. Occasionally they may be situated on one side of the midline, and exceptionally more than one tumor is present.

The majority of cases occur in the first two decades, but occasionally they present in adult life (fig. 286). The sex incidence of intracranial teratomas shows a marked preponderance of males due to their prevalence in the pineal region (p. 275). No such sex differences are found in the spinal examples.

INTRACEREBRAL TERATOMA

Figure 286. This section is from a large, firm, circumscribed intracranial tumor unattached to the dura that excavated the under surface of the right frontal lobe in a 42-year-old man. An island of young stratified epithelium is seen among undifferentiated mesenchymal elements. van Gieson. × 145.

GROSS AND MICROSCOPIC. The gross (pl. X–E) and microscopic appearances are described in the relevant section on tumors of the pineal region (p. 276). Well differentiated elements derived from any of the three germ layers may be found. Figure 286 illustrates an area of young stratified epithelium among undifferentiated mesenchymal elements in a right frontal teratoma in a 43-year-old man.

MALIGNANCY. The teratomas containing adult tissues are circumscribed and benign. Not infrequently, however, they contain more primitive elements that confer malignant features to the neoplasm. The name "teratoid" is then often given to these tumors. Some of the following variants belong to that category.

VARIANTS

Teratomas and Teratoid Tumors of the Fourth Ventricle

The validity of separating these tumors according to their location is of course questionable, but attention is drawn to this midline area as a potential site of teratoid neoplasms that may give rise to confusion with other forms of primitive tumor, especially medulloblastomas. Figures 287 and 288 illustrate the case submitted by Dr. Cecil S. Treip of a lobulated cystic tumor that occupied the vermis in a 3-year-old boy. Part consisted of darkly staining medulloblastoma-like cells; other areas contained well defined differentiated astrocytic islands, or papillary and tubular elements composed of pigmented epithelium resembling the ciliary epithelium and embedded in a connective tissue stroma (fig. 287), whereas still other areas showed tall columnar glandular elements secreting mucus (fig. 288). Another example recently examined in a 2-year-old girl arose in the vermis and was composed partly of astrocytic, partly of ependymomatous areas, as well as of mesodermal myxomatous tissue that enclosed glandular elements and transitional epithelium.

PIGMENTED TERATOMA OF FOURTH VENTRICLE

(Figures 287 and 288 from same case)

Figure 287. The area shown is from a well defined, lobulated, cystic tumor occupying the vermis and abutting onto the fourth ventricle in a 3-year-old boy. Tubular formations composed of darkly pigmented epithelium (melanin) are scattered in a mesenchymal stroma. The gray fibrillated cells at the periphery of the field are well differentiated astrocytic elements. Glandular structures composed of tall columnar epithelium were found in another field. PTAH. × 195.

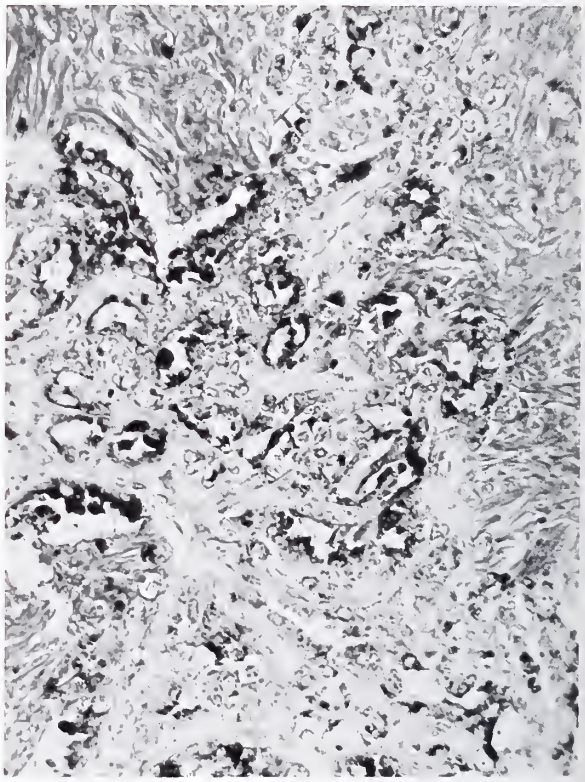

Fig. 287

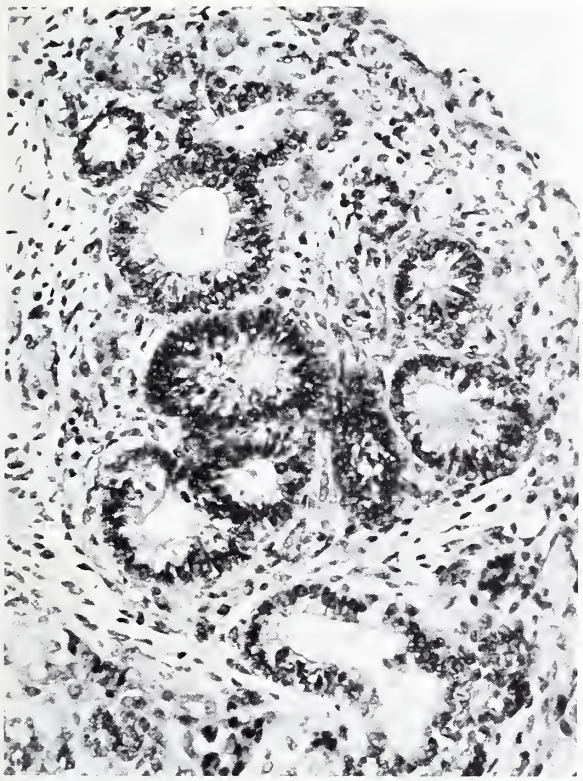

TERATOMA FROM FOURTH VENTRICLE

(Figures 287 and 288 from same case)

Figure 288. This section shows glandular structures composed of tall columnar epithelium. × 215.

Another group of tumors in the posterior fossa that may fall into this category is the so-called "**medullomyoblastoma**" (p. 142), in which neuroepithelial cells with the metallic affinities of neuroblasts have been found adjacent to striated muscle fibers (Russell and Rubinstein; Ingraham and Bailey, Case 4). The interpretation of these cases is complicated by reports of rhabdomyosarcomas that have been demonstrated to originate in the same site (Legier and Wells; Shuangshoti et al.). As noted on page 201, an alternative interpretation in the latter examples should be considered; that is, they may represent embryonal sarcomas with rhabdomyoblastic differentiation. A similar case of rhabdomyosarcoma in a child was reported from the lumbosacral region, associated with spina bifida (O'Connell). The nosologic definition of these exceptional tumors awaits clarification.

Possibly another example of teratoid tumor originating in the vermis is the **pigmented papillary medulloblastoma**, mentioned on page 141, which has recently been suggested to be a variant of the **melanotic neuroectodermal tumor of infancy** (Borello and Gorlin). Similar neoplasms are known to arise from the anterior fontanelle.

Germinoma (or Atypical Teratoma)

This important variant of teratoid tumor situated in the pineal or the suprasellar region is described in the section on Tumors of the Pineal Region (p. 269).

Spinal Enterogenous Cyst (or Teratomatous Cyst of the Vertebral Canal, or Cyst of Endodermal Structure)

This benign form of teratoma consists of a well defined intradural **extramedullary** cyst, usually attached to the spinal cord, most frequently dorsal, but occasionally ventral to it (Harriman; Hoefnagel et al.). All levels may be involved, but there is a slight predominance of the cervical segment. The clinical history is often a long one, punctuated by intermittent symptoms of cord compression. Most surgical patients have been adults in the third decade, but frequently the symptoms date from childhood. The radiologic findings are usually limited to a widening of the vertebral canal and a thinning of the pedicles at the involved levels. Similar **intramedullary** cysts have also been described in infants (Knight et al.; Rhaney and Barclay).

Microscopically the cyst is lined by tall mucus-secreting columnar, usually nonciliated epithelium that resembles intestinal epithelium (pl. X–D). Very occasionally it shows cilia in places (Knight et al.; Hoefnagel et al.). Not infrequently part of the

cyst epithelium is flattened or shows pseudostratification.

These cysts are similar to those that arise in the mediastinum and are then associated with developmental defects of the vertebrae, which may cause a Klippel-Feil deformity, and other dysrhaphic abnormalities such as the Arnold-Chiari malformation (Rhaney and Barclay). Whether the cysts lined partly by ciliated epithelium are related to bronchogenic cysts that are sometimes found in the upper part of the posterior mediastinum is unclear, but the presence of cilia could alternatively be explained by analogy to the esophageal sequestered cysts, in which the ciliated epithelium is a vestige from an early fetal developmental stage (Willis).

References

Borello, E. D., and Gorlin, R. J. Melanotic neuroectodermal tumor of infancy—a neoplasm of neural crest origin. Cancer 19:196–206, 1966.

Furtado, D., and Marques, V. Spinal teratoma. J. Neuropath. Exp. Neurol. 10:384–393, 1951.

Harriman, D. G. F. An intraspinal enterogenous cyst. J. Path. Bact. 75:413–419, 1958.

Hoefnagel, D., Benirschke, K., and Duarte, J. Teratomatous cysts within the vertebral canal. Observations on the occurrence of sex chromatin. J. Neurol. Neurosurg. Psychiat. 25:159–164, 1962.

Ingraham, F. D., and Bailey, O. T. Cystic teratomas and teratoid tumors of the central nervous system in infancy and childhood. J. Neurosurg. 3:511–532, 1946.

Knight, G., Griffiths, T., and Williams, I. Gastrocytoma of the spinal cord. Brit. J. Surg. 42:635–638, 1955.

Legier, J. F., and Wells, H. A., Jr. Primary cerebellar rhabdomyosarcoma. Case report. J. Neurosurg. 26:436–438, 1967.

Müller, R., and Wohlfart, G. Intracranial teratomas and teratoid tumors. Acta Psychiat. Scand. 22:69–95, 1947.

O'Connell, J. E. A. The subarachnoid dissemination of spinal tumours. J. Neurol. Neurosurg. Psychiat. 9:55–62, 1946.

Rhaney, K., and Barclay, G. P. T. Enterogenous cysts and congenital diverticula of the alimentary canal with abnormalities of the vertebral column and spinal cord. J. Path. Bact. 77:457–471, 1959.

Russell, D. S., and Rubinstein, L. J. Pathology of Tumours of the Nervous System, 3d ed. London: Edward Arnold, 1971.

Shuangshoti, S., Piyaratn, P., and Viriyapanich, P. L. Primary rhabdomyosarcoma of cerebellum—necropsy report. Cancer 22:367–371, 1968.

Soas, J. M. Contribution à l'étude anatomique et clinique des tératomes de l'épiphyse. Minerva Neurochir. 10:1–19, 1966.

Sweet, W. H. A review of dermoid, teratoid and teratomatous intracranial tumors. Dis. Nerv. Syst. 1:228–238, 1940.

Willis, R. A. The Borderland of Embryology and Pathology, p. 315. London: Butterworth & Co., Ltd., 1958.

DERMOID AND EPIDERMOID CYSTS

DEFINITION. PATHOGENESIS. Although skin and its appendages often form part of a teratoma, dermoid and epidermoid cysts constitute well recognized separate entities in the central nervous system. Whereas epidermoid cysts are lined solely by stratified squamous epithelium, the lining of dermoid cysts includes, in addition, skin appendages such as hair follicles and sebaceous glands or sweat glands. There are definite differences in the clinical and anatomic incidence of these two types of cyst, but they are often grouped together under the name of "pearly tumors" (Tytus and Pennybacker). Both are regarded as resulting from the inclusion of epithelial elements at the time of closure of the neural groove, between the third and fifth week of fetal life; this is especially likely in the case of dermoid cysts, since these are most frequently midline and often coexist with associated defects of the overlying bone and skin.

In some cases, however, the lower spinal cysts have a traumatic origin that results

from the iatrogenic penetration of skin fragments in that region. This has been reported in children who were treated with repeated lumbar punctures for meningitis, usually tuberculous (Blockey and Schornstein). Both dermoid and epidermoid cysts have been produced experimentally in the brain and cord of young rats, using a similar method (van Gilder and Schwartz).

Dermoid cysts are rarer in the intracranial cavity than epidermoid cysts, but somewhat more common in the spinal canal. In the intracranial cavity they are most frequently found in the posterior fossa, either in the vermis or in the cavity of the fourth ventricle. In the **spinal canal** most dermoid cysts occur in the lumbosacral region (fig. 289), either in an extramedullary or in an intramedullary location. Symptoms usually arise in the first two decades of life for the intraspinal group (List), and in the third decade for the intracranial examples. Occasionally intraspinal dermoid cysts are associated with syringomyelia (fig. 289). A more frequent coexisting anomaly is that of spina bifida.

GROSS. Dermoid cysts vary greatly in size, but usually present as well defined pink, sometimes lobulated masses (fig. 289). Calcification may be found. On section they contain thick buttery-yellow material, due to the secretions of sebaceous glands and desquamated epithelium. Occasionally they are multiple (List). A frequent association, especially in the spinal examples, is the presence of a **dermal sinus** overlying the site of the cyst, which may pave the way for a pyogenic meningitis. Dermal sinuses in the occipital region may also be associated with cerebellar cysts (Tytus and Pennybacker) and they too may be a source of meningitis.

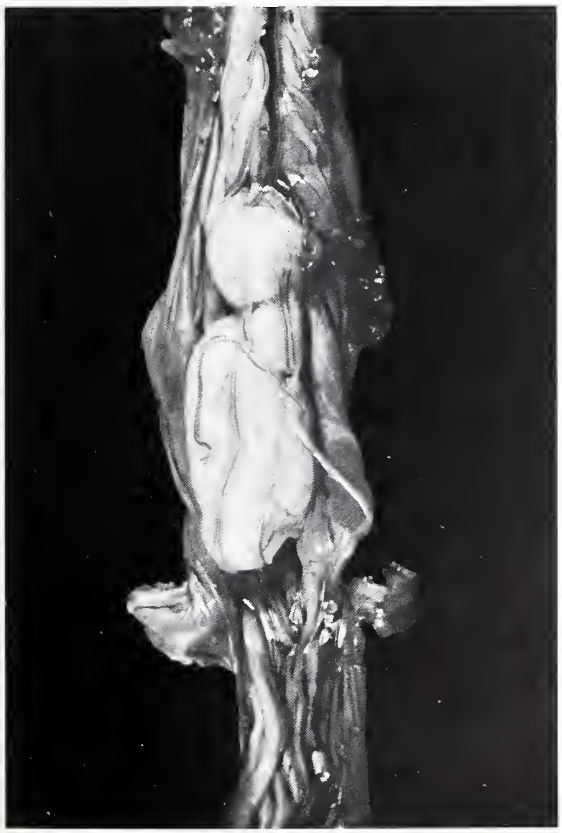

Fig. 289

INTRASPINAL DERMOID CYST

Figure 289. A large multiloculated, intraspinal dermoid cyst covers the conus medullaris in a 48-year-old man. This patient had slowly progressing symptoms of neuralgic leg pain and weakness, a neurogenic bladder, and saddle hyperesthesia for 27 years. Associated with this dermoid cyst was an extensive syringomyelia with multicystic cavitation of the cord at many levels extending from the third cervical segment to the distal end of the cord. In the latter area it was adjacent to the dermoid cyst. The syringomyelic cavity was largest in the cervical expansion, but completely absent at some levels. The central canal was always present and separate from the cavity. The coexistence of syringomyelia and intraspinal neoplasm is well established, but the significance of this association is unclear. (Courtesy of Dr. L. S. Forno, Stanford, Calif.)

MICROSCOPIC. The lining of the cyst consists of stratified squamous epithelium with hair follicles, sebaceous, and sweat glands. When the contents of the cyst spill into the cerebrospinal fluid pathways, they are apt to induce a granulomatous form of meningitis with a marked foreign body giant cell reaction, which may be fatal.

These tumors are benign, but will recur if incompletely removed. This is likely to occur when the cyst wall is closely attached to the spinal cord. Malignant change is exceptional, but has been reported in one cerebral example (Gluszcz).

Epidermoid cysts (cholesteatomas) are somewhat more frequent than dermoid cysts, especially in the cranial cavity, and may also involve the diploe. They may occur at any age, but most are found in middle age; the peak incidence is in the fifth decade.

The location of epidermoid cysts shows a much greater variation than that of dermoid cysts and also a greater tendency to deviate from the midline. The most frequent site is the cerebellopontine angle (fig. 290); next is the parapituitary region, in the middle fossa, where the tumor is usually embedded in the temporal lobe. The diploe is next in frequency, usually in the frontal and parietal bones, followed by the spinal canal, and the paratrigeminal region. This may be accompanied by erosion of the apex of the petrous temporal bone (Baumann and Bucy). Occasionally epidermoid cysts occupy the cerebral hemispheres (Peyton and Baker), and may fill a lateral ventricle (fig. 291). Considerable dilatation of the ventricular system may result.

In the spinal canal there is a lesser concentration of these tumors in the lumbosacral region than with dermoid cysts, but as with the latter they may be associated with congenital defects of the vertebral column and occasionally with dermal sinuses (Saunders).

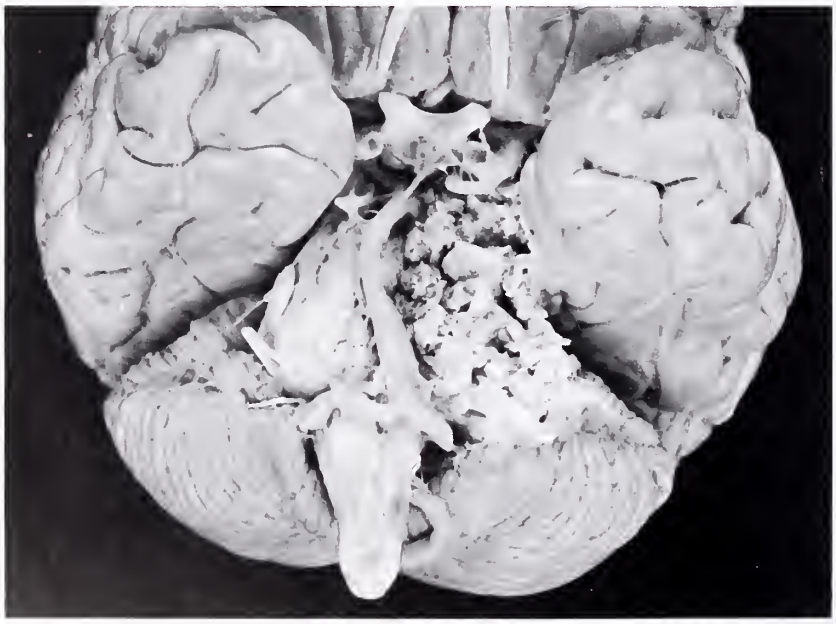

EPIDERMOID CYST IN PONTOCEREBELLAR ANGLE

Figure 290. The characteristic gross appearance of a so-called "pearly tumor" in the left pontocerebellar angle is shown. Note the granular, grumose appearance of this epidermoid cyst, which had been ruptured during removal. (Fig. 120 from Fascicle 35, First Series).

WALL OF EPIDERMOID CYST

Figure 291. This grossly flattened and distorted brain has been opened to display a large intraventricular epidermoid cyst containing whitish flaky material in its wall. Note the considerable dilatation of the remainder of the ventricular system. This lesion was found in an 11-month-old girl. (Courtesy of the Armed Forces Institute of Pathology).

GROSS. Epidermoid cysts are well defined with an irregular nodular outer surface and a shiny "mother of pearl" appearance, from which the term "pearly tumor" is derived (fig. 290). Focal calcification may be present (Peyton and Baker). The inside of the cyst is filled with soft waxy or flaky material (fig. 291) rich in cholesterol crystals resulting from the progressive desquamation of keratin from the cyst wall.

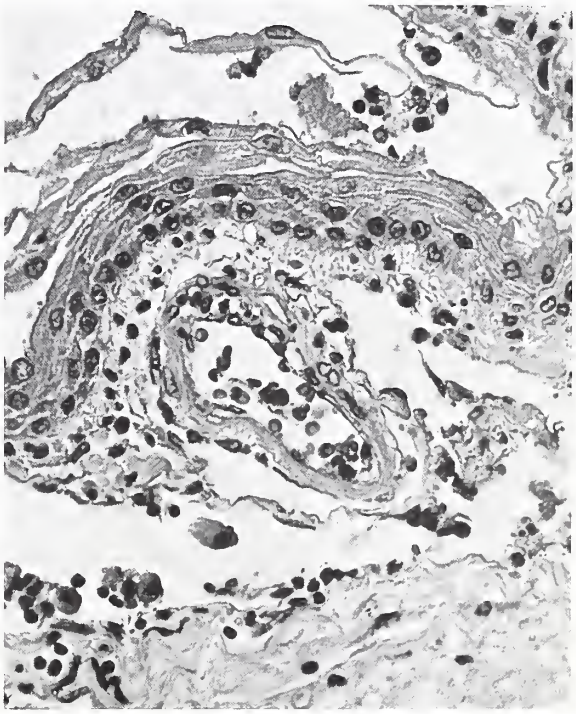

Fig. 292

WALL OF EPIDERMOID CYST

Figure 292. This is the microscopic appearance of the wall of an epidermoid cyst. It is composed of stratified squamous epithelium. The cyst wall lines the ventricle. Note the active chronic inflammation beneath the epithelium. × 300.

MICROSCOPIC. The cyst is lined by simple stratified squamous epithelium showing a variable degree of keratinization (fig. 292). The epithelium rests on an outer layer of connective tissue which may be moderately vascular.

One well known complication of epidermoid cysts results, as in the case of dermoid cysts, from the spilling of the desquamated keratin into the cerebrospinal fluid pathway with the production of a chemical granulomatous meningitis.

Like dermoid cysts, epidermoid cysts are usually benign, but will recur if incompletely removed. When they occupy the ventricle, recurrence may be accompanied by a gradual spread of the squamous epithelium along the ventricular lining so that a major portion of the ventricle may then be epithelialized. Carcinomatous change in epidermoid cysts with carcinomatosis of the leptomeninges has occasionally been reported (Davidson and Small; Landers and Danielski).

References

Baumann, C. H. H., and Bucy, P. C. Paratrigeminal epidermoid tumors. J. Neurosurg. 13:455–468, 1956.

Blockey, N. J., and Schorstein, J. Intraspinal epidermoid tumors in the lumbar region of children. J. Bone Joint Surg. 43B:556–562, 1961.

Davidson, S. I., and Small, J. M. Malignant change in an intracranial epidermoid. J. Neurol. Neurosurg. Psychiat. 23:176–178, 1960.

Gluszcz, A. A cancer arising in a dermoid of the brain. J. Neuropath. Exp. Neurol. 21:383–387, 1962.

Landers, J. W., and Danielski, J. J. Malignant intracranial epidermoid cyst. Arch. Path. 70:419–423, 1960.

List, C. F. Intraspinal epidermoids, dermoids, and dermal sinuses. Surg. Gynec. Obstet. 73:525–538, 1941.

Peyton, W. T., and Baker, A. B. Epidermoid, dermoid and teratomatous tumors of the central nervous system. Arch. Neurol. 47:890–917, 1942.

Saunders, R. L. Intramedullary epidermoid cyst associated with a dermal sinus. J. Neurosurg. 31:83–86, 1969.

Tytus, J. S., and Pennybacker, J. Pearly tumours in relation to the central nervous system. J. Neurol. Neurosurg. Psychiat. 19:241–259, 1956.

van Gilder, J. C., and Schwartz, H. G. Growth of dermoids from skin implants to the nervous system and surrounding spaces of the newborn rat. J. Neurosurg. 26:14–20, 1967.

CRANIOPHARYNGIOMA

SYNONYMS AND RELATED TERMS: Suprasellar epidermoid cyst; Rathke pouch tumor; adamantinoma; ameloblastoma.

PATHOGENESIS. These well known and relatively common tumors are widely believed to originate from squamous cell nests that are frequently found at the junction of the lower infundibular stem with the pars distalis of the adenohypophysis. These nests have long been thought to represent remnants of the original Rathke pouch, but their prevalence in later life has led several workers to adopt the alternative view that they are the result of metaplasia in the cells of the adenohypophysis rather than embryonic rests (Luse and Kernohan; Hunter). However, these nests have also been reported occasionally in the newborn (Goldberg and Eshbaugh). Perhaps they play no special part in the etiology of craniopharyngiomas, which could then simply represent another form of midline congenital tumor not fundamentally different from epidermoid cysts in other sites.

INCIDENCE. CLINICAL DATA. Craniopharyngiomas account for 3 percent of all intracranial tumors, and are among the most frequent supratentorial neoplasms in childhood. More than half are seen in the first and second decades, when they may cause symptoms referable to the hypothalamus, depress anterior pituitary function, and

compress the optic chiasm and tracts, with the production of hemianopsias. They are also not uncommonly found in adult life, especially in the fifth decade. Plate X-F illustrates an example in a 53-year-old man, which was associated with an intrasellar chordoma (Belza).

GROSS. Craniopharyngiomas may be either largely cystic, or partly solid and cystic. They vary greatly in size, the small tumors presenting as small cystic nodules which occupy the tuber cinereum, whereas the larger examples may fill the cavity of the third ventricle (pl. X-F) and cause obstruction to the flow of cerebrospinal fluid. The tumors are usually well defined, but firmly attached to the surrounding brain, due to considerable reactive gliosis. Occasionally the tumor extends into the pituitary fossa and is of hourglass shape, due to constriction of its waist by the diaphragm sellae. In some cases it may project posteriorly along the ventral aspect of the pons. Exceptionally it may directly invade the basal ganglia and brainstem parenchyma (Grover and Rorke). On section the solid areas are usually pale and granular, often containing gritty foci of calcification and even bone formation. The cystic areas contain straw-colored, shimmering or brownish machine-oil-like fluid, rich in cholesterol crystals.

MICROSCOPIC. The histologic appearances are those of a microcystic epithelial tumor, in which the cells are arranged in thin cords of uniform angulated columnar cells resting on a collagen basement membrane. In many areas the epithelium is squamous and arranged in whorls with keratin pearl formations. In other fields the columnar elements are separated by loosely arranged stellate cells in a scanty fibrillated matrix, producing the so-called "adamantinomatous" pattern (fig. 293). Transitions are found between the solid adamantinomatous areas and the more cystic areas lined by stratified epithelium. The masses of keratin tend to become confluent and often undergo calcification and even bone formation. Gliosis around the tumor is often considerable and of long duration, and may pinch off small masses of tumor cells, giving the erroneous impression of carcinomatous invasion. True carcinomatous change, however, has not been reported. Degenerative changes characterized by the presence of Rosenthal fibers are frequent in the surrounding reactive neuroglia.

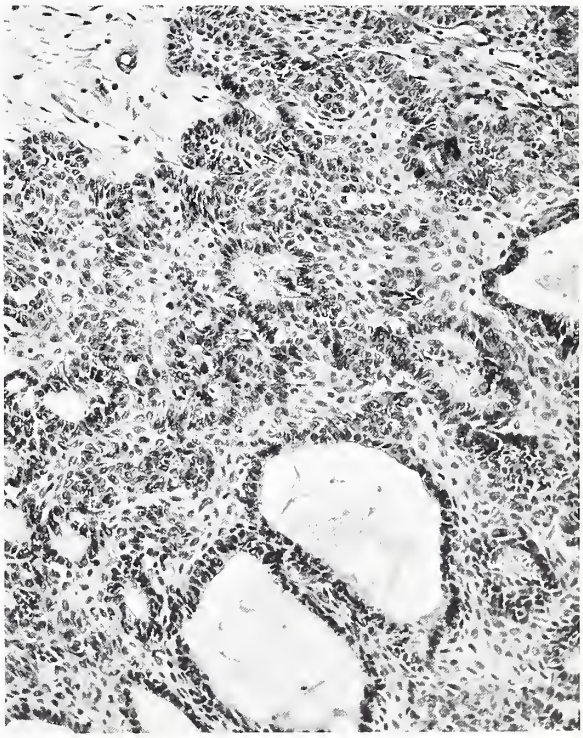

CRANIOPHARYNGIOMA

Figure 293. This microscopic picture of a craniopharyngioma shows a typical adamantinomatous pattern. × 145.

Some examples contain no adamantinomatous elements, and simply consist of a large cyst lined by stratified squamous keratinizing epithelium. These tumors, frequently designated "suprasellar cysts," are histologically indistinguishable from the epidermoid cysts previously described.

Further details and illustrations of this tumor will be found in Fascicle 36, "Tumors of the Pituitary Gland and Infundibulum" by Kernohan and Sayre.

TREATMENT. PROGNOSIS. The treatment of craniopharyngiomas is notoriously difficult. Their location and their firm attachment to the surrounding brain usually make total removal impossible, and only partial removal of the cyst wall with drainage of the cyst is generally feasible. The tumor is radioresistant, but because of the hazards that accompany attempts at surgical removal, efforts have been made to treat it with high doses of radiation or with the introduction of radioactive material in the cyst wall (Overton and Sheffel). Favorable results have been reported by Kramer and associates in cases treated by combined surgery and radiation therapy. In their series, 9 of 10 patients were living and well 8 to 10 years after treatment; one patient had a recurrence.

Intrasellar Rathke Cleft Cysts

In distinction to the typical craniopharyngioma, there are intrasellar cysts lined by cuboidal and occasionally ciliated epithelium that are regarded as genuinely originating from remnants of the original Rathke pouch (Berry and Schlezinger). They occasionally arise above the sella turcica, may show spontaneous hemorrhage, and compress the pituitary gland. The epithelium of the cyst is identical with that which lines the small cleft that is frequently found incidentally in the normal pituitary between the pars anterior and the infundibular process.

References

Belza, J. Double midline intracranial tumors of vestigial origin: contiguous intrasellar chordoma and suprasellar craniopharyngioma. Case report. J. Neurosurg. 25:199–204, 1966.

Berry, R. G., and Schlezinger, N. S. Rathke-cleft cysts. Arch. Neurol. 1:48–58, 1959.

Goldberg, G. H., and Eshbaugh, D. E. Squamous cell nests of the pituitary gland as related to the origin of craniopharyngiomas. Arch. Path. 70:293–299, 1960.

Grover, W. D., and Rorke, L. B. Invasive craniopharyngioma. J. Neurol. Neurosurg. Psychiat. 31: 580–582, 1968.

Hunter, I. J. Squamous metaplasia of cells of the anterior pituitary gland. J. Path. Bact. 69:141–145, 1955.

Kernohan, J. W., and Sayre, G. P. Tumors of the Pituitary Gland and Infundibulum. Fascicle 36, Atlas of Tumor Pathology. Washington: Armed Forces Institute of Pathology, 1956.

Kramer, S., McKissock, W., and Concannon, J. P. Craniopharyngiomas: Treatment by combined surgery and radiation therapy. J. Neurosurg. 18:217–226, 1961.

Luse, S. A., and Kernohan, J. W. Squamous-cell nests of the pituitary gland. Cancer 8:623–628, 1955.

Overton, M. C., and Sheffel, D. D. Recurrent cyst formation in craniopharyngioma treated with radioactive chromic phosphate. J. Neurosurg. 20:707–710, 1963.

LIPOMAS

Intracranial lipomas are rare and often clinically silent (fig. 294). Some examples may produce epilepsy or hypothalamic symptoms. The spinal tumors may cause cord compression. They are found at any age.

Intracranial lipomas are most common in the midline, especially over the corpus callosum, where their characteristic wineglass shape may be seen on anteroposterior x-ray, outlined by peripheral calcification

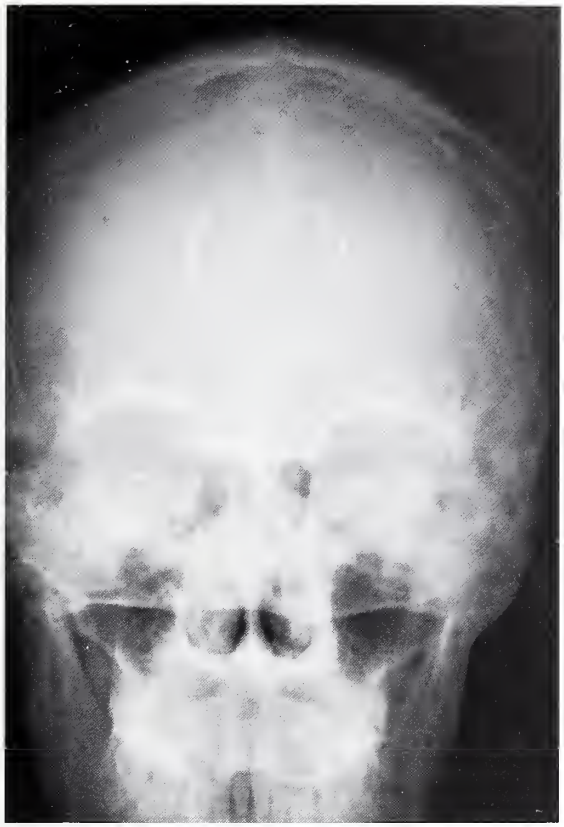

Fig. 294

(fig. 294). In this region lipomas are frequently associated with partial or complete agenesis of the corpus callosum (Zettner and Netsky). Other areas include the tuber cinereum and the tegmentum of the midbrain, where they may be the cause of internal hydrocephalus.

In the spinal canal they account for about one percent of all tumors, most of them being found in the second and third decades. The majority are situated in the thoracic region. They are associated with other congenital abnormalities in about one third of the cases (Giuffrè). Spina bifida, especially occulta, fairly frequently accompanies lumbosacral lipomas. Most of them are intradural and extramedullary, but a minority are intramedullary.

LIPOMA OF CORPUS CALLOSUM

Figure 294. X-ray of skull shows a large central wineglass-shaped lipoma with peripheral calcification. This was found on incidental radiologic examination in a 20-year-old man. (Courtesy of Col. Ludwig Kempe, Walter Reed Army Medical Center)

Microscopically they show, in addition to obvious adipose tissue, a variable amount of collagen, sometimes striated or unstriated muscle fibers (Taniguchi and Mufson), fibrillary neuroglia, ganglion cells and neurites, vascular elements, and frequently calcification and bone formation. In the latter, foci of erythropoiesis and leukopoiesis may be found. The neuroglial and ganglionic elements are probably part of the malformation and presumably originate from the displacement of these tissues during development, followed by their incorporation into the lipoma. The presence of elements other than fat stresses the malformative origin of this lesion.

References

Giuffrè, R. Intradural spinal lipomas. Review of the literature (99 cases) and report of an additional case. Acta Neurochir. 14:69–95, 1966.

Taniguchi, R., and Mufson, J. A. Intradural lipoma of the spinal cord; report of a case. J. Neurosurg. 7:584–586, 1950.

Zettner, A., and Netsky, M. G. Lipoma of the corpus callosum. J. Neuropath. Exp. Neurol. 19:305–319, 1960.

NEUROEPITHELIAL ECTOPIC TUMORS AND HAMARTOMAS

ECTOPIC GLIOMAS

Cases of ectopic gliomas arising in the leptomeninges have been described on the assumption that they may have originated from heterotopic central nervous tissue which is sometimes found in infants in the subarachnoid space (Popoff and Feigin). The reported intracranial examples, however, must be treated with great reservations, since none have been described in which subsequent postmortem examination excluded an underlying glioma that might have originated from a relatively limited neoplastic field within the central nervous system parenchyma.

In relation to the cranial cavity, a rare site of ectopic glioma is the bridge of the nose, and more rarely, the soft palate or the pericranium. Most of the reported **nasal gliomas** consist of fibrillary glia, and many are associated with an underlying bony defect in the cribriform plate, through which the tumor is attached to the interior of the cranium by a fibrous or glial stalk. The pathogenesis and the literature on previous cases have been reviewed by Black and Smith, and by Smith and associates. Whether they should be regarded as true neoplasms or essentially hamartomas devoid of the biologic features of active growth is uncertain. The treatment is surgical, but the risk of meningitis is great.

In the **spinal canal**, ectopic gliomas have been described both as intradural extramedullary tumors and as extraspinal neoplasms that may produce considerable erosion of the sacral bone (Cooper et al.). The **intradural** extramedullary gliomas have been thought to originate from heterotopic glial remnants in the spinal subarachnoid space, and are usually situated in the lumbosacral region, often being associated with spina bifida occulta. They may be either astrocytomas or ependymomas. The **extraspinal** gliomas are usually well differentiated ependymomas and frequently diagnosed in adult life. A minority are astrocytic, as in the case of a large sacral tumor in a 3½-month-old infant boy, which consisted in an intersecting array of finely fibrillated neuroglial tissue separated into lobules by a delicate regular connective tissue stroma (figs. 295, 296).

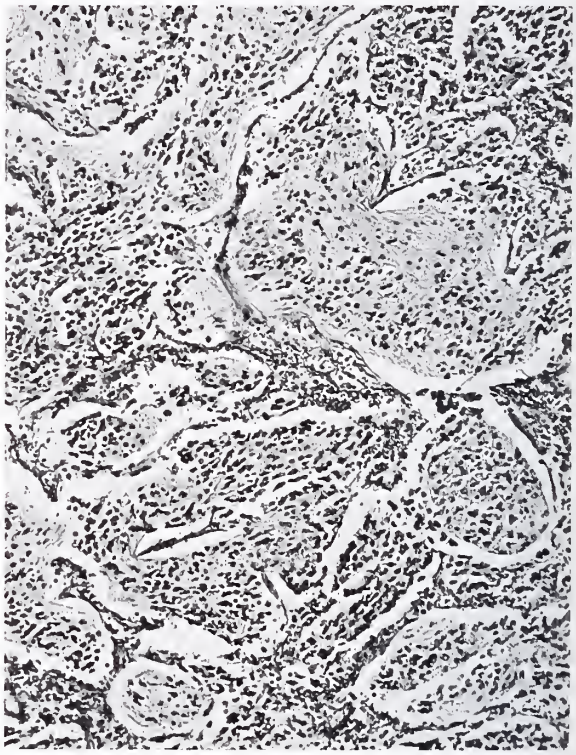

ECTOPIC SACRAL GLIOMA

(Figures 295 and 296 from same case)

Figure 295. This ectopic astrocytoma was found in the sacral region of a 3½-month-old boy. The lobules are composed of delicate fibrillated neuroglia intersected by a thin vascular connective tissue stroma. × 100.

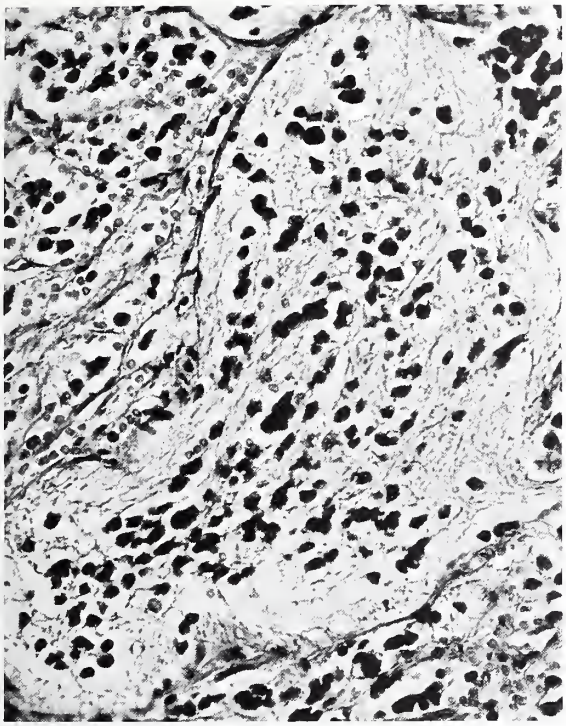

ECTOPIC SACRAL GLIOMA

(Figures 295 and 296 from same case)

Figure 296. This high power view shows the fibrillary nature of this neuroglial tumor and is clearly seen at this magnification. × 265.

References

Black, B. K., and Smith, D. E. Nasal glioma. Two cases with recurrence. Arch. Neurol. 64:614–630, 1950.

Cooper, I. S., Craig, W. M., and Kernohan, J. W. Tumors of the spinal cord; primary extramedullary gliomas. Surg. Gynec. Obstet. 92:183–190, 1951.

Popoff, N., and Feigin, I. Heterotopic central nervous tissue in subarachnoid space. Arch. Path. 78:533–539, 1964.

Smith, K. R., Jr., Schwartz, H. G., Luse, S. A., and Ogura, J. H. Nasal gliomas: a report of five cases with electron microscopy of one. J. Neurosurg. 20:968–982, 1963.

MELANOTIC NEUROECTODERMAL TUMOR OF INFANCY

SYNONYMS AND RELATED TERMS: "Retinal anlage tumor"; melanotic progonoma; melano-ameloblastoma; melanotic adamantinoma; pigmented epulis.

This rare but well documented pigmented tumor usually arises in the maxillary region in infants. Its origin remains a matter of considerable controversy. It is locally invasive but usually benign, and surgical treatment is almost always successful. Aside from the maxillary region other areas from which it originates include the mandible, the anterior fontanelle (fig. 297), and occasionally the cerebellum (p. 141). The histologic picture, which is identical to that illustrated in the cerebellar tumor shown in figure 149, is highly distinctive; it is composed of islands of uniform spheroidal or

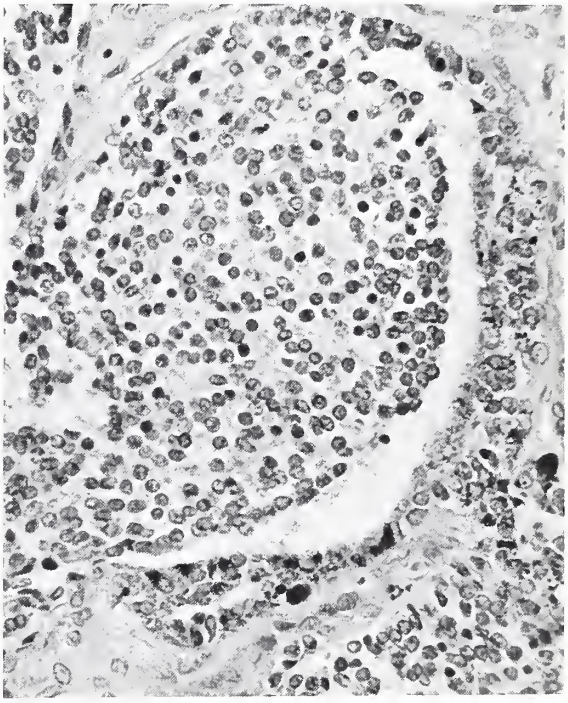

MELANOTIC NEUROECTODERMAL TUMOR OF INFANCY ("RETINAL ANLAGE TUMOR")

Figure 297. This section is from a tumor in the region of the anterior fontanelle in a 3½-month-old infant. Closely packed collections of small neuroectodermal cells resembling neuroblasts are shown with an outer ring of similar cells containing melanin pigment. There is a rather coarse intersecting connective tissue stroma. × 340.

polygonal cells on a finely fibrillated neuroepithelial matrix, and partly of papillary formations whose lining cells are filled with melanin granules. The previously reported cases have been tabulated by Borello and Gorlin, who have discussed in detail the various histogenetic theories of this curious neoplasm, and favor its neural crest origin. The case they report showed a high urinary excretion of vanilmandelic acid that returned to normal after excision of the tumor. The fine structure of one example originating from the region of the anterior fontanelle has been reported by Neustein.

References

Borello, E. D., and Gorlin, R. J. Melanotic neuroectodermal tumor of infancy—a neoplasm of neural crest origin. Cancer 19:196–206, 1966.

Neustein, H. B. Fine structure of a melanotic progonoma or retinal anlage tumor of the anterior fontanel. Exp. Molec. Path. 6:131–142, 1967.

HYPOTHALAMIC GANGLIONIC HAMARTOMA

This rare lesion is a well defined malformation composed of redundant gray matter that projects from the base of the brain and is usually attached to the tuber cinereum or the mamillary bodies by a thick stalk. In a few cases, however, there is no such attachment (Bedwell and Lindenberg). The condition is classically associated with precocious puberty (Schmidt et al.) and usually occurs in males. Microscopically the tissue resembles normal gray matter, but the neurons may show considerable variation in size and shape, with some unipolar and others multipolar (fig. 298). They bear a resemblance to some of the hypothalamic nuclei, and occasionally definite fiber connections with the hypothalamus have been demonstrated (Wolman and Balmforth). These authors have argued that pubertas praecox may be due to neurosecretory activity by the neurons in the hamartoma, but this view has been countered by Northfield and Russell on the evidence that one of their cases with pubertas praecox showed no peduncular attachment of the hamartoma to the brain. Furthermore, precocious puberty has been associated with a variety of other hypothalamic lesions, and especially with pineal tumors, the majority of which were teratomatous (p. 269). It would seem therefore that the endocrine dysfunction typically associated with this lesion may be mechanical. The mass, which is entirely benign and in the nature of a simple malformation, is amenable to surgical excision with long-term survival. Although no

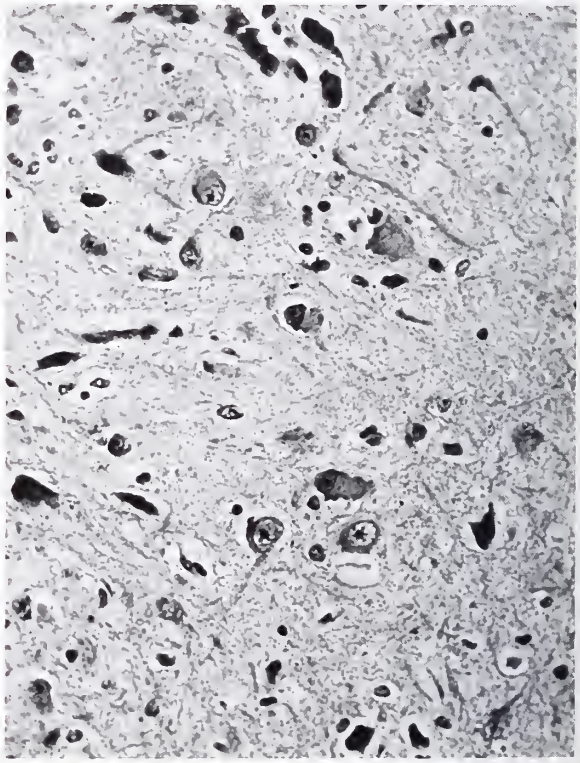

HYPOTHALAMIC GANGLIONIC HAMARTOMA

Figure 298. This hypothalamic ganglionic hamartoma was present in a boy with pubertas praecox. There is an irregular distribution of neurons of various sizes and shapes. × 300.

regression of the macrogenitosomia was obtained, normal somatic development resumed in one case (Northfield and Russell).

References

Bedwell, S. F., and Lindenberg, R. A hypothalamic hamartoma with dendritic proliferation and other neuronal changes associated with "blastomatoid" reaction of astrocytes. J. Neuropath. Exp. Neurol. 20:219–236, 1961.

Northfield, D. W. C., and Russell, D. S. Pubertas praecox due to hypothalamic hamartoma: report of two cases surviving surgical removal of the tumour. J. Neurol. Neurosurg. Psychiat. 30:166–173, 1967.

Schmidt, E., Hallervorden, J., and Spatz, H. Die Entstehung der Hamartome am Hypothalamus mit und ohne Pubertas Praecox. Dtsch. Z. Nervenheilk. 177:235–262, 1957.

Wolman, L., and Balmforth, G. V. Precocious puberty due to a hypothalamic hamartoma in a patient surviving to late middle age. J. Neurol. Neurosurg. Psychiat. 26:275–280, 1963.

CHORISTOMA OF THE NEUROHYPOPHYSIS

SYNONYMS AND RELATED TERMS: "Myoblastoma."

The name "choristoma" was given by Sternberg to the microscopic groups of large, oval, faintly granulated eosinophilic cells with eccentric nuclei that are frequently found incidentally in the pituitary stalk and the pars nervosa of the hypophysis, especially in the older age groups. Figures 299 and 300 illustrate a small well defined tumor seen grossly to originate in the region of the tuber cinereum and surround the pituitary stalk in a 65-year-old woman. On section it was well defined, rather soft and granular with a homogeneous yellowish gray cut surface (fig. 300). Microscopically it uniformly consists of large cells measuring 30 to 40 micra in diameter with a regular polyhedral outline, a finely granular cyto-

CHORISTOMA OF THE NEUROHYPOPHYSIS

Figure 299. This is the ventral view of a well defined tumor arising in the region of the tuber cinereum in a 65-year-old woman. It was found incidentally at postmortem examination. Part of the pituitary stalk is seen in the center of the nodule.

(Figures 299–301 from same case)

Figure 300. This coronal section of the specimen in figure 299 reveals a well defined nodule with a homogeneous cut surface.

plasm, and small eccentric, usually deeply staining nuclei (fig. 301). Separate foci of identical microscopic appearance were also found in the pars nervosa of the pituitary in this patient.

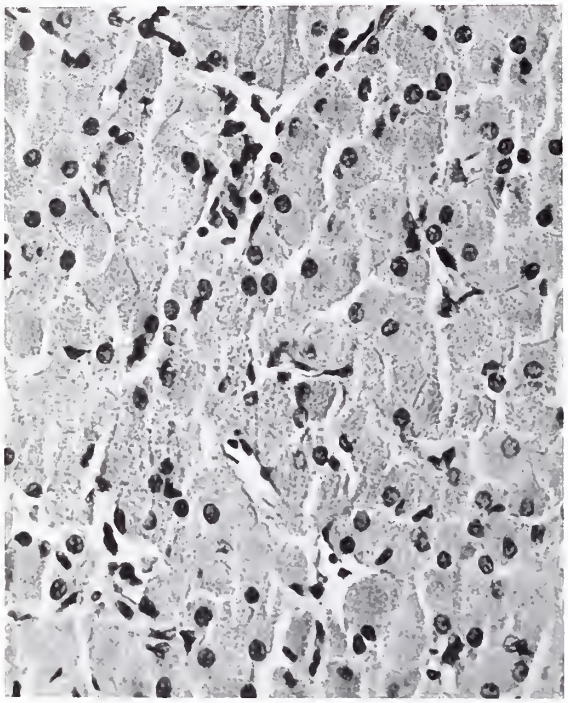

CHORISTOMA OF THE NEUROHYPOPHYSIS

(Figures 299–301 from same case)

Figure 301. This is the microscopic picture of the tumor in the two preceding figures. Similar foci were found in the infundibular process (pars nervosa of the pituitary) of this patient. × 265.

Occasionally larger examples occur that may press upon the optic chiasm, cause bitemporal hemianopsia or optic atrophy, or invade the floor of the third ventricle. Because of the presence of cytoplasmic granules that are positive both with PTAH and PAS, they have been called "myoblastomas" by analogy with the "granular myoblastomas" found elsewhere in the body (Burston et al.). The nature of the cells from which choristomas originate remains enigmatic, but it is probable that they are derived from pituicytes, in other words modified astrocytes. This view is supported by the finding of similar cells in tumors arising in the infundibular region that have been designated by their observers as "pituicytomas" (Liss and Kahn). In a small pilocytic astrocytoma that occupied the infundibular process (pars nervosa) of a 55-year-old woman, I have seen typical nests of these "choristoma cells" that contained PAS positive granules.

References

Burston, J., John, R., and Spencer, H. "Myoblastoma" of the neurohypophysis. J. Path. Bact. 83:455–461, 1962.

Liss, L., and Kahn, E. A. Pituicytoma. Tumor of the sella turcica. A clinicopathological study. J. Neurosurg. 15:481–488, 1958.

DYSGENETIC SYNDROMES (PHACOMATOSES) ASSOCIATED WITH TUMORS OR TUMOR-LIKE MALFORMATIONS OF THE NERVOUS SYSTEM

The phacomatoses constitute a group of diseases characterized by widespread maldevelopmental disorders affecting many systems, but including always a combination of lesions in the central or peripheral nervous systems or their coverings with abnormalities in the visceral organs and frequently the skin. Because of the latter the name "neurocutaneous diseases" is sometimes used, but this appellation is too restrictive. Many of the conditions under this heading are genetically determined and familial. Numerous forms, many of which are eponymic, have been described, but this section will deal solely with those in which an association with tumors or tumor-like malformations in the central nervous system or its coverings forms an essential part of the pathologic picture. The diseases comprise the tuberous sclerosis complex, von Recklinghausen's neurofibromatosis, melanoma of the leptomeninges and neurocutaneous melanosis, von Hippel-Lindau disease, and Sturge-Weber's disease.

TUBEROUS SCLEROSIS

This condition, clinically characterized by mental deficiency, epilepsy, and adenoma sebaceum, has a well known familial incidence (Ross and Dickerson). The full spectrum of the pathologic picture includes, aside from a number of characteristic cutaneous lesions ("peau de chagrin," subungual fibromas, adenoma sebaceum, cutaneous molluscum), widespread structural anomalies of the central nervous system, visceral tumors of a hamartomatous nature (rhabdomyomas, angiofibrolipomas) involving most frequently the myocardium and kidney, and small retinal tumors, usually astrocytic. Many cases, however, show the incomplete form *(forme fruste)* of the disease (Critchley and Earl).

The central nervous system lesions consist of widespread abnormalities of the cytoarchitecture, with loss of normal cortical lamination and the presence of highly bizarre giant neurons with considerable atypia of their cell processes (fig. 302). Superficial foci of cortical gliosis containing abnormal neuronal and glial cells, known as cortical tubers, and small subependymal, frequently calcified nodules consisting of elongated fibrillated and gemistocytic astrocytes, termed candle gutterings, are characteristic. In addition nests of atypical large rounded glial cells with an abundant eosinophilic cytoplasm, eccentric nuclei, and prominent nucleoli may be present throughout the cortex and white matter (fig. 303).

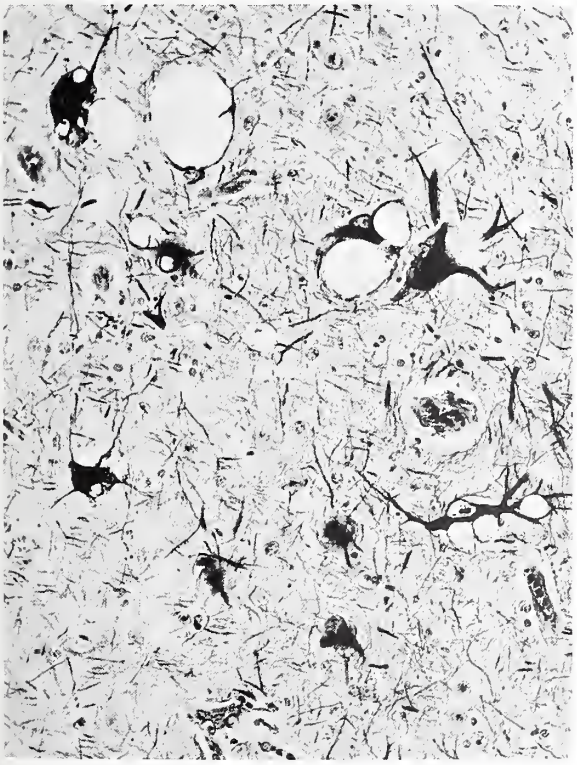

TUBEROUS SCLEROSIS

Figure 302. Giant abnormal neurons are seen in the cortical tuber of an 11-year-old girl with mental retardation and intractable epilepsy. Note the cytoplasmic vacuolations in the abnormal neurons. Bielschowsky preparation on paraffin. × 165.

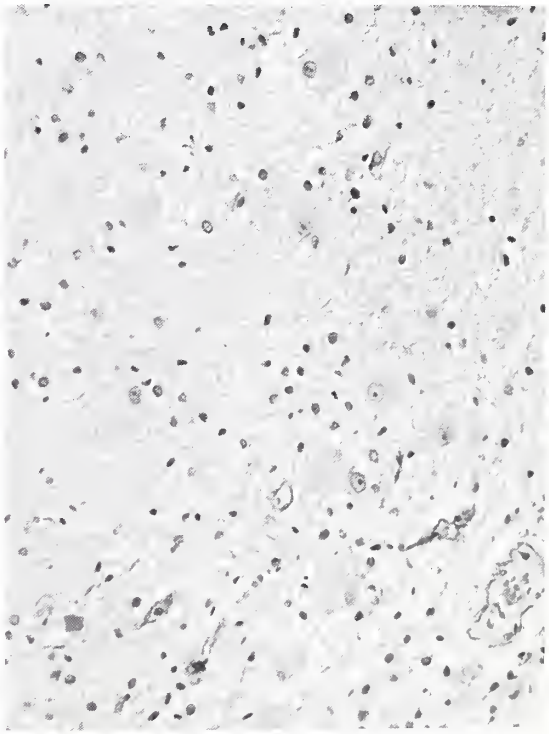

GLIAL ECTOPIAS IN WHITE MATTER IN TUBEROUS SCLEROSIS

Figure 303. Atypical glial cells with eccentric nuclei and prominent nucleoli are scattered in the white matter of a case of tuberous sclerosis. A large paraventricular giant cell astrocytoma was present in the vicinity. × 200.

The association of brain tumors is well known in this disease, but they are relatively rare in the syndrome as a whole. Characteristically these neoplastic lesions are composed of giant cell astrocytes, grow slowly, and are benign but they may cause hydrocephalus by obstructing the foramen of Monro (p. 40; figs. 22, 23). They seem to originate in most cases from the small foci of subependymal giant astrocytes characteristic of the condition, and are therefore mostly subependymal and intraventricular.

Occasionally other forms of glioma have been reported, including malignant giant cell tumors resembling glioblastomas (Jervis), ependymomas (Norman and Taylor), and diffuse gliomatosis of the cerebral hemisphere and brainstem (Dretler). Replacement of a cerebral hemisphere by a large ganglioglioma tous neoplasm, essentially in the nature of a malformation, has also been described (Jervis; Davis and Nelson).

References

Critchley, M., and Earl, C. J. C. Tuberose sclerosis and allied conditions. Brain 55:311–346, 1932.

Davis, R. L., and Nelson, E. Unilateral ganglioglioma in a tuberosclerotic brain. J. Neuropath. Exp. Neurol. 20:571–581, 1961.

Dretler, J. Uber eine Diffuse, ausgereifte—durch abortive tuberöse Sklerose komplizierte—Hirngeschwulst. Dtsch. Z. Nervenheilk. 148:84–106, 1938.

Jervis, G. A. Spongioneuroblastoma and tuberous sclerosis. J. Neuropath. Exp. Neurol. 13:105–116, 1954.

Norman, R. M., and Taylor, A. L. Congenital diverticulum of the left ventricle of the heart in a case of epiloia. J. Path. Bact. 50:61–68, 1940.

Ross, A. T., and Dickerson, W. W. Tuberous sclerosis. Arch. Neurol. 50:233–257, 1943.

VON RECKLINGHAUSEN'S NEUROFIBROMATOSIS

This well known and relatively common condition is conveniently divided into three forms which usually present distinctive clinical and pathologic features:

(1) A **peripheral form**, characterized by large numbers of peripheral and subcutaneous nerve sheath tumors, associated with multiple cutaneous café-au-lait patches.

(2) A **central** form, consisting of multiple intracranial and intraspinal tumors that arise from the central nervous system parenchyma, its coverings, and the cranial and spinal nerve roots.

(3) A **visceral** form, in which ganglioneuromas and nerve sheath tumors predominantly involve the viscera and the autonomic nervous system, and may be associated with other visceral neoplasms derived from the neural crest, such as peripheral neuroblastomas, adrenal ganglioneuromas, and pheochromocytomas.

Although some overlap exists between these different forms, it is characteristic that patients with the peripheral variant very seldom show the central manifestations of the disease, and, conversely, patients with the central form usually exhibit few or none of its peripheral stigmata. However, all variants will manifest themselves indiscriminately in members of the same family.

The peripheral and visceral forms of von Recklinghausen's disease, with a detailed consideration of the peripheral nerve sheath tumors (schwannomas and neurofibromas) that make up the basis of this disorder, are described and illustrated in the fascicle, "Tumors of the Peripheral Nervous System" by Harkin and Reed. The pathologic features of acoustic schwannomas, which are typical of the central form of von Recklinghausen's disease, are separately treated on page 206 of this fascicle. This section is concerned solely with a brief and general review of the neoplastic and hamartomatous lesions that involve the central nervous system and its coverings in **central** neurofibromatosis; a detailed

analysis of personally examined material comprising 11 such cases has been published elsewhere (Rubinstein).

Tumors in Central Neurofibromatosis

In contrast to patients with the peripheral form, those with the central form constitute a considerably younger age group; most cases come to autopsy in the second and third decades. The tumors that involve the cranial and spinal nerve roots are almost invariably multiple. They are usually **schwannomas.** A typical feature is the incidence of **bilateral acoustic schwannomas,** which in some cases may be the sole feature of the disease, yet may be transmitted in the same family as a mendelian dominant (Gardner and Turner; Moyes). Commonly associated with nerve sheath neoplasms, cranial and spinal **meningiomas,** again usually multiple, are characteristic; also the choroid plexuses appear to be involved with unusual frequency (pl. VI-B).

The gliomas commonly found in this disease are of two kinds: **pilocytic astrocytomas** of the third ventricle of juvenile type (pp. 22, 34), and **ependymomas,** which are often multiple and usually situated in the spinal cord (figs. 114, 115), although the brainstem is occasionally involved. Exceptionally, diffuse gliomas have been reported implicating the cerebral hemisphere, cerebellum, or spinal cord (Russell and Rubinstein). The occurrence of fourth ventricle pilocytic astrocytomas ("spongioblastomas") in identical twins with a family history of neurofibromatosis has been recorded (Brady). Another characteristic glioma associated with the disease is the **optic nerve glioma** (Davis; see also the fascicle "Tumors of the Eye and Adnexa" by Reese). **Retinal** astrocytic tumors, occasionally bilateral, have been documented (Saran and Winter). Hyperplasia of the optic nerve, falling short of glioma formation and sometimes unilateral, has also been described (Spencer and Borit). Further details on the incidence of primary intracranial tumors in von Recklinghausen's neurofibromatosis will also be found in the paper by Rodriguez and Berthrong.

Hamartomas in Central Neurofibromatosis

In addition to these neoplasms, the central form of von Recklinghausen's disease may display characteristic malformative lesions that are in the nature of **hamartomas.** These are often microscopic and differ from those found in tuberous sclerosis (compare figs. 303, 304). They are frequently

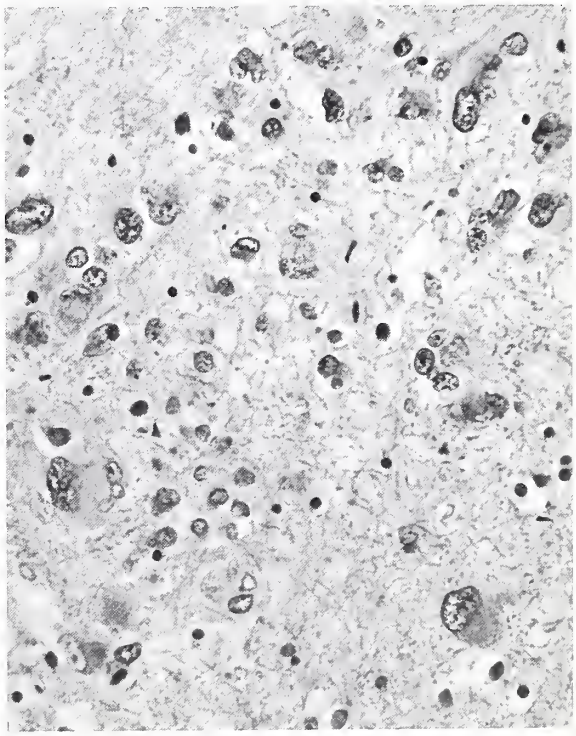

CENTRAL FORM OF VON RECKLINGHAUSEN'S NEUROFIBROMATOSIS

(Figures 304, 305, and 313 from same case)

Figure 304. Glial cortical heterotopias are seen in a case of central neurofibromatosis. PTAH. × 340.

found in association with the tumors previously described and may involve the neuroglia, blood vessels, meningeal cells, or ectopically located Schwann cells.

The malformations affecting the glia consist mostly of nests of **pleomorphic atypical glial** cells with prominent enlarged, frequently notched nuclei, often of giant form and showing irregular hyperchromatism (fig. 304). They are not associated with any obvious disorder of cortical lamination. Cilia and blepharoplasts are often found in the cytoplasm of these cells (fig. 305); presumably they are vestigial, or indicative of abnormality in the centriolar system. These cells are mostly encountered in the cerebral cortex, but may also be seen occasionally in the basal ganglia and spinal cord. They are often closely associated with the meningiomatous cortical malformations to be described. They have been thought to be a possible source of origin for the associated malignant hemispheric gliomas with the features of glioblastoma multiforme that have occasionally been reported (Taylor).

Another form of glial abnormality, apparently less specific for neurofibromatosis than the others and also found in tuberous sclerosis, consists of highly fibrillated **subependymal** nodules in which elongated pilocytic astrocytes are arranged tangentially to the ventricular surface (fig. 306). It is possible that these astrocytic foci are the source of origin of some of the large fibrillary astrocytomas found in the disease. These subependymal granulations may also cause stenosis of the aqueduct of Sylvius and internal hydrocephalus. Other irregular neuroglial proliferations may be found in which fibrillated glial cells are seen to invade focally the leptomeninges or the Virchow-Robin spaces (fig. 307).

CENTRAL NEUROFIBROMATOSIS
CILIA IN DYSPLASTIC GLIA

Figure 305. Under high power four cilia are seen in the cytoplasm of an atypical glial cell in the cerebral cortex. PTAH. × 1360.

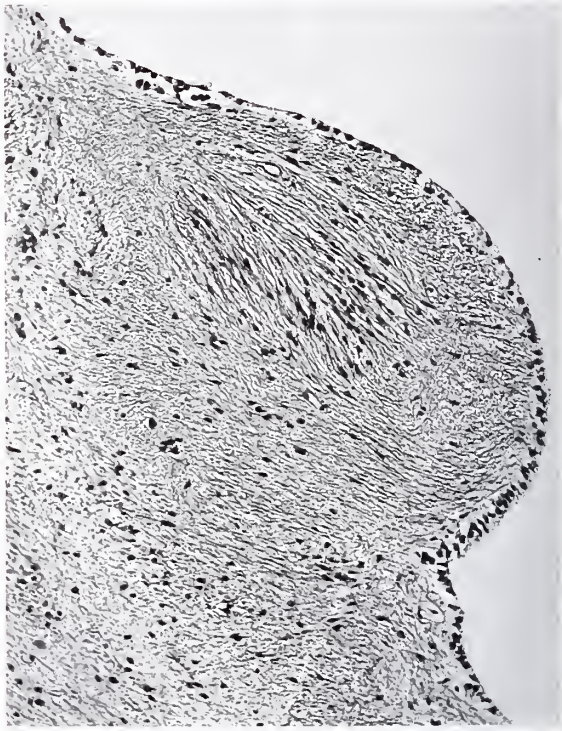

CENTRAL LESIONS IN
VON RECKLINGHAUSEN'S
NEUROFIBROMATOSIS

(Figures 306 and 307 from same case)

Figure 306. This fibrillated subependymal nodule was present in the fourth ventricle of a 50-year-old woman with the peripheral form of neurofibromatosis. × 130.

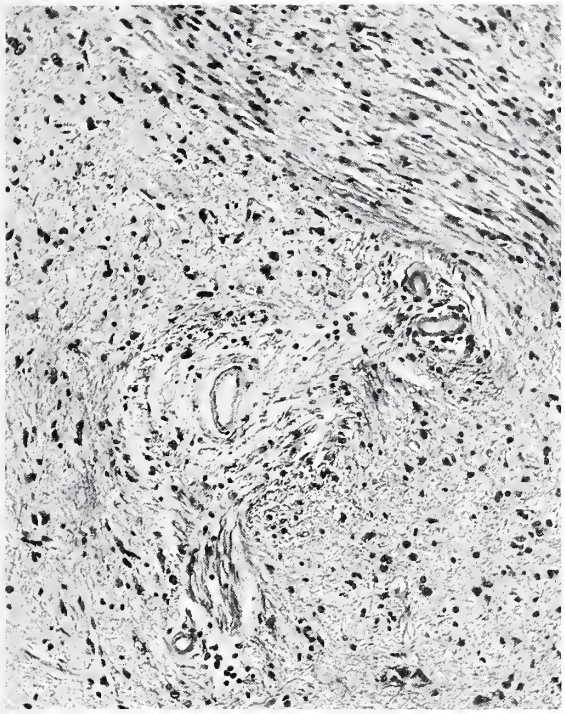

CENTRAL LESIONS IN THE PERIPHERAL FORM OF VON RECKLINGHAUSEN'S NEUROFIBROMATOSIS

(Figures 306 and 307 from same case)

Figure 307. Adjacent to the subependymal nodule illustrated in the previous figure, the region of the locus ceruleus shows this proliferation of elongated and highly fibrillated neuroglia forming intersecting bundles across the neural parenchyma (right upper corner). Note the focal invasion of the Virchow-Robin spaces by neuroglial tissue (center). × 130.

Other ectopic glial foci consist of discrete collections of cells with oval or spheroidal nuclei, with the morphology of ependymal cells (fig. 308); groups of blepharoplasts can again frequently be demonstrated adjacent to the nuclei (fig. 309). These nests most frequently appear in the spinal cord and are often found in association with multiple spinal intramedullary ependymomas. They may be the source of some of these neoplasms as suggested in figure 310, which illustrates a microscopic ependymoma abutting on the surface of the spinal cord and obviously ectopic in origin.

Another characteristic feature of central neurofibromatosis is illustrated in plate IX-F. It is termed **meningiomatosis**, or **meningioangiomatosis** (Worster-Drought et al.), and is often associated with multiple meningiomas. Grossly the cortex may present as an indurated plaque. Microscopically it consists in a diffuse but topographically restricted infiltration of the gray matter by

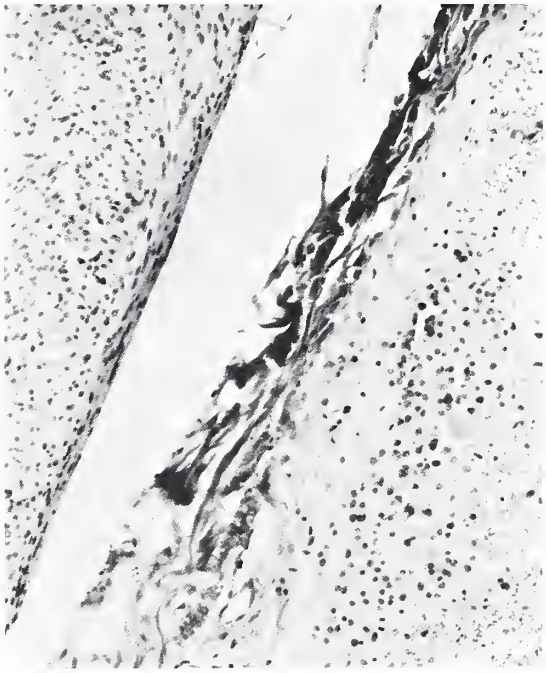

CENTRAL NEUROFIBROMATOSIS. ECTOPIC EPENDYMAL CELLS IN SPINAL CORD

Figure 308. Nests of ectopic ependymal cells are shown in the marginal layer of the spinal cord (right part of field). The left upper corner is occupied by a schwannoma of the dorsal nerve root. van Gieson. × 130. (Fig. 18 from Rubinstein, L. J. Tumeurs et hamartomes dans la neurofibromatose centrale. In: Les Phakomatoses Cérébrales. (Eds.) Michaux, L., and Feld, M. S.P.E.I. Editeurs, Paris, 1963).

arrays of psammomatous meningeal elements that appear to grow along, or even be incorporated among, an intersecting stroma of greatly thickened blood vessels.

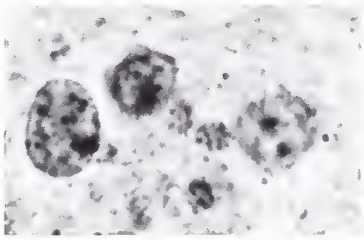

CENTRAL NEUROFIBROMATOSIS
ECTOPIC EPENDYMAL CELLS

Figure 309. Two small groups of blepharoplasts (center) separate two nuclei in a nest of ectopic ependymal cells in the basal ganglia. PTAH. × 1440. (Fig. 19 from Rubinstein, L. J. Tumeurs et hamartomes dans la neurofibromatose centrale. In: Les Phakomatoses Cérébrales. (Eds.) Michaux, L., and Feld, M. S.P.E.I. Editeurs, Paris, 1963).

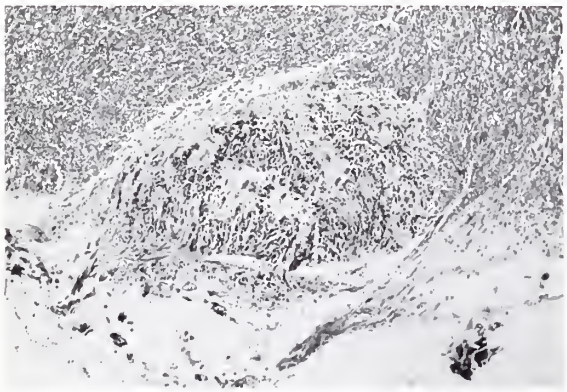

CENTRAL NEUROFIBROMATOSIS
MICROSCOPIC ECTOPIC
SPINAL EPENDYMOMA

Figure 310. A microscopic ependymoma abuts onto the surface of the spinal cord near a ventral nerve root at the fifth cervical level. The location of this tumor indicates its malformative origin. van Gieson. × 38. (Fig. 8 from Rubinstein, L. J. Tumeurs et hamartomes dans la neurofibromatose centrale. In: Les Phakomatoses Cérébrales. (Eds.) Michaux, L., and Feld, M. S.P.E.I. Editeurs, Paris, 1963).

Certain areas resemble a transitional or fibroblastic meningioma, others are somewhat reminiscent of a schwannoma. They occur most frequently in the cerebral cortex and may be multiple, but occasionally the basal ganglia or cerebral peduncle are involved. Occasionally angiomatous malformations may also be found in the overlying leptomeninges (fig. 311). A variant of this anomaly is a simple **cortical angiomatosis** without meningeal involvement, consisting in a focal infiltration of the neural parenchyma by a collection of thick-walled, fibrosed, and hyalinized blood vessels.

Another type of hamartoma seems to affect the Schwann cell elements. Aside from the common proliferations of Schwann cells along the blood vessels, resembling miniature traumatic neuromas, which may be due to a regenerative reaction of peripheral nerve elements secondary to lesions in the spinal cord, there are other proliferations sometimes referred to as **schwannosis** of the central nervous system. These consist of irregular extensions of Schwann cells within the spinal cord parenchyma, usually at the site of entrance of a dorsal nerve root (figs. 312, 313). These apparently displaced intramedullary Schwann cells are almost invariably adjacent to a schwannomatous nodule of the corresponding dorsal root. In addition, small microscopic proliferations of Schwann cells are often found on examination of the spinal or cranial nerve roots, and may again constitute a form of "schwannosis" (fig. 314).

Another well known associated abnormality in the central nervous system is **syringomyelia** (Poser; Rodriguez and Berthrong).

The incidence of these hamartomatous lesions in the central form of von Recklinghausen's disease, discussed in further detail

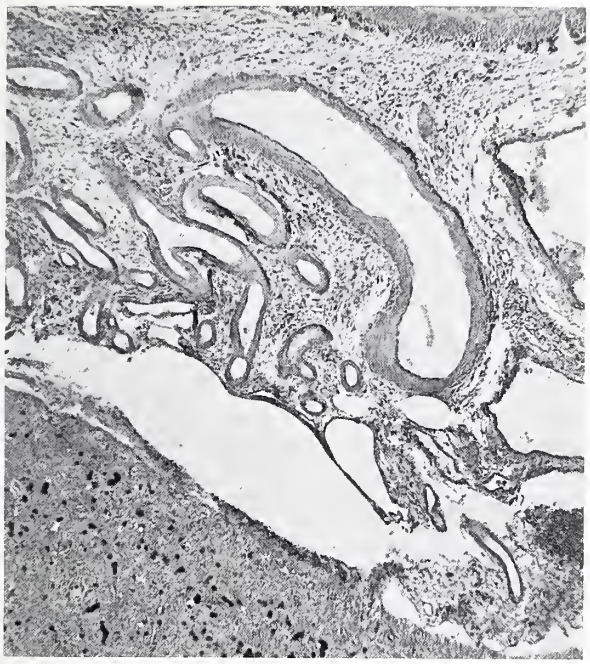

CENTRAL NEUROFIBROMATOSIS ARTERIOVENOUS MALFORMATION

(Figure 311 and Plate X-F from same case)

Figure 311. An arteriovenous malformation in the leptomeninges overlies a focus of meningio-angiomatosis (lower left) with calcifications. × 26.

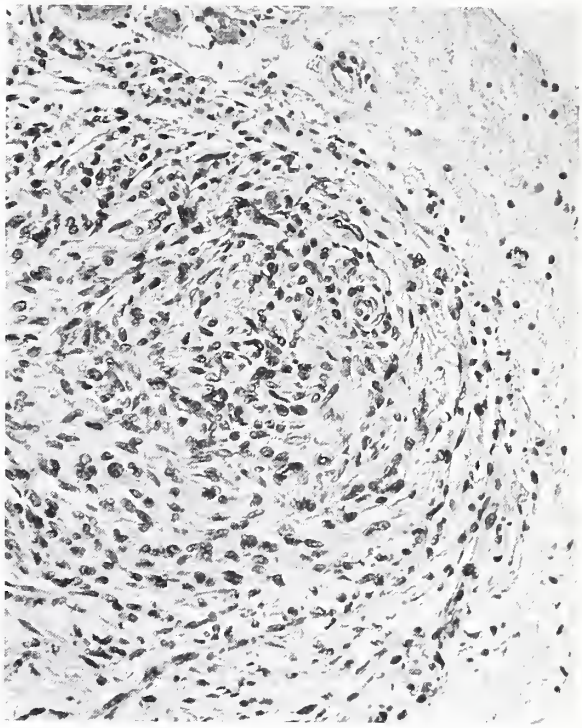

CENTRAL NEUROFIBROMATOSIS INTRAMEDULLARY SCHWANNOSIS

(Figures 114, 115, 222, 223, 312, 314, and Plate VI-B from same case)

Figure 312. A collection of Schwann cells form whorls in the parenchyma of the spinal cord near the entrance of a dorsal nerve root. × 200.

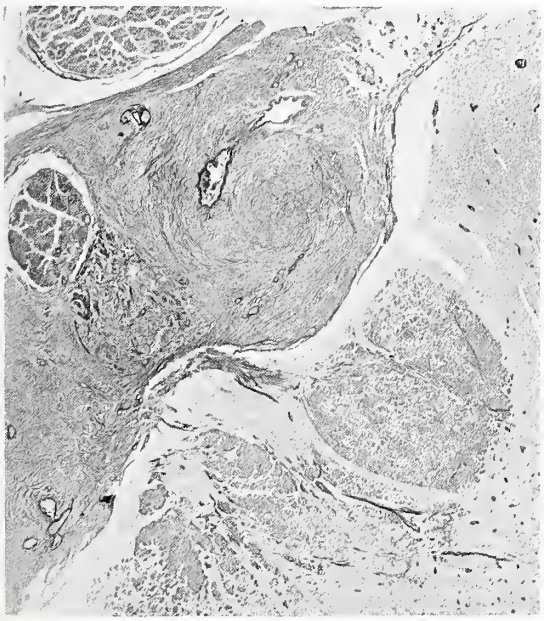

Fig. 313

CENTRAL NEUROFIBROMATOSIS INTRAMEDULLARY SCHWANNOSIS

(Figures 304, 305, and 313 from same case)

Figure 313. The low power view of this reticulin preparation shows foci of intramedullary schwannosis near the site of entrance of a dorsal nerve root (lower right). The adjacent extramedullary nerve root is partly replaced by a schwannoma. Silver stain for reticulin. × 23. (Fig. 18 from Russell, D. S., and Rubinstein, L. J. Pathology of Tumours of the Nervous System, 3d ed. London: Edward Arnold, 1971).

elsewhere (Rubinstein), is remarkably high; they were seen in 10 of 13 cases I have studied. They are extremely rare in the peripheral form (figs. 306, 307); the small subependymal fibrillary nodule in figure 306 was one of several along the fourth ventricle and the aqueduct of a 50-year-old woman who had multiple peripheral neurofibromas associated with a pheochromocytoma.

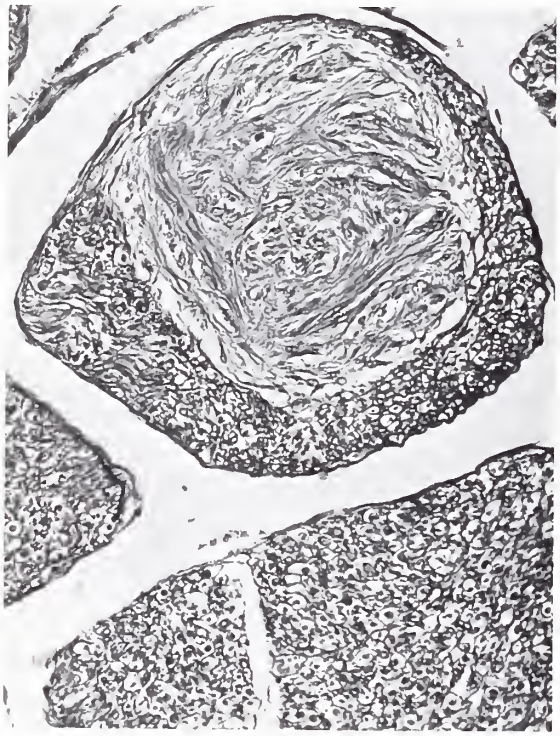

CENTRAL FORM OF VON RECKLINGHAUSEN'S NEUROFIBROMATOSIS

(Figures 114, 115, 222, 223, 312, 314, and Plate VI-B from same case)

Figure 314. This microscopic schwannomatous nodule was found in the dorsal nerve root of a 17-year-old girl with central neurofibromatosis. The patient had multiple meningiomas, schwannomas, and intramedullary ependymomas. PTAH. × 175. (Fig. 27 from Rubinstein, L. J. Seminario de Neuropatologia, Mérida, Yucatán, Bol. Asoc. Mex. Patol., A. C., 7:13–59, 1969).

In contradistinction to the lesions found in tuberous sclerosis, the structural dysplastic anomalies involving the central nervous system in the central form of von Recklinghausen's disease most often implicate the neuroglial elements. Tumors of ganglionic origin invariably seem to originate from the peripheral neurons, and I am not aware of any well documented central ganglionic tumor in this malady. However, the careful examination of brains from patients with the disease, especially those in whom some degree of mental retardation was present, has disclosed a number of cytoarchitectonic abnormalities which may conceivably form the morphologic basis of the mental retardation in these cases (Rosman and Pearce).

References

Brady, W. J. Brain stem gliomas causing hydrocephalus in twins with von Recklinghausen's disease. J. Neuropath. Exp. Neurol. 21:555–565, 1962.

Davis, F. A. Primary tumors of the optic nerve (a phenomenon of Recklinghausen's disease). A clinical and pathologic study with a report of five cases and a review of the literature. Arch. Ophth. 23:735–821, 957–1022, 1940.

Gardner, W. J., and Turner, O. Bilateral acoustic neurofibromas: further clinical and pathological data on hereditary deafness and Recklinghausen's disease. Arch. Neurol. 44:76–99, 1940.

Harkin, J. C., and Reed, R. J. Tumors of the Peripheral Nervous System, Fascicle 3, Atlas of Tumor Pathology. Washington: Armed Forces Institute of Pathology, 1969.

Moyes, P. D. Familial bilateral acoustic neuroma affecting 14 members from four generations. Case report. J. Neurosurg. 29:78–82, 1968.

Poser, C. M. The Relationship Between Syringomyelia and Neoplasm. Springfield, Ill.: Charles C Thomas, 1956.

Reese, A. B. Tumors of the Eye and Adnexa, Fascicle 38, Atlas of Tumor Pathology. Washington: Armed Forces Institute of Pathology, 1956.

Rodriguez, H. A., and Berthrong, M. Multiple primary intracranial tumors in von Recklinghausen's neurofibromatosis. Arch. Neurol. 14:467–475, 1966.

Rosman, N. P., and Pearce, J. The brain in multiple neurofibromatosis (von Recklinghausen's disease): A suggested neuropathological basis for the associated mental defect. Brain 90:829–838, 1967.

Rubinstein, L. J. Tumeurs et Hamartomes dans la Neurofibromatose Centrale. In: Les Phakomatoses Cérébrales. (Eds.) Michaux, L., and Feld, M. Paris: S.P.E.I. Editeurs, 1963.

Russell, D. S., and Rubinstein, L. J. Pathology of Tumours of the Nervous System, 3d ed. London: Edward Arnold, 1971.

Saran, N., and Winter, F. C. Bilateral gliomas of the optic discs associated with neurofibromatosis. Amer. J. Ophthal. 64:607–612, 1967.

Spencer, W. H., and Borit, A. Diffuse hyperplasia of the optic nerve: in von Recklinghausen's disease. Amer. J. Ophthal. 64:638–642, 1967.

Taylor, P. E. Encapsulated glioma of the sylvian fissure associated with neurofibromatosis. Report of a case with histopathological comparison of surgical lesion and autopsy specimen following recurrence. J. Neuropath. Exp. Neurol. 21:566–578, 1962.

Worster-Drought, C., Carnegie Dickson, W. E., and McMenemey, W. H. Multiple meningeal and perineural tumours with analogous changes in the glia and ependyma (neurofibroblastomatosis). With report of two cases. Brain 60:85–117, 1937.

VON HIPPEL-LINDAU DISEASE

This syndrome is classically associated with single or multiple capillary hemangioblastomas of the nervous system and is discussed on page 235.

STURGE-WEBER DISEASE (ENCEPHALOTRIGEMINAL ANGIOMATOSIS)

This condition is characterized by the association of facial vascular nevi in the distribution of the trigeminal nerve, intracranial calcification, and leptomeningeal venocapillary angiomatosis and is described on page 255.

NEUROCUTANEOUS MELANOSIS AND PRIMARY MENINGEAL MELANOMA

Melanoblasts are normally found in the pia mater, being usually most numerous on the ventral aspect of the lower medulla. These cells are presumably the source of melanomas that originate in the central nervous system. The disorders span the full range from a simple increased pigmentation of the leptomeninges to the development of highly malignant neoplasms. Some forms are associated with pigmented cutaneous nevi. Although many transitional examples are recognized (figs. 315, 316), the condition is usually divided into the following variants:

A rare form of nonneoplastic diffuse pigmentation of the leptomeninges associated with cutaneous pigmented nevi (**neurocutaneous pigmentation**) is known to exist as a familial condition (Touraine).

Neurocutaneous melanosis is a nonfamilial disease in which diffuse and often frankly invasive (fig. 316) proliferation of melanin-containing cells occurs throughout the leptomeninges and is associated with giant cutaneous nevi (Hoffman and Freeman; Slaughter et al.). Some examples are found at birth and most occur in infants under two years of age. The extensive involvement of the basal leptomeninges may produce internal hydrocephalus. Cases of meningeal melanosis have also been associated with widespread peripheral neurofibromas.

This condition is further described and illustrated in the fascicle "Tumors of the Peripheral Nervous System" by Harkin and Reed.

Primary meningeal melanoma (Gibson et al.; Pappenheim and Bhattacharji) may or may not be associated with cutaneous nevi, and may present either as a circumscribed tumor or a diffuse neoplastic process involving wide areas of the leptomeninges (fig. 315). Occasionally the growth remains circumscribed and relatively benign; more often it is cytologically malignant with many mitotic figures, and frequently spreads extensively through the cerebrospinal fluid

MELANOMATOSIS OF THE LEPTOMENINGES

Figure 315. Diffuse leptomeningeal melanomatosis unassociated with cutaneous nevi was found in a 22-month-old boy. Multiple pigmented foci of melanosis are present in the gray matter. (Courtesy of Dr. K. M. Earle, Washington, D. C.; also fig. 9 from Slaughter, J. C., Hardman, J. M., Kempe, L. G., and Earle, K. M. Neurocutaneous melanosis and leptomeningeal melanomatosis in children. Arch. Path. 88:298-304, 1969).

pathways (fig. 316). Usually it clearly arises from the leptomeninges, but occasionally it seems to originate primarily as an intracerebral or intramedullary mass. Even then it is presumably of pial origin. Those that present primarily within the parenchyma of the spinal cord have been reviewed by Hirano and Carton.

The prognosis of meningeal melanomas is poor and most patients die within 12 months. There is no evidence that the tumor is radiosensitive.

The acceptance of these tumors as primarily leptomeningeal must depend on the rigorous exclusion of alternative primary sites, since it is well known that a small unrecognized primary cutaneous melanoma may be the source of extensive visceral and central nervous system metastases. The age incidence is somewhat different, however; most instances of primary cutaneous malignant melanoma are found in the seventh decade, whereas the major peak of incidence of leptomeningeal melanomas lies in the fourth, and a fairly high proportion are encountered in the first two decades. However, here too the interpretation calls for caution, because children with extensive cutaneous nevi have an incidence of melanoma in over 10 percent of cases, and these tumors are then apt to metastasize widely and involve the central nervous system in the process.

As previously noted on page 184, some meningiomas may contain melanin granules in both the meningeal cells and the macrophages, and this may occasionally be a diagnostic problem in the differentiation from a primary or metastatic melanoma. Usually, however, the morphologic charac-

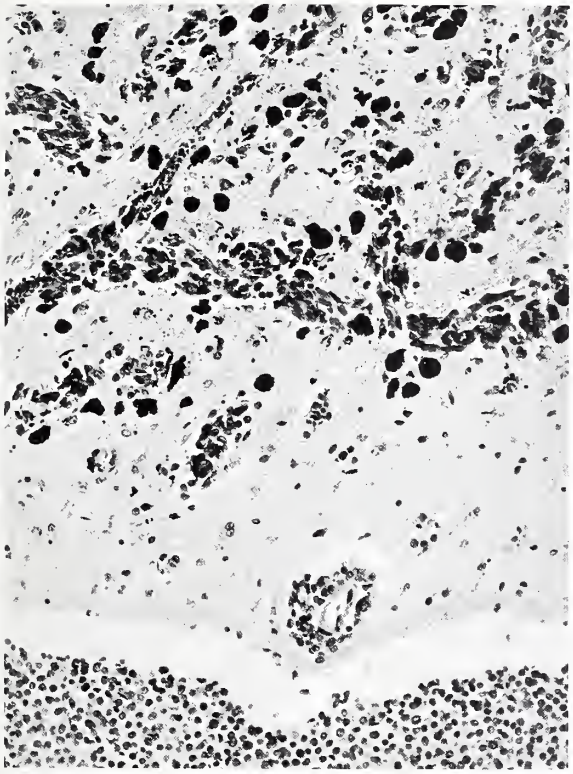

Fig. 316

NEUROCUTANEOUS MELANOSIS WITH MALIGNANT MELANOMATOSIS OF THE LEPTOMENINGES

Figue 316. Melanoma cells are shown in the subarachnoid and perivascular spaces, and infiltrate the adjacent parenchyma in a case of primary meningeal melanomatosis. This 8-year-old boy began to have fits of petit mal from the age of eight months, followed later by convulsions. He also had hydrocephalus, which was temporarily relieved by shunting procedures. The skin over the entire body contained numerous flat, hair-bearing, brown, well circumscribed nevi. An extensive confluent glistening gray melanotic tumor was found to spread around the inferior surface of the brain. Numerous foci were scattered throughout the brain, spinal cord, and nerve roots. × 165.

ter of the pigmented meningioma is sufficiently clear-cut to establish the diagnosis.

Finally the possibility that a primary malignant melanoma of the leptomeninges might itself metastasize outside the central nervous system should be considered, but such an interpretation can be admitted only after the most stringent elimination of a potential cutaneous, ocular, or visceral primary. An acceptable example has been described by Salm, in a 43-year-old woman in whom a melanoma arose in the cerebellum and metastasized to the cerebral hemispheres and the lungs; in this case a meticulous necropsy excluded an alternative primary site.

References

Gibson, J. B., Burrows, D., and Weir, W. P. Primary melanoma of the meninges. J. Path. Bact. 74:419–438, 1957.

Harkin, J. C., and Reed, R. J. Tumors of the Peripheral Nervous System, Fascicle 3, Atlas of Tumor Pathology. Washington: Armed Forces Institute of Pathology, 1969.

Hirano, A., and Carton, C. A. Primary malignant melanoma of the spinal cord. J. Neurosurg. 17: 935–944, 1960.

Hoffman, H. J., and Freeman, A. Primary malignant leptomeningeal melanoma in association with giant hairy nevi. Report of two cases. J. Neurosurg. 26:62–71, 1967.

Pappenheim, E., and Bhattacharji, S. K. Primary melanoma of the central nervous system. Arch. Neurol. 7:101–113, 1962.

Salm, R. Primary malignant melanoma of the cerebellum. J. Path. Bact. 94:196–200, 1967.

Slaughter, J. C., Hardman, J. M., Kempe, L. G., and Earle, K. M. Neurocutaneous melanosis and leptomeningeal melanomatosis in children. Arch. Path. 88:298–304, 1969.

Touraine, A. Les mélanoses neuro-cutanées. Ann. Derm. Syph. 9:489–524, 1949.

NIH LIBRARY

SECONDARY TUMORS OF THE CENTRAL NERVOUS SYSTEM

The central nervous system and its coverings may be involved by secondary tumors, either by local extension or as a result of bloodborne dissemination.

DIRECT EXTENSION OF LOCAL TUMORS

PITUITARY ADENOMAS

The pathology of these tumors is described in detail in the fascicle, "Tumors of the Pituitary Gland and Infundibulum" by Kernohan and Sayre. Only those aspects related to secondary involvement of the central nervous system will be mentioned here.

Pituitary adenomas, especially the chromophobe variety, have a notorious tendency to spread beyond the confines of the sella turcica and to invade the hypothalamic region, the cavity of the third ventricle, the frontal or temporal lobe, and in some instances even the posterior fossa. These neoplasms may spread in this manner relatively silently at first, and therefore present clinically as deep intracerebral space-occupying lesions from which often only a small biopsy may be obtained. In the absence of information that draws attention to the pituitary fossa and in cases in which little or no endocrine dysfunction is apparent, such a biopsy may trap the unwary into the diagnosis of a primary neuroglial tumor. The most characteristic histologic pattern of the chromophobe pituitary adenoma is either sinusoidal, or papillary (fig. 317), or of a more diffuse type in which homogeneous masses of pale cells with well defined cytoplasmic membranes are intersected by a delicate connective tissue stroma (fig. 318). The two patterns are frequently found side by side within the same tumor: the sinusoidal pattern may, because of the perivascular arrangement of the tumor cells, invite suspicion of an astroblastoma or an ependymoma; and the diffuse pattern may closely mimic that of an oligodendroglioma.

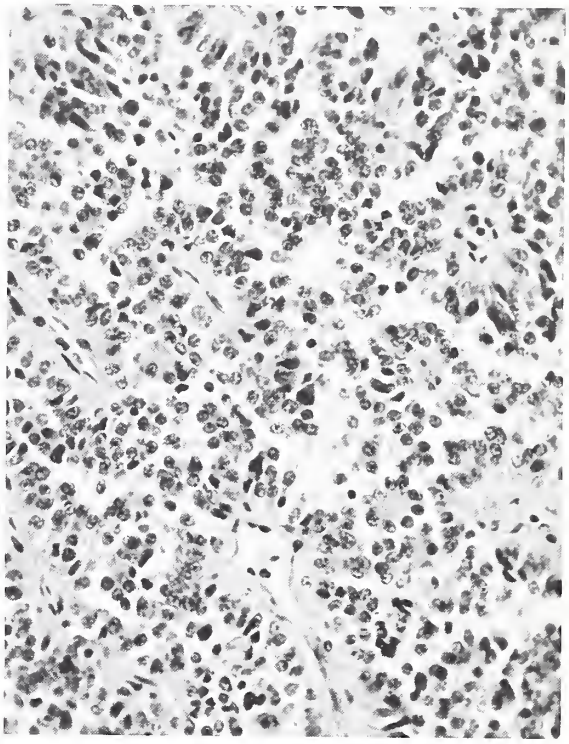

CHROMOPHOBE PITUITARY ADENOMA

Figure 317. A typical sinusoidal, or papillary, pattern is seen in this chromophobe pituitary adenoma. × 265.

Pituitary adenomas may occasionally develop multiple separate subdural nodules in the cranial cavity. This may be associated with moderate cytologic atypia of the tumor

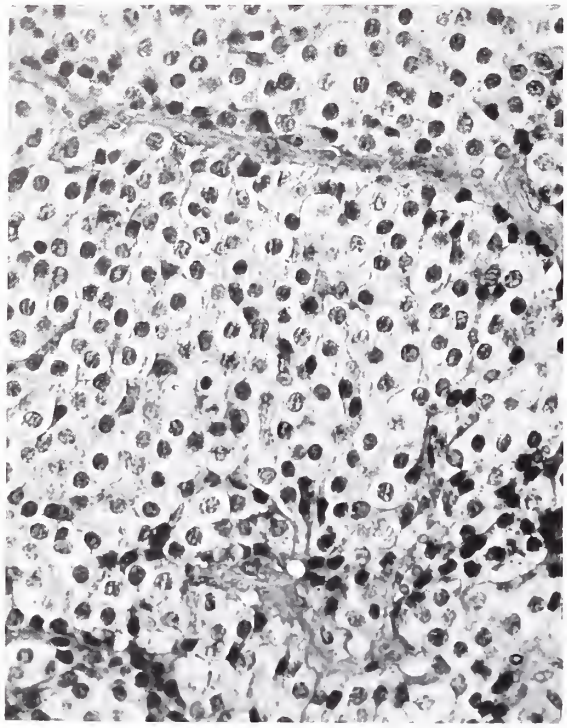

CHROMOPHOBE PITUITARY ADENOMA

Figure 318. A diffuse cellular pattern is shown in this chromophobe pituitary adenoma, mimicking an oligodendroglioma. × 350.

cells, and sometimes mitotic figures; it has been noted especially in recurrent tumors that may extend over a period of years. The local invasive propensities of pituitary adenomas are well known and, like meningiomas, they are apt to infiltrate the dura and the adjacent venous sinuses. The term "invasive adenoma" is sometimes given to this development and it is probably more correct than the designation of "carcinoma of the pituitary." Endocrine tumors are of course notorious in their tendency to show cellular pleomorphism, nuclear hyperchromatism, and local venous permeation; yet these features are not usually equated with clinical malignancy. Occasionally also, cells from a pituitary adenoma may disseminate in the cerebral subarachnoid space (Madonick et al.). But neither this event, nor the atypical cytologic features that are sometimes found in rapidly growing pituitary adenomas, nor the occasional development of distinct subdural or subarachnoid nodules some distance away from the main mass are sufficient to warrant the diagnosis of malignant tumor. This diagnosis should be reserved for those exceptional cases sometimes associated with Cushing's syndrome, in which infiltration of the adjacent structures results in the development of metastases outside the central nervous system (Scholz et al.).

References

Kernohan, J. W., and Sayre, G. P. Tumors of the Pituitary Gland and Infundibulum, Fascicle 36, Atlas of Tumor Pathology. Washington: Armed Forces Institute of Pathology, 1956.

Madonick, M. J., Rubinstein, L. J., Dacso, M. R., and Ribner, H. Chromophobe adenoma of pituitary gland with subarachnoid metastases. Neurology 13:836–840, 1963.

Scholz, D. A., Gastineau, C. F., and Harrison, E. G., Jr. Cushing's syndrome with malignant chromophobe tumor of the pituitary and extracranial metastasis: report of a case. Mayo Clin. Proc. 37:31–42, 1962.

CHEMODECTOMA OF THE GLOMUS JUGULARE

SYNONYMS AND RELATED TERMS: Non-chromaffin paraganglioma; glomus jugulare tumor; paraganglioma.

This tumor arises from elements that form part of the chemoreceptor system, and originates in the middle ear from the glomus jugulare, which consists of a group of cells situated in the adventitia of the jugular bulb or along the ramus tympanicus of the glossopharyngeal nerve. The clinical presentation is usually that of middle ear symptoms with deafness, pain in the ear, and otorrhea, often accompanied by the appearance of a red, fleshy, hemorrhagic mass

in the external auditory meatus. There may be extensive destruction of the petrous temporal bone; up to 40 percent of cases present with neurologic symptoms referable to the posterior fossa or to a pontocerebellar angle mass (Henson et al.). The literature has been reviewed by Schermer and associates, and further cases have recently been reported by Fuller and associates. See also the fascicle, "Tumors of the Carotid Body and Related Structures" by LeCompte.

MICROSCOPIC. The histologic picture is identical with that of a carotid body tumor (fig. 319). The diagnosis presents no difficulty in cases where the histologic picture is typical, but may be missed in those examples presenting clinically as a posterior fossa tumor if the possibility of a chemodectoma is not kept in mind. The vascularity of the tumor and the microscopic picture of clear cells separated by an abundant vascular stroma may mimic a capillary hemangioblastoma or an angioblastic meningioma; diagnostic difficulties may especially arise when the tumor has become secondarily attached to the tentorium.

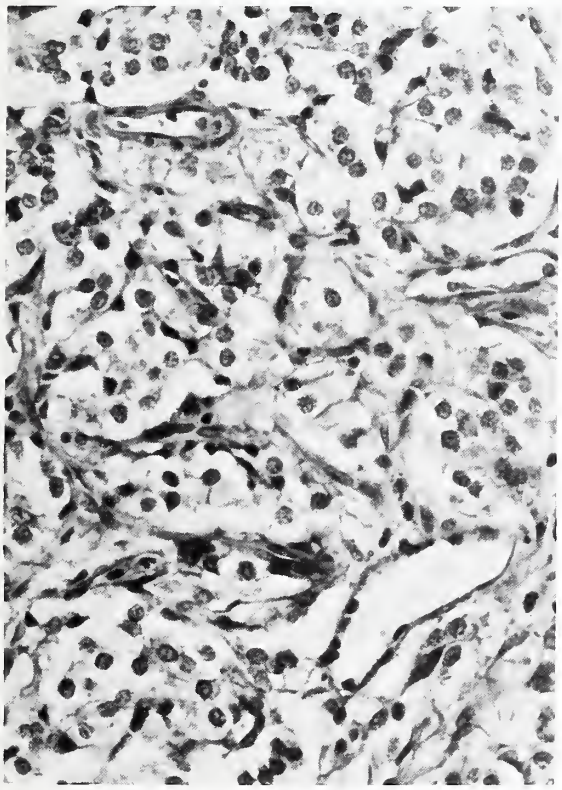

CHEMODECTOMA OF GLOMUS JUGULARE

Figure 319. This typical pattern of well defined lobules composed of clear cells separated by thin-walled capillaries illustrates a glomus jugulare tumor. × 305.

References

Fuller, A. M., Brown, H. A., Harrison, E. J., Jr., and Siekert, R. G. Chemodectoma of the glomus jugulare tumors. Laryngoscope 77:218–238, 1967.

Henson, R. A., Crawford, J. V., and Cavanagh, J. B. Tumours of glomus jugulare. J. Neurol. Neurosurg. Psychiat. 16:127–138, 1953.

LeCompte, P. M. Tumors of the Carotid Body and Related Structures (Chemoreceptor System), Fascicle 16, Atlas of Tumor Pathology. Washington: Armed Forces Institute of Pathology, 1951.

Schermer, K. L., Pontius, E. E., Dziabis, M. D., and McQuiston, R. J. Tumors of the glomus jugulare and glomus tympanicum. Cancer 19:1273–1280, 1966.

CHORDOMA

DEFINITION AND HISTOGENESIS. It is widely recognized that this tumor originates from intraosseous notochordal vestigial remnants and is most frequently found in the cranial and sacrococcygeal regions. Notochordal vestiges have been found embedded within the dorsum sellae of 4 to 5 percent of adults (Willis). The tumor, however, seldom seems to arise from the small vestigial gelatinous nodules commonly found lightly attached to the ventral aspect of the pons as an incidental postmortem discovery; these are ectopias of notochordal tissue that have long been known by the name of "ecchordosis," or "ecchondrosis physaliphora."

SITES. GROSS. The sacrococcygeal examples are the most common. They may

extend into the epidural space, invade the dura, and surround the nerve roots of the cauda equina and produce symptoms of nerve root compression. Those arising in the skull most frequently originate beneath the pituitary fossa, from which they emerge as a soft grayish, lobulated, and frequently hemorrhagic mass that may simulate a large invasive pituitary adenoma (fig. 320).

Fig. 320

INTRACRANIAL CHORDOMA

Figure 320. This large intracranial chordoma arose from the clivus. (Courtesy of Dr. J. W. Hanbery, Stanford, Calif.)

The cut surfaces may be soft, or often rather firm, with a lobulated pattern of grayish areas frequently showing focal hemorrhages. When extensive spread has taken place in the posterior fossa considerable compression of the pons and medulla may result. Occasionally the tumor may spread laterally as well as upward, occupy the cavernous sinus, and extend well into the middle fossa. Often it grows downward and forward and presents as a nasopharyngeal mass. It may also invade the accessory nasal air sinuses. Although grossly lobulated the tumor is locally invasive and may cause extensive bone destruction.

MICROSCOPIC. Chordomas are composed of compact masses or elongated cords of clear cells with a regular cytologic appearance (fig. 321). A lobular pattern is often produced by the intersection of thick strands of fibrous connective tissue. The cells contain large characteristic intracytoplasmic vacuoles, an appearance often termed "physaliphorous," or bubble-like (fig. 322). The intracytoplasmic material is frequently PAS positive, but much of it is lost in the usual paraffin preparations. It is also positive for mucicarmine. The cytologic features are usually benign and mitotic figures are not found. The differential diagnosis of this tumor usually includes that of a chondroma, but the typical arrangement of cellular doublets or tetrads surrounded by a clear empty space and a basophilic matrix characteristic of cartilaginous tumors is not found.

PROGNOSIS. On the whole the prognosis of chordomas is poor because of their irreversible invasive propensity, but true cytologic malignancy with the accompaniment of distant metastases is very uncommon (Poppen and King). Reviews of these tumors and of their clinicopathologic behavior will be found in the papers by Congdon and by Dahlin and MacCarty.

INTRACRANIAL CHORDOMA

(Figures 321 and 322 from same case)

Figure 321. This is the microscopic appearance of a large intracranial chordoma that caused marked compression of the ventral lateral surface of the medulla in a 48-year-old woman. × 190. (Fig. 13 from Rubinstein, L. J. Seminario de Neuropatologia, Mérida, Yucatán, Bol. Asoc. Mex. Patol., A. C. 7:13–59, 1969).

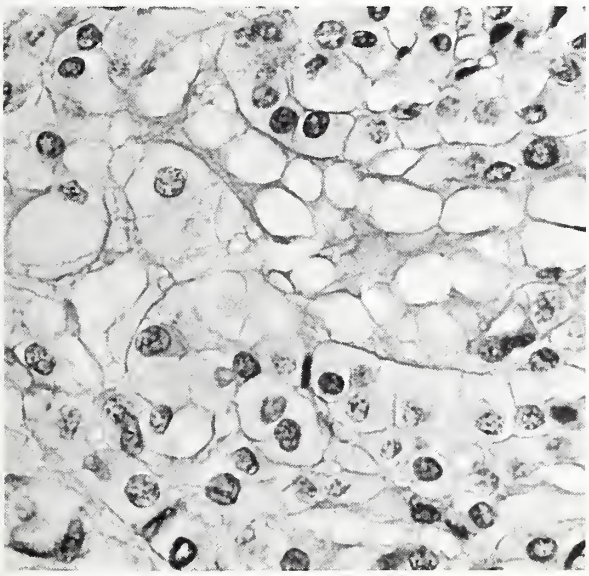

Fig. 322

Figure 322. A high power view of the tumor cells shows the typical physaliphorous, or bubble-like, appearance of the cytoplasm. × 440. (Fig. 14 from Rubinstein, L. J. Seminario de Neuropatologia, Mérida, Yucatán, Bol. Asoc. Mex. Patol., A. C. 7:13–59, 1969).

References

Congdon, C. C. Benign and malignant chordomas. A clinico-anatomical study of twenty-two cases. Amer. J. Path. 28:793–821, 1952.

Dahlin, D. C., and MacCarty, C. S. Chordoma. A study of fifty-nine cases. Cancer 5:1170–1178, 1952.

Poppen, J. L., and King, A. B. Chordoma: experience with 13 cases. J. Neurosurg. 9:139–163, 1952.

Willis, R. A. The Borderland of Embryology and Pathology, 2d ed., p. 300. London: Butterworth & Co., Ltd., 1962.

OTHER TUMORS

Ivory osteomas of the nasal sinuses may occasionally compress the frontal lobe. Chondromas and osteochondromas apparently arising from the dura of the cerebral convexity and the falx have also been described (Forsythe et al.); others originate from the base of the skull (Klingler). The tumors are encapsulated and not invasive. In the vertebral canal they may present as firm white lobulated masses.

Osteosarcomas and chondrosarcomas originating from the skull and vertebrae may extend into the dura, but transgression and invasion of the underlying neural tissues is exceptional. Malignant primary bone tumors of the skull are extremely rare (Coley). They are usually found in children and young adults, except for those exceptional examples that complicate advanced Paget's disease (Kirshbaum; Vandenberg and Coley).

Myxosarcomas and **myxochondrosarcomas** occasionally arise from the dura of the convexity of the brain, especially its outer layer, but unlike the chondromas, which have been reported to originate mostly from the calvarium, they tend to arise more frequently from the base of the skull. Occasional examples have originated from the falx (Wolf and Echlin) and invaded the frontal lobes. Several instances of this rare form of neoplasm were identified by Kernohan and Uihlein in their series of sarcomas of the nervous system.

Infiltration of the nervous system may occur, followed by metastatic spread in the leptomeninges by a **rhabdomyosarcoma** originating in the ear and growing as a pontocerebellar tumor through the internal auditory meatus (Russell and Rubinstein).

Direct spread from a **carcinoma** arising in the ear, mastoid cavity, and especially the **nasopharynx** is well known. The tumor may penetrate through the base of the skull and infiltrate the leptomeninges and cranial nerve roots. The clinical picture may be that of multiple cranial nerve palsies. Occasionally more extensive spread takes place through the cerebrospinal fluid pathways. Such a sequence has been seen resulting from invasion at the pontocerebellar angle by a recurrent, slowly growing adenocarcinoma of the parotid gland. Occasionally basal cell carcinomas of the scalp have been known to erode through the bone and the subjacent dura (Courville).

References

Coley, B. L. Neoplasms of Bone and Related Conditions, 2d ed. New York: Hoeber, 1960.

Courville, C. B. Malignancies of the scalp with invasion of skull and intracranial space; report of four cases with necropsy verification. Bull. Los Angeles Neurol. Soc. 21:162–174, 1956.

Forsythe, R. W., Baker, G. S., Dockerty, M. B., and Camp, J. D. Intracranial osteochondroma. Mayo Clin. Proc. 22:350–356, 1947.

Kernohan, J. W., and Uihlein, A. Sarcomas of the Brain. Springfield, Ill.: Charles C Thomas, 1962.

Kirshbaum, J. D. Fibrosarcoma of the skull in Paget's disease. Arch. Path. 36:74–79, 1943.

Klingler, M. Uber Knorpelgechwülste der Schädelbasis mit intrakranieller Ausdehnung. Acta Neurochir. 1:337–380, 1951.

Russell, D. S., and Rubinstein, L. J. Pathology of Tumours of the Nervous System, 3d ed. London: Edward Arnold, 1971.

Vandenberg, H. J., Jr., and Coley, B. L. Primary tumors of the cranial bones. Surg. Gynec. Obstet. 90:602–612, 1950.

Wolf, A., and Echlin, F. Osteochondrosarcoma of the falx invading frontal lobes of cerebrum. Bull. Neurol. Inst. New York 5:515–525, 1936.

HEMATOGENOUS SPREAD

METASTATIC CARCINOMA

INCIDENCE. PRIMARY SITES. The incidence of metastatic carcinoma among intracranial tumors varies greatly according to whether the figures are obtained from neurosurgical sources or from autopsy material. It may be as low as 4.2 percent in some series and as high as 37 percent in others. In pathologic practice a figure of 15 to 25 percent is usually found.

There is general agreement that the bronchus is the preponderant site of origin, amounting to 65 percent in one of the more recent series (Richards and McKissock). The breast usually takes second rank; its incidence as a primary site is roughly half that of the lung. Rarer sites include the kidney, colon, pancreas, prostate, and testis. Cutaneous malignant melanomas, an important source of secondary neoplasm in the brain, are dealt with separately on page 328; they may amount to almost 15 percent of the metastatic tumors found in the central nervous system.

In many cases intracranial or intraspinal disease is known clinically to be secondary to a primary neoplasm elsewhere. Frequently, however, it is the presenting sign, especially notorious with a small silent primary carcinoma of the bronchus. Occasionally also removal of a solitary metastatic deposit may precede the discovery of a primary lung tumor by several years (Russell and Rubinstein; Richards and McKissock). Another rare but well documented phenomenon is the occurrence of a long latent period between the removal of a primary neoplasm and the appearance of a secondary cerebral deposit; this has been particularly noted in renal carcinoma, in which intervals of 9 to 13 years may elapse between the two events.

SITES AND GROSS APPEARANCES. Both the central nervous system and its coverings may be involved (fig. 323). In some cases this is the result of a direct spread by tumor that has first metastasized to the skull or vertebrae. In the spinal canal the existence of the normally roomy epidural space may allow the growth and spread of extensive metastases. These may develop as tough masses that form a collar constricting the cord and result in a rapidly progressive paraplegia. Relief of the spinal compression by laminectomy may lead to rapid improvement in some instances (Barron et al.). The effects on the spinal cord

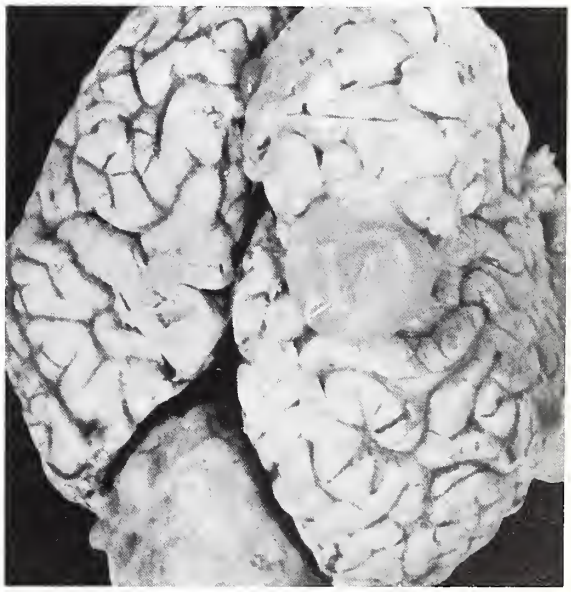

METASTATIC CARCINOMA TO THE LEPTOMENINGES

(Figures 323 and 325 from same case)

Figure 323. Two well defined lobulated, partly solid, partly cystic masses are lightly adherent to the brain. These lesions are from a case of intraductal carcinoma associated with Paget's disease of the breast. The tumors were unattached to the dura. One compresses the superior surface of the right frontal lobe; the other is situated above the vermis and separates the occipital lobes.

parenchyma are referred to on page 348. In the spinal canal transgression of the dura is very unusual, but the spinal nerve roots may be compressed by the adjacent growth or invaded along the intravertebral foramina (fig. 330).

By contrast, involvement of the **cranial dura** by bony metastases is frequently followed by transgression of this membrane with the formation of **subdural** deposits. Infiltration of the cranial dura may take various forms. In some cases there is irregular separation of the membrane from the diploe by periosteal growth; in others, well defined subdural nodules firmly attach to the dura and excavate the underlying brain (pl. XI-A). In other cases still there is slight diffuse thickening of the dura only, which appears hemorrhagic along its inner surface. This may be one of the causes of the condition referred to in the older literature as **pachymeningitis interna hemorrhagica**, and may progress to the formation of unilateral or bilateral subdural hematomas (Russell and Cairns). This sequence is most frequently found in carcinomas originating from the breast or stomach that have metastasized widely through the osseous system with the production of a myelophthisic, or leukoerythroblastic, anemia. It is also not uncommonly seen as a result of extensive dural infiltration by lymphomatous masses, especially reticulum cell sarcoma or Hodgkin's disease. Occasionally the subdural hematoma is confined to the spinal subdural space. Microscopically it appears attributable to permeation of the dural veins and capillaries by neoplastic cells (fig. 324).

Another site of involvement is the **subarachnoid space**. This may consist, exceptionally, in the formation of well defined masses, unattached to the dura or the underlying brain, that have become circumscribed through the production of a rich connective tissue stroma originating from the infiltrated leptomeninges (fig. 325). More common, however, is a highly diffuse infiltration of the leptomeninges resulting in the picture of **meningeal carcinomatosis**, or "carcinomatous meningitis," described as a variant on page 325.

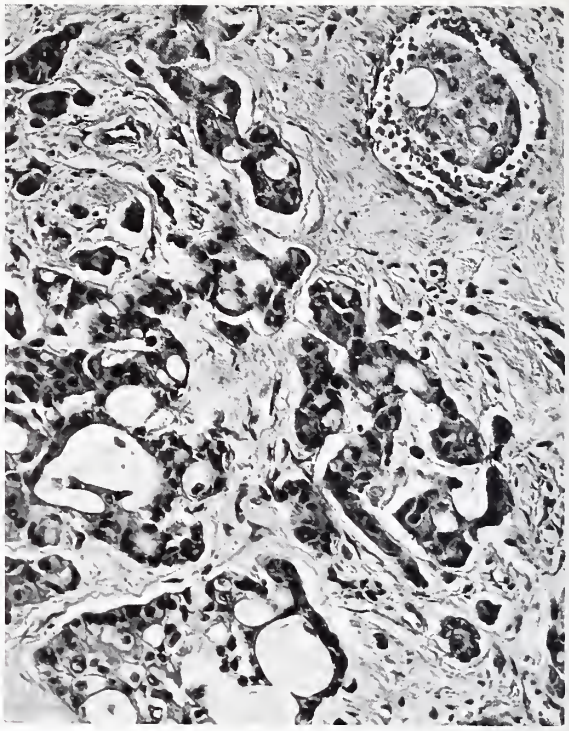

METASTATIC CARCINOMA IN THE DURA PERMEATING DURAL VEINS

(Figures 324 and 330 from same case)

Figure 324. Metastatic carcinoma infiltrates the dura and permeates a dural vein (upper right) in a case of pachymeningitis interna hemorrhagica. × 180.

Parenchymatous involvement of the central nervous system is extremely common; the brain is the most frequent site involved while the spinal cord is seldom directly affected. In the brain all areas of the cerebral hemispheres may be the site of metastatic deposits without any particular selective localization. The cerebellum is

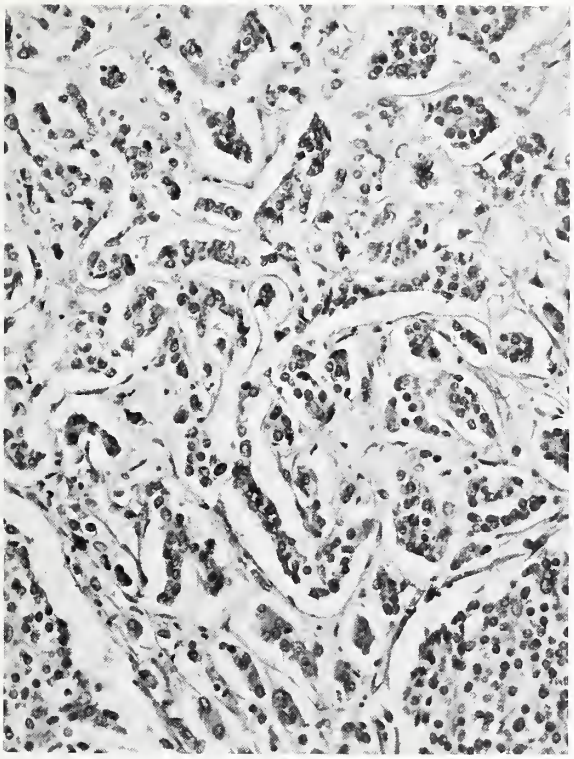

METASTATIC CARCINOMA IN LEPTOMENINGES WITH MARKED DESMOPLASTIC REACTION

(Figures 323 and 325 from same case)

Figure 325. Clumps of metastatic carcinoma are separated by a very abundant fibrous connective tissue stroma resulting from the fibroblastic proliferation in the invaded leptomeninges. × 160.

frequently involved. Not uncommonly the pineal may be the site of a metastatic deposit, and occasionally metastases are even found in a primary brain tumor, such as a meningioma (fig. 331) or primary glioma (pl. XI-F). I have seen 3 cases of metastatic carcinoma in a meningioma, and one example of a metastatic oat cell carcinoma of the bronchus in a fourth ventricle ependymoma.

In the brain parenchyma, metastatic disease may consist of single or multiple well defined, circumscribed nodules, either solid (pl. XI-B) or partly cystic (pl. XI-C). The cut surface is usually variegated, with extensive foci of yellow necrosis and hemorrhage, and in cases originating from a mucus-secreting carcinoma the metastases may contain slimy gelatinous greenish fluid. Occasionally the outline of the tumor may be somewhat lobulated. Cystic foci may either be yellow or greenish after fixation, or contain dark red or brownish hemorrhagic fluid (pl. XI-C.) A characteristic feature of these tumors is the presence of edema in the surrounding brain (pl. XV-A), which in some cases may be remarkably extensive. Further details on the mechanism and pathologic features of cerebral edema are discussed on page 333. The incidence of necrosis in metastatic deposits is not necessarily related to their size; sometimes large deposits show little or no necrosis, while small foci may show extensive necrosis. In multiple carcinomatous disease, the smaller foci are often situated at the junction between the gray and white matter, a preferential site similar to that of multiple metastatic brain abscesses, presumably attributable to the rapid narrowing of the arterioles at that site and the sudden reduction of vascularity that takes place in the underlying white matter.

MICROSCOPIC. The histologic picture usually presents no difficulty; the appearance is that of metastatic carcinoma in any other site of the body. The cytologic features usually reproduce those of the primary tumor. In the better differentiated types the diagnosis should be obvious. In a limited biopsy, difficulty may arise in distinguishing between an anaplastic carcinoma and a poorly differentiated glioma. In most cases, however, the cytologic features are quite different. In metastatic carcinoma the appearances are those of polygonal cells arranged singly or in small clumps, showing large vesicular nuclei with prominent nucleoli and numerous mitotic figures.

PLATE XI

SUBDURAL METASTATIC CARCINOMA

A. A well defined disk of subdural metastatic carcinoma has excavated the left parietal lobe. The primary tumor was in the lung.

METASTATIC ADENOCARCINOMA

B. A well defined nodule of metastatic adenocarcinoma from the lung is seen in the frontal white matter. The surrounding white matter was soft and edematous.

METASTATIC CARCINOMA

C. A well defined partly cystic, partly solid and necrotic metastatic carcinoma is present in the right parietal lobe causing marked compression of the lateral ventricle.

SMEAR FROM METASTATIC CARCINOMA

D. Polygonal cells are arranged singly and in small clumps in a smear of metastatic breast carcinoma. Note mitotic figures and large vesicular nuclei with prominent nucleoli. Morris. × 530.

METASTATIC MELANOMA

E. The cortex is occupied by metastatic melanoma cells arranged singly or in groups. Melanin pigment is present. The tumor infiltration has stimulated a marked hypertrophic astroglial reaction. PTAH. × 300.

METASTATIC CARCINOMA IN PRIMARY GLIOMA

F. Well defined clumps of solid polygonal cell carcinoma are shown in an area of diffuse glioma. van Gieson. × 180.

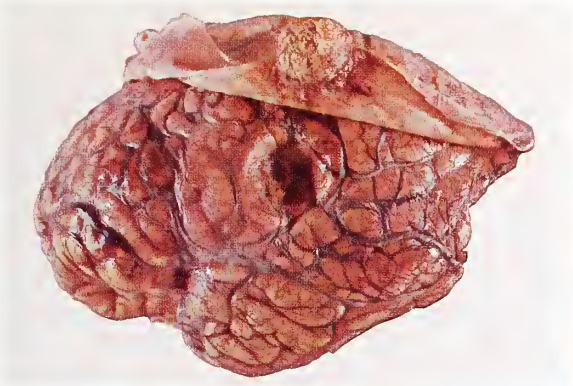

A

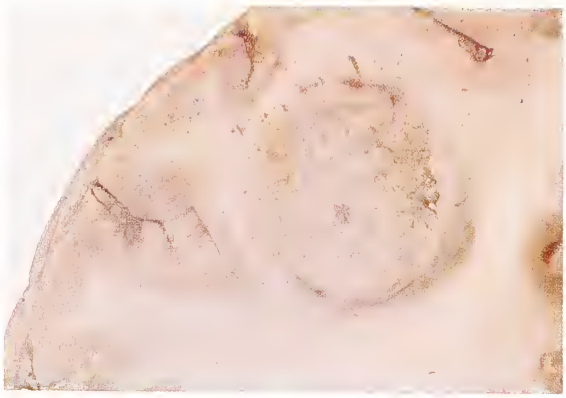

B

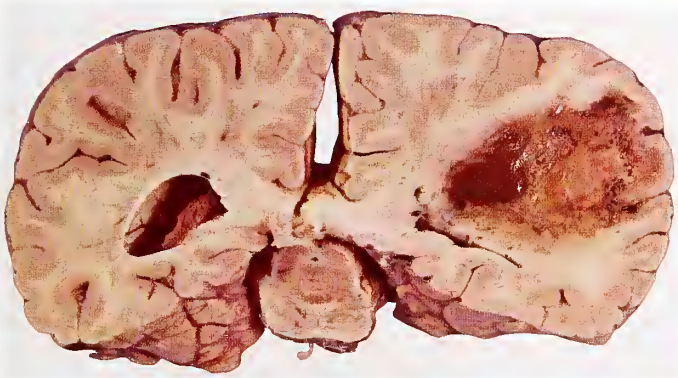

C

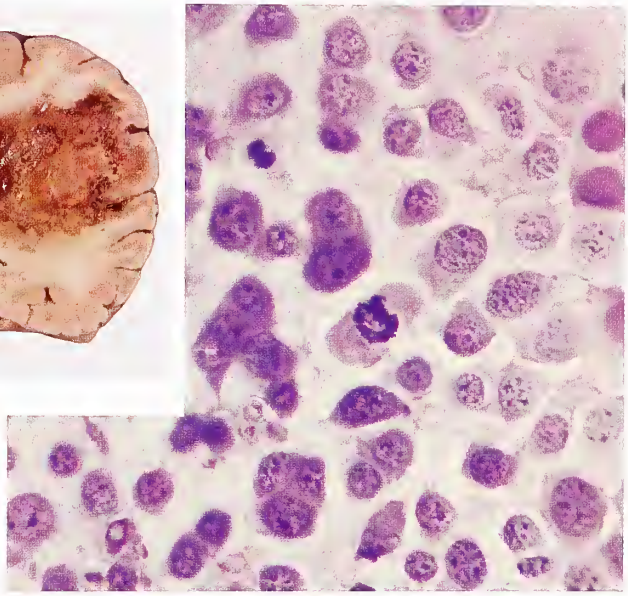

D

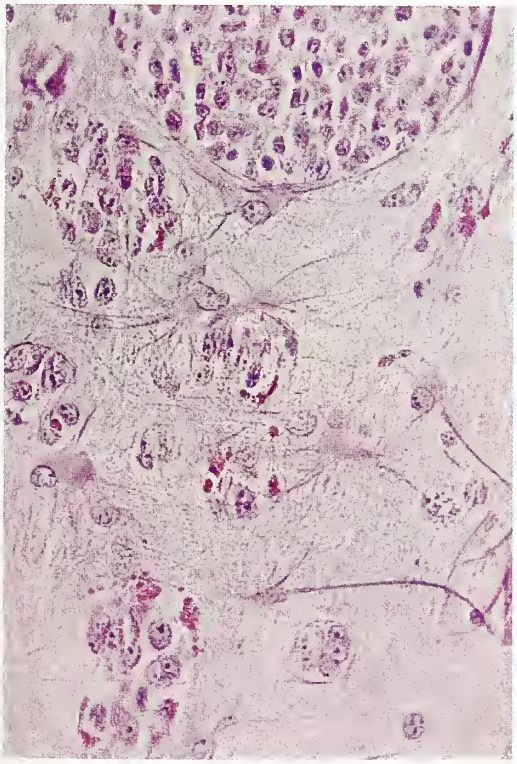

E

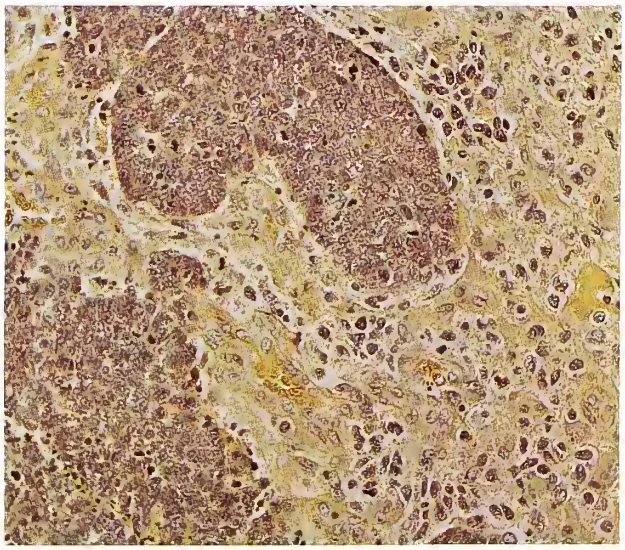

F

PLATE XI

These features are particularly well displayed in smears obtained at the time of surgery (pl. XI-D). In some instances the secondary tumor may be even better differentiated than in the primary site, especially in metastatic adenocarcinoma (fig. 326). The tumor cells are easily distinguishable from the invaded neural parenchyma. Infiltration of the latter may take place both directly through the parenchyma or by way of the Virchow-Robin spaces (fig. 327).

The presence of metastatic carcinoma usually stimulates a variable degree of hypertrophic astrocytic reaction (fig. 341), usually associated with edema of the surrounding brain parenchyma (pl. XV-A). Vascular endothelial proliferation may also be present, but this is usually much less severe than with primary gliomas. Occasionally an unusually severe fibrous connective tissue reaction is found, especially associated with secondary renal cell carcinoma.

Metastatic carcinoma involving the dura is usually accompanied by a marked desmoplastic reaction due to the proliferation of connective tissue by dural fibroblasts (fig. 324). Occasionally an extraordinary fibroblastic proliferative reaction occurs as the result of infiltration of the leptomeninges (fig. 325); this example had the gross appearance shown in figure 323 and was ob-

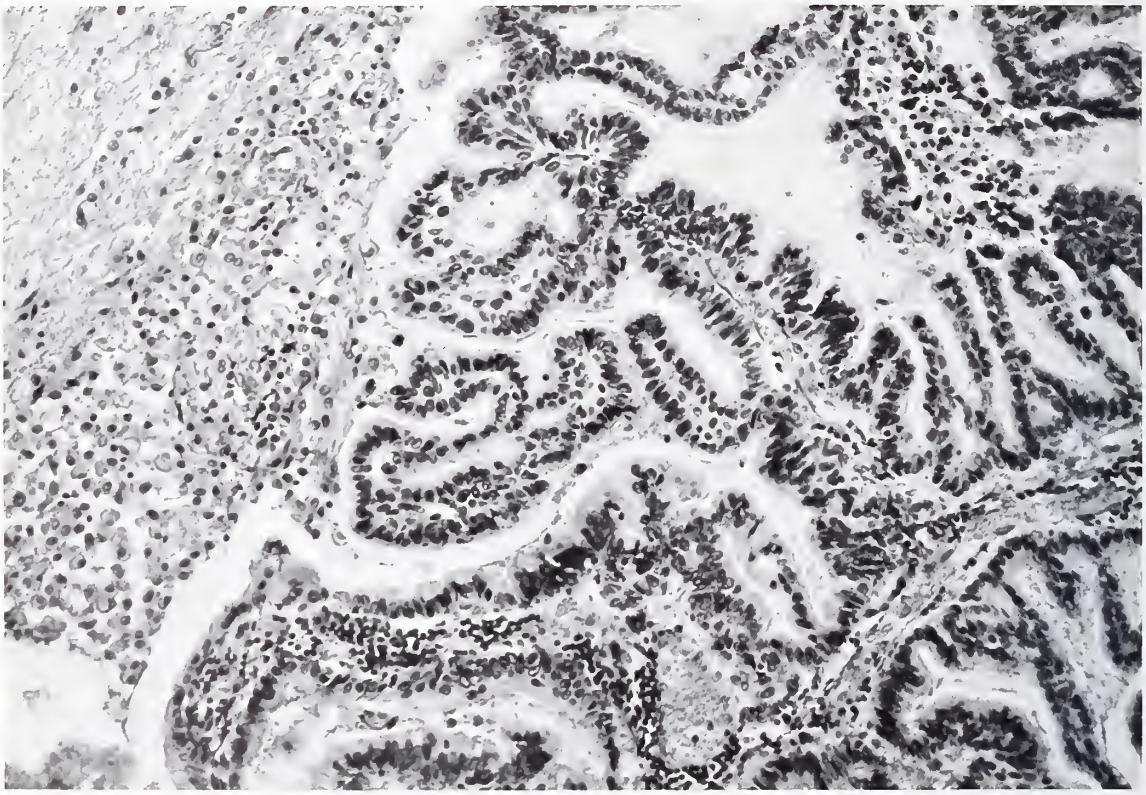

METASTATIC ADENOCARCINOMA

Figure 326. Well differentiated tubular and papillary, mucus-secreting adenocarcinoma is shown in the brain of a 65-year-old woman, who presented clinically with progressive mental deterioration and hemiplegia. A small mucus-secreting bronchogenic adenocarcinoma was found postmortem. × 180.

tained from a metastatic tumor originating from an intraductal carcinoma in a woman with Paget's disease of the breast.

METASTATIC CARCINOMA

Figure 327. Metastatic carcinoma infiltrates the brain parenchyma as well as the perivascular space (below). × 135.

VARIANT

Meningeal Carcinomatosis or Carcinomatous Meningitis

These cases may run an unusually long clinical course, mimicking a subacute or chronic meningitis. Pathologically they may present either as a diffuse opaque, milky white exudate filling the subarachnoid space maximal over the base of the brain and the posterior aspect of the spinal cord, or as a delicate lacy pattern of fine yellowish streaks of material that can just be recognized grossly on the surface of the brain. Occasionally the gross appearance is entirely normal, but microscopic examination reveals the presence of carcinomatous meningitis.

In some examples involvement of the central nervous system is restricted entirely to infiltration of the subarachnoid space. In the majority of cases, however, further sectioning discloses several or many small foci throughout the brain substance, and occasionally one or more of these deposits may be found immediately adjacent to the ventricle. In such cases it is reasonable to attribute the meningeal spread by the tumor to the spilling of neoplastic cells into the cerebrospinal fluid pathways.

In addition to diffuse meningeal spread, extensive infiltration of the cranial, and more frequently the spinal nerve roots may take place; as a result they may show marked thickening with the formation of multiple beady enlargements, as demonstrated in figure 329, taken from the cauda equina of a patient with widespread leptomeningeal carcinomatosis from the breast. Larger nodules attached to the spinal nerve roots or in the pontocerebellar angles may also be present.

MICROSCOPIC. Involvement of the leptomeninges by carcinoma may vary greatly at different levels. In some areas the subarachnoid space may be filled by metastatic tumor that penetrates the brain and cord along the perivascular spaces and then the central nervous system parenchyma more diffusely further afield. In many instances carcinomatous meningitis is accompanied by a diffuse infiltration of the cranial and spinal nerve roots (fig. 330). This is often associated with a variable degree of fibrous connective tissue proliferation. One particular form of diffuse carcinomatosis of the meninges is characterized by the formation of a single layer of neoplastic cells that covers the pial surfaces over wide distances (Fischer-Williams et al.).

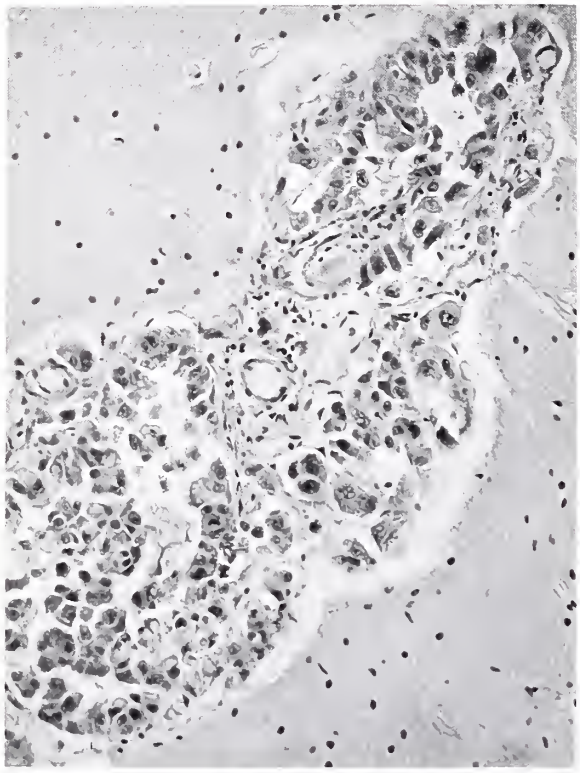

CARCINOMATOSIS OF THE MENINGES

Figure 328. Columnar-cell adenocarcinoma occupies the leptomeninges over the cerebellar cortex in a case of carcinomatous meningitis from a primary carcinoma in the bronchus. × 160.

In such cases the tumor cells are usually tall and columnar (fig. 328), sometimes mucus-secreting, and originate from an adenocarcinoma, most frequently from the stomach or the bronchus. These cases are typically associated with an increase of cells and a decrease of glucose in the cerebrospinal fluid.

DIFFERENTIAL DIAGNOSIS. The diffential diagnosis of metastatic carcinoma usually poses no problem, but occasional difficulties may be encountered in distinguishing an anaplastic carcinoma from an undifferentiated glioma. The demonstration of large reactive astrocytes in such a biopsy is useful in weighing the diagnosis in favor of a metastatic neoplasm. Oat cell carcinoma may occasionally cause confusion with small fusiform undifferentiated glial neoplasms, either glioblastoma or even medulloblastoma (fig. 332). Metastatic carcinoma from a primary renal cell carcinoma sometimes mimics a capillary hemangioblastoma, and occasionally when the cells are stellate, it may resemble a gemistocytic astrocytoma. Some metastatic clear cell carcinomas may also superficially resemble an oligodendroglioma. Other epithelial neoplasms with which metastatic carcinoma may be confused include pituitary adenoma, choroid plexus papilloma, and occasionally meningotheliomatous meningioma.

DIFFUSE INFILTRATION OF SPINAL NERVE ROOTS BY METASTATIC CARCINOMA

Figure 329. This diffuse thickening with multiple beadings of the spinal nerve roots of the cauda equina resulted from widespread subarachnoid metastatic infiltration in a case of primary carcinoma of the breast.

INFILTRATION OF SPINAL NERVE ROOTS BY METASTATIC CARCINOMA

(Figures 324 and 330 from same case)

Figure 330. This microscopic picture shows infiltration of the subarachnoid space and permeation of the nerve roots of the cauda equina by metastatic adenocarcinoma. × 70.

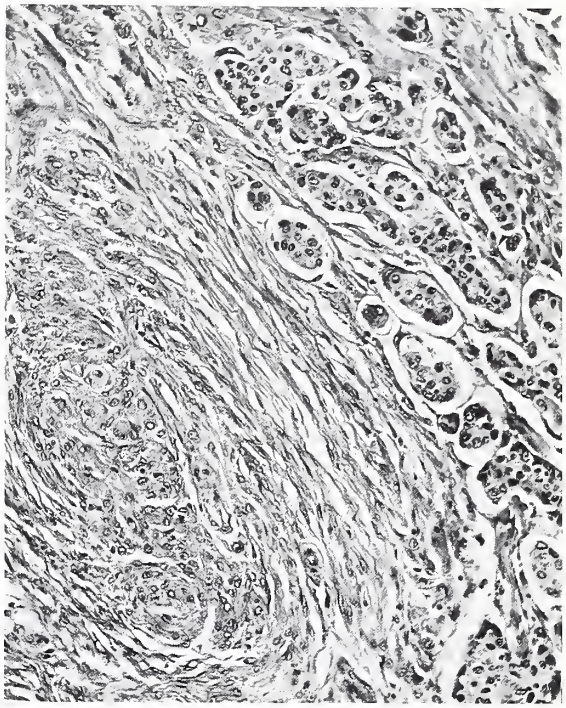

METASTATIC CARCINOMA IN A MENINGIOMA

Figure 331. This is metastatic carcinoma from the breast (upper right) in a large transitional meningioma in a 74-year-old woman. × 130.

METASTATIC OAT CELL CARCINOMA IN BRAIN WITH ROSETTE FORMATIONS

Figure 332. This 59-year-old man had a large mass removed from the posterior and superior mediastinal region, with involvement of the paratracheal lymph nodes, approximately one year before death. At postmortem examination he had multiple cerebral metastases, but no residual tumor in the rest of the body. The cytologic picture throughout was that of an oat cell carcinoma of bronchogenic origin. Rosettes such as those illustrated in this photomicrograph were found only at the periphery of the metastatic foci, but the primary growth also showed a few areas suggesting ill-defined rosette formation. Patterns of rosettes have been described in bronchogenic oat cell carcinoma. × 340.

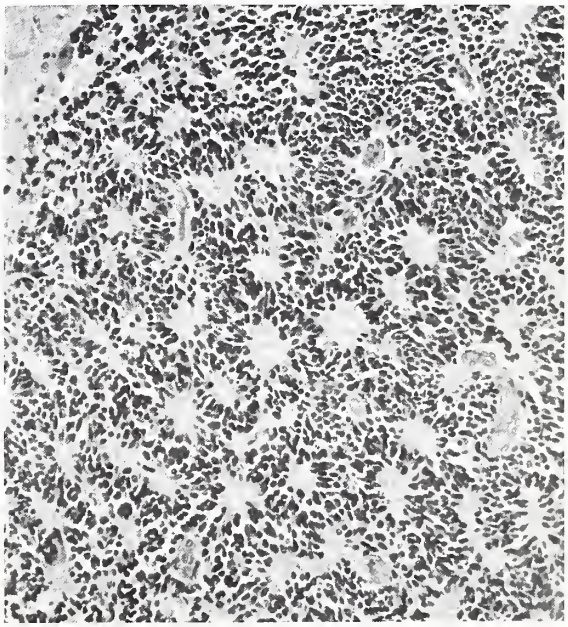

Fig. 332

METASTATIC MELANOMA

The brain is usually involved as part of the generalized bloodborne dissemination in this frequent metastatic tumor. In most cases the primary site is the skin.

GROSS. The appearances and distribution of metastatic melanoma vary greatly. In some cases the tumor is solitary, but more often it is multiple. As in metastatic carcinoma, it is well defined but not encapsulated, and may be accompanied by severe edema of the adjacent white matter (fig. 333). The pigmentation of the tumor is usually obvious to the naked eye, but some examples are amelanotic. In other cases the involvement is largely meningeal with the formation of well defined, rather firm, subarachnoid masses which excavate the underlying brain. As in metastatic carcinoma the infiltration of the leptomeninges may stimulate a vigorous fibrous connective tissue reaction (fig. 336). In some examples (fig. 334) the leptomeninges contain innumerable pigmented metastatic plaques and nodules, and more of these are found impinging upon the ependyma on coronal section of the brain. As in meningeal carcinomatosis it is probable that the cerebrospinal meningeal spread resulted from the irruption of tumor nodules into the ventricular cavity (fig. 335).

MICROSCOPIC. DIFFERENTIAL DIAGNOSIS. The cytologic features are highly variable, and in cases in which only a limited biopsy is obtained this may cause considerable diagnostic difficulty. Typically the melanoma cells are small polyhedral cells with round nuclei and prominent nucleoli, that invade the neural parenchyma either singly or in small groups (pl. XI-E). Melanin pigment may be recognized, and the tumor may stimulate a marked hypertrophic neuroglial reaction (pl. XI-E). In other cases the tumor cells display a bulky eosinophilic cytoplasm with large nuclei and prominent nucleoli, which may somewhat simulate those of an astrocytic glioma (fig. 337). A particular diagnostic difficulty may arise in amelanotic melanomas because of their tendency to invade the host tissue as single cells, mimicking a diffusely infiltrating glioma. This is illustrated in figure 338, taken from an example in which innumerable pigmented deposits were found: the parenchyma is diffusely invaded by undifferentiated neoplastic elements that lack any of the recognizable histologic characters that would mark them as metastatic. Occasionally tumor cells form perivascular pseudorosettes that may recall an astroblastoma. Infiltration of the spinal or cranial nerve roots by amelanotic melanoma may also mimic a malignant schwannoma or fibrosarcoma (fig. 339). Certain examples may even show pseudopalisading, thus imitating a glioblastoma multiforme.

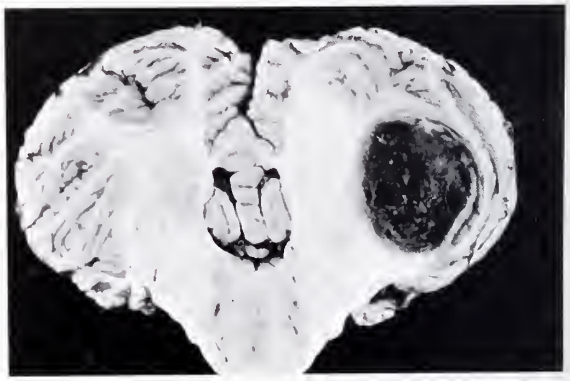

METASTATIC MELANOMA IN CEREBELLUM

Figure 333. One large circumscribed pigmented metastatic deposit is seen in the cerebellar hemisphere in a case of primary cutaneous malignant melanoma. There is considerable edema of the cerebellar white matter.

DIFFUSE METASTATIC MENINGEAL SPREAD FROM A PRIMARY CUTANEOUS MELANOMA

(Figures 334 and 335 from same case)

Figure 334. Diffuse and focal infiltration of the subarachnoid space is seen over the base of the brain and inferior surfaces of the cerebellum from a widely metastasizing primary cutaneous melanoma. On section numerous melanotic nodules were found scattered throughout the brain and occupying the ventricular cavity.

CEREBROSPINAL METASTASES FROM A PRIMARY CUTANEOUS MELANOMA

(Figures 334 and 335 from same case)

Figure 335. The posterior aspect of the spinal cord and the cauda equina are completely covered by an extensive sheet of metastatic melanoma. A lumbar puncture on this patient yielded black cerebrospinal fluid.

METASTATIC MELANOMA IN LEPTOMENINGES

(Figures 336 and 337 from same case)

Figure 336. Metastatic amelanotic melanoma infiltrates the leptomeninges and is accompanied by a marked fibrous stromal reaction. × 135.

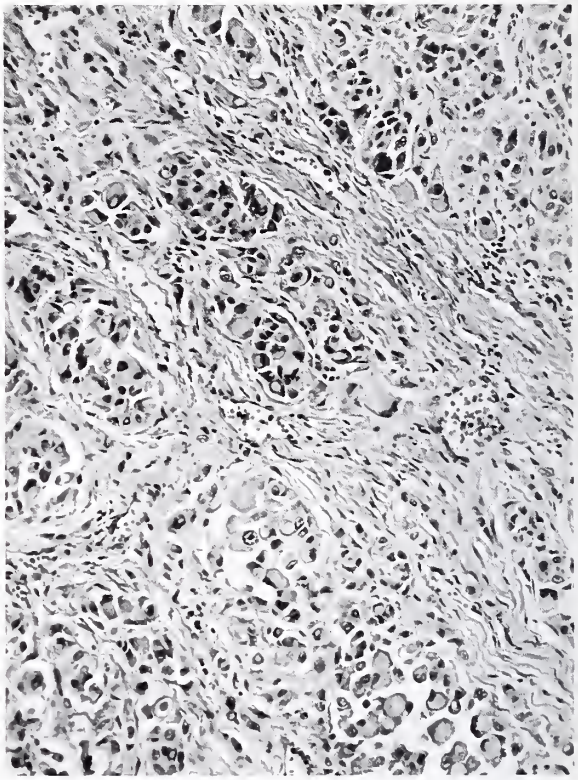

Fig. 336

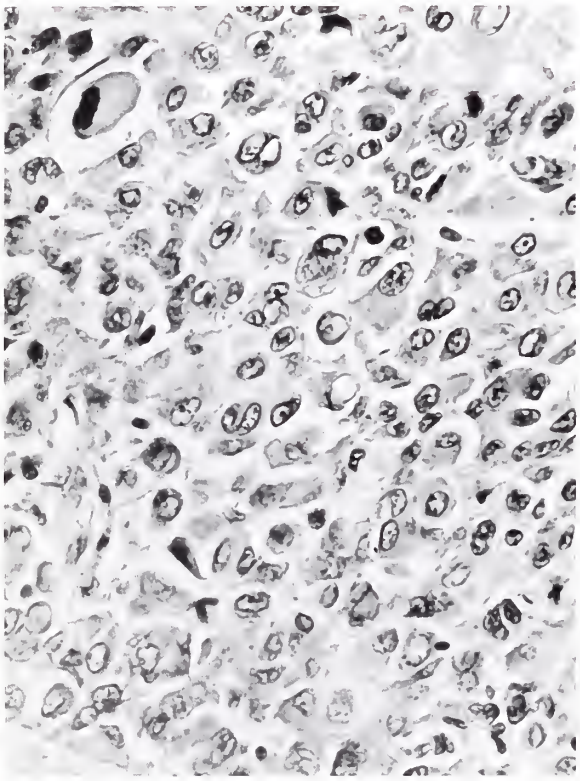

Fig. 337

METASTATIC INTRACEREBRAL MELANOMA

(Figures 336 and 337 from same case)

Figure 337. Amelanotic melanoma cells are seen in the brain. Note the morphologic resemblance to anaplastic glioma cells. × 340.

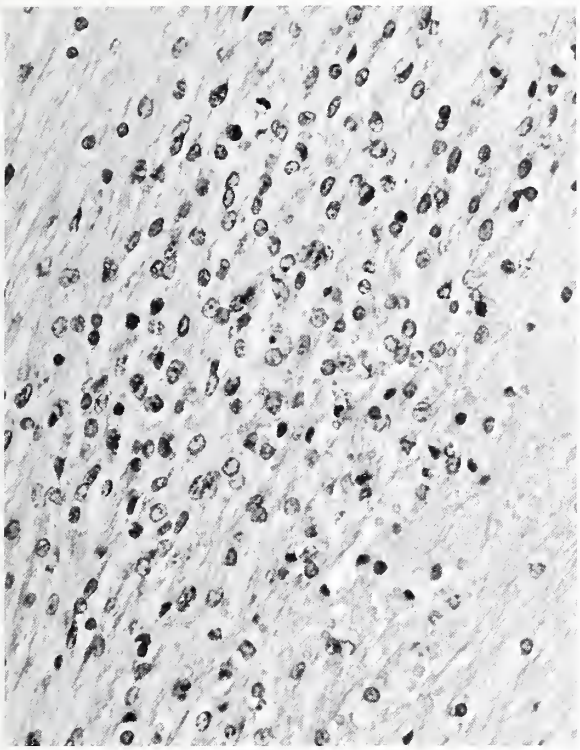

Fig. 338

AMELANOTIC METASTATIC MELANOMA DIFFUSELY INFILTRATING THE BRAIN

Figure 338. This microscopic picture illustrates a diffuse infiltration of the brain by amelanotic melanoma cells. Tumor cells merge imperceptibly into the cerebral parenchyma, thus mimicking a primary glioma. × 300.

METASTATIC AMELANOTIC MELANOMA INFILTRATING A SPINAL NERVE ROOT

Figure 339. Amelanotic metastatic melanoma infiltrates a dorsal nerve root. The tumor cells are elongated and form intersecting bundles, mimicking a primary nerve sheath neoplasm. × 340.

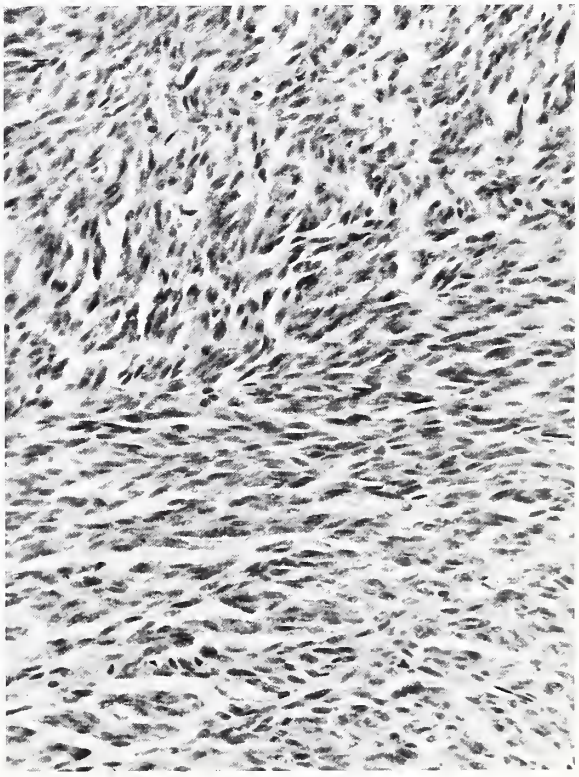

Fig. 339

PROGNOSIS. The prognosis of metastatic melanoma, although poor in the majority of cases, is not invariably so. Cases of several years survival after the removal of a single, even recurrent, metastatic deposit have been recorded (McCann et al.; McNeel and Leavens).

OTHER METASTATIC TUMORS

Occasionally the central nervous system is involved by metastatic tumor from a fibrosarcoma or an embryonal sarcoma. Penetration of the dura by metastatic peripheral neuroblastoma, or sympathicoblastoma, infiltrating the cranial periosteum may also occur but it is rare.

References

Barron, K. D., Hirano, A., Araki, S., and Terry, R. D. Experiences with metastatic neoplasms involving the spinal cord. Neurology 9:91–106, 1959.

Fischer-Williams, M., Bosanquet, F. D., and Daniel, P. M. Carcinomatosis of the meninges. A report of 3 cases. Brain 78:42–58, 1955.

McCann, W. P., Weir, B. K. A., and Elvidge, A. R. Long-term survival after removal of metastatic malignant melanoma of the brain. Report of two cases. J. Neurosurg. 28:483–487, 1968.

McNeel, D. P., and Leavens, M. E. Long-term survival with recurrent metastatic intracranial melanoma. Case report. J. Neurosurg. 29:91–93, 1968.

Richards, P., and McKissock, W. Intracranial metastases. Brit. Med. J. 1:15–18, 1963.

Russell, D. S., and Cairns, H. Subdural false membrane or haematoma (packymeningitis interna haemorrhagica) in carcinomatosis and sarcomatosis of the dura mater. Brain 57:32–48, 1934.

———, and Rubinstein, L. J. Pathology of Tumours of the Nervous System, 3d ed. London: Edward Arnold, 1971.

CHANGES IN THE BRAIN, SPINAL CORD, AND OTHER NEIGHBORING STRUCTURES PRODUCED BY LOCAL NEOPLASMS

The unimpeded growth of an intracranial tumor will inevitably produce an increase of intracranial pressure. This is the result not only of the space-occupying and expanding lesion but also of the secondary circulatory and structural changes in the adjacent brain that the growing neoplasm may bring into its train. These changes are apt to set in motion a self-perpetuating chain of events that will, unless relieved, inexorably result in the death of the patient. The most important of these events are cerebral edema, obstructive hydrocephalus, and internal herniations with their secondary vascular consequences.

CEREBRAL EDEMA

PATHOGENESIS AND MECHANISMS. One of the most serious complications of intracranial neoplasms is the advent of cerebral edema. This condition has been the object of extensive clinical and experimental investigation in recent years with special emphasis on the mechanism of its production, the cytologic and fine structural localization of edema formation, and its relationship to the phenomenon of the blood-brain barrier and to alterations of cerebral vascular permeability. Many of the questions at issue appear now on the way to resolution. The obstacles that initially beset investigators in this field hinged principally on the difficulty of accommodating the opposite views of light microscopists and biochemists on the one hand, and of electron microscopists on the other. To the former, the edema fluid in the white matter appeared localized largely extracellularly, an impression that was supported by the biochemical data of radioactive tracer substances designed to identify the extracellular compartment. But according to the electron microscopists, the extracellular space in the brain was restricted to a 200 angstrom interval and, except for those extreme examples in which rupture of the cell membranes had occurred, edema remained confined to the distended processes of astrocytic glial cells. More recent work has shown, however, that in the white matter the extracellular space may vary up to 800 angstroms; that 200 angstroms will permit the free passage of macromolecules; and that experimental edema of the white matter is in specific instances characterized by an appreciable increase of the extracellular space. These modified views now allow an easier reconciliation of the biochemical data from radioactive tracers with the morphologic observations at the fine structural level. Moreover it is now evident that the various experimental—and presumably clinical—models that will produce the pathologic picture of cerebral edema differ in a number of fundamental aspects that can be distinctly characterized both biochemically and ultrastructurally. These different mechanisms have been the subject of several recent exhaustive reviews (Fox; Stern). Further details with extensive discussions will be found in the monograph on Brain Edema edited by Klatzo and Seitelberger.

Summarizing the findings to date, Klatzo has defined cerebral edema in two main, fundamentally different types. In **vasogenic edema** the principal mechanism is related to vascular injury with resulting alterations in capillary permeability. The site of the edema is predominantly the white matter; the increased permeability results in the leakage of serum proteins and the extravasation of substances that are demonstrated with the conventional blood-brain barrier indicators. The fine structural changes are those of enlargement of the extracellular space in the white matter with cellular swelling affecting largely the astrocytes. Biochemical measurements show an increase in sodium, chloride, and serum proteins. The data from radioactive extracellular tracers are in agreement with the enlargement of the extracellular space as seen in the electron microscope. This type of edema is produced by stab wound injuries, cold lesions induced in the cortex, and the intracranial insertion of pellets, balloons, or other space-occupying or expanding substances.

In **cytotoxic edema** the principal mechanism is apparently related to direct damage to the parenchymal cells resulting in their swelling. Both gray and white matter may be affected depending upon the type of cytotoxic agent. The vascular permeability remains unimpaired and there is no leakage of protein or extravasation of conventional blood-brain barrier indicators. The fine structural features show no enlargement of the extracellular space, but demonstrate swelling of various tissue components depending on the type of cytotoxic agent. The biochemical data indicate that the fluid has the features of a plasma ultrafiltrate, free of serum protein, and there is no increase of the sulfate or thiocyanate space. This type of edema occurs after triethyl tin poisoning, in water intoxication, hypercapnic hypoxia, and cyanide poisoning.

The edema that accompanies intracranial tumors is of the first type. The breakdown of the blood-brain barrier associated with tumor formation and edema of the adjacent white matter is demonstrated in plate XII through the kindness of Dr. Igor Klatzo. This shows a massive glioblastoma in the hypothalamic region and right basal ganglia in a patient who consented to receive an intravenous injection of fluorescein isothiocyanate shortly before his death.

Cerebral edema may follow the growth of any type of intracranial neoplasm, either intracerebral or extracerebral, whether benign or malignant. Thus it may be associated with the late stages in the growth of a meningioma or with a glioblastoma multiforme (pl. XII), but it is particularly apt to accompany the growth of rapidly expanding neoplasms such as **metastatic carcinomas.** Indeed with the latter the extent of the edema may bear no direct relationship to the size of the tumor, and relatively small solitary nodules of metastatic carcinoma may produce a quite disproportionate degree of edema of white matter that may be responsible for the clinical symptoms.

GROSS. The edema that accompanies intracranial tumors is essentially a **white matter** phenomenon (fig. 340). The cortex is not involved and the arcuate fibers are characteristically spared (pl. XII), perhaps because of differences in the water contents in this zone as compared to the centrum ovale (Adachi and Feigin). On the other hand edema has been shown to travel along certain fiber tracts (Clasen et al.), the corpus callosum being one of the routes of spread (pl. XII). On inspection the white

matter is obviously expanded (fig. 340), sometimes with a yellowish waxy tinge, and on palpation is softer than its contralateral side. In extreme cases cyst formation may occur. When adjacent to a nodule of mucus-secreting metastatic adenocarcinoma, the cysts may contain viscid greenish fluid that may stain rather faintly for mucin.

Consequent to the increased space occupied by the edematous brain, the ventricular system is displaced to the opposite side and the contralateral ventricular horn is raised and usually compressed (fig. 340); however, in cases when the tumor has also produced obstructive hydrocephalus, the contralateral ventricle will be dilated as well as displaced. Further complications include the various types of **internal herniations** with their vascular sequelae, to be described.

MICROSCOPIC. The histologic appearances of white matter edema are easily recognized under the light microscope, and consist in the presence of focal spongy changes with the formation of optically empty, oval, and circular spaces that tend to become confluent, and along the margins of which the processes of enlarged reactive astrocytes are often seen (fig. 341). In severe instances lakes of eosinophilic with the tinctorial properties of plasma material are found in the perivascular spaces and the adjacent neural tissues, presumably indicative of the extravasation of serum protein. An important astrocytic response takes place usually within 24 hours of the production of vasogenic edema. Although these changes are sometimes regarded as "regressive," there is fairly convincing evidence that the alterations in the astrocytes

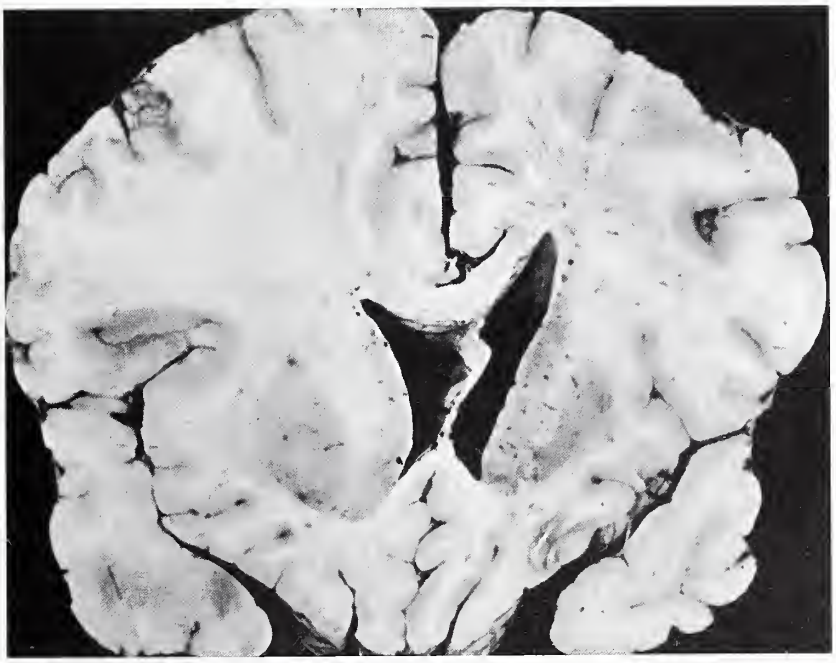

EDEMA OF CEREBRAL WHITE MATTER AND VENTRICULAR COMPRESSION

Figure 340. A coronal section anterior to a cerebral tumor shows edema of the left frontal centrum ovale with right-sided displacement of the ventricular system. The right lateral ventricle is slightly compressed and elevated.

PLATE XII

INCREASED PERMEABILITY OF BLOOD-BRAIN BARRIER IN CEREBRAL TUMOR AND ADJACENT WHITE MATTER

(Plate XII-A and B from same case)

This patient with a glioblastoma was injected one hour premortem with fluorescein isothiocyanate.

A. The brain at postmortem examination shows a glioblastoma occupying the hypothalamic region and extending into the right basal ganglia.

B. The same slice examined under ultraviolet light reveals the fluorescent dye which binds to serum albumin and demonstrates the areas in which the blood-brain barrier has broken down. The maximal fluorescence (yellow) is seen in the zone of tumor involvement. Less severe but definite fluorescence (green) is seen in the adjacent edematous white matter. Note the sparing of the arcuate fibers in the right middle and inferior frontal gyri. The edema has also spread in the corpus callosum and to a slight extent in the left central white matter. (Courtesy of Dr. Igor Klatzo, Bethesda, Md.)

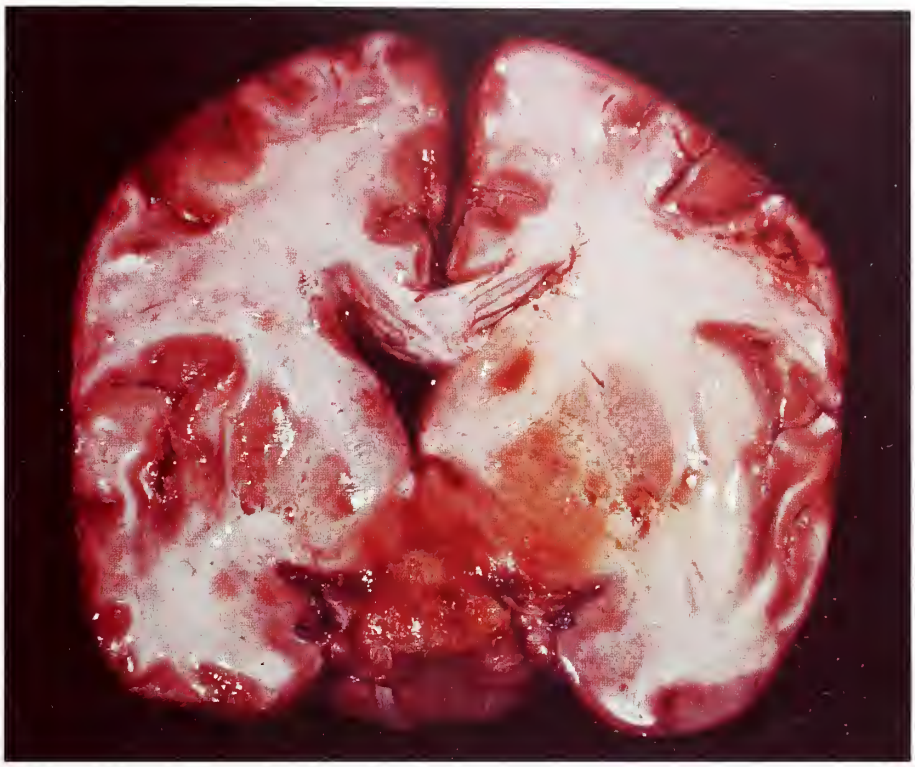

A

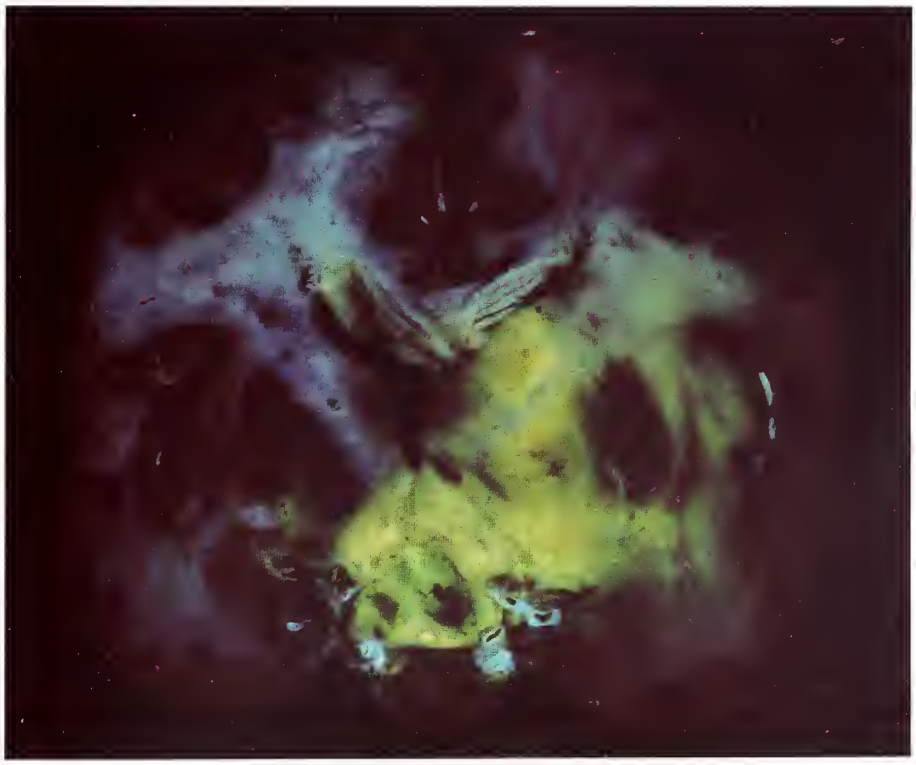

B

PLATE XII

are more likely the result of increased metabolic activity, presumably related to their role in the uptake of the extravasated serum proteins resulting from the breakdown of the blood-brain barrier. Thus enlargement of the astrocytes is seen in a variety of preparations (fig. 341), including frozen sections stained with dyes that have a strong affinity for tissue proteins (pl. XV-A), or impregnated by metallic methods (fig. 342).

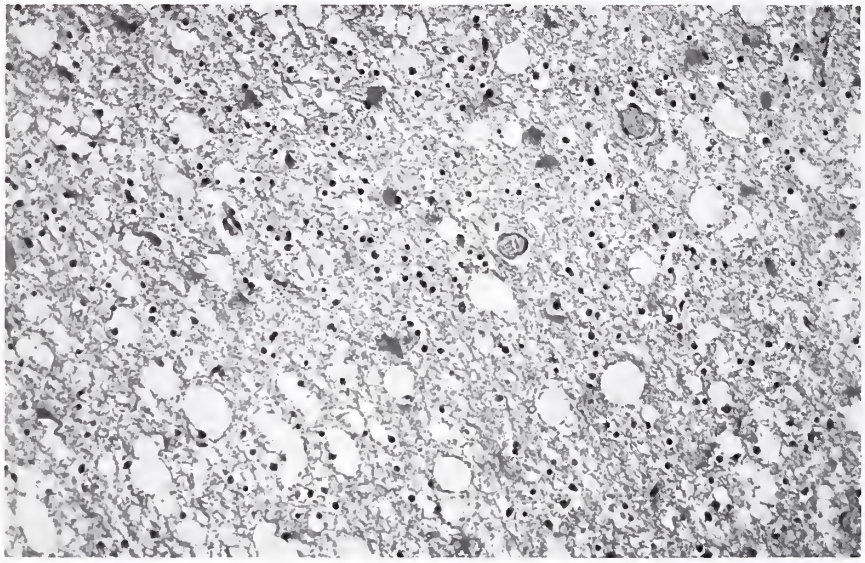

ACUTE EDEMA OF WHITE MATTER

Figure 341. Spongy vacuolation of the white matter typifies cerebral edema adjacent to metastatic carcinoma. Large reactive astrocytes are scattered throughout the field. × 135.

REACTIVE ASTROCYTIC HYPERTROPHY IN CEREBRAL EDEMA

Figure 342. There is marked enlargement of reactive astrocytes (a) in the white matter in cerebral edema following experimental cortical injury, compared to normal astrocytes (b) in the contralateral white matter. Cajal's gold chloride. × 220. (Figs. 9-A and B from Rubinstein, L. J., Klatzo, I., and Miquel, J. Histochemical observations on oxidative enzyme activity of glial cells in a local brain injury. J. Neuropath. Exp. Neurol. 21:116–136, 1962).

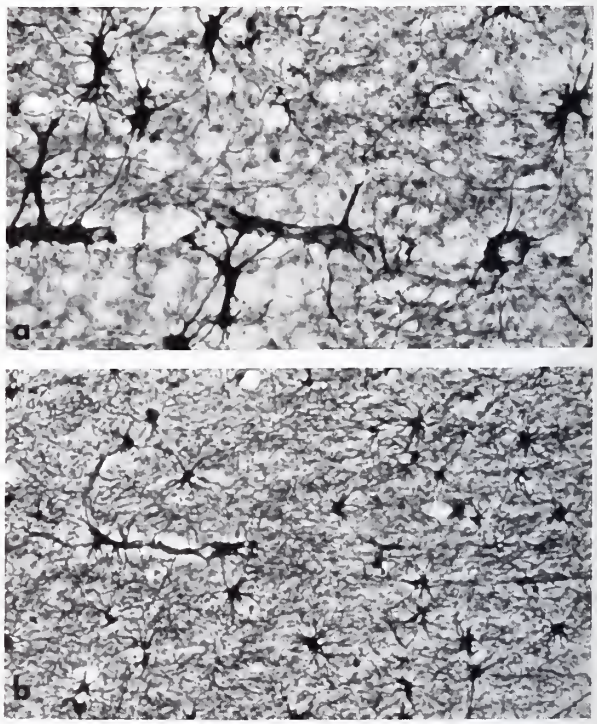

Fig. 342

Increased metabolic activity of the astrocytes is also suggested by their increased enzymatic reaction on incubation for tetrazolium reductase activity (fig. 343) and by the demonstration of their uptake of fluorescent-labeled protein inclusions (Rubinstein et al.), a phenomenon which appears similar to the mechanism of pinocytosis demonstrated in astrocytes grown *in vitro* (Klatzo and Miquel). The astrocytic reaction shows a moderate degree of lysosomal activity, as demonstrated in acid phosphatase preparations (fig. 344) and from the appearance by electron microscopy of increased numbers of membrane-bound osmiophilic bodies in the cytoplasm (fig. 345).

Observations have been made on the **ultrastructure** and **biochemical features** of cerebral edema associated with experimental neoplasms (Aleu et al.; Herzog et al.). In the early stages the edema in the tissue adjacent to the tumor is intracellular and present in the dilated cytoplasmic processes of glial cells. This is particularly the case in the neuropil of the gray matter (fig. 346). Enlargement of the extracellular space, however, soon appears, and may for a while be associated with distension of the cytoplasmic glial cell processes accompanied by rupture of their cell membranes (fig. 347). In the later stages, especially when the edema involves the deep white matter, the extracellular space shows wide distension with relative preservation of the myelinated axons and cell organelles (fig. 348). These data are in accord with the markedly increased water contents, sodium/potassium ratio, and labeled sulfate space present in the edematous white matter as compared to the normal.



INCREASED TETRAZOLIUM REDUCTASE ACTIVITY OF REACTIVE ASTROCYTES IN CEREBRAL EDEMA

Figure 343. There is increased tetrazolium reductase activity in the astrocytes of the white matter 30 hours after experimental cortical injury (a), compared to the normal reactivity of glial cells in the contralateral white matter (b). Sodium glutamate—dependent NADH tetrazolium reductase incubation. × 300. (Figs. 1-A and B from Rubinstein, L. J., Klatzo, I., and Miquel, J. Histochemical observations on oxidative enzyme activity of glial cells in a local brain injury. J. Neuropath. Exp. Neurol. 21:116–136, 1962).

REACTIVE ASTROCYTE IN CEREBRAL EDEMA. ACID PHOSPHATASE REACTION

Figure 344. A reactive astrocyte in the edematous white matter adjacent to a metastatic carcinoma shows discrete cytoplasmic granules in the perikaryon and cell processes positive for acid phosphatase. Gomori's lead nitrate method for acid phosphatase on frozen sectioned tissue fixed in cold formol-calcium. × 550.

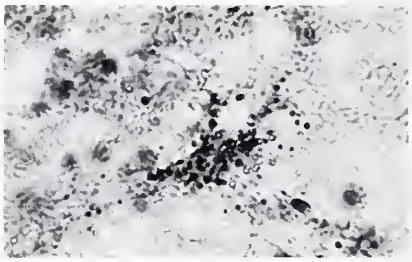

Fig. 344

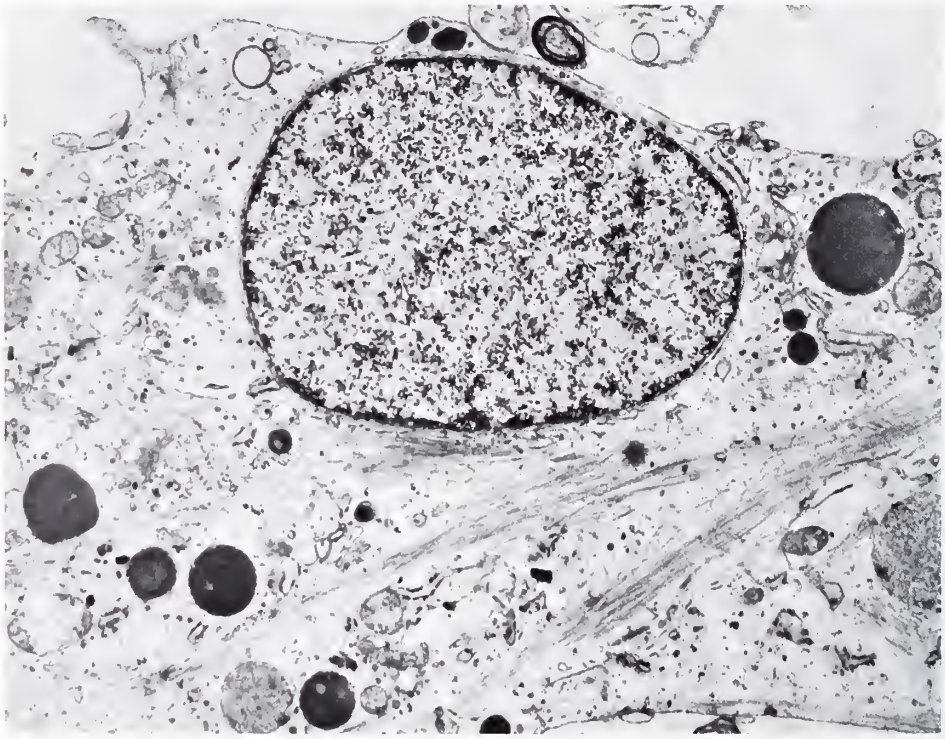

REACTIVE ASTROCYTE IN EXPERIMENTAL CEREBRAL EDEMA

Figure 345. An electron micrograph reveals an enlarged astrocyte in the parietal white matter of the cat 24 hours after ultraviolet radiation of the brain. Note the bundles of cytoplasmic glial filaments, and several membrane-bound osmiophilic bodies probably representing lysosomes. × 9000. (Courtesy of Dr. Mary M. Herman).

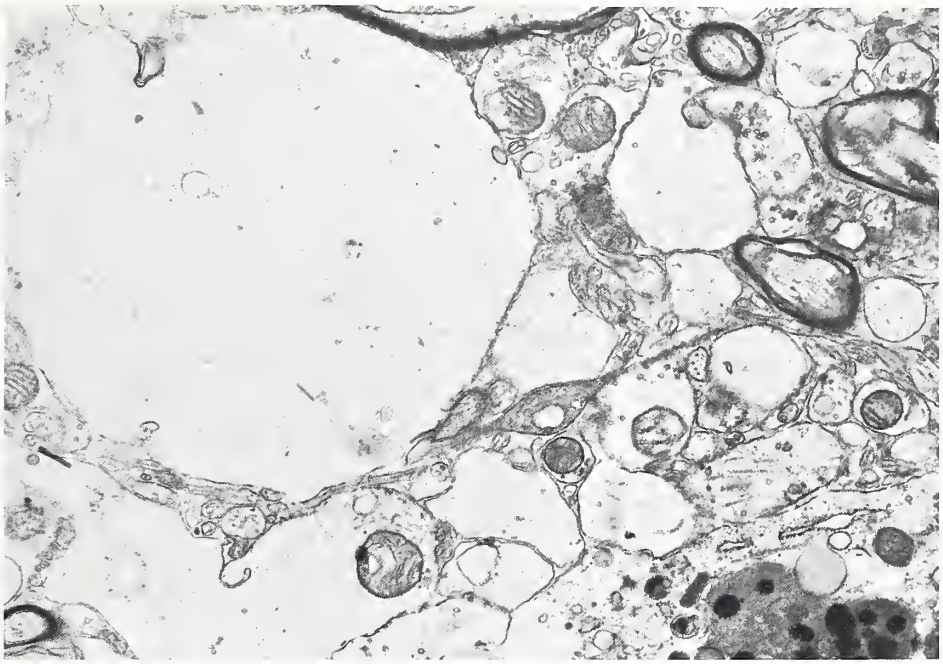

EARLY STAGE OF VASOGENIC CEREBRAL EDEMA

Figure 346. This is the early stage of vasogenic cerebral edema in the parietal cortex of the cat three hours after ultraviolet radiation of the brain. There is extreme distension of the pale cytoplasmic processes of glial cells, without enlargement of the extracellular space. The intracellular edema in the cortical neuropil produced in this experimental model is similar to the early stage of cerebral edema associated with experimental intracranial neoplasms. × 14,570. (Courtesy of Dr. Mary M. Herman).

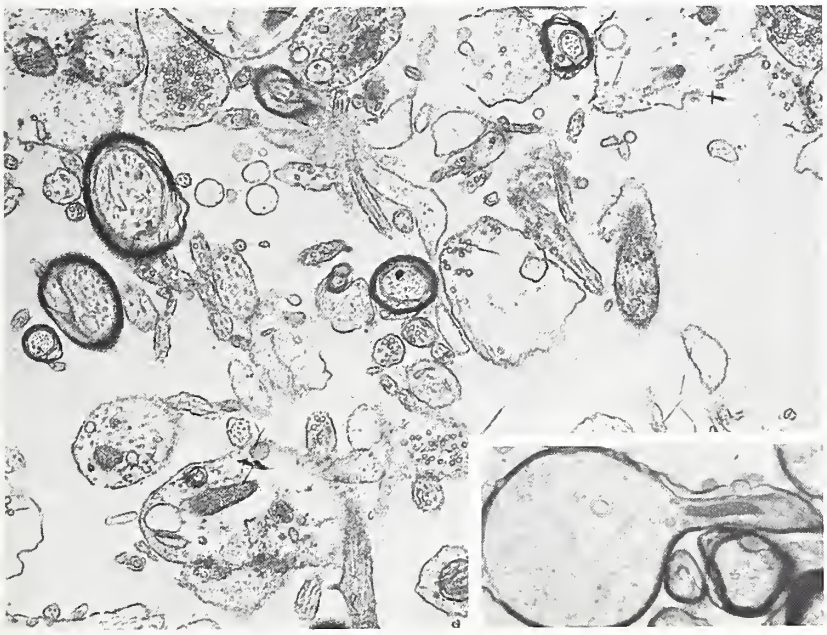

Fig. 347

EARLY STAGE OF VASOGENIC CEREBRAL EDEMA

Figure 347. Marked edema of the cortical neuropil is seen in a cat three hours after ultraviolet radiation of the brain. The edema is partly intracellular, with distension of the cytoplasmic processes, and partly extracellular. Several of the cell processes show rupture of their membranes. Note an intact synaptic complex in the left upper corner. × 14,000. Inset: Marked focal ballooning of a small myelinated axon is seen in the subcortical white matter. × 8000. (Courtesy of Dr. Mary M. Herman).

VASOGENIC EDEMA IN CEREBRAL WHITE MATTER

Figure 348. This illustrates white matter edema in the parietal lobe of a cat 24 hours after ultraviolet radiation of the brain. There is extreme enlargement of the extracellular space. The edema produced in this experimental model is similar to that associated with experimental intracranial neoplasms. × 14,000. (Courtesy of Dr. Mary M. Herman).

EFFECTS. As a result of the increased pressure produced by the tumor and the accompanying edema, several cycles are set into motion all of which will result in further pressure increases in the cranial cavity. Once the buffering effect of the other intracranial compartments becomes inadequate, further cell injury will lead to increased intracerebral edema and further disruption of the blood-brain barrier. These cycles will be aggravated by the effects of respiratory depression and hypoxia, themselves the result of increased intracranial pressure; the release of toxins and metabolites in the area of brain injury; the vascular dilatation resulting from the elevated temperature consequent on depression of body temperature regulation; and impairment of adrenocortical stimulation as a consequence of injury to the hypothalamic-hypophyseal system (Fox).

HYDROCEPHALUS

Obstruction of the cerebrospinal fluid pathways by tumor blocking either one of the foramina of Monro, or the aqueduct, or occupying a lateral ventricle is a well known mechanical complication of intracranial tumors that has been illustrated in this fascicle in several examples (frontispiece; figs. 3, 108, 137). Aside from the local obstruction produced by a solitary space-occupying lesion, hydrocephalus may also result from the generalized infiltration of the cerebrospinal leptomeninges by a diffusely growing neoplastic process, especially in gliomatosis, carcinomatosis, and melanomatosis. The various aspects of obstructive hydrocephalus have been described in Russell's monograph. A special etiologic variety of hydrocephalus is related to the hypersecretion of cerebrospinal fluid by choroid plexus papilloma. Reference to this phenomenon is found on page 257.

INTERNAL HERNIATIONS AND THEIR SECONDARY VASCULAR EFFECTS

As a result of increased intracranial pressure, certain parts of the brain are apt to herniate across internal openings particularly related to the dural folds. The consequences of these herniations are usually due to compression of the arteries along the free edges of the dural leaflets with the production of infarctions related to certain specific arteries of supply (Lindenberg). A unilateral frontal tumor frequently causes a herniation of the ipsilateral **cingulate** gyrus (fig. 349). In severe instances pressure by the free edge of the falx on one of the anterior cerebral arteries or its branches will lead to infarction in the distribution of that artery (Sohn and Levine). It is in association with this type of herniation that there is a special tendency for the contralateral ventricle to be compressed and elevated (fig. 340).

CINGULATE HERNIATION IN INCREASED INTRACRANIAL PRESSURE

Figure 349. Marked left cingulate herniation accompanies cerebral edema in a case of glioblastoma multiforme.

A superior frontal neoplasm may cause a herniation of the inferior aspect of the frontal lobe with consequent grooving of its posterior portion by the **sphenoidal ridge.**

A more dangerous type of herniation (**hippocampal**, or **tentorial herniation**) resulting from frontal, frontoparietal, or temporal lobe tumors involves the medial part of the temporal lobe through the tentorial opening (figs. 350, 351). In the early stage only grooving of the uncinate process may be present. In severe instances the entire hippocampal gyrus is herniated with resulting **compression** and **edema** of the **brainstem** (figs. 350, 351). The effects upon the latter are extremely important. In the early stages of unilateral herniation, compression of the brainstem against the contralateral free edge of the tentorium may produce wedging of the opposite cerebral peduncle with the clinical picture of the "false localizing sign" of the pyramidal tract, confirmed anatomically by the demonstration of the "Kernohan notch" (Kernohan and Woltman). Distortion of, and damage to, the compressed midbrain takes place in three major ways. At first there is side-to-side compression of the brainstem with narrowing of the aqueduct, which may be reduced to a narrow slit (fig. 350); the compression of the midbrain is uneven and the ipsilateral half of the midbrain is always wider due to edema, while the contralateral side is compressed (fig. 350). The second effect upon the brainstem consists in an anteroposterior elongation and a caudal shift of that structure. This is regarded by many as one of the principal mechanisms for the third form of damage, namely, the development of brainstem hemorrhages (figs. 351-353).

HIPPOCAMPAL HERNIATION IN INCREASED INTRACRANIAL PRESSURE

Figure 350. This severe right-sided hippocampal herniation is secondary to intracranial tumor. Early changes are seen in the brainstem; the ipsilateral half is slightly edematous and the contralateral half slightly compressed.

BRAINSTEM HEMORRHAGES

The mechanism of brainstem hemorrhages in increased intracranial pressure has been the subject of much dispute. There is no agreement on whether they are principally arterial or venous, and various mechanical theories have been suggested to explain their occurrence and distribution. Some workers ascribe their incidence largely to compromise of the venous return to the great vein of Galen, a view that is supported by the frequent tendency of these lesions to affect mostly the tegmental region (fig. 352). On the other hand another school holds that the hemorrhages are largely of arterial origin and distribution, involving the branches of the basilar artery, and are consequent to pressure on the rostral end of that vessel, to the caudal shift of the brainstem, and to the overstretching of the long perforating branches of the basilar artery, which are then directed obliquely toward the brainstem. It is certainly true that hemorrhages are often found in the distribution of the median and paramedian branches of the basilar artery (figs. 351, 353).

It is probable that in many cases these hemorrhages involve both the arterial and the venous systems. The lesions are often a combination of hemorrhage and hemorrhagic necrosis, the early stages being characterized by intense venocapillary congestion with extravasation of blood into the perivascular spaces, accompanied by edema of the surrounding parenchyma. These hemorrhages are typically associated with the rapid onset of unconsciousness and are in most instances directly related to the severity of the temporal herniation; in the great majority of cases, they are terminal. Occasionally, when the supratentorial pressure has been relieved, foci of old hemorrhagic necrosis are found in the brainstem.

Anatomically the areas most frequently involved are the median raphe in the lower midbrain and midpons, and the tegmental region in the upper and midpons (figs. 351-353). Other areas include the red nucleus and the cerebral peduncles (fig. 351). The lower pons and the medulla escape.

In evaluating the role of neurosurgical procedures in the pathogenesis of brainstem hemorrhages, Klintworth (1966) has suggested that decompression of supratentorial space-occupying lesions in patients with coma and manifesting hypertension might be a factor in their production. There is also some experimental evidence which suggests that they are dependent on adequate blood flow through the downward displaced brainstem and that they do not occur when accompanied by brainstem ischemia (Klintworth, 1965).

HIPPOCAMPAL HERNIATION SECONDARY TO INCREASED INTRACRANIAL PRESSURE

Figure 351. This closeup view of another example of hippocampal herniation shows severe tentorial grooving. The free edge of the tentorium has compressed the right posterior cerebral artery and its branches. The midbrain shows edema on the ipsilateral side, and brainstem hemorrhages are present in the red nucleus on the ipsilateral side, the peduncle of the contralateral side, and in the median raphe.

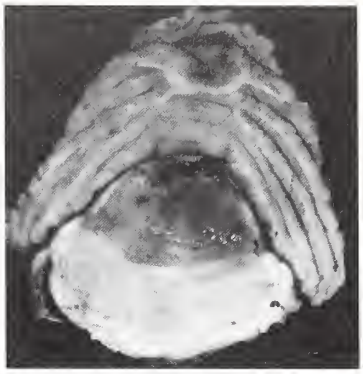

BRAINSTEM HEMORRHAGIC NECROSIS SECONDARY TO INCREASED INTRACRANIAL PRESSURE

Figure 352. Hemorrhagic necrosis is evident in the upper pons secondary to increased intracranial pressure by a large supratentorial space-occupying lesion. The main brunt of the lesion affects the tegmentum.

BRAINSTEM HEMORRHAGES SECONDARY TO INCREASED INTRACRANIAL PRESSURE

Figure 353. Hemorrhages in the midpontine region involve the median raphe, the basis pontis, and the tegmentum on one side.

Calcarine Infarction

One further consequence of hippocampal herniation results from the compression of the posterior cerebral artery and its branches by the free edge of the tentorium (fig. 351). This may produce hemorrhagic infarction in the distribution of that artery, which may be either unilateral or in severe instances bilateral (fig. 354). In the latter the involvement is asymmetric; on the more severely affected side, total infarction in the distribution of the posterior cerebral artery may be present, while on the other, infarction may be restricted to the calcarine cortex or an adjacent gyrus. Clinically this will cause unilateral field defects, another false localizing sign. Cases in which the hemorrhagic infarction is massive are associated with severe and almost always irreversible tentorial herniation, a fatal event. Occasionally the affected cortex presents the picture of an anemic arterial infarct, and in patients who survive it undergoes atrophy in the course of time. In such cases the herniation has been of a less fulminating character and has undergone reversion; the calcarine infarction then lacks the hemorrhagic features.

Cerebellar Herniations

In the posterior fossa, herniation of the cerebellar tissues may take place either upward through the tentorial opening or downward through the foramen magnum. Both may occur as the result of an expanding space-occupying mass in the posterior fossa. **Superior herniation** of the cerebellar hemispheres with notching of the cortical folia by the free edge of the tentorium is uncommon; it may sometimes follow rapid evacuation of a large supratentorial space-occupying lesion (fig. 355). This is presumably due to the inequality of pressure above and below the tentorium, which was demonstrated by Smyth and Henderson by simultaneous readings of the intraventricular and spinal fluid pressures; intraventricular readings were found to be from 20 to 100 mm. of

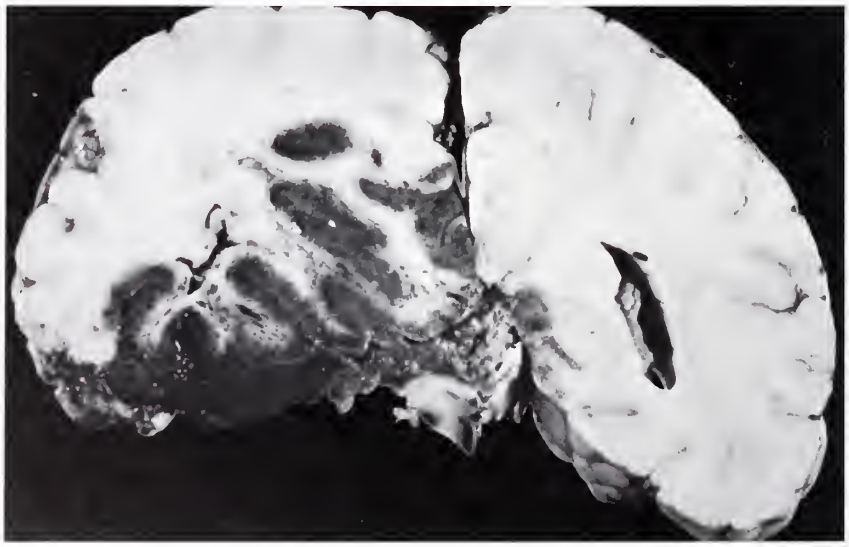

CALCARINE INFARCTIONS

Figure 354. Hemorrhagic cortical infarction involves the total supply of the posterior cerebral artery on one side and only the calcarine cortex on the other, in a case with severe hippocampal herniation secondary to increased supratentorial pressure.

water higher than the spinal. Evacuation of a large supratentorial mass in a case with increased supratentorial pressure would be a reasonable mechanism for this type of herniation, but then its rarity is surprising.

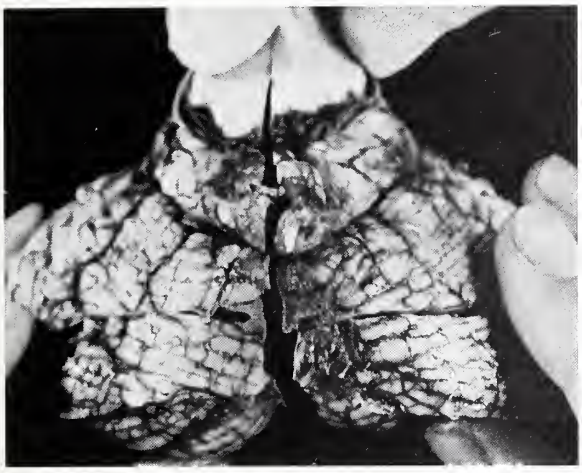

SUPERIOR CEREBELLAR HERNIATION WITH TENTORIAL NOTCHING

Figure 355. The cerebellum has herniated upward and a deep constriction is seen along its superior aspect due to tentorial notching. This patient had a subtotal excision of a large cerebral glioma. This complication is occasionally seen after rapid evacuation of a large supratentorial space-occupying lesion.

Downward herniation of the cerebellar tonsils into the foramen magnum (fig. 356) will result in edema followed by necrosis of the medulla and upper cervical cord if unrelieved. Compression of the dependent tonsillar folia against the edges of the foramen magnum may produce superficial cortical hemorrhages (fig. 356). In even more severe cases hemorrhagic necrosis of the tonsils may occur, and as these structures are squeezed into the spinal subarachnoid space, cerebellar parenchymatous tissue may be deposited in the leptomeninges of the more dependent portions of the spinal cord and grossly mimic in extreme instances the picture of metastatic subarachnoid metastases.

PRESSURE EFFECTS ON THE PITUITARY GLAND

Foci of anemic infarction in the pars distalis of the adenohypophysis are a frequent finding in cases with increased intracranial pressure. The mechanism is probably compression of the pituitary stalk with resulting impairment of circulation in the portal hypophyseal system (Wolman). Tentorial herniation is frequently associated with this event.

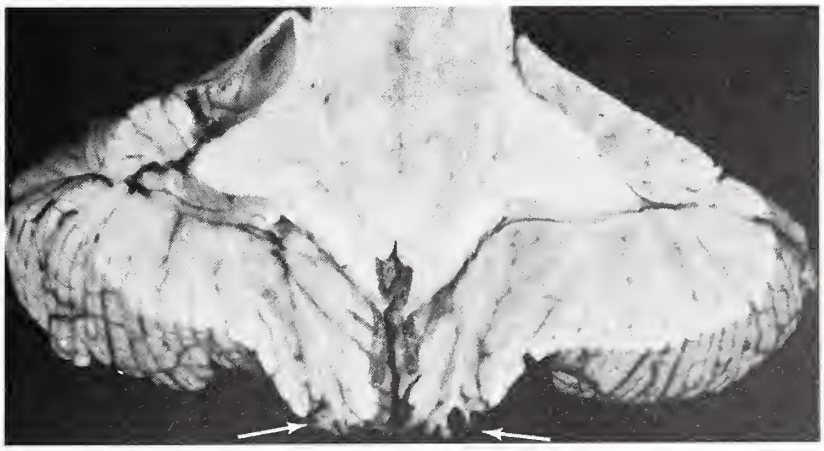

TONSILLAR CEREBELLAR HERNIATION

Figure 356. There is downward protrusion of the cerebellar tonsils due to increased generalized intracranial pressure. Note the small, dark, cortical hemorrhages in the most dependent part of the tonsillar folia (arrows) due to contusion of the tonsils against the edges of the foramen magnum.

PRESSURE EFFECTS ON THE DURA AND SKULL

Pressure resulting from intracranial tumors, especially basal or temporal, may result in transdural herniation of the brain, and in pressure effects upon the bone of the middle fossa, the orbital plate, and the dorsum sellae. Flattening of the latter structure, accompanied or preceded by erosion of the posterior clinoid processes, is an early and frequent radiologic feature of raised intracranial pressure. In young subjects increased intracranial pressure, especially of long standing, will produce characteristic zones of bony rarefaction over the convexities with the picture of increased convolutional markings and, in extreme examples, the well known "silver beating" appearance on radiography of the skull.

EFFECTS OF INTRASPINAL NEOPLASMS ON THE SPINAL CORD

The most important consequence of intraspinal extramedullary neoplasms is spinal cord compression. This is characterized by a patchy myelomalacia that tends to spare the gray matter and mostly involves the white. Microscopically the picture is that of an irregular spongy state of the cord parenchyma, usually starting in its more peripheral zones, unaccompanied by conspicuous astroglial reaction, and distinct from the sharp, well defined infarcts that result from arterial occlusion. Secondary demyelination may occur in the more long-standing cases. Even in patients who have had spastic paraplegia with flexor spasms for several days, relief of the paraplegia has been obtained by operative decompression and removal of the compressing tumor (Barron et al.).

References

Adachi, M., and Feigin, I. Cerebral oedema and the water content of normal white matter. J. Neurol. Neurosurg. Psychiat. 29:446–450, 1966.

Aleu, F. P., Edelman, F. L., Katzman, R., and Scheinberg, L. C. Ultrastructural and biochemical analysis in cerebral edema associated with experimental mouse gliomas. J. Neuropath. Exp. Neurol. 23:253–263, 1964.

Barron, K. D., Hirano, A., Araki, S., and Terry, R. D. Experiences with metastatic neoplasms involving the spinal cord. Neurology 9:91–106, 1959.

Clasen, R. A., Cooke, P. M., Pandolphi, S., Boyd, D., and Raimondi, A. J. Experimental cerebral edema produced by focal freezing. I. An anatomic study utilizing vital dye techniques. J. Neuropath. Exp. Neurol. 21:579–596, 1962.

Fox, J. L. Development of recent thoughts on intracranial pressure and the blood-brain barrier. J. Neurosurg. 21:909–967, 1964.

Herzog, I., Levy, W. A., and Scheinberg, L. C. Biochemical and morphologic studies of cerebral edema associated with intracerebral tumors in rabbits. J. Neuropath Exp. Neurol. 24:244–255, 1965.

Kernohan, J. W., and Woltman, H. W. Incisura of crus due to contralateral brain tumor. Arch. Neurol. 21:274–287, 1929.

Klatzo, I. Neuropathological aspects of brain edema. J. Neuropath. Exp. Neurol. 26:1–14, 1967.

———, and Miquel, J. Observations on pinocytosis in nervous tissue. J. Neuropath. Exp. Neurol. 19: 475–487, 1960.

———, and Seitelberger, F. Brain Edema. New York: Springer-Verlag, 1967.

Klintworth, G. K. The pathogenesis of secondary brainstem hemorrhages as studied in an experimental model. Amer. J. Path. 47:525–536, 1965.

———. Evaluation of the role of neurosurgical procedures in the pathogenesis of secondary brainstem haemorrhages. J. Neurol. Neurosurg. Psychiat. 29:423–425, 1966.

Lindenberg, R. Compression of brain arteries as pathogenetic factor for tissue necroses and their areas of predilection. J. Neuropath. Exp. Neurol. 14:223–243, 1955.

Rubinstein, L. J., Klatzo, I., and Miquel, J. Histochemical observations on oxidative enzyme activity of glial cells in a local brain injury. J. Neuropath. Exp. Neurol. 21:116–136, 1962.

Russell, D. S. Observations on the Pathology of Hydrocephalus. Medical Research Council Special Report Series No. 265. Special Reprint 1966. London: Her Majesty's Stationery Office, 1949.

Smyth, G. E., and Henderson, W. R. Observations on cerebrospinal fluid pressure on simultaneous ventricular and lumbar punctures. J. Neurol. Neurosurg. Psychiat. 1:226–238, 1938.

Sohn, D., and Levine, S. Frontal lobe infarcts caused by brain herniation. Compression of anterior cerebral artery branches. Arch. Path. 84:509–512, 1967.

Stern, W. E. The contribution of the laboratory to an understanding of the cerebral edemas. Neurology 15:902–912, 1965.

Wolman, L. Pituitary necrosis in raised intracranial pressure. J. Path. Bact. 72:575–586, 1956.

RADIATION CHANGES IN INTRACRANIAL NEOPLASMS AND THE ADJACENT BRAIN

EFFECTS OF RADIATION ON INTRACRANIAL TUMORS

The effects of ionizing radiation on human intracranial tumors are difficult to assess objectively. Controlled data on their radiosensitivity are not available, and the inaccessibility and histologic heterogeneity of many brain tumors only permit a subjective evaluation of the cytologic changes to be made on postmortem material. The radiosensitivity of brain tumors, the radiologic modalities and technics, and the methods and results of treatment according to the different tumor types have been reviewed by Schulz and associates. There is disagreement on the radiosensitivity of the various types of intracranial neoplasms, but there is a wide consensus that the most primitive and embryonal forms are the most radiosensitive, and that this is especially valid for the **medulloblastoma**, in which the proper treatment is radiation of the entire neuraxis. There is also general agreement that the **germinoma** responds well to radiation, and a definite clinical impression that **tumors of the lymphoreticular system**, both primary and secondary, are radiosensitive.

Objective data on the clinical efficacy and long-term effects of radiotherapy on intracranial tumors, especially primary gliomas, are available only from **animal experimentation.** The results of **single** doses of gamma radiation on experimentally induced gliomas are highly variable (Tansley and Wilson; Netsky et al.). The latter have critically reviewed the difficulties of determining the value of radiation treatment in human gliomas. They also noted the liability of experimental tumors treated with single high doses of x-rays (3000 to 5000 R) to grow again after initial regression. On occasion this regrowth was extremely rapid, a development they interpreted as perhaps due to the stimulation of tumor areas that had been either unradiated or exposed to inadequate doses of radiation. More recent experimental work has shown that if **fractional** doses of radiation are delivered, total destruction of the neoplasm can be achieved (Edelman et al.).

From a morphologic point of view the most obvious effect of radiation on both human and experimental tumors is the development of extensive **necrosis.** In human material the interpretation is evidently subject to caution owing to the well known propensity of malignant gliomas to undergo necrosis spontaneously. Nevertheless repeated experience in the examination of radiated gliomas will convince the observer that necrosis is usually far more widespread than is to be expected in unradiated examples. In some instances tumor, as originally diagnosed in a previous biopsy, may no longer be found at the site of radiation. This is a frequent phenomenon in the case of medulloblastomas, even when the terminal picture is that of widespread metastasis through the cerebrospinal fluid pathway.

Only a few foci of residual microscopic tumor were found at the primary site in the vermis, in the example of medulloblastoma illustrated in figures 161, 162, 164, and 166. A similar disappearance of the neoplasm may be obtained in cases of radiated pineal germinoma, and occasionally in instances of primary or secondary lymphomatous proliferation involving the central nervous system and its coverings.

A frequent radiation effect consists in an alteration of tumor **cytologic characteristics.** This interpretation calls for caution in view of the well documented liability of gliomas to undergo histologic changes in the course of time. However, in tumors in which the cells are characteristically uniform, the presence of large multinucleated giant cells with swollen hyaline eosinophilic cytoplasm, bizarre or grotesque alterations in cell shape, hyperchromatism and irregularity of the nuclei, and abnormal mitotic figures are widely accepted as resulting from radiation (fig. 148; Oppenheimer). Similar morphologic changes in radiated experimental tumors have been illustrated by Tansley and Wilson, and by Netsky and associates.

Although according to the latter authors the vascular changes seen in experimental tumors are minimal, this does not appear to be the case in human radiated gliomas. On the contrary the **vascular exudative** and **proliferative changes,** the subsequent **degenerative** alterations in the thickened hyalinized and occluded blood vessels (pl. XIII-E), and the perivascular and parenchymatous collagenous proliferations characteristic of the radiated brain are frequently found in human postmortem tumor material. They constitute an important diagnostic hallmark for the recognition of radiation changes in brain tumors.

EFFECTS OF RADIATION ON THE NORMAL BRAIN AND ON THE BRAIN ADJACENT TO INTRACRANIAL TUMORS (RADIONECROSIS)

An appreciation of the radiation changes in the brain adjacent to radiated glioma is of considerable importance from both the clinical and the pathologic standpoint. Clinically the alterations in the brain parenchyma may result in a picture that mimics recurrence of the neoplasm. This development is found in its purest form in cases in which the normal brain has undergone a process of **radionecrosis** that simulated a space-occupying lesion following radiation of a tumor outside the central nervous system, such as a pituitary adenoma (Crompton and Layton; Bignami et al.) or a basal cell carcinoma of the scalp (Pennybacker and Russell; Mandybur and Gore). From the pathologic point of view an awareness of the characteristic gross and microscopic changes is important for the recognition of radionecrosis in the absence of a brain tumor, and for an evaluation of radiation effects on patients in whom a brain tumor was present. These effects are often seen in the brain adjacent to the glioma, and it is possible that the contiguous brain may be more vulnerable to radiation than the normal central nervous system parenchyma.

EARLY DELAYED EFFECTS. The effects with which we are concerned are specifically termed delayed effects. They can themselves be divided into early and late. Until recently most descriptions of human cases of radionecrosis have been concerned with the latter; attention has now been drawn to the picture of early delayed effects (Lampert and Davis). These are usually seen within three months after the initial dose of radia-

tion, and consist of multiple punched-out foci of demyelination that resemble the lesions of multiple sclerosis. The blood vessels show no degenerative changes, but display perivascular infiltration by lymphocytes and plasma cells. Lampert and Davis believe that the lesion developed on the basis of an autoimmune response, in which demyelination is conceivably the primary pathologic process.

LATE DELAYED EFFECTS. The late delayed effects of radiation are usually seen months or even years after initial radiotherapy.

GROSS. The quite distinctive picture is seen both in "pure" radionecrosis, that is in normal brains accidentally exposed to radiation because of a neoplastic process outside the central nervous system, and in areas of the brain adjacent to a radiated tumor (fig. 357). Typically the neural parenchyma has the appearance of being replaced by an ill-defined, firm, space-occupying mass that mimics a diffusely infiltrating glioma both on inspection and palpation. The distinction between gray and white matter is blurred and the outlines of the normal neuroanatomy are lost. However, only the white matter is the usual site of vulnerability. In some cases it is softened as well as expanded, with a yellow waxy color occasionally tinged with pink, and shows isolated red or brown pinpoint petechial hemorrhages. In some examples foci of more severe softening are present and the white matter is granular and crumbly (fig. 358). Rarely cystic cavitation is found. The arcuate fibers of the white matter tend to be spared by the process. In extreme and long-standing cases the affected lobe is reduced in size because of the loss of white matter, and the latter is gray as well as cystic. Even in these cases the cortical gray matter often appears grossly normal, although microscopic alterations may be found on histologic examination.

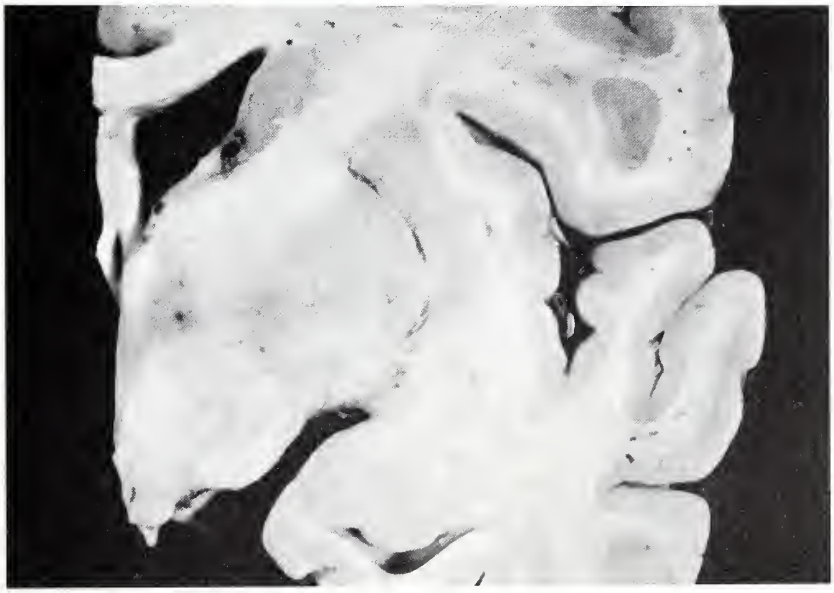

RADIATION EFFECTS ON THE BRAIN

Figure 357. Homogeneous, firm, whitish tissue replaces and obscures the hypothalamic region in a case of radiated glioma. Microscopically this area showed radiation effects only and no viable tumor.

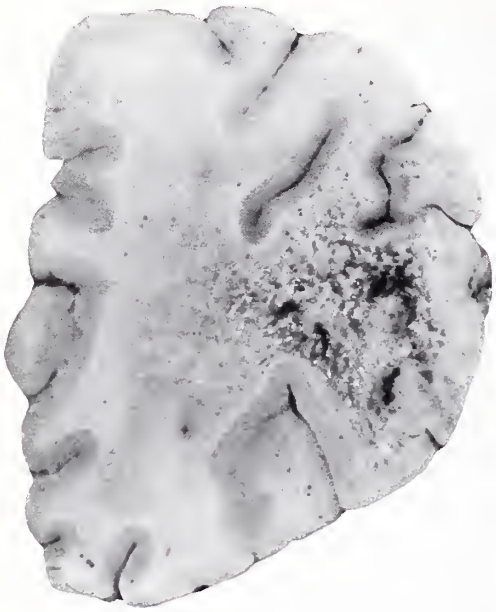

RADIATION EFFECTS ON THE BRAIN

Figure 358. Foci of confluent softening are seen in the digitate white matter of the middle frontal gyrus anterior to an astrocytoma that was radiated two years previously. The surrounding white matter showed a waxy yellow discoloration.

MICROSCOPIC. The histologic appearances are multiple and varied. In many areas the picture may be that of a simple coagulative necrosis with a lack of staining affinity of the parenchymal elements, and little or no accompanying inflammatory cellular reaction. Ghosts of nerve cells, glial cells, and blood vessels only may be seen and the neural parenchyma has been transformed into a homogeneous eosinophilic tissue. In other areas **demyelination** may be the most striking feature, characterized by a loss of oligodendroglial cells and myelin sheaths. Usually there is a severe reduction in the number of axons, some of which may show beaded swellings analogous to those commonly seen in other degenerative and necrotizing processes. These changes are accompanied by a marked macrophagic reaction characterized by the large numbers of foam cells containing sudanophilic lipid in the demyelinated tissue. Accompanying this process, perivascular infiltrations by inflammatory cells are seen, some of which are foamy macrophages (fig. 359) while others may be mixtures of lymphocytes and plasma cells. In some cases plasma cells appear unusually abundant, and excessive numbers of eosinophilic leukocytes have also been noted (Crompton and Layton). This cellular infiltrate is present both in the Virchow-Robin spaces and in the overlying leptomeninges.

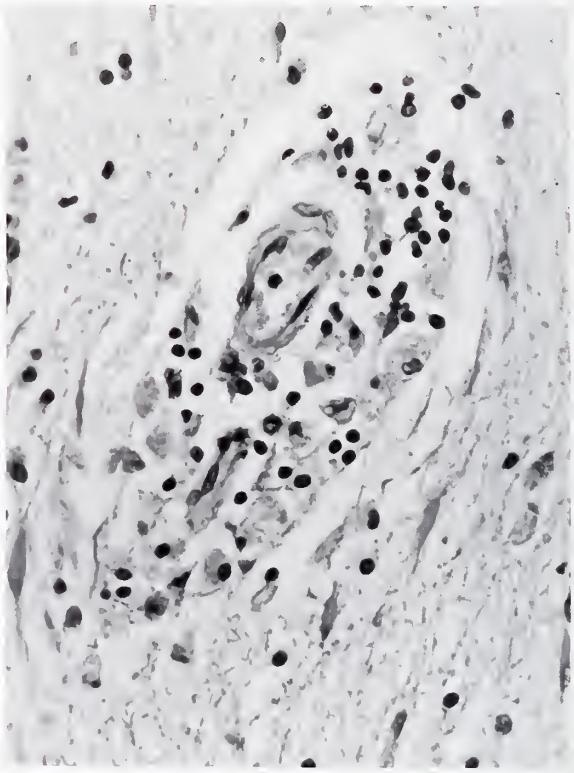

RADIATION CHANGES

Figure 359. A perivascular cellular inflammatory response is present in the radiated brain, consisting of lymphocytes and foamy macrophages. The surrounding brain shows astrocytic gliosis. × 380.

The vascular changes are among the most striking and have been repeatedly emphasized. The most characteristic and virtually diagnostic alteration consists in a fibrinoid necrosis of the blood vessel walls, which may be partial or complete and is often seen to merge with the deposition of a thin layer of mural fibrinoid material inside their lumens (pl. XIII-B). Associated with vascular mural necrosis, there is infiltration of the adjacent brain by strands of extravasated fibrinous material (pl. XIII-B), which in other places has become inspissated into the central nervous tissue parenchyma (pl. XIII-A, C). A further accompaniment is the presence of recent parenchymatous hemorrhages, some of which may form rings adjacent to a necrosed blood vessel. Thrombotic occlusions of various ages are also a frequent feature (pl. XIII-D). It should be emphasized that these vascular changes are classically indicative of late delayed radiation effects. Yet morphologically they suggest a recent acute process.

In adjacent areas changes are present in the blood vessel walls that are obviously older. These consist in proliferations of the vascular endothelium (fig. 360) which may ultimately result in obliteration of the lumen, and of various degrees of periadventitial fibroblastic proliferations that appear to extend from the vessel wall into the adjacent neural parenchyma (fig. 361). Still more chronic vascular lesions are seen in contiguity, consisting of extensive and frequently confluent fibrous acellular hyaline thickenings of the blood vessel walls (pl. XIII-C, E) that result in virtually complete occlusion of these vessels. Focal calcifications may be present. In other areas the vessel lumen is occluded by a more uniform delicate fibrous connective tissue (pl. XIII-F), possibly the end-result of former thrombosis. The hyaline material seen in blood vessel walls is also found in central nervous tissue parenchyma, where it may be intimately mixed with lakes of fibrinoid material (pl. XIII-C). The relationship between hyaline material deposited in the brain and that which is found in the blood vessel wall is not always clear. As shown in plate XIII-C, transitions are found between the fibrinoid and the hyaline material, suggesting that in the course of time the former may have become converted into the latter. In some cases this material, which is now no longer fibrinoid but stains brown with van Gieson,

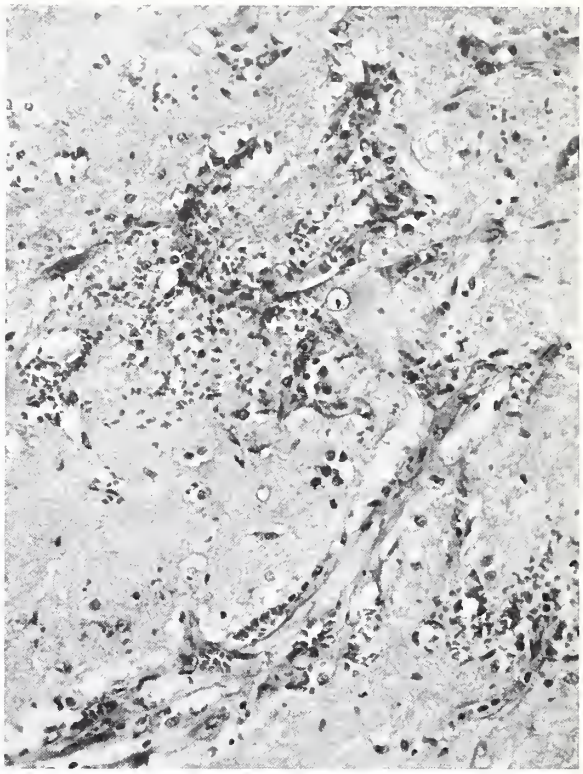

RADIATION CHANGES

(Figure 360 and Plate XIII-B from same case)

Figure 360. Vascular endothelial proliferation is seen in the deep cortical gray matter of a brain with radiation necrosis three years after radiotherapy for a nasopharyngeal carcinoma. × 192.

takes up congo red and has been identified as amyloid (Mandybur and Gore). It is apparent from published reports that its various staining reactions for amyloid are inconstant.

The vascular alterations may also take the form of large irregular **telangiectatic** dilatations of the small capillaries, which may contain laminated thrombotic material (pl. XIII-D).

Changes in the **neuroglia**, although less conspicuous than those affecting the vascular elements, are nevertheless important. There is hypertrophy of, and increased fiber formation in, the astrocytes (fig. 362).

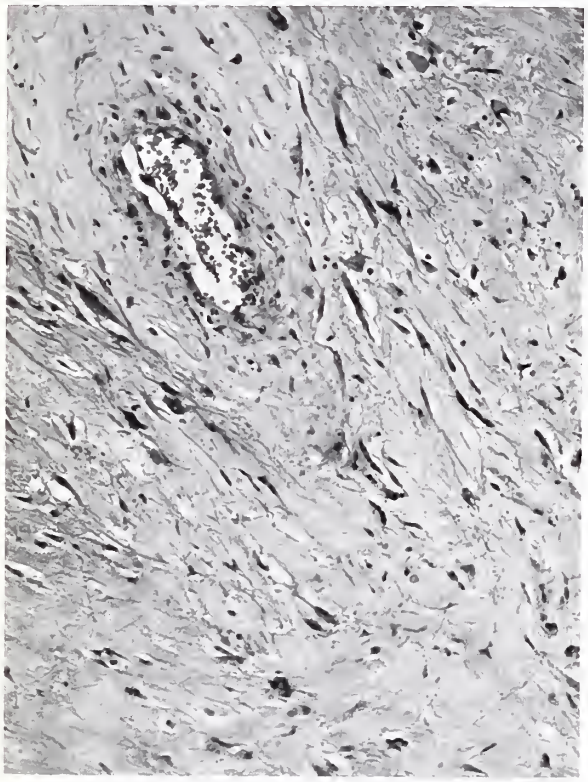

RADIATION CHANGES

Figure 361. Hyaline thickening of a blood vessel wall is seen (upper left) with proliferation of adventitial fibroblasts extending from the vessel wall into the adjacent radionecrotic brain. × 133.

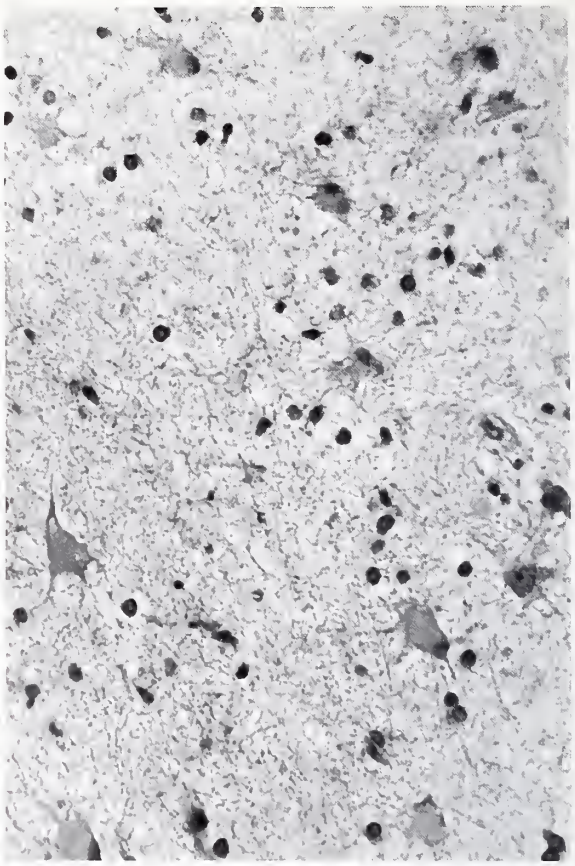

RADIATION CHANGES

Figure 362. There is marked hypertrophy of astrocytes in this brain showing radionecrosis two years after x-ray treatment for a lacrimal gland tumor. × 340.

Admittedly the significance of this reaction following radiation is limited in view of the frequency with which edema associated with a similar change in the astrocytes is found in the white matter adjacent to the tumor. However, in the adjacent radiated brain, the nuclei of the reactive astrocytes often show considerable irregularity and hyperchromatism, and occasionally bizarre multinucleated giant cells are found in areas far removed from the radiated neoplasm. Similar glial cell abnormalities have been described in the radiated brains of humans and primates by Arnold and Bailey.

Extensive and relatively **acellular** fibrosis may also be a feature of the radiated brain adjacent to a tumor. The source of this mesenchymal tissue is not always clear. In some cases it may be presumed to have arisen from the proliferation of periadventitial fibroblasts from the blood vessel walls, but in many instances these areas of fibrosis do not appear associated with the presence of large numbers of blood vessels, nor topographically related to the meninges. These changes are often found in the depths of the brain, mostly in the white matter. In some instances areas of intense fibrosis are found adjacent to zones that still contain lakes of fibrinoid material. Frequently central fibrosis is surrounded by a peripheral zone of hypercellular or fibrillary gliosis, and in places islands of reactive neuroglial tissue are encompassed by poorly cellular zones rich in collagen fibers (pl. XIII-G). It is difficult on histologic grounds to dismiss altogether the possibility that fibrinoid material could have converted directly into collagen.

One of the most characteristic features of delayed effects of radiation on the central nervous system is their preponderant affinity for the white matter. However, in very long-standing cases of several years duration, even the **cortex** may show pronounced alterations consisting of neuronal cell losses and degeneration, usually in the deeper layers, which may be accompanied by calcifications (fig. 363). Vascular changes including fibrinoid necrosis and hyaline thickening of the blood vessel walls may also be found in the cortex, although usually to a lesser degree than in the white matter.

Radiation effects on the **cerebellar cortex** in man have seldom been described. They may be seen after radiation for medulloblastoma or cerebellar astrocytoma, and occasionally following radiation of the brainstem for a pontine glioma. As in the white matter changes described above, both recent and obviously long-standing chronic degenerative lesions are seen. The "earliest" change is the formation of small optically empty spaces in the Purkinje cell layer that enlarge to become confluent and form a lacy pattern of vacuoles between the Purkinje cells and the granular neurons (fig. 364). This is accompanied by loss of granular neurons, which may be patchy or diffuse. Loss of Purkinje cells occurs also, but may not be complete. The central and digitate subcortical white matter shows obvious fibrillary gliosis. These appearances are highly suggestive of a process that starts as an edematous change within the lamina dissecans and then increases by confluence. In

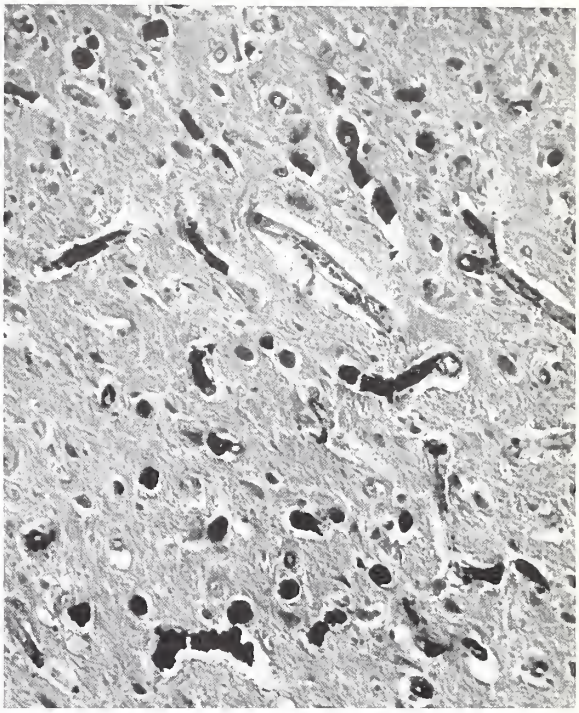

RADIATION CHANGES. EFFECTS ON CEREBRAL CORTEX

Figure 363. Neuronal cell loss is accompanied by focal calcifications in the deeper layers of the cerebral cortex eight years after x-radiation. × 108.

PLATE XIII

RADIATION CHANGES

(Plate XIII-A, C, and E from same case)

A. Extravasation of fibrinoid material is seen in radiated brain adjacent to an astrocytoma. Fibrous hyaline thickening of the blood vessels is present in the left upper corner. PTAH. × 180.

(Plate XIII-B and Figure 360 from same case)

B. Fibrinoid necrosis of the blood vessel wall is shown with radial strands of fibrin extravasation into the adjacent white matter. This is from a case of radionecrosis of the brain, three years following radiation of a nasopharyngeal carcinoma. PTAH. × 160.

C. Irregular extensions of fibrinoid (blue) and hyaline (pink) material, presumably of different ages, often surrounding thickened hyalinized blood vessels, are present in radiated brain adjacent to an astrocytoma. The pink structure in the left upper corner is probably the remnant of a thickened hyalinized, occluded blood vessel. PTAH. × 70.

(Plate XIII-D and Figures 6, 29, and 74–78 from same case)

D. A large irregular telangiectatic blood vessel is seen in the edematous white matter surrounding a radiated glioma. The blood vessel wall shows focal hyaline thickening in the left lower corner. It is partly filled by laminated thrombotic material. The myelin is normal along the right lower edge of the illustration, and pale, due to edemo, in the remainder of the field. PTAH. × 30.

E. Clusters of greatly thickened hyalinized and occluded blood vessel walls are illustrated in a radiated astrocytoma. H & E. × 120.

(Plate XIII-F and G from same case)

F. There is complete occlusion of an arteriole by pink delicate fibrous connective tissue in the white matter adjacent to a radiated primary cerebral sarcoma. The intact internal elastic lamella is well seen in places. PTAH. × 265.

G. A mixture of longstanding fibrosis (pink) and islands of reactive, highly fibrillated neuroglia (blue) is seen in the brain adjacent to a radiated polymorphic cell sarcoma. PTAH. × 165.

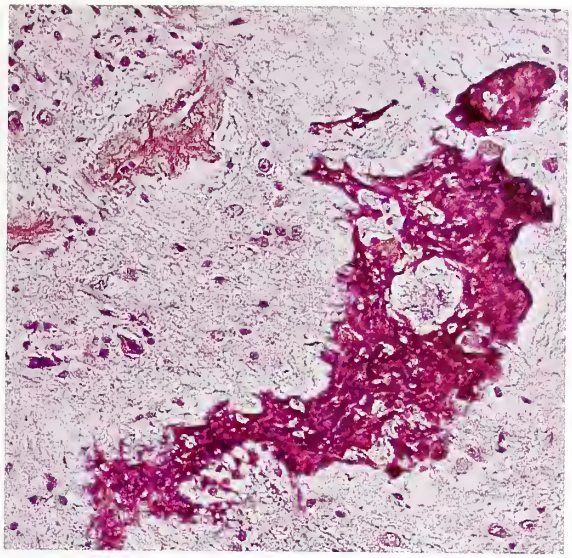

A

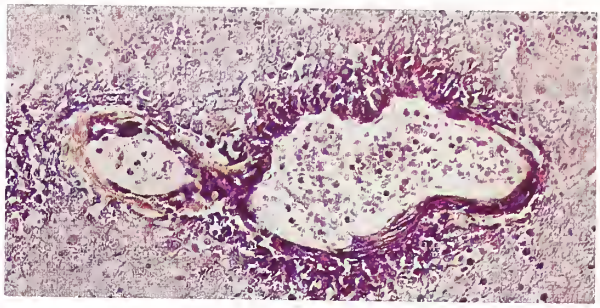

B

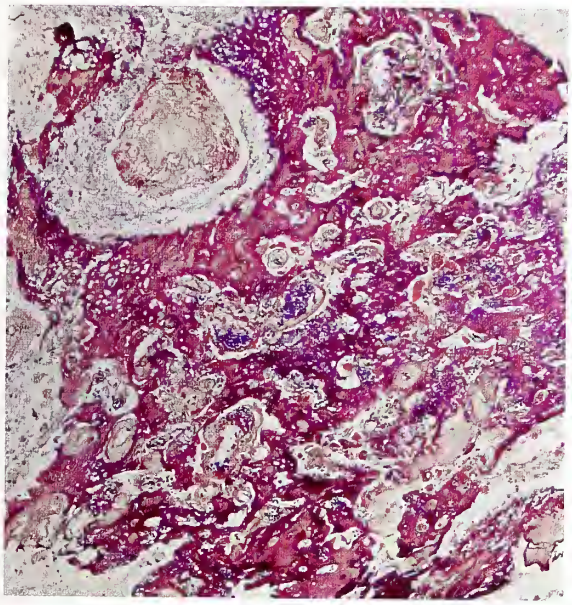

C

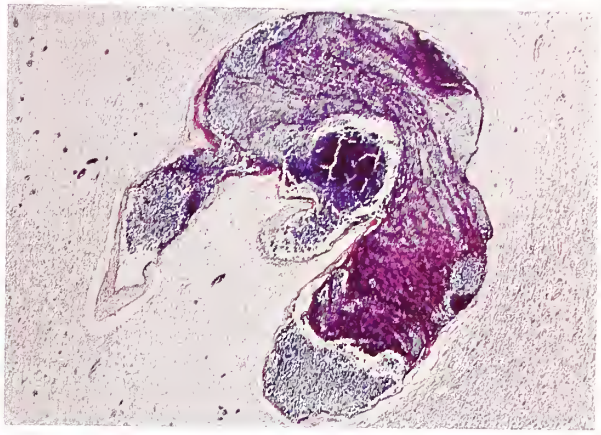

D

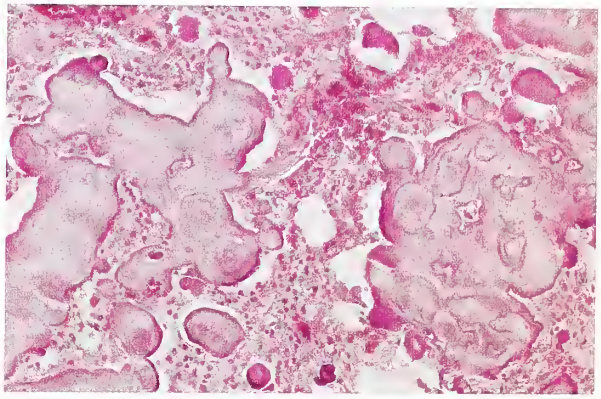

E

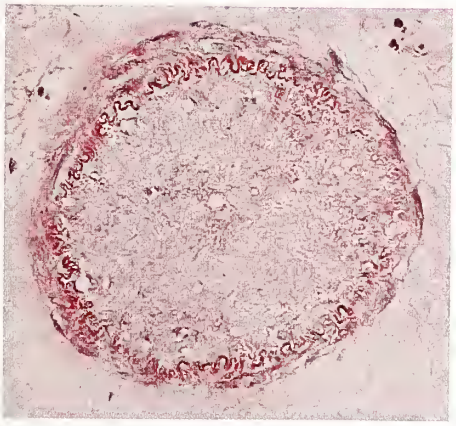

F

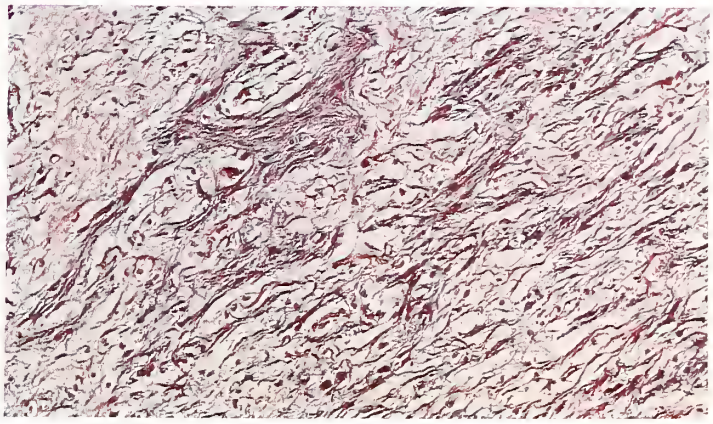

G

PLATE XIII

the late stages there is striking devastation of the cerebellar folia, the residual cortex presenting as poorly cellular and highly fibrillary ribbons without recognizable Purkinje cells or granular neurons, but showing a remarkable degree of laminar fenestration that seems to follow the contours of the folia (fig. 365). This is accompanied by focal calcifications and by the presence of extravasated fibrinoid material that seems to spread radially along the surviving fibers of the molecular layer. The blood vessels of the leptomeninges and cortex may show considerable fibrous hyaline thickening.

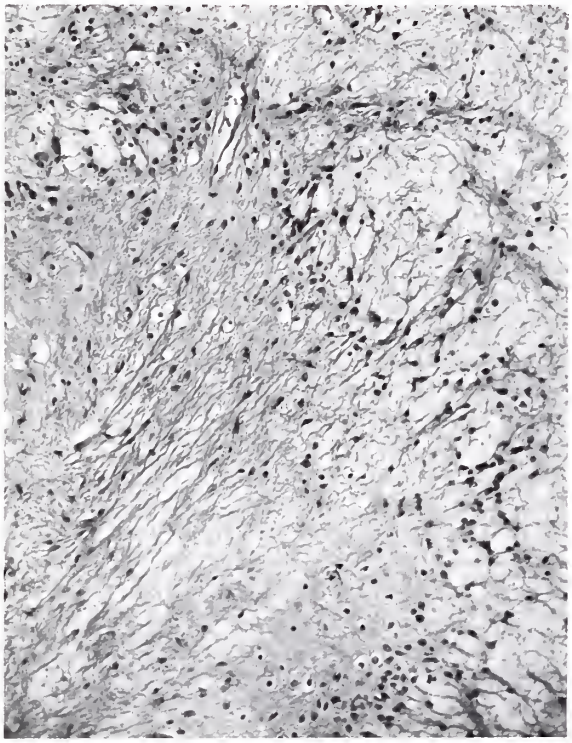

RADIATION CHANGES. EFFECTS ON CEREBELLAR CORTEX

Figure 364. There is loss of granular neurons and Purkinje cells, with multiple vacuolations in the Purkinje cell layer and in the molecular layer, and white matter demyelination and gliosis in this cerebellum adjacent to a radiated medulloblastoma. Radiation was given four and one-half years previously. × 108.

RADIATION CHANGES. EFFECTS ON CEREBELLAR CORTEX

Figure 365. Late changes of delayed radiation effects on the cerebellar cortex are seen in a case of radiated cerebellar astrocytoma. There is complete demyelination with gliosis of the white matter accompanied by severe devastation of the cortex. The granular neuron layer and the Purkinje cells are replaced by a lacy pattern of multiple lacunae. The laminar fenestration follows the contour of the folia. PTAH. × 40.

PATHOGENESIS. The basic mechanism of radionecrosis is poorly understood. There is general agreement on the prominence of the vascular changes and on the role played by the fibrinoid necrosis that occurs in the vessel walls and results in the exudation of protein-rich serum into the necrosed brain. The process is characteristic and unlike any other type of tissue necrosis following vascular occlusion. Alternative views have been held: (1) that the vascular changes are secondary to parenchymal necrosis, the latter being the primary result of radiation; or (2) that the prominent

vascular alterations play the major part in the production of the parenchymatous necrosis (Pennybacker and Russell). From the latter hypothesis, the basic mechanism would primarily involve the vascular endothelium, which as the result of direct cell injury by the ionizing radiation would demonstrate an increase of permeability and consequently an impairment of the blood-brain barrier. Essentially, therefore, the lesion would have features in common with those of vasogenic edema, but aggravated by an intense exudation of fibrin from the damaged capillaries into the white matter. Some support for this view is found in experiments by Clemente and Holst on brains of radiated monkeys, in which they demonstrated selective damage to the blood-brain barrier by using protein-bound dyes. Primary damage to the capillary vessel walls has also been described by McDonald and Hayes in their electron microscopic study of the rabbit brain following proton and alpha particle radiation. They found regular increases in the thickness of the capillary basal lamina from 1 to 3 months after radiation, these changes apparently preceding and being adjacent to radionecrotic areas. They suggested that these alterations in capillary structure might be sufficient to interfere with the passage of blood in the vessel lumen and with the maintenance of the normal capillary wall permeability.

However, there are difficulties in accepting the hypothesis that radionecrosis is simply secondary to primary uncomplicated vascular endothelial damage. First, the histologic appearances differ in a number of important respects from those found in clinical or experimental vasogenic edema. Second, it is not clear why blood vessels of the white matter should be more vulnerable to radiation than cortical capillaries, which are considerably more numerous and would be expected to show maximal changes. The argument advanced by McDonald and Hayes that selective vulnerability of the white matter is to be explained by the presence of fewer capillaries, with the corollary that damage to a smaller number of blood vessels would be more critical to the white matter than the gray, is unconvincing. If this were the case, at least as many damaged capillaries would be found in the gray matter as in the white. More important still, as pointed out by several workers, neither of the two hypotheses accounts for the delay in the onset of changes, usually months or even years after radiation has ceased, or for the presence of contiguous acute and chronic changes in the same specimen, suggesting a self-perpetuating process. On the analogy of the vascular fibrinoid lesions found in conditions associated with hypergic reactions, Crompton and Layton, and Bignami and associates have suggested that the mechanism of radionecrosis might be based on a hypersensitivity phenomenon resulting from alterations in the central nervous system tissues produced by the radiation. Such a view, which is inferential only, would be in agreement with the interpretation offered by Lampert and Davis as an explanation of the early phase of delayed radiation effects. It might also reconcile data suggesting that disturbances of nucleic acid metabolism take place in the glial cells before delayed radionecrosis is apparent (Zeman, 1963) with the electron microscopic observations on the early damage to the capillary basement membrane seen in radiated rabbits. It is of course entirely possible that primary damage to the capillary basement membrane at a fine structural level would result in subtle changes in the central nervous system parenchyma that would long precede any alterations seen with the light microscope. Autoradiographic studies using labeled nucleic acid precursors suggest that not only may large numbers of cells in the central nervous system be subject to cell repro-

ductive death, presumably due to chromosomal damage, but also that damage to RNA synthesizing mechanisms may occur which could conceivably be associated with somatic mutations (Zeman, 1968). Thus these cellular alterations might remain latent for a considerable time until the development of a chain of hyperergic events, manifested at first by the onset of fibrinoid vascular necrosis and followed by fibrin extravasation into the neural parenchyma. At this stage a self-perpetuating process of secondary parenchymatous necrosis would be set in motion to produce the vascular, exudative, proliferative, and parenchymatous changes that constitute the total picture of delayed radionecrosis.

NEOPLASTIC TRANSFORMATION. Although bizarre abnormal giant cells with morphologic appearances suggesting polyploidy may be found among neuroglial cells as a result of radiation, neoplastic transformation of the glial elements has not been described. However, isolated reports have documented the very occasional development of a malignant mesodermal tumor at the site of radiation (p. 191). In most instances this event occurred between 5 and 10 years after the onset of radiation for a pituitary adenoma (Waltz and Brownell). Most examples have been fibrosarcomas of the dura at the site of the previous craniotomy scar. However, Noetzli and Malamud reported a case in which a large fibrosarcoma developed eight years after partial removal of a medulloblastoma; the sarcoma was unrelated to the site of previous operation and was regarded to have arisen from a focus of vascular proliferation in the occipital lobe in the area of the radiated field.

References

Arnold, A., and Bailey, P. Alterations in the glial cells following irradiation of the brain in primates. Arch. Path. 57:383–391, 1954.

Bignami, A., Giuffrè, R., and Riccio, A. Radionecrosi tardiva del chiasma dei nervi ottici e dell'ipotalamo conseguente a cobalto-terapia dell'ipofisi e simulante un processo espansivo. Riv. Neurol. 33:709–730, 1963.

Clemente, C. D., and Holst, E. A. Pathological changes in neurons, neuroglia, and blood-brain barrier induced by x-irradiation of heads of monkeys. Arch. Neurol. 71:66–79, 1954.

Crompton, M. R., and Layton, D. D. Delayed radionecrosis of the brain following therapeutic x-radiation of the pituitary. Brain 84:85–101, 1961.

Edelman, F. L., Aleu, F., Scheinberg, L. C., Evans, J. C., and Davidoff, L. M. Effect of irradiation on the growth of intracerebral gliomas in mice. J. Neuropath. Exp. Neurol. 23:1–17, 1964.

Lampert, P. W., and Davis, R. L. Delayed effects of radiation on the human central nervous system. "Early" and "late" delayed reactions. Neurology 14:912–917, 1964.

Mandybur, T. I., and Gore, I. Amyloid in late post-irradiation necrosis of brain. Neurology 19:983–992, 1969.

McDonald, L. W., and Hayes, T. L. The role of capillaries in the pathogenesis of delayed radionecrosis of brain. Amer. J. Path. 50:745–764, 1967.

Netsky, M. G., Shapiro, J., Hoffman, M., Corsentino, B., Freid, J. R., and Zimmerman, H. M. The effects of single doses of roentgen radiation on experimentally induced gliomas: with a critical review of the effects of roentgen radiation on gliomas in man. Amer. J. Roentgen. 76:351–366, 1956.

Noetzli, M., and Malamud, N. Postirradiation fibrosarcoma of the brain. Cancer 15:617–622, 1962.

Oppenheimer, D. R. The effect of irradiation on a medulloblastoma. J. Neurol. Neurosurg. Psychiat. 32:94–98, 1969.

Pennybacker, J., and Russell, D. S. Necrosis of the brain due to radiation therapy; clinical and pathological observations. J. Neurol. Neurosurg. Psychiat. 11:183–198, 1948.

Schulz, M. D., Wang, C-C., Zinninger, G. F., and Tefft, M. Radiotherapy of Intracranial Neoplasms, pp. 318-370. In: Progress in Neurological Surgery, Vol. 2. (Eds.) Krayenbühl, H., Maspes, P. E., and Sweet, W. H. Chicago: Year Book Medical Publishers, Inc., 1968.

Tansley, K., and Wilson, C. W. Irradiation of experimental cerebral tumours. Radiology 49:62–71, 1947.

Waltz, T. A., and Brownell, B. Sarcoma: a possible late result of effective radiation therapy for pituitary adenoma. Report of two cases. J. Neurosurg. 24: 901–907, 1966.

Zeman, W. Disturbances of the nucleic acid metabolism preceding delayed radionecrosis of nervous tissue. Proc. Nat. Acad. Sci. 50:626–630, 1963.

_____. The Effects of Atomic Radiation, pp. 864–939. In: Pathology of the Nervous System, Vol. 1, (Ed.) Minckler, J. New York: McGraw-Hill Book Company, 1968.

DIAGNOSTIC AIDS FOR THE HISTOLOGIC AND CYTOLOGIC EXAMINATION OF TUMORS OF THE CENTRAL NERVOUS SYSTEM

The purpose of this section is to give a summary account of the approach toward special staining and impregnation procedures which I have found useful in the elucidation of diagnostic problems in tumors of the central nervous system. For a description of the numerous special technics available, the reader is referred to the several excellent manuals that deal with this topic. An up-to-date and concise description of most of the histopathologic technics in general use today will be found in the third edition of the Manual of Histologic Staining Methods of the Armed Forces Institute of Pathology, edited by L. G. Luna.

The routine stain employed, hematoxylin and eosin, is adequate in most tumor cases. In some instances, however, special stains are essential for diagnosis or desirable for teaching purposes. Special stains are more frequently required in neuropathology than in most other areas of diagnostic pathology, and this rule applies also in the area of central nervous system tumors. Since the immediate postoperative course of the neurosurgical patient is hardly likely to be deflected by the prompt availability of a histopathology report, urgency in rendering a diagnosis on a brain tumor tends at times to be overrated in the surgical pathology laboratory. The pathologist need feel no qualms in delaying his opinion until the special stains are at hand.

Since confidence in the special staining and impregnation technics applicable to the nervous system is necessary for the pathologist when he requires them, he should familiarize himself with their range, vagaries, and limitations when applied to tumor material that presents no diagnostic difficulty. Intimate knowledge of these technics is particularly important in the central nervous system owing to the frequency with which tissues of neuroectodermal origin have to be distinguished from those of mesodermal origin. Fortunately the technics available permit this distinction to be made with great ease. An awareness of the standard neuropathologic technics that permit the differential demonstration of the various cellular and fibrillary constituents of the central nervous system is also essential.

In practice most diagnostic problems can be resolved with the application of only three or four special stains: it is advisable to select and retain for routine use a single method for each of the few special stains that are most frequently required, so that the results remain as constant as possible in the hands of the pathologist and technologist who employ them. This is preferable to attempting, on a difficult case, a battery of special stains with which the pathologist is not familiar. In addition, impregnation methods have a definite place in the overall evaluation of the cytologic components.

SPECIAL STAINS

The special stains most frequently employed in neurosurgical pathology fall under four headings, each of which will be illustrated by examples that indicate their diagnostic usefulness.

Connective Tissue Stains

These permit an easy differentiation between neuroectodermal and mesenchymal tissues. The most reliable are Masson's trichrome, azocarmine (or azan), and especially the picro-fuchsin method of van Gieson combined with Weigert's iron hematoxylin. Plates III-E and VII-A illustrate the azocarmine stain. Plates VII-B and C; VIII-C, D, and E; IX-B, C, D, and F; XI-F; and XIV-A illustrate the van Gieson stain or a combination employing the van Gieson method.

Silver Impregnations for Reticulin Fibers

These are essential not only for the recognition of fibers produced by cells of mesodermal origin but also to permit, under the low power or the dissecting microscope, an easy orientation of the tumor, and an assessment of its characteristic growth and spread. The need to determine whether tumor is present in the nervous system parenchyma or in the leptomeninges or perivascular spaces has been repeatedly emphasized in this fascicle. Numerous methods for the demonstration of reticulin fibers have been described, and their selection is often a matter of personal choice. The Laidlaw and Foot technics are excellent. The Wilder method, widely used in the United States, has in my hands often been disappointing in the central nervous system, being inconstant in some cases and nonspecific in others. The most reliable technics have been that of Gomori, which also demonstrates the nuclei, and the excellent method described by Gordon and Sweets, which does not. Counterstaining of the nuclei with neutral red is sometimes useful. Examples of serial sections stained respectively with hematoxylin and eosin (or van Gieson) and with the Gordon-Sweets method for reticulin are illustrated in figures 70, 71, 100, 101, 152, 158, and 159.

Methods for Neuroglia

Neuroglial tissue is easily distinguished from other tissues with the van Gieson method (pls. VIII-C and XIV-A). The Holzer method for glia is of limited value in neurosurgical pathology, since it stains all fibers irrespective of their nature. An example of the Holzer stain in a fibrillated ependymal tumor is shown in plate IV-D. The most useful stain for neuroglia in paraffin preparations is Mallory's phosphotungstic acid hematoxylin as adapted for the central nervous system. This is perhaps the most important of the special stains for neuroglial tumors and is a most reliable tool, provided: the formalin-fixed paraffin-embedded section is mordanted with bichromate before staining; care is taken that the hematoxylin is suitably ripened but not over-ripe; and the timing of the "Mallory bleach" prior to staining (i.e., preliminary oxidation of the section with potassium permanganate followed by decolorization with oxalic acid for the same period of time) is properly adjusted to give the optimal differential staining required (see Russell's 1939 Manual on Histological Techniques for Intracranial Tumors). Unfortunately, sections are apt to fade if exposed to light and should always be covered. The value of the PTAH stain lies in its excellent differentiation between glial and collagen fibers, and the sharpness of the nuclear detail that makes it especially suitable for photomicrography (pls. II-A, B, C; VII-D; XI-E; and XIII-A, B, C, D, F, G). The fact that it stains myelin sheaths as well as glial fibers is hardly likely to pose a problem in neurosurgical pathology.

Stains for Nerve Cells and Neurites

These include the classic methods for the demonstration of Nissl substance, and the various technics for the demonstration of axons and myelin sheaths. In the diagnosis of cerebral tumors, only the first two

are generally needed. Cresyl violet or any other of the usual basic aniline dyes used in the central nervous system, such as toluidine blue, thionin, azure B, or carbol azure are employed for the identification of Nissl bodies (pl. V-D).

For the demonstration of axons various modifications of the Bielschowsky method applicable to paraffin-embedded sections may be used; the one described by Marsland, Glees, and Erickson is very reliable. These technics, however, only show the axons or the intracellular neurofibrils of well differentiated ganglion cells (figs. 175, 302; pl. XIV-D). They are of no value for the demonstration of young neurofibrils or the cytoplasmic processes of neuroblasts, for which the more sensitive silver impregnations on frozen material must be used. It is only exceptionally that the Bodian and the Holmes method are able to demonstrate neurofibrils in primitive tumors of neuroblastic origin (fig. 139).

SPECIAL METALLIC IMPREGNATIONS

These methods are applied to frozen tissue material only. Although it is exceptional in my experience for the diagnosis to be dependent on these methods, nevertheless they are of considerable usefulness and often essential for the full characterization of the tumor elements.

The gold chloride sublimate method of Cajal, excellent for the demonstration of reactive astrocytes, can also be used for well differentiated astrocytomas, but is of limited value in the less differentiated tumors of the astrocytic type. On the other hand the different variants of the Hortega silver carbonate method adapted for the various glial cell types in the central nervous system are of the greatest value, even in relatively poorly differentiated tumors. For the demonstration of astrocytic tumor cells, the double silver carbonate impregnation method described by Penfield, or the double or triple silver carbonate impregnations described by Scharenberg may be most valuable (figs. 7, 32; pl. XIV-B, C). For the above methods the tissue must either be fixed in formol-ammonium-bromide, or if originally fixed in formalin, undergo bromidation before impregnation. Excellent results are also obtained in formalin-fixed tissue by using the triple silver impregnation for astroglial cells and glial fibrils as described by Polak.

For the demonstration of oligodendrocytes, the Hortega silver carbonate method described by Penfield for oligodendrocytes is the most reliable.

For the demonstration of pineal parenchymal cells including their clubbed processes, the Hortega variant for the pineal parenchyma described by Horrax and Bailey may be successfully employed.

Silver impregnation methods are indispensable for the study of cells of the reticulum cell sarcoma-microglioma group. The Penfield modification of the Hortega silver carbonate method for microglia and the Weil-Davenport method are very reliable (figs. 233, 234, 236). The method of Griño, which utilizes a combination of silver nitrate and sodium tungstate may also be successful in demonstrating microglial elements.

For primitive cells of neuroblastic origin and for mature ganglion cells, the Bielschowsky method on frozen section is probably the most reliable (fig. 284). Hortega's double silver impregnation method for nerve fibers and neurofibrils described by Polak has also been found to be useful.

It is advisable in all these impregnations to have at least four sections available for study, including two that have been toned with gold chloride. The latter may sometimes result in a slight loss of the metallic impregnation as the silver is replaced by gold, but may increase the sharpness of the impregnation (pl. XIV-C).

PLATE XIV

SPECIAL STAINING PROCEDURES FOR THE DEMONSTRATION OF MIXED TUMOR ELEMENTS AND OF GANGLION CELLS

(See also Plates III-E and VIII-A, C, and D)

SPINDLE CELL SARCOMA WITH ADJACENT MALIGNANT GLIOMA (VAN GIESON)

(Plate XIV-A and Figure 208 from same case)

A. The upper half of the photomicrograph shows densely cellular, darkly staining spindle sarcoma cells. The lower part shows more loosely textured anaplastic glial elements. This is from a circumscribed spindle cell sarcoma that arose from the temporal leptomeninges in a 21-year-old woman. This stain is particularly suitable for the demonstration of mixed gliomatous and sarcomatous elements. Hematoxylin and van Gieson. × 180.

FOCUS OF MALIGNANT GLIOMA IN AN INVASIVE FIBROSARCOMA (HORTEGA SILVER CARBONATE PREPARATION)

B. A clearly defined island of fibrillated, silver positive neuroglial cells (dark brown) is shown among the lighter yellowish brown stroma of sarcomatous cells that have no affinity for silver. The section is from a mixed chondrosarcoma and glioblastoma arising in the temporal lobe of a 64-year-old man. Penfield's modification of Hortega's double silver carbonate impregnation, untoned. × 280.

ISLAND OF MALIGNANT ASTROCYTOMA IN AN INVASIVE FIBROSARCOMA (HORTEGA SILVER CARBONATE METHOD)

(Plate XIV-C and Figures 211–213 from same case)

C. An island of positively impregnated astrocytic tumor cells is surrounded by sarcoma cells showing no affinity for silver. The positive silver impregnation in this photomicrograph from a circumscribed parietal tumor in a 60-year-old woman establishes the glial nature of the islands illustrated in figures 211 and 212. Scharenberg's modification of Hortega's double silver carbonate impregnation, toned with gold chloride. × 280.

GANGLIOGLIOMA (BIELSCHOWSKY IMPREGNATION ON PARAFFIN SECTION)

D. Positive silver impregnation of cytoplasm, cell processes, and intracytoplasmic neurofibrils is shown in a large ganglioglioma in a 3-month-old girl. The unimpregnated cells are neuroglial. Glees-Marsland modification of the Bielschowsky method for axons, adapted to paraffin sections. × 350.

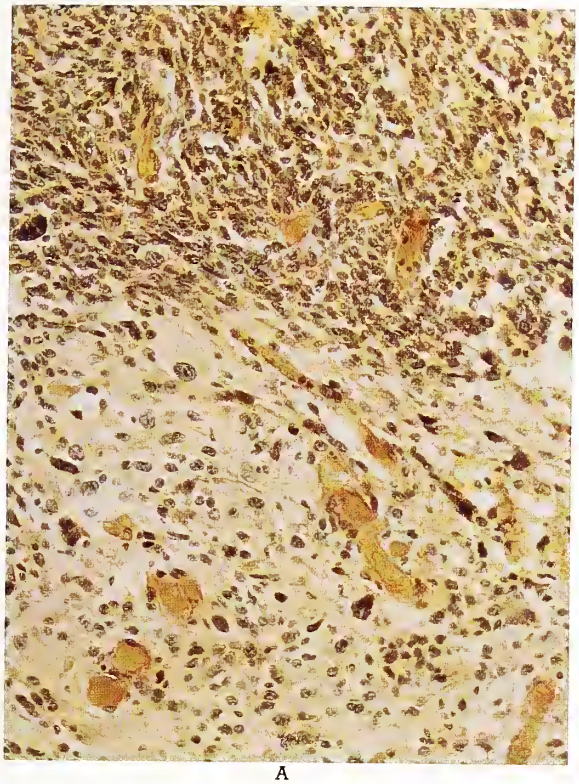

A

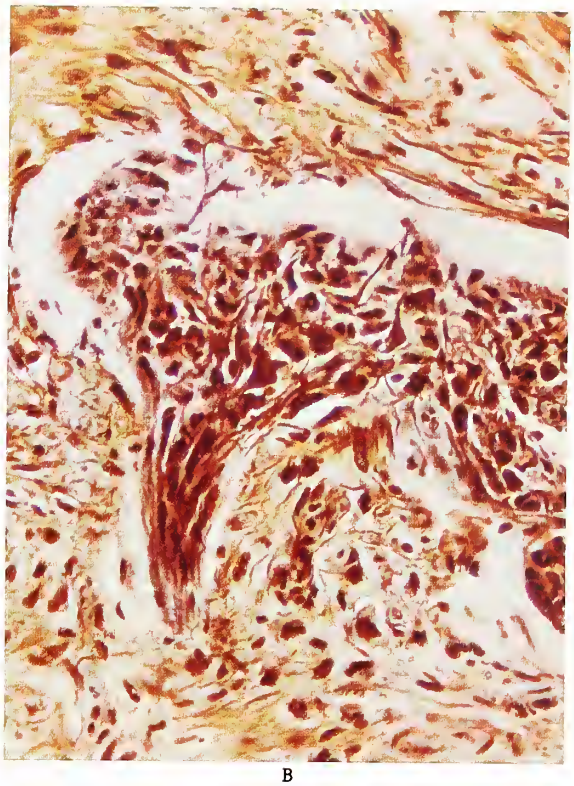

B

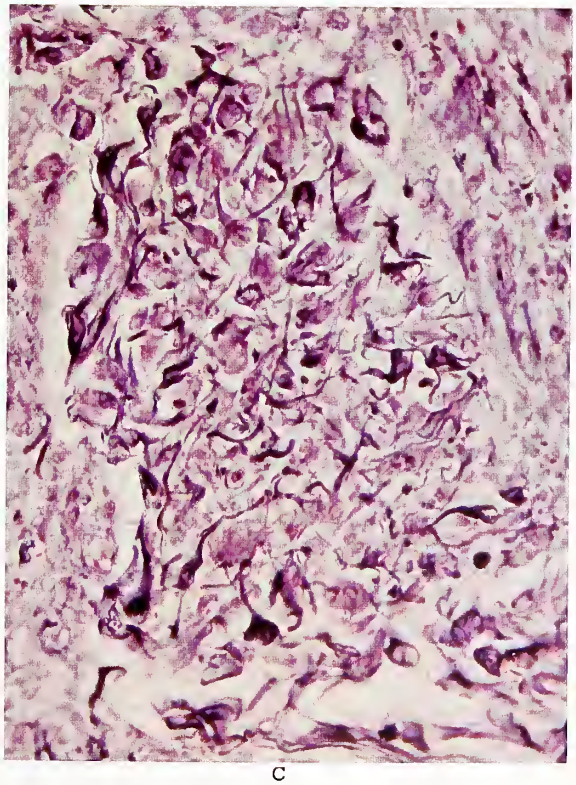

C

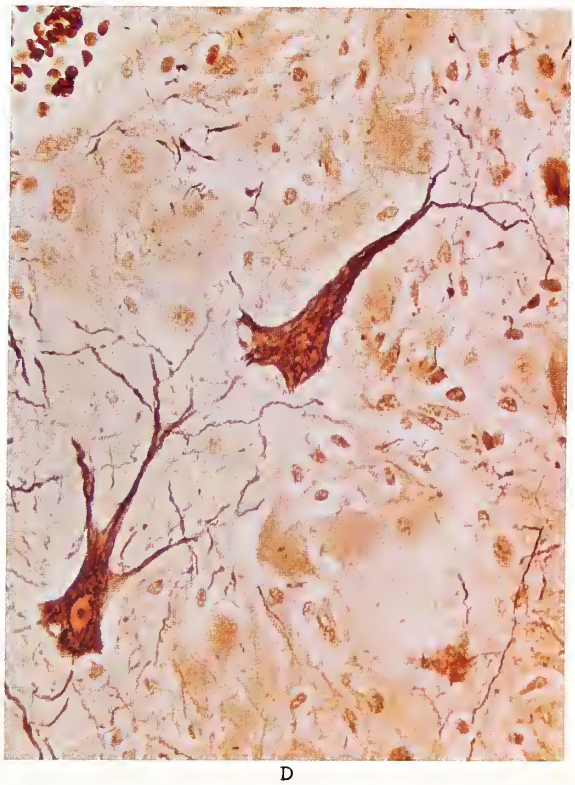

D

PLATE XIV

ENZYME HISTOCHEMICAL TECHNICS

To date these are of no obvious diagnostic value in differential problems on cerebral tumors, but they have provided a certain amount of useful data for the cytologic demonstration of increased enzyme activity by slide histochemical methods. The technics used are described in the histochemistry manuals by Pearse, and by Barka and Anderson, or constitute modifications thereof. The information provided by these technics for the understanding of the metabolism of cerebral tumors still awaits evaluation. Two main groups of enzyme systems that have been the subject of most investigation are the oxidative enzymes, using the various established tetrazolium reductase methods, and the hydrolytic enzymes, especially the phosphatases, using either the Gomori method or the azo-dye technics described by Barka and Anderson. These technics have made it possible to demonstrate various increases of oxidative enzyme activity in neoplastic cells; a markedly increased oxidative enzyme activity in the proliferating vascular endothelium associated with malignant gliomas; the identification of sharply delineated areas of highly different oxidative and hydrolytic enzyme activities in meningiomas; and considerable oxidative and acid phosphatase activity in the Antoni B type of tissue in schwannomas, a finding which speaks against these areas being degenerative. As expected, the tumor elements in the reticulum cell sarcoma-microglioma group can be demonstrated to show considerable acid phosphatase activity, a finding which is in agreement with their affinity to cells of the macrophage cell system.

RAPID DIAGNOSTIC METHODS

Smear or Wet Film Technic

Opinions differ on the value and reliability of this approach for the rapid diagnosis of brain tumors at the time of surgery. Some arguments against the method stem from the opposition by some neurosurgeons to any needle biopsy technic through a small trephine opening as opposed to open craniotomy. From the diagnostic point of view, one of the most obvious disadvantages of the wet film technic is that the architecture of the tissue is destroyed to some extent during the process of obtaining the smear. Another disadvantage is that an estimate of the cellularity is often difficult. Much of the value of the preparation depends on an even distribution of tissue on the slide.

On the other hand the method need not be limited to cases from which only a needle biopsy is obtained, and is often employed at the time of decompressive craniotomy. It may be particularly useful for fragments that are too soft and friable to be sectioned with the freezing microtome, and often reveals cytologic details with a delicacy that is not easily matched in rapid frozen section material. Experience is necessary for the diagnosis of tumor material by the smear technic. The problem is often a cytologic one, and familiarity with the cytologic appearances of known cerebral tumors should be acquired in order to gain competence in interpretation. It is also important for the pathologist to familiarize himself with the picture of the normal gray and white matter as seen in smears, including the appearances of samples obtained from the hippocampal region and the cerebellar cortex. The density of the granular neurons in these areas may trap the inexperienced into a diagnosis of highly cellular undifferentiated tumor. Details on the method and the various cytologic appearances obtained have been published by Russell (1951), and an appraisal of the

technic with a description of the difficulties and pitfalls that may be encountered by the pathologist are also given by McMenemey.

The most reliable stains for the wet film technic are a one percent solution of toluidine blue or thionin, or the modification of Mann's eosin and methylene blue as described by Morris.

The smear technic demonstrates beautifully the nuclear details as well as the delicate neuroglial fibers in fibrillated glial neoplasms. The cytologic appearances are similar to those found in tissue culture (pls. II-D; III-B; IV-C, E; V-C; VI-C, D; and XI-D).

Frozen Sections

The rapid frozen section technic using the freezing microtome following rapid formalin fixation has long been in use, and is usually effective with tumors that are hard or tough, such as meningiomas. Soft, friable, or gelatinous neuroglial tumors are much more difficult to handle. Needle biopsies are often too small to be sectioned with ease with the conventional freezing microtome.

Cryostat-cut Unfixed Sections

The recent introduction of cryostat microtomy, in which unfixed frozen tissues are sectioned and then "post-fixed" for a brief period before staining, has several advantages. It allows the material to be further studied by histochemical, fluorescent, and immunologic technics in which conventional fixation procedures are contraindicated. It also produces sections that are appreciably thinner than those normally obtained with the conventional freezing microtome and therefore approximate those obtained after paraffin embedding. This is particularly desirable in neurosurgical pathology because an accurate estimate of the density of the cell population may be crucial in the diagnosis of diffusely infiltrating gliomas.

The usefulness of the technic can be further increased by the modification of Rahman and Luttrell, who recommend the embedding of fragments of fresh unfixed material in egg albumen before freezing and cryostat sectioning. This permits the sectioning and mounting of very small tissue samples, such as may be obtained through a brain biopsy needle. There is no distortion of the tissue with this procedure.

Proper fixation following cryostat sectioning is important, and is most expeditiously performed by exposing the sections to formalin vapor from 1 to 4 minutes. Various staining methods may be used, but a useful one for central nervous system tumors is described by Miquel and associates and uses a combination of basic fuchsin, amido black, and naphthol yellow (FAN) as a substitute for hematoxylin and eosin. This stain incorporates dyes that have strong affinity for tissue proteins, as demonstrated by gel methods on human serum protein fractions. Reactive and neoplastic glial cell cytoplasm and their processes are well demonstrated in this method, which stains the cytoplasm green and the nuclei red. Examples of neurosurgical specimens embedded unfixed in egg albumen before cryostat sectioning, and stained by the FAN method are illustrated in plate XV-A through D. The preparations are permanent. The tissue architecture is preserved and comparable to permanent paraffin preparations, but the nuclear detail cannot compare with that seen in smears or in conventional paraffin-embedded tissues.

PLATE XV

CRYOSTAT-CUT FROZEN SECTIONS, SUBSEQUENTLY POSTFIXED, FROM NEUROSURGICAL SPECIMENS

REACTIVE ASTROCYTES IN BIOPSY FROM CEREBRAL EDEMA

A. Enlarged reactive astrocytes with blue-green staining cytoplasm and processes are seen in an area of edema adjacent to a metastatic carcinoma. The nuclei stain red by this method. FAN stain of Miquel et al. × 230.

GLIOBLASTOMA MULTIFORME

B. This highly cellular glial tumor shows pseudopalisades along the lower portion of the photomicrograph. The cytoplasm of many of the tumor cells in the upper half of the illustration are well demonstrated in this rapid diagnostic method. FAN stain of Miquel et al. × 200.

MENINGIOMA

C. The whorling pattern is well seen in this transitional meningioma identified on frozen section at the time of surgery. FAN stain of Miquel et al. × 140.

METASTATIC CARCINOMA

D. This is the edge of a solid polygonal cell metastatic carcinoma obtained at frozen section, with reactive brain in the right lower portion of the field. FAN stain of Miquel et al. × 165.

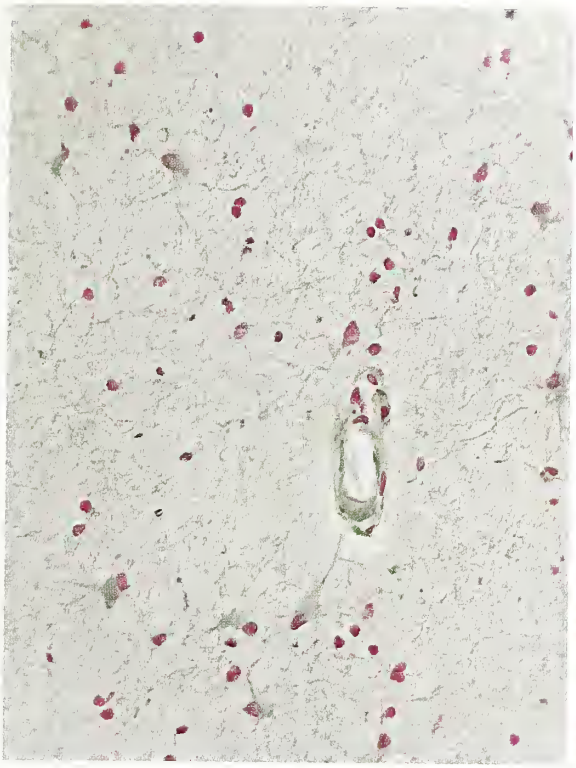

A

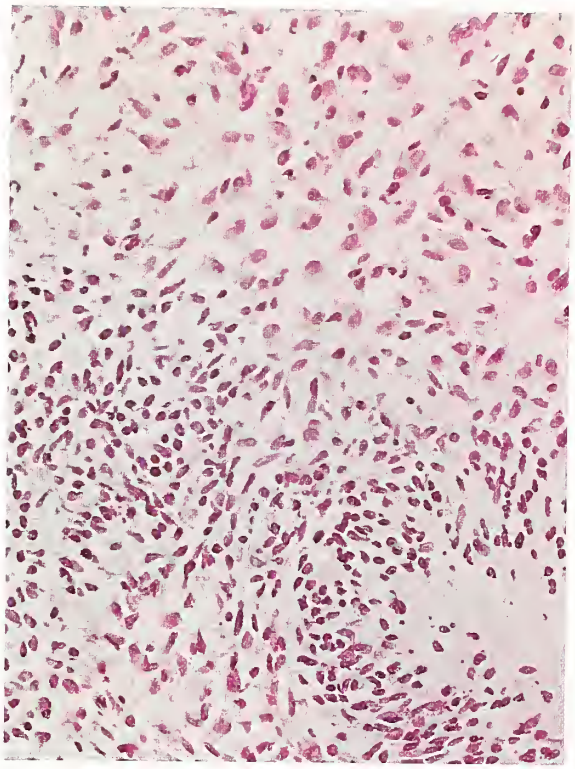

B

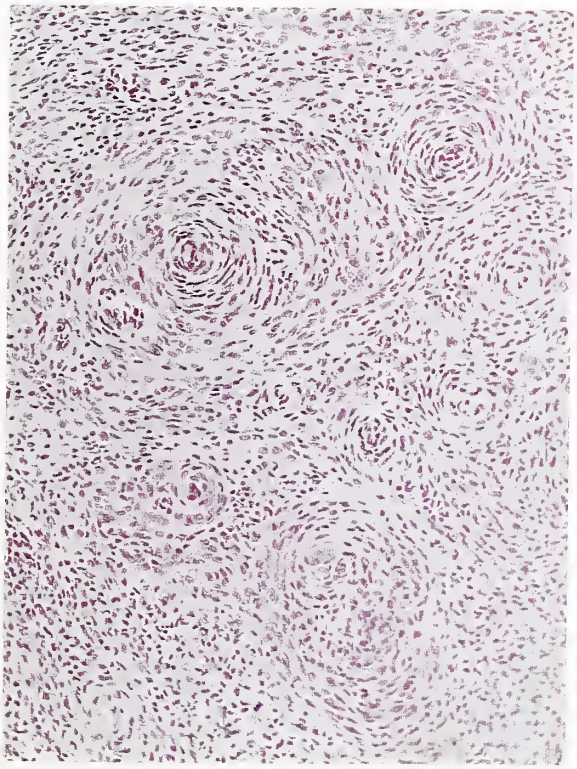

C

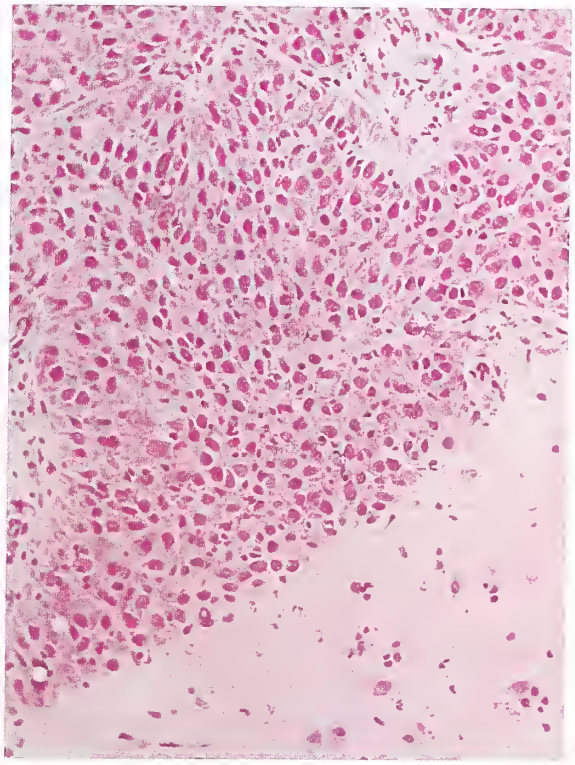

D

PLATE XV

SPINAL FLUID CYTOLOGY

For many years various methods have been employed for the isolation and identification of neoplastic and other cells in the cerebrospinal fluid. In the past most technics have been based on the use of dried smears from centrifuged fluid samples. The recent development of millipore filter technics has greatly improved this type of examination by permitting an evaluation of the cells in a fluid medium in a relatively undisturbed state. The method is of special value for the detection of neoplastic cells in tumors that are suspected of metastasizing in the cerebrospinal fluid pathways. The stain is usually the Papanicolaou stain or a modification thereof. Further details on the applications of this technic and its results are given by Wilkins and Odom, and in a useful account by Rich.

GLIOBLASTOMA

Figure 366. This 11-year-old girl was hospitalized because of double vision, weakness of the right hand and leg, and a peculiar bending of the neck to the left. Papilledema was also present.

A, B, C, and D. Cerebrospinal fluid was obtained by lumbar puncture and processed on a 5 μ pore filter membrane (Millipore-SM). The small, dark cells in A have a chromatin pattern, scanty but intact cytoplasm, and a high nucleocytoplasmic ratio typical of leukocytes. The two larger nuclei have the pale chromatin pattern, elongated oval, fusiform shape, and wispy or absent cytoplasm associated with meningeal fibrocytes. The larger darker cells in B, C, and D have many bizarre morphologic features. In the cerebrospinal fluid, single bizarre cells are most frequently exfoliated subarachnoid-lining cells which are proliferating or reactive to irritation. To differentiate these from tumor cells in cerebrospinal fluid, it is important to locate and positively identify true tissue fragments in contradistinction to secondarily aggregated single cells. Such true tissue fragments are present in B, C, and D and can be identified by the nuclear molding characteristic of cells that have grown together, and by the lack of intercellular "windows" or spaces between cell membranes, evidence of their true tissue nature. In addition, these cells have many morphologic features of malignancy, including multiple and irregular chromatin clumps and nucleoli, hyperchromasia in large nuclei, parachromatin clearing, nuclear membrane irregularities, and very high nucleocytoplasmic ratios. There is no evidence of differentiation in these cells. They indicate a moderately pleomorphic anaplastic malignant tumor. This is borne out in the section of tissue illustrated at the same magnification in F. Papanicolaou stain. $\times$ 1640. E. and F. A cerebellopontine angle tumor was found which proved to be a glioblastoma. E, $\times$ 125; F, $\times$ 1640. (Courtesy of Dr. John K. Frost, Baltimore, Md.)

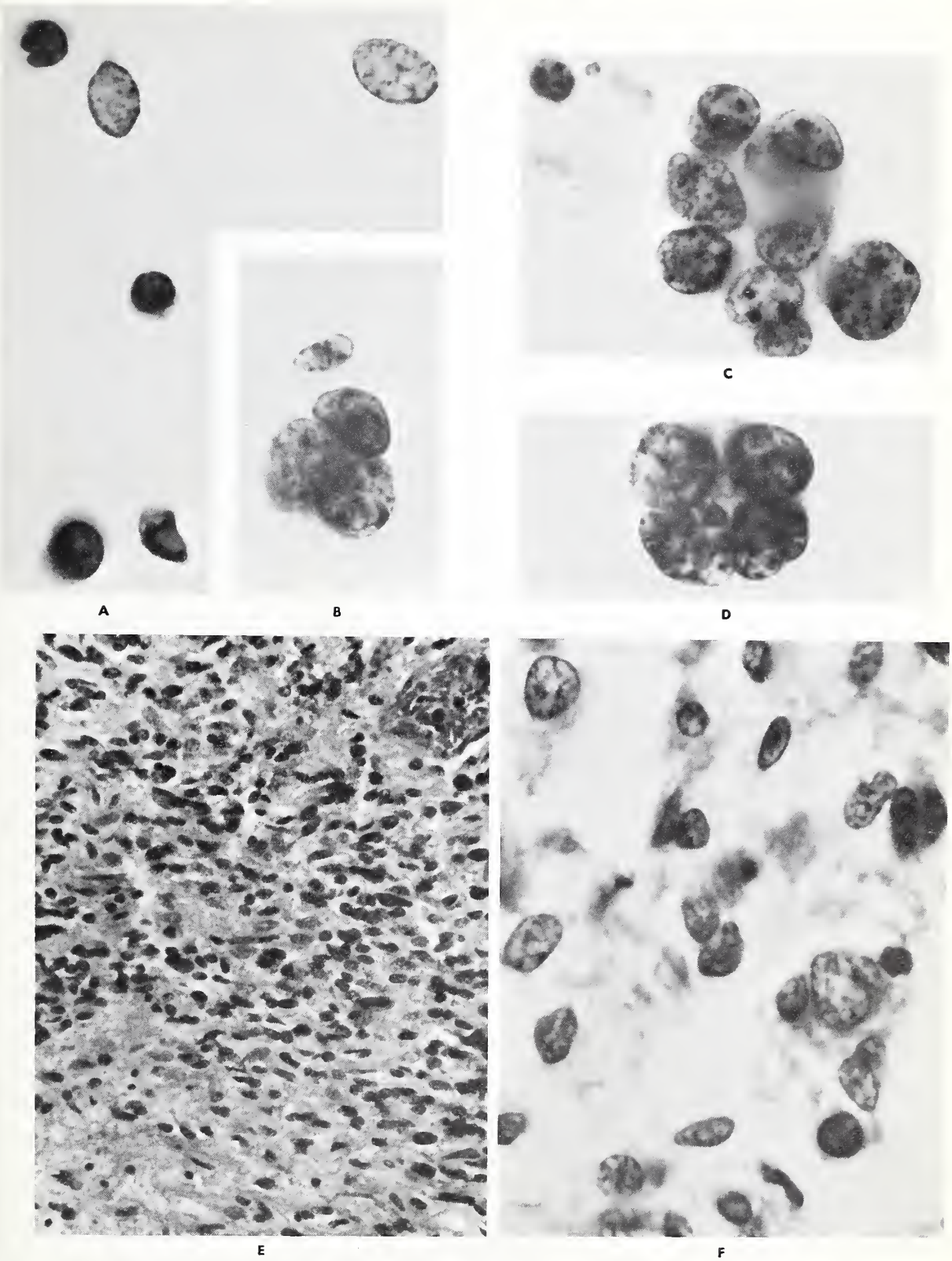

Fig. 366

DESMOPLASTIC MEDULLOBLASTOMA

Figure 367. A 17-month-old girl had irritability and vomiting for three weeks. She had bilateral sixth cranial nerve palsy with strabismus and increased intracranial pressure.

A and B. Cerebrospinal fluid was obtained by lumbar puncture and processed on a 5 μ pore filter membrane (Millipore-SM). The moderately large cells seen in A and B are shed in true tissue fragments with nuclear molding and scanty, but intact cytoplasm. There are other morphologic features of malignancy including hyperchromasia, varying numbers of prominent chromatin masses, irregular nuclear contours, and high nucleocytoplasmic ratios. These findings indicate a small-celled, undifferentiated malignant tumor, and reflect the basic cellular pattern in the tissue seen in D. Papanicolaou stain. $\times$ 1640.

C and D. Surgical exploration of the posterior fossa revealed this desmoplastic medulloblastoma. C, $\times$ 160; D, $\times$ 1640. (Courtesy of Dr. John K. Frost, Baltimore, Md.)

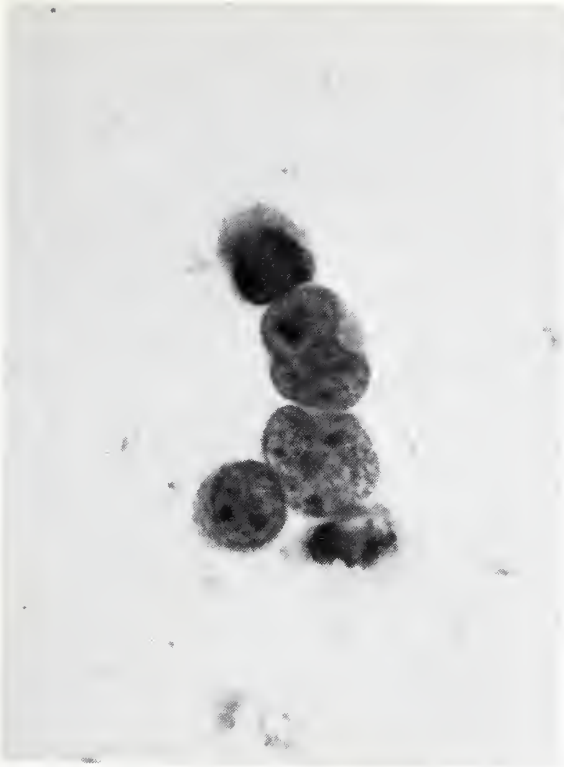

A

B

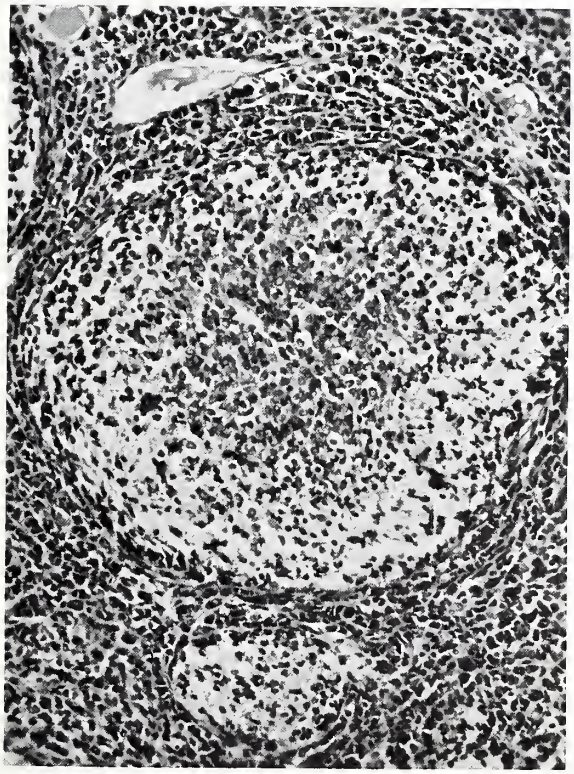

C

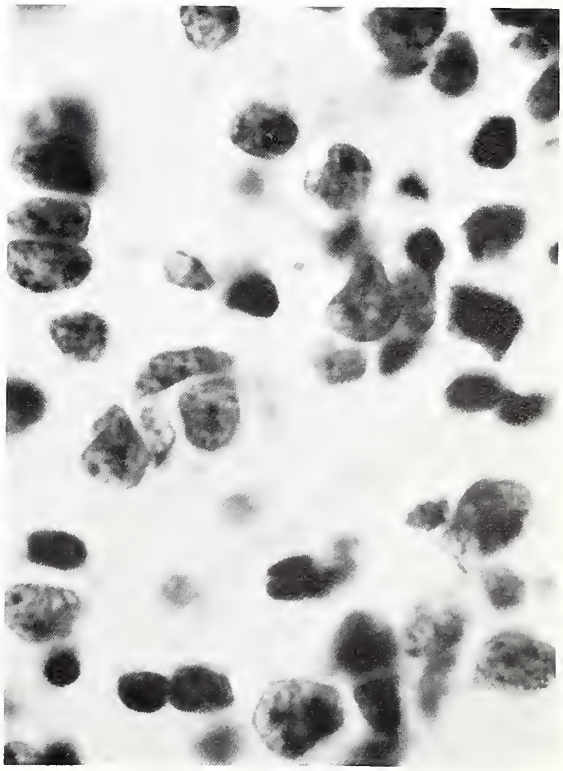

D

Fig. 367

METASTATIC ADENOCARCINOMA FROM LUNG

Figure 368. A 45-year-old man developed severe headaches and decreased hearing in the right ear, sagging of the left side of his face, inability to close the left eye, and diplopia. He had had a productive morning cough with dyspnea on exertion.

A and B. Cerebrospinal fluid was obtained by lumbar puncture and processed on a 5 μ pore filter membrane (Millipore-SM). The cells in A and B were shed as small tissue fragments which are recognized by the lack of intercellular "windows" (A), and by nuclear molding (B). There are many morphologic features of malignancy in the cells, including large chromatin clumps in the huge nucleus in A, with extreme and irregularly placed parachromatin clearing. Nuclear irregularity in both shape and thickness is present in B. Compare these features with those seen in the histologic sections of the tumor in the subarachnoid space at the same magnification (D). There are some vacuoles in the cells shown in A, suggestive of secretory differentiation in adenocarcinoma. Papanicolaou stain. $\times$ 1640.

C. The spinal cord shows the subarachnoid space occupied by metastatic adenocarcinoma. $\times$ 125.

D. The neoplastic glands in the subarachnoid space are shown at the same magnification as the cytologic preparations (A and B). $\times$ 1640. (Courtesy of Dr. John K. Frost, Baltimore, Md.)

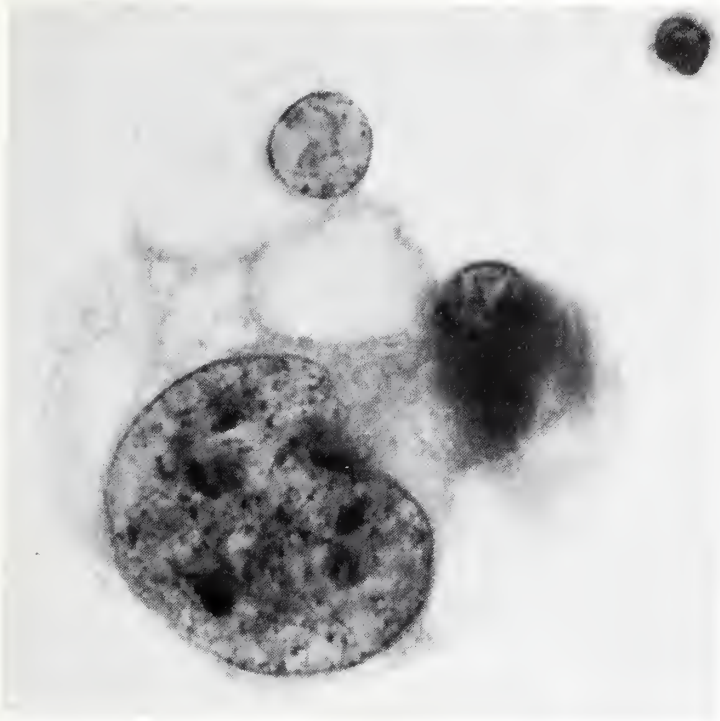

A

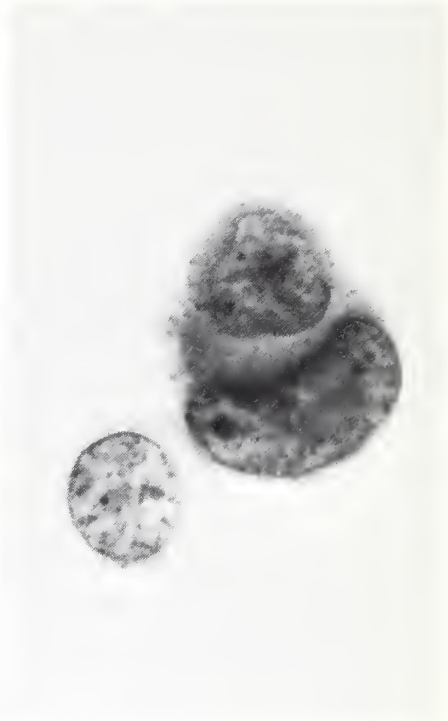

B

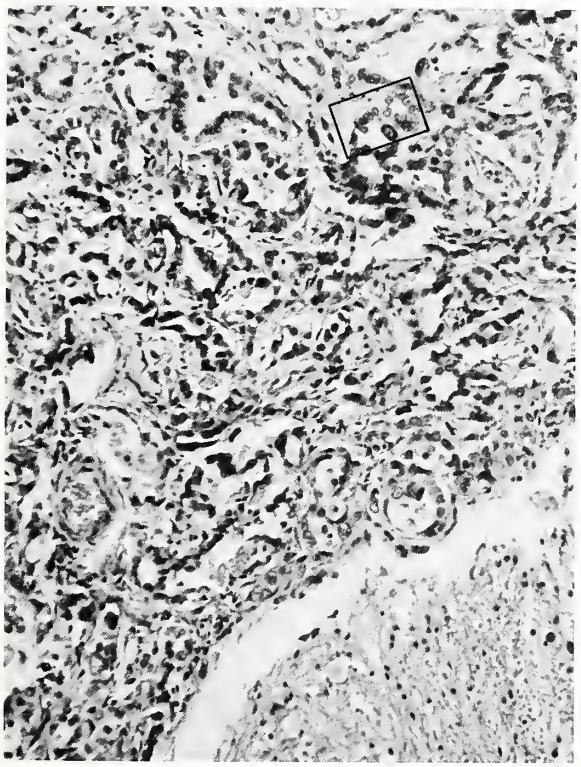

C

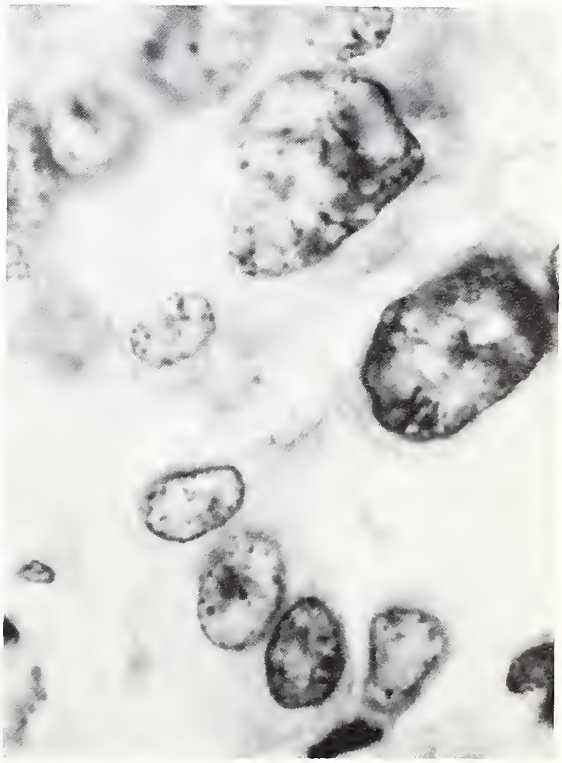

D

Fig. 368

LYMPHOBLASTIC LYMPHOSARCOMA

Figure 369. A 4-year-old girl had a history of periods of unconsciousness.

A and B. Cerebrospinal fluid was obtained by lumbar puncture and processed on a 5 μ pore filter membrane (Millipore-SM). The moderately large single cells in the cerebrospinal fluid (A) are nearly all young lymphocytes with multiple, irregular chromatin clumps and nucleoli, cleared perichromatin, irregular nuclear membranes, and scanty cytoplasm. These features, especially the prominent nucleoli, which stain red with the Papanicolaou technic, are key in recognizing these lymphoblasts as malignant. An occasional true tissue fragment (B) (note nuclear molding), rather than mere cellular clustering, helps to distinguish lymphosarcoma from leukemia. Papanicolaou stain. $\times$ 1640.

C and D. The subarachnoid and Virchow-Robin perivascular spaces of the medulla are occupied by lymphoblastic lymphosarcoma. C, $\times$ 125; D, $\times$ 1640. (Courtesy of Dr. John K. Frost, Baltimore, Md.)

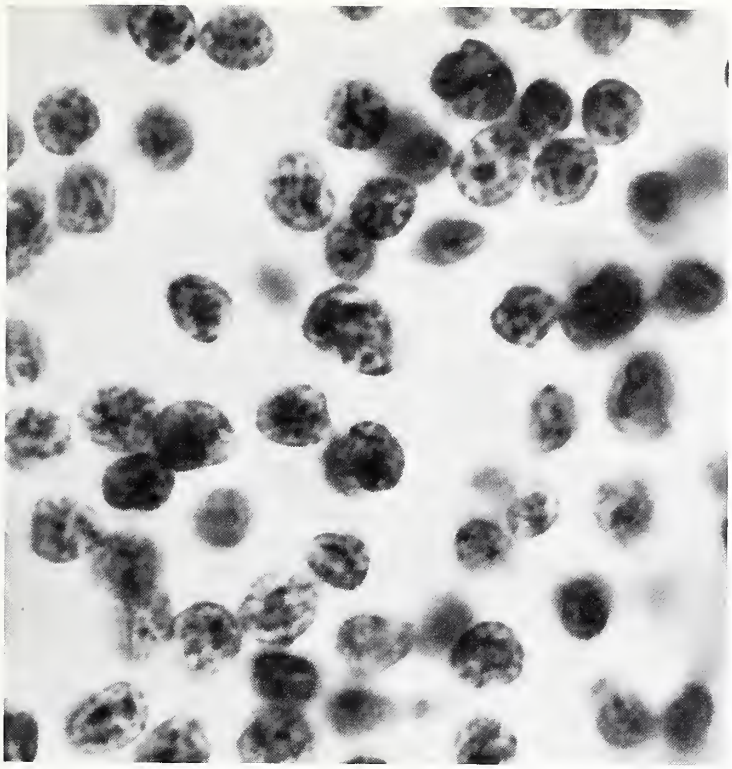

A

B

C

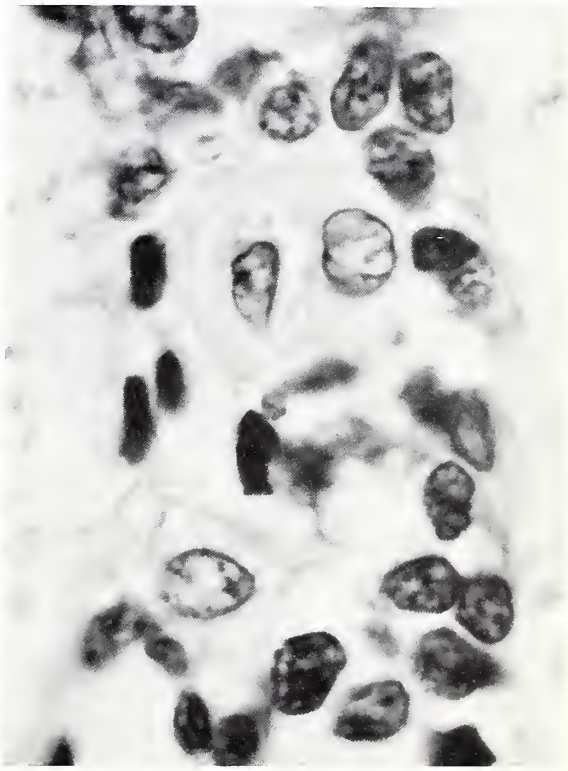

D

Fig. 369

References

Barka, T., and Anderson, P. J. Histochemistry: Theory, Practice, and Bibliography. New York: Hoeber Medical Division, Harper and Row, Publishers, Inc., 1963.

Gordon, H., and Sweets, H. H., Jr. A simple method for the silver impregnation of reticulum. Amer. J. Path. 12:545–552, 1936.

Griño, A. A new method for impregnation of oligodendroglia and microglia in ordinary necropsy material. J. Neuropath. Exp. Neurol. 4:93–97, 1945.

Horrax, G., and Bailey, P. Tumors of pineal body. Arch. Neurol. 13:423–470, 1925.

Luna, L. G. Manual of Histologic Staining Methods of the Armed Forces Institute of Pathology, 3d ed. Washington: American Registry of Pathology, 1968.

Marsland, T. A., Glees, P., and Erikson, L. B. Modification of the Glees silver impregnation for paraffin sections. J. Neuropath. Exp. Neurol. 13:587–591, 1954.

McMenemey, W. H. An appraisal of smear-diagnosis in neurosurgery. Amer. J. Clin. Path. 33:471–479, 1960.

Miquel, J., Calvo, W., and Rubinstein, L. J. A simple and rapid stain for the biopsy diagnosis of brain tumors. J. Neuropath. Exp. Neurol. 27:517–523, 1968.

Morris, A. A. The use of smear technique in the rapid histological diagnosis of tumours of the central nervous system. Description of a new staining method. J. Neurosurg. 4:497–504, 1947.

Pearse, A. G. E. Histochemistry: Theoretical and Applied, 2d ed. Boston: Little, Brown and Co., 1960.

Polak, M. Blastomas del Sistema Nervioso Central y Periferico. Buenos Aires: Lopez Libreros Editores, 1966.

Rahman, A. N., and Luttrell, C. N. Albumen-embedding method for frozen sectioning of fresh tissues for histological, fluorescent antibody and histochemical studies. Bull. Johns Hopkins Hosp. 110:6–72, 1962.

Rich, J. R. A survey of cerebrospinal fluid cytology. Bull. Los Angeles Neurol. Soc. 34:115–131, 1969.

Russell, D. S. Histological Technique for Intracranial Tumours. London: Oxford University Press, 1939.

———. The wet-film technique in neurosurgery, pp. 455–462. In: Dyke, S. C. Recent Advances in Clinical Pathology, 2d ed. London: J. & A. Churchill, Ltd., 1951.

Scharenberg, K. Blastomatous oligodendroglia as satellites of nerve cells. A study with silver carbonate. Amer. J. Path. 30:957–967, 1954.

Wilkins, R. H., and Odom, G. L. Cytological changes in cerebrospinal fluid associated with resections of intracranial neoplasms. J. Neurosurg. 25:24–34, 1966.

INDEX

Abbott, K. H., 172, 174, 180, 181, 189
Acinar mucus-secreting adenoma, see under Adenoma
Acoustic nerve, see under Cranial region
Acoustic neuroma, neurofibroma, schwannoma, see under the nouns
Adachi, M., 334, 348
Adamantinoma, **292**
  melanotic, **297**
Adams, J. H., 216, 217, 233
Adenocarcinoma
  metastatic 324, **324**
    from lung, detection by spinal fluid cytology, 374, **375**
  papillary and tubular columnar cell, diagnostic differentiation, medulloepithelioma, **129**
Adenoma
  invasive, **314**
  papillary and acinar mucus-secreting, 259, **260**, **267**
  pituitary
    association, Cushing's syndrome, **314**
    chromophobe, **313**, **314**
    differential diagnosis
      astrocytoma, 313
      ependymoma, 126, 313
      metastatic carcinoma, 326
      oligodendroglioma, 101, 313, **314**
    direct extension, **313–314**
Adventitial sarcoma, see under Sarcoma
Agents
  chemical, experimental, **5–6**
  epilepsy, 4
  radiation, **5**, 349
  trauma, **5**
    meningioma, **172**
  virus, **4–5**
Aleu, F. P., 339, 348
Alexander, G. L., **256**
Alexander, W. S., 56, 84
Ambler, M., 164, 166, 167
Ameloblastoma, 292
Ancient schwannoma, see under Schwannoma
Anderson, R. M., 247, 256
Aneurysm, congenital berry, association, arteriovenous malformations, **247**
Angioblastic meningioma, see under Meningioma, types
Angiodysgenetic myelomalacia, **253**, 255
Angioglioma, 49, 240
Angioma
  arteriovenous, **246**
  cavernous, **243**, 245–246
    basal ganglia, **245**
    differentiation, multiple telangiectases, **241**
  cirsoid or serpentine, **246**
  venous, **255**
Angiomatosis
  cortical, **306**
  encephalofacial, **255**, **309**
  encephalotrigeminal, **255**, **309**
  mesencephalo-oculo-facial, 250, **251**
  meninges, **253**
Angioreticuloma, 235
Arachnoid villi, see under Cranial region
Ariëns Kappers, J. A., 263, 265, 278, 284
Arnold, A., 354, 360
Arnold-Chiari malformation, association, spinal enterogenous cyst, 288
Arteriosus, patent ductus, association, arteriovenous malformations, 247, 250, **251**
Arteriovenous malformations, angioma, aneurysm, see under the nouns
Astroblastoma, **50–52**
  astroblasts, **52**
  differential diagnosis, **52**
    ependymoma, **125**
    metastatic melanoma, **328**
    pineocytoma, **281**
    pituitary adenoma, 313
  frontal lobe, **25**
  temporal lobe, **51**
Astrocytoma, **19–50**
  appearance
    gross, **21–26**
    microscopic, **26–38**
  associated conditions, **21**
    central form, von Recklinghausen's neurofibromatosis, **21**, **303**
  cerebellar type, 34
  cerebellum 32–34, **32**, **33**
    cystic, **25**, **34**
    infiltration, adjacent brain, **10**
    Rosenthal fibers, 33, 36, **36–38**
  classification, **8**, **20**
  clinical data, **21**
    onset, epilepsy, **21**

cystic, cerebellum, 25, **34**
cytogenesis, 19
dedifferentiated, **42**
definition, 19
differential diagnosis, 46–49
amelanotic melanoma, 49
capillary hemangioblastoma, 49, **240**
ependymoma, 52, 125
ganglioneuroma and ganglioglioma, 159, **167**
glioblastoma multiforme, 49
large cerebellar cyst, 49
medulloblastoma, 138, **139**, 152
metastatic renal cell carcinoma, 326
oligodendroglioma, 101
reactive gliosis, 46–47
sarcoma, 194, **203**
Schilder's disease, 47
schwannoma, 49, **211**, 212–213
diffuse
cerebrum, **22**
malignant change, **47**
diffuse fibrillary
cerebrum, 26–27
invasion, leptomeninges, **31**
midbrain, **31**
diffuse malignant
invasion, Virchow-Robin spaces, **44**
palisading effect, **45**
diffusely infiltrating, secondary structures, 11, 28, **28**
29
fibrillary
microcyst formation, 27, 28
smear, **31**
gemistocytic, **31**, 40, **40**
association, multiple sclerosis, 5
conversion to glioblastoma multiforme, 42
differential diagnosis, Schilder's disease with gemistocytic reactive astrocytes, 47
grade 3, 8, 42, 55
grade 4, 55
grading system, 8, 20, 34, 38
hydrocephalus, **frontispiece**
incidence, 20
juvenile
clinical malignancy, **10**
hypothalamic region, **23**
malignant, 42–49, **48**
invasion, leptomeninges, **43**
radiated, invasion, superior longitudinal sinus, 13
island in invasive fibrosarcoma, **365**
mixed, oligodendroglioma, 93, 97, **99**
multiplicity, **21**
piloid or pilocytic
adult type, 39, **39**
juvenile type, 22, 34–38, **35**
association, central form, von Recklinghausen's neurofibromatosis, 21, 303
Rosenthal fibers, 36, **36**
malignant, **48**
pons, 24, **25**, 37–38
prognosis, 45–46
protoplasmic, 39, **39**, 40
spinal cord, 26, 38, 56
prognosis, 46
subependymal, **116**
subependymal giant cell, 40–42, **41**
association, tuberous sclerosis, **21**, **40**, **301**
subependymal glomerate, **116**
third ventricle, **frontispiece**, 21
treatment, 44–45
radiation, 44–45
results, **352**, **357**, **358**
variants, 39–42
vascular endothelial proliferation
cerebellar, **32**
pilocytic, 35, **36**
Atkinson, W. J., 212, 214
Atypical forms, see under the respective nouns
Ayala's disease, diagnostic differentiation, cerebral form of histiocytosis X, 225–226
Ayres, W. W., 262, 265

Bailey, O. T., 202, 204, 235, 240
Bailey, P., 1, 7–9, 13, 15, 34, 49, 50, 52, 85, 104, 120, 125–127, 129, 130, 132, 133, 137, 152, 180, 189, 203, 204
Barka, T., 366, 370
Barnard, R. O., 98, 99, 104
Barron, K. D., 319, 332, 348
Basal ganglion, see under Cranial region
Batson, R., 227, 233
Batzdorf, U., 11, 15
Baumann, C. H. H., 290, 292
Beck, D. J. K., 99, 104
Becker, D. P., 73, 84
Bedwell, S. F., 298, 299
Belza, J., 293, 294
Bennington, J. L., 202, 204
Bernard, J. D., 225, 233
Berry, R. G., 294
Best, P. V., 13, 15, 99, 104, 208, 214
Bestle, J., 276, 284
Bichel, J., 217, 233

Bickerstaff, E. R., 132, 152
Bignami, A., 350, 359, 360
Bigner, D. D., 6, 15
Bing, J., 217, 233
Black, B. K., 200, 204, 296, 297
Bloch, M., 83, 84
Blockey, N. J., 289, 292
Blood-brain barrier, see under Cranial region
Blood vessels
  malformations, 241–256
  neoplasms, 235–240
Bloom, H. J. G., 151, 152
Boczko, M. L., 241, 256
Bodian, M., 2, 11, 15, 101, 104, 138, 140, 152
Bofin, P. J., 142, 152
Bone marrow metastasis
  cerebellar medulloblastoma, 149–150, **140–151**
  glioblastoma multiforme, 79, **81**
Bonebrake, R. A., 236, 240
Borello, E. D., 141, 153, 287, 288, 298
Borit, A., 227, 233, 276, 284
Bouchard, J., 45, 46, 49
Brady, W. J., 303, 308
Brain, see under Cranial region
Brainstem, see under Cranial region
Brand, M. M., 217, 233
Brightman, M. W., 104, 105, 126
Brihaye, J., 5, 15, 248, 256
Brion, S., 255, 256
Brown, M. H., 200, 204
Brust, J. C. M., 13, 15
Bucciarelli, E., 6, 15
Bucy, P. C., 227, 233
Burstein, S. D., 216, 217, 233
Burston, J., 300

Calcarine infarction, 346, 346
Capillary hemangioblastoma, telangiectases, hemangioendothelioma, see under the nouns
Carcinoma
  choroid plexus, 260–261, **260**, 261, 267
  differential diagnosis, meningioma, 189
  direct extension, 318
  embryonal, pineal region, 276–277, **277**
    foci, germinoma, 276
  metastatic, 319–327, **323**, **325**, **369**
    appearance
      gross, 319–321
      microscopic, 321–324
    cerebral edema, 334
    differential diagnosis, 326
      meningioma, 189, 326
      poorly differentiated glioma, 321–322, 326
  diffuse infiltration, spinal nerve roots, **326**, **327**
    dura, 320, **320**, 324
    to meningioma, 321, 327
    to primary glioma, 321, 323
    incidence, 319
    leptomeninges, **319**, 324–325
      desmoplastic reaction, **321**, 324
    parenchymatous involvement, 320–321, **325**
    primary sites, 319
    sites, 319–321
    smear, 323
    subarachnoid space, 320
    subdural, 320, 323
    variant (meningeal carcinomatosis or carcinomatous meningitis), 320, 325–326
  oat cell
    bronchus, metastatic to fourth ventricle ependymoma, 321
    differential diagnosis
      glioblastoma, 326
      medulloblastoma, 152, 326, **327**
      oligodendroglioma, **101**
  pituitary, **314**
  renal cell
    association, capillary hemangioblastoma, in von Hippel-Lindau's disease, 240
    differential diagnosis
      capillary hemangioblastoma, 240, 326
      gemistocytic astrocytoma, 326
Carcinomatosis, meningeal, 320, 325–326, **326**
  differential diagnosis, 326
    oat cell carcinoma, 326, **327**
Carcinomatous meningitis, see Meningitis, carcinomatous
Castaigne, P., 226, 233, 235, 239, 240
Cauda equina, see under Spinal canal
Cavanagh, J. B., 4, 15, 158, 167
Cavernoma, 245
Cavernous angioma, see under Angioma
Central neurofibromatosis, see Neurofibromatosis, von Recklinghausen's, central form
Central neurogenic tumors, 7–17 (see also specific types)
  classification, 7–8
  general biologic characteristics, 9–15
Central schwannoma, see under Schwannoma
Cerebellum, see under Cranial region
Cerebrum, see under Cranial region
Cervós-Navarro, J., 184, 189, 211, 214
Chatty, E. M., 151, 153
Chemical agents, experimental, 5–6

Chemodectoma
glomus jugulare, 314–315, **315**
differential diagnosis
angioblastic meningioma, **315**
capillary hemangioblastoma, 315
pineal gland, **283**
Cholesteatoma, **262**, **290**
Cholesterinosis, **262**
Cholesterol granuloma, **262**
Chondroma, direct extension, **318**
Chondrosarcoma
direct extension, **318**
meninges, **200**
mesenchymal, 200, **200**
Chordoma, 315–318
appearance
gross, **315–316**
microscopic, **316**
definition and histogenesis, 315
intracranial, **316**, **317**
malformative origin, 4
prognosis, 316
sites, 315–316
Choriocarcinoma, pineal region, 276
Chorioepithelioma, **276**
Choristoma of neurohypophysis, 299–300, **299**, **300**
Christensen, E., 192, **201**, **203**, **204**
Choroid plexus, see under Cranial region
Choroid plexus papilloma, see under Papilloma
Circumscribed arachnoidal cerebellar sarcoma, see under Sarcoma
Cirsoid angioma, see under Angioma
Cisterna magna, see under Cranial region
Clarke, E., **232**, 233
Clasen, R. A., 334, 348
Clemente, C. D., **359**, **360**
Coley, B. L., **318**
Colloid cysts, see under Cyst
Congdon, C. C., **316**, **318**
Cooper, I. S., **108**, **126**, **296**, **297**
Corpus callosum, see under Cranial region
Cortex, see under Cranial region
Courville, C. B., 1, 15, **108**, **126**, **158**, **167**, **318**
Coxe, W. S., **264**, **265**
Cramer, F., 237, **240**
Cranial region
acoustic nerve, schwannoma, 207, **207–209**, **211**
anterior fontanelle, melanotic neuroectodermal tumor of infancy (retinal anlage tumor), **297**
arachnoid villi
meningioma, 169
normal, **171**
associated hamartomas, von Recklinghausen's neurofibromatosis, **303**, **304**, 304–308
basal ganglion
arteriovenous malformation, **253**
cavernous angioma, **245**
blood-brain barrier, effects of cerebral edema, 334, **337**, 338, 342
brain
carcinoma metastatic to, **320–321**
normal, radiation effects, **350–351**
radiation effects, 350–360, **351–357** (see also Radionecrosis, brain)
vascular changes, 350, 353–354, **357**, 358–360
tumor immunization studies, **15**
brainstem
astrocytoma, prognosis, **46**
compression, 343
hemorrhage, 343–344, **345**
carotid arteriogram, arteriovenous malformations, **248**
cerebellum
astrocytoma, 21, 24, 32–34, **32**, **33**
cystic, **25**
diffusely infiltrating, **28**
solid, **24**
capillary hemangioblastoma, **237**
cortex, effects, radiation, 355–358, **358**
dysplastic gangliocytoma, 164, **164**, **165**, 166
herniations, 346–347
superior, with tentorial notching, 346, **347**
tonsillar, 347, **347**
incidence of tumors, 2
medulloblastoma, 132, **133–146**
melanoma metastatic to, **328**
cerebrum
astrocytoma, 22
diffuse, **22**
diffuse fibrillary, **26–27**
edema, 333–342
astrocytic response, 335–339, **338–340**
effects, white matter, 334–335, **335**, **338**, 339
histiocytosis X, 225–227, **226**
neuroblastoma, 154, **155**, **156**
differentiating (ganglioneuroblastoma), **156**, **157**
Sturge-Weber disease, **253**, 255–256, **256**
teratoma, **285**
changes produced by neoplasms, 333–348
brainstem hemorrhages, 344, **345**
calcarine infarction, 346, **346**
cerebral edema, 333–342
ventricular compression, **335**

compression
brainstem, 343
ventricle, **335**
hydrocephalus, 342
choroid plexus papilloma, 257, **258**
internal herniations, 343–347
cerebellar, 346–347, **347**
cingulate, 343, **343**
hippocampal, 343, **344**, **345**
pressure effects
dura and skull, 348
pituitary gland, 347
vascular, glioblastoma multiforme, 64–68, **64–68**
chordoma, 315–316, **316**, **317**
choroid plexus, 257–267
carcinoma, 260–261, **260**, **261**, **267**
colloid cysts, 263–264
meningioma, 263
papillary and acinar mucus-secreting adenomas, 259, **260**, **267**
papillomas, 257–262, **258–261**, **267**
xanthogranuloma, 262–263, **262**, **263**
cisterna magna, ependymoma, **109**, **110**
corpus callosum
lipoma, **295**
reticulum cell sarcoma-microglioma, **218**, **221**, **223**
cortex
cavernous hemangioma, **246**
diffuse cerebral astrocytoma, 21, **22**
effects on
arteriovenous malformation, **251**
radiation, 355–358, **355**, **358**
frontal, and subcortical white matter, multicentric glioblastoma, **57**
cortical tuber, tuberous sclerosis, **301**
dura
carcinoma metastatic to, 320, **320**
fibrosarcoma, **192**, **193**
invasion, glioblastoma multiforme, 70, **70–71**
pressure effects, tumors, 348
sarcoma, 192
ectopic gliomas, 296
fetal external granular layer
medulloblastoma
desmoplastic pattern, **146**
neoplastic proliferation, **131**
normal, **130**
frontal cortex and subcortical white matter, multicentric glioblastoma, **57**
frontal lobe, glioblastoma multiforme, **59**
glomus jugulare, chemodectoma, 314–315, **315**
gray matter
hypothalamic ganglionic hamartoma, 298
radiation effects, 351, **353**, 359
hypothalamic region
ganglionic hamartoma, **298**
germinoma, **274**
juvenile astrocytoma, **23**
incidence, tumor types, 1–3
infiltration
generalized lymphosarcoma, **231**
Hodgkin's disease, **232**
lymphosarcoma, **228**
intracranial chordoma, **316**, **317**
intracranial hemorrhage, as terminal lesion, acute leukemia, 233
leptomeninges
arteriovenous malformation, **253**
in central neurofibromatosis, **307**
carcinoma metastatic to, **319**
desmoplastic reaction, **321**
ectopic gliomas, 296
invasion
diffuse fibrillary astrocytoma, **31**
glioblastoma multiforme, **59**, 68, **69**
malignant astrocytoma, **43**
medulloblastoma, 142, **143**, **144**
microgliomatosis, **223**, **224**
melanoma metastatic to, **330**
melanomatosis, **310**
malignant, with neurocutaneous melanosis, **311**
meningeal carcinomatosis, 325–326, **326**
neurocutaneous melanosis, 309–311
with malignant melanomatosis, **311**
primary meningeal melanoma, 309–311
spindle cell sarcoma, **194**
lipoma, 294–295
corpus callosum, 285
lobe
frontal, glioblastoma multiforme, **59**
temporal
astroblastoma, 51
secondary infiltration, sarcoma, 228, **228**
medulla
capillary hemangioblastoma, 237, 243
capillary telangiectases, **244**
medullary velum, origin, cerebellar medulloblastoma, 131
medulloepithelioma, **128**, **135**
meninges
angiomatosis, **253**

carcinomatosis or carcinomatous meningitis, 325–326, **326**
fibrosarcoma, **191**
meningioma, 169–190
tuberculum sellae, **179**
primary lymphosarcoma, 227
sarcoma, **197**
metastasis to, 332
carcinoma, 319–327
dura, 320, **320**, 324
leptomeninges, **319**, **321**
oat cell, with rosette formations, 326, **326**, **327**
parenchymatous involvement, 320–321, **325**
subarachnoid space, 320
subdural, 320, **323**
melanoma, 328–332, **330**
amelanotic, diffusely infiltrating brain, **331**
diffuse meningeal spread, **329**
microgliomatosis, **218**, **222**, **223**
midbrain, diffuse fibrillary astrocytoma, **31**
molecular and granular layers, invasion, medulloblastoma, **144**
nerve root tumors, 205–214
histogenesis and nomenclature, 205–206
neuroglia, radiation changes, 354
neurohypophysis, choristoma, 299–300, **299**, **300**
optic nerve, associated tumors, central form, von Recklinghausen's neurofibromatosis, 21, 303
astrocytoma, 21
paraphysis, origin, colloid cysts, 263, 265
parasagittal region, meningioma, 172, **173**
parenchyma, carcinoma metastatic to, 320–321, **325**
periosteum, metastasis, sympathicoblastoma, 332
pineal region, 269–284
choriocarcinoma, 276
embryonal carcinoma, 276–277, **277**
epidermoid and dermoid cysts, 283
germinoma, 269–275, **271**, **274**
association, teratoma, 270, **272**, **273**
glial cysts, 283
meningioma, 283
normal pineal gland, **278**
parenchyma, 277–283
chemodectoma, 283
ganglioglioma, 282–283, **282**, **283**
ganglioneuroma, 282–283
glioma, 283
pineoblastoma, 281, **281**
pineocytoma, 279–281, **279**, **280**
teratoma, **267**, 275–276
association, germinoma, 270, **272**, **273**
pituitary gland
adenoma, 314–315
chromophobe, **314**, **315**
pressure effects, tumors, 347
pons, astrocytoma, 24, **25**
pontocerebellar angle
choroid plexus papilloma, **258**
epidermoid cyst, **290**
radiation changes, 349–360
reticulum cell sarcoma, **219**
skull
hyperostosis, meningioma, 174, **175**
malignant primary bone tumors, 318
pressure effects, tumors, 348
silver beating appearance, 348
subarachnoid space
arteriovenous malformation, **249**
carcinoma metastatic to, 320
invasion
cerebellar astrocytoma, 43, **43**
medulloblastoma, 142, **143**, 148–149
venous malformations, 254
superior longitudinal sinus, invasion, radiated malignant astrocytoma, 13
suprasellar region
germinoma, 269–275, **272**, **273**
mixed, teratoma, 270, **272**, **273**
teratoma, 275–276
mixed, germinoma, 270, **272**, **273**
temporal lobe, astroblastoma, 51
tuberculum sellae, meningioma, **179**
vascular endothelial proliferation
cerebellar astrocytoma, 32
glioblastoma multiforme, 64–68, **64–68**
pilocytic astrocytoma, 35, **36**
oligodendroglioma, 96, **96**, **97**
malignant, 96, **98**
vascular lumen, invasion, glioma, 12
vein of Galen
aneurysm of, 250, **251**
arteriovenous malformations, 247–248, **251**, **253**
involvement, brainstem hemorrhage, 344
ventricle
compression, **335**
fourth
ependymoma, **110**
teratoma, 286–287, **286**, **287**
ganglioglioma, **160**, **163**, **164**
glioblastoma multiforme, vascular patterns, **67**
meningioma, 172, **174**, **179**

third
astrocytoma, frontispiece
colloid cysts, 263–265, **264**, **265**
craniopharyngioma, **267**
vermis
medulloblastoma, **133**, **136–139**
pigmented papillary form, **141**
polymorphic cell sarcoma, 202
white matter
arteriovenous malformations, 250, **251**
edema, 334–335, **335**, 338, **338**
metastatic adenocarcinoma, **323**
multiple carcinomatous disease, 321
radiation effects, 351, **352**, 355, **357**, 358, 359
subcortical, multicentric glioblastoma, **57**
suboccipital, cavernous hemangioma, **246**
tuberous sclerosis, 301
glial ectopias, **301**
Craniopharyngioma, 292–294, **293**
appearance, gross and microscopic, 293
clinical data, 292
incidence, 292
malformative origin, 4
pathogenesis, 292
third ventricle, **267**
treatment and prognosis, 294
Cravioto, H., 205, 211, 212, 214
Crawford, J. V., 247, 256
Critchley, M., 301, 302
Crompton, M. R., 350, 352, 359, 360
Cryptic arteriovenous and venous malformations, 247, 249
Cushing, H., 49, 100, 172, 186, 189, 235, 240
Cushing's syndrome, association, pituitary adenoma, 314
Cyst
cerebellar, differential diagnosis, astrocytoma, 49
colloid, third ventricle, 263–265, **264**, **265**
origin, paraphysis, 263, 265
dermoid, 288–292
appearance
gross, 289
microscopic, 290
definition, 288
intraspinal, **289**
pathogenesis, 288–289
lumbar puncture, 5
malformative origin, 4
pineal region, 283
sites, 289
epidermoid, 288–292
appearance
gross, 291
microscopic, 292
definition and pathogenesis, 288–289
malformative origin, 4
pineal region, 283
pontocerebellar angle, **290**
sites, 290
suprasellar, 292
wall, **291**
glial, pineal region, 283
intrasellar Rathke cleft, 294
neuroepithelial, third ventricle, 263–265, **264**, **265**
of endodermal structure, 287
pineal, 283
spinal enterogenous, **267**, 287–288
association
Arnold-Chiari malformation, 288
Klippel-Feil deformity, 288
teratomatous, of vertebral canal, 287
Cystic astrocytoma, see under Astrocytoma

Dahlin, D. C., 316, 318
Davidson, S. I., 292
Davis, F. A., 303, 308
Davis, R. L., 259, 265, 302
Dayan, A. D., 270, 275, 284
Deck, J. H. N., 128, 129
Degenerative diseases, nervous system, 5 (see also under specific disease)
Den Hartog, B. J. C., 225, 233
Dermoid cyst, see under Cyst
Desmoplastic medulloblastoma, see under Medulloblastoma, variants
Diagnostic aids, 361–370
cryostat-cut unfixed sections, 367
enzyme histochemical technics, 366
frozen sections, 367
metallic impregnations, 363
Hortega silver carbonate, 363, **365**
silver, reticulin fibers, 362
smear or wet film technic, 366–367
spinal fluid cytology, 370, **371**, **373**, **375**, **377**
stains, 361–362
connective tissue, 362
hematoxylin and eosin, 361
nerve cells and neurites, 362–363
Bielschowsky, 363, **365**
neuroglia, 362
Papanicolaou, 370, 372, 374, 376

silver, reticulin fibers, 362
van Gieson, 362, **365**
Differentiating cerebral neuroblastoma, see under Neuroblastoma
Dom, R., 166, 167
Drachman, D. A., 6, 15, 33, 40, 49, 149, 150, 153
Dretler, J., 302
Druckrey, H., 6, 15
Duffell, D., 6, 15, 33, 40, 49
Dunn, J., Jr., 42, 49, 263, 265
Dura, see under Cranial region and under Spinal canal
Durity, F. A., 138, 153
Dysgenetic syndromes, 300–311 (see also under specific syndrome)
Dysglobulinemia, association, reticulum cell sarcoma-microglioma, 217
Dysplastic gangliocytoma of cerebellum, see under Gangliocytoma

Earle, K. M., 172, 187
Ecchondrosis physaliphora, 315
Ecchordosis, 315
Ectopic pinealoma, glioma, see under the nouns
Edelman, F. L., 349, 360
Edema, cerebral
astrocytic response, 335–339, **338–340**, **369**
increased tetrazolium reductase activity, 339, **339**
cytotoxic, 334
effects, 342
experimental, 333, **339**, **340–342**
glioblastoma multiforme, 334, **337**
cingulate herniation, **343**
pathogenesis, 333–335
vasogenic, 334, **341**, **342**
white matter, 334-335, **335**, **338**, 339
Edgar, R., 217, 233, 247, 256
Elvidge, A. R., 46, 49, 83, 84
Embryonal carcinoma, sarcoma, see under the nouns
Encephalitis
atypical granulomatous, 215
reticulohistocytic, 215
Encephalotrigeminal or encephalofacial angiomatosis, see under Angiomatosis
Endodermal sinus tumor, 276
Endothelioma, cholesteatomatous, 262
Endotheliomatous meningioma, see under Meningioma, types
Ependymitis blastomatosa, 79, **79**
Ependymoblastoma, 119–123, **120–122**
differential diagnosis, medulloepithelioma, 129
Ependymoma, 104–126
appearance
gross, 108–110
microscopic, 110–113
association
central form, von Recklinghausen's neurofibromatosis, 108, **112**, **113**, 303, **305**, **306**
syringomyelia, 108
blepharoplasts, 104–105, **105**, **107**
cartilaginous transformation, 113
cellular, **112**
cisterna magna, **109**, **110**
clinical data, 105–108
definition, 104
differential diagnosis, 124–126
astroblastoma, 52, 125
choroid plexus papilloma, 125–126, 261
chromophobe adenoma of pituitary, 126, 313
medulloblastoma, 125, 152
sarcoma, 203
sympathicoblastoma, 125
fibrillated ependymal cells, 111, **113**
fourth ventricle, **110**
carcinoma metastatic to, 321
incidence, 108
malignant, 119–123, **120–122**
rosette, 122, **122**
metastatic spread, 13, 123–124
extraneural, 123, **123**, **124**
multiplicity, 108
myxopapillary, of filum terminale, 118–119, **119**
natural history, 105–108
normal and abnormal ependymal cell, 104–105, **107**
papillary, 113, **115**
spinal cord, extraneural metastases, 123, **123**, **124**
perivascular pseudorosettes, 113, **115**, 125
blepharoplasts, **112**
plastic, 108, **110**
prognosis, 124
rosettes
ependymal, 111, **111**, **112**
Homer Wright, 125, **125**
malignancy, 122, **122**
sites, 108
smear, **103**
spinal cord, 108, 110
malignant, **121**
treatment, 124
variants, 116–123
Epidermoid cyst, see under Cyst

Epilepsy, 4
  astrocytoma, 21
  ganglioneuroma and ganglioglioma, 158, 159
  Jacksonian, Sturge-Weber disease, 255
Epithelioid meningioma, see under Meningioma, types
Epulis, pigmented, 297
Erythrocythemia, association, capillary hemangioblastoma, 236
Escourolle, R., 140, 153
Experimental tumors, 5–6

Fallot's tetralogy, association, arteriovenous malformations, 247, 250, **251**
Farrell, D. F., 241, 256
Feigin, I. H., 68, 74, 84, 216, 233
Ferry, D. J., 4, 16
Fibrillary astrocytoma, see under Astrocytoma
Fibroblastic meningioma, see under Meningioma, types
Fibroblastoma, perineurial, 206
Fibrosarcoma, 192–193
  differential diagnosis, metastatic melanoma, 328, **331**
  dura, **192**, **193**
  giant cell, 203
  invasive
    focus of malignant glioma, **365**
    island of malignant astrocytoma, **365**
  meningeal, **191**
  metastasis
    central nervous system, 332
    extraneural, mixed, glioblastoma, 82
  mixed, glioblastoma, 74–78, **74–78**, 82
Filum terminale, see under Spinal canal
Fischer-Williams, M., 325, 332
Fisher, D., 223, 234
Flexner, S. A., 125, 126
Foix-Alajouanine disease, **253**, 255
Fokes, E. C., Jr., 108, 120, 123, 124, 126
Fontanelle, anterior, see under Cranial region
Forsythe, R. W., 318
Fowler, M., 127, 129, 141, 153
Fox, J. L., 333, 342, 348
Freeman, L., 85, 104
Freireich, E. J., 233, 234
French, J. D., 227, 234
Friedman, N. B., 269, 284
Frost, John K., 370, 372, 374, 376
Fujita, S., 130, 153
Fuller, A. M., 315
Furtado, D., 285, 288

Gagel's granuloma, see under Granuloma
Gangliocytoma, 158
  dysplastic, of cerebellum, 164, **164**, **165**, 166, **166**
Ganglioglioma, **135**, 158–167, 160, 163, **365**
  chemical pathogenesis, experimental, 6
  cytogenesis, 158
  definition, 158
  differential diagnosis, 167
    astrocytoma, 159, 167
  growth and spread, 161
  malignant changes, 161
  pineal region, 282–283, **282**, **283**
  transitional forms with neuroblastomas, 161
  treatment, 166
  variants, 164–166
  vascular pattern, 161, **164**
Gangliomatosis of the cerebellum, 164
Ganglion, basal, see under Cranial region
Ganglioneuroblastoma, 156, **156**, **157**
Ganglioneuroma, 158–167
  definition and cytogenesis, 158
  differential diagnosis, 167
    astrocytoma, 159, 167
  growth and spread, 161
  malignant changes, 161
  pineal region, 282–283
  transitional forms with neuroblastomas, 161
  treatment, 166
  variants, 164–166
Gardner, W. J., 207, 214, 303, 308
Gemistocytic astrocytoma, see under Astrocytoma
Germinoma, 269–275, **274**, 287
  foci in embryonal carcinoma, 276
  hypothalamic region, **274**
  intrasellar, 272
  nomenclature, 269
  pineal and suprasellar, 269–275, **271**
    appearance
      gross, 271–272
      microscopic, 272–275
    clinical effects, 270–271
    definition and cytogenesis, 269
    differential diagnosis, 275
      reticulum cell sarcoma-microglioma, 225, 275
    incidence, 269–270
    mixed, teratoma, 270, **272**, **273**
    multifocality, 270
    nomenclature, 269
    sites of origin, 269–270
    treatment and prognosis, 275

radiation response, 349
suprasellar, 269 (see also Germinoma, pineal and suprasellar)
Ghatak, N. R., 272, 284
Giant cell glioblastoma, fibrosarcoma, see under the nouns
Gibbs, N. M., 187, 189
Gibson, J. B., 309, 311
Giuffrè, R., 295
Gland, pituitary and pineal, see under Cranial region
Glasauer, F. E., 13, 16, 123, 126
Glial cyst, see under Cyst
Glioblastoma
application of term, 7, 55
dedifferentiation, 7
detection of by spinal fluid cytology, 370, **371**
differential diagnosis, oat cell carcinoma, 326
epithelial appearance resembling carcinoma on experimental transplantation, 15
giant cell, 72–74, **73**
metastasis, 13
multiforme, 55–85, **60–63**, **369**
appearance
gross, 56–57
microscopic, 57–68
associated lesions, 56
fibrosarcoma, **59**
sarcoma, **59**
biologic behavior, 10
butterfly type, 57, **59**
cerebral edema, 334, **337**
cingulate herniation, **343**
clinical data, 56
cytogenesis, 55
definition, 55
derivation
astrocytoma, 42
virus, experimental, 6
differential diagnosis, 83–84
malignant astrocytoma, 49
medulloblastoma, 137, 152
metastatic melanoma, 328
oligodendroglioma, 101
sarcoma, 83–84, 193, 203
direct spread, 69
frontal, **59**
growth and spread, 68–72
incidence, 55–56
invasion
dura, 70, **70–71**
leptomeninges, **59**, 68, **69**
metastatic spread, 78–82
bone marrow, 79, **81**
cerebrospinal fluid pathways, **78–79**
extracranial metastasis, lymph node, **82**
extraneural metastases, **80–81**
mixed, fibrosarcoma, 82
reinvasion, brain, 79
mixed, fibrosarcoma, 74–78, **74–78**, 82
multicentric, **57**
multiplicity, 56
prognosis, 83
secondary structures, 68
separate identity, 9
sites, 56
smear, **59**
spinal cord, 78–79, **78**
spongioblasts, 60, **62**
tertiary structures, 71, **71–72**
treatment, 82–83
variants, 72–78
vascular patterns, 64–68, **64–68**
Glioma (see also specific type)
association, central form, von Recklinghausen's neurofibromatosis, 303
biologic behavior, 10–15
metastasis, 12–15
transplantation experiments, 14–15
primary structures, 11
secondary structures, 11–12
tertiary structures, 12
venous permeation, 12
dedifferentiation, 9
differential diagnosis
anaplastic carcinoma, 321–322, 326
metastatic melanoma, 328, **331**
ectopic, 296–297
sacral region, **296**, **297**
experimental, chemically induced, 6
incidence, 2–3
invasion, vascular lumen, 12
malignant
adjacent, spindle cell sarcoma, **365**
association, multiple sclerosis, 5
in invasive fibrosarcoma, **365**
multicentricity, 10–11
mixed, 9
sarcoma, 198
pencil, 26
pineal gland, 283

primary, metastatic carcinoma in, 321, **323**
radiation treatment, 349, 350, **351**, **357**
Gliomatosis cerebri, **28**, 42
association
neurofibromatosis, 42
tuberous sclerosis, 42
diffuse growth, 10
Gliosis, reactive, differential diagnosis, diffuse fibrillary astrocytoma, 46–47
β-Globulinemia, association, reticulum cell sarcoma-microglioma, 217
Globus, J., 36, 49
Globus, J. H., 269, 284
Glomus jugulare, see under Cranial region
Gluszcz, A., 290, 292
Goldberg, G. H., 292, 294
Goldman, R. L., 78, 84
Gordon, H., 362, 370
Grace, J. T., Jr., 15, 16
Granuloma
cholesterol, 262
Gagel's diagnostic differentiation, cerebral form of histiocytosis X, 225–226
hypothalamic, 225–227 (see also Histiocytosis X, cerebral form)
Gray matter, see under Cranial region
Grcevic, N., 36, 49
Greene, H. S. N., 14, 16, 77, 84
Griño, A., 363, 370
Grove, A. S., Jr., 5, 6, 16
Grover, W. D., 293, 294
Gullotta, F., 77, 84

Hallervorden, J., 164, 166, 167
Hamartoma
hypothalamic ganglionic, 298–299, **298**
association, pubertas praecox, 298, **298**
gray matter, 298
neurogenic intra-axial and ectopic, malformative origin, 4
Hand-Schüller-Christian disease, association, hypothalamic granuloma or cerebral form of histiocytosis X, 225–227
Harkin, J. C., 205, 206, 209, 211, 213, 214, 302, 308, 309, 311
Harriman, D. G. F., 287, 288
Harris, W., 269, 284
Heffner, R. R., Jr., 241, 256
Hemangioblastoma, 235
capillary, 235–241, **238**
appearance
gross, 237
microscopic, 237–239
associated lesions, 235–236
erythrocythemia, 236
pheochromocytoma, 236
syringomyelia, 236, **237**
von Hippel-Lindau disease, 235–236, 239, 240
cerebellum, **237**
clinical data, 235
cytogenesis, 235
definition, 235
differential diagnosis, 239–240
astrocytoma, 49, 239
chemodectoma, glomus jugulare, 315
meningioma, 181–182, 189, 239
metastatic clear cell renal carcinoma, 240, 326
oligodendroglioma, 239
genetic basis, 236
growth and spread, 239
incidence, 235
medulla, **237**, **243**
prognosis, 239
recurrence, 239
reticulin fibers, 237, **238**
sites, 236
stromal cells, 237–239, **238**
sudanophilic lipid droplets, 237, **243**
treatment, 239
cerebellar, differential diagnosis oligodendroglioma, 101
Hemangioendothelioma, 235
capillary, 235
Hemangioma, cavernous, **246**
Hemangiopericytoma of meninges, 182, 203
Hemorrhage
brainstem, 344, **345**
intracranial, as terminal lesion, acute leukemia, 233
Henry, J. M., 198, 204
Henson, R. A., 315
Herman, M. M., 15, 16
Herndon, R. M., 36, 49
Herniation, 343–347
cerebellar, 346–347
superior, with tentorial notching, 346, **347**
tonsillar, 347, **347**
cingulate, 343, **343**
effects
brainstem compression, 343
brainstem hemorrhage, 344, **345**

calcarine infarction, 346, **346**
hippocampal or tentorial, 343, **344**, **345**
Kernohan notch, 343
Herzog, I., 339, 348
Hirano, A., 247, 250, 256, 310, 311
Histiocytosis X, cerebral form, 225–227, **226**
association
Hand-Schüller-Christian disease, 225–227
Letterer-Siwe's disease, 226–227
Hodgkin's disease
as primary neoplastic proliferation, 225
secondary involvement, nervous system, 232
intracerebral infiltration, **232**
Hoenig, E. M., 259, 265
Hoff, J. T., 236, 239, 240
Hoffman, H. J., 309, 311
Hoffmann, G. T., 187, 189
Hope-Stone, H. F., 151, 153
Horrax, G., 239, 240, 282, 284, 363, 370
Horvat, B., 216, 217, 234
Hosobuchi, Y., 6, 16
Hossman, K. A., 35, 49
Hunter, I. J., 292, 294
Hydrocephalus, 342
astrocytoma, **frontispiece**
choroid plexus papilloma, 257, **258**
etiologic variety, 257, 342
Hypertrophy, diffuse, of cerebellar cortex, 164
Hypothalamic ganglionic hamartoma, see under Hamartoma
Hypothalamic granuloma, see under Granuloma
Hypothalamic region, see under Cranial region

Ikuta, F., 5, 16
Infarction, calcarine, 346, **346**
Infundibuloma, 36
Ingraham, F. D., 285, 287, 288
Intramedullary schwannoma, see under Schwannoma, variant
Intramedullary schwannosis, see Schwannosis, intramedullary
Intrasellar Rathke cleft cyst, see under Cyst
Intraventricular meningioma, see under Meningioma, types
Isomorphous oligodendroglioma, see under Oligodendroglioma
Ivankovic, S., 6, 16
Ivory osteoma, see under Osteoma

James, T. G. I., 100, 104
James, W., 270, 284
Jellinger, K., 255, 256, 276, 284
Jelsma, R., 82–84
Jernstrom, P., 227, 234
Jervis, G. A., 302

Kadin, M. E., 4, 16, 131, 140, 153
Kageyama, N., 270, 276, 284
Kakulas, B. A., 217, 234
Kane, W., 138, 153
Keegan, H. R., 184, 189
Kepes, J., 184, 189, 225–227, 234
Kernohan, J. W., 7, 8, 16, 35, 50, 55, 72, 84, 118, 126 157, 161, 167, 182, 190, 191, 198, 200, 203, 204, 294, 313, 314, 318, 343, 348
Kershman, J., 130, 153
Kersting, G., 9, 16, 35, 50, 140, 153
Kirshbaum, J. D., 318
Klatzo, I., 333, 334, 339, 348
Klinger, M., 318
Klintworth, G. K., 344, 348
Klippel-Feil deformity, association, spinal enterogenous cyst, 288
Knight, G., 287, 288
Krabbe, K. H., 269, 284
Kramer, S., 294
Kruse, F., Jr., 182, 190
Kurland, L. T., 1, 16

Lampert, P. W., 350, 351, 360
Landers, J. W., 292
Layers, fetal external granular, granular, molecular, see under Cranial region
Layton, D. D., 158, 167
LeCompte, P. M., 315
Legier, J. F., 287, 288
Lehrer, H., 227, 234
Leptomeninges, see under Cranial region
Letterer-Siwe's disease, association, cerebral form, histiocytosis X, 226–227
Leucoencephalopathy, progressive multifocal, 4
Leukemia, secondary involvement, 232–233
intracranial hemorrhage as terminal lesion, 233
Lewis, P., 260, 265
Lhermitte-Duclos disease, 164
Lindau, A., 235, 236, 240
Lindau's syndrome, see von Hippel-Lindau disease
Lindau's tumor, 235
Lindenberg, R., 343, 348
Lipoma, 294–295

corpus callosum, **295**
intracranial, 294–295
spinal canal, 295
Liss, L., 157, 161, 167, 300
List, C. F., 289, 292
Lobes, frontal and temporal, see under Cranial region
Løken, A. C., 270, 284
Lopes de Faria, J., 201, 204
Lüginbühl, H., 3, 16, 85, 104, 169, 190
Lumsden, C. E., 9, 16, 35, 50, 153
Luna, L. G., 361, 370
Lung
metastasis from, carcinoma, 319
metastasis to, papillary malignant meningioma, **187**, **188**
Luse, S. A., 33, 40, 64, 84, 93, 104, 206, 211, 212, 214, 292, 294
Lymph node, see under Lymphoreticular system
Lymphoma, malignant, 215
secondary infiltration, nervous system, **229–231**
Lymphoreticular system, 215–234
lymph node metastasis, glioblastoma multiforme, **82**
radiation response, 349
secondary proliferations, 227–228
Lymphosarcoma
lymphoblastic, 376, **377**
detection of by spinal fluid cytology, 376, **377**
primary meningeal, 227
confinement, spinal epidural space, 227
secondary proliferations, 228–229, **228**, **231**
Lynn, J. A., 74, 84

Macroglobulinemia, Waldenström's, association, reticulum cell sarcoma-microglioma, 217
Madonick, M. J., 314
Mair, W. G. P., 255, 256
Makeever, L. C., 149, 153
Malformations
Arnold-Chiari, association, spinal enterogenous cyst, 288
arteriovenous, 246–250
appearance
gross, 248–249
microscopic, 250
associated lesions, 247
congenital berry aneurysms, 247
Fallot's tetralogy and patent ductus, arteriosus, 247, 250, **251**
basal ganglion, **253**
carotid arteriogram, **248**
cryptic, 247
definition, 246
effects, cerebral cortex, **251**
incidence and natural history, 246–247
leptomeninges, **253**
sites, 247
subarachnoid space, **249**
variants, 250
vein of Galen, 247–248, **251**, **253**
venous, 254–256
spinal cord, **253**, **254**, 255
variants, 255–256
Malignant astrocytoma, lymphoma, reticulosis, reticuloendotheliosis, etc., see under the nouns
Mandybur, T. I., 350, 354, 360
Manuelidis, E. E., 15, 16, 35, 50
Marshall, A. H. E., 216, 234, 274, 284
Marshall, G., 232, 234
Marsland, T. A., 363, 370
Matson, D. D., 257, 265
McCann, W. P., 332
McConnell, T. H., 247, 256
McCormick, W. F., 46, 50
McDonald, L. W., 359, 360
McGrath, J. T., 3, 16
McMenemey, W. H., 367, 370
McNeel, D. P., 332
Medulla, see under Cranial region
Medullary velum, see under Cranial region
Medulloblastoma, 130–153
appearance
gross, 132
microscopic, 133–141
clinical data, 131–132
cytogenesis, 4, 130–131
dedifferentiation, 7
definition, 130
desmoplastic, 372, **373**
detection of by spinal fluid cytology, 372, **373**
differential diagnosis, 151–152
cerebral neuroblastoma, 152
ependymoma, 125, 152
malignant astrocytoma, 138, **139**, 152
microcellular glioblastoma, 152
oat cell carcinoma, 152
oligodendroglioma, 101, 140, **140**, 152
pineoblastoma, 152, 281
sarcoma, 152, 203
teratoma, fourth ventricle, 286
differentiation, 138–140

astrocytic, 138, **139**
neuronal, **139**
oligodendroglioma, 140, **140**
spongioblastic, 136, **137**, 138
growth and spread, 142–146
incidence, 131–132
invasion
leptomeninges, 142, **143**, **144**
molecular and granular layers, **144**
metastasis, 147–150
extraneural, 14, 149–150, **149**
femoral marrow, **150**, **151**
lymphatic, **150**
spinal subarachnoid, **148**
spread, cerebrospinal fluid pathways, 147, **147**
ventricular, **148**
neurofibrillary processes, 133, **136**
palisading pattern, 136, **137**
perivascular pseudorosettes, 133, **138**
pigmented papillary, 141, **141**, 287
prognosis, 151
pseudopalisading pattern, 137, **138**
radiation effects, 140–141, **141**, 349, 350
therapy, 150–151, 349, 350
rosettes, 133, **136**
site, cerebellum, 132
fetal external granular layer, **130**, **131**, **146**
lateral lobe, **135**
midline, **133**
smear, **135**
subpial secondary structures, 142, **142**
treatment, 150–151
radiation, 150–151, 349, 350
variants, 141–146
desmoplastic, 143, **145**, **146**
extracerebellar growth, 146, **146**, **147**
medullomyoblastoma, 142
pigmented papillary, 141, **141**, **287**
vermis, **133**, **136–139**
pigmented papillary form, **141**
whorled pattern, **136**
Medulloepithelioma, 127–129, **128**, **135**
differential diagnosis, 129
choroid plexus adenoma, 129
ependymoblastoma, 129
teratoma, 129
pineal, 129
well differentiated papillary and tubular columnar cell adenocarcinoma, 129
metastasis, 129
Medullomyoblastoma, 142, 287
Melano-ameloblastoma, 297
Melanoma
metastatic, 328–332
amelanotic, 328
diffusely infiltrating brain, **331**
infiltrating spinal nerve root, **331**
cerebellum, **328**
differential diagnosis, 328
cerebral astrocytoma, 49, 328
glioblastoma multiforme, 328
glioma, 328, **331**
schwannoma, fibrosarcoma, 328, **331**
diffuse meningeal spread, **329**
gross and microscopic appearance, 328
intracerebral, **330**
prognosis, 332
primary meningeal, 309–311
Melanomatosis, leptomeninges, **310**
malignant, with neurocutaneous melanosis, **311**
Melanosis, neurocutaneous, 309–311
with malignant melanomatosis of leptomeninges, **311**
Melanotic neuroectodermal tumor of infancy, 287, 297–298, **297**
Melanotic progonoma, adamantinoma, see under the nouns
Meningeal carcinomatosis, see Carcinomatosis, meningeal
Meninges, see under Cranial region
Meningioangiomatosis, in central form, von Recklinghausen's neurofibromatosis, 253, 305–306
Meningioma, 169–190, **173**, **185**, **369**
appearance
gross, 173–175
microscopic, 175–184
associated lesions, 172
central form, von Recklinghausen's neurofibromatosis, 172, **253**, 303, 305–306
atypical, 186, **186**
choroid plexus, 263
clinical data, 172
definition and cytogenesis, 169
differential diagnosis, 188–189
capillary hemangioblastoma, 181–182, 189, 239
chemodectoma, glomus jugulare, 315
metastatic carcinoma, 189, 326
oligodendroglioma, 101, 189
schwannoma, 188–189, 212
en plaque, **173**
etiologic factors, 169–172

trauma, 5, 172
giant cells, **184**
growth and spread, 184–186
hyperostosis of skull, 174, **175**
incidence, 169
malignant, 186–187
metastasis, 187
metastatic carcinoma in, 321, **327**
multiplicity, 172
papillary malignant, **187**
pulmonary metastases, **188**
pineal region, 283
prognosis, 187–188
sites, 172–173
small incidental, **175**
treatment, 187
tuberculum sellae, **179**
types
angioblastic, 180–182, **181, 182**
endotheliomatous, 175–176
smear, **179**
epithelioid, 175
fibroblastic, 177–180, **180**
smear, **179**
intraventricular, 172, **174, 179**
meningotheliomatous, 175–177, **176**
highly vascular, **183**
psammomatous, 176, **177**
syncytial, 175
transitional, 176, **177**
Meningiomatosis
association, central form, von Recklinghausen's neurofibromatosis, **253**, 305–306
meningeal, 200
Meningitis, carcinomatous, 320, 325–326, **326**
differential diagnosis, 326
oat cell carcinoma, 326, **327**
Meningotheliomatous meningioma, see under Meningioma, types
Mesencephalo-oculo-facial angiomatosis, 250, **251**
Mesenchymoma, mixed malignant, meninges, 201, **201, 202**
Michael, J. C., 241, 245, 256
Microglioma, see under Sarcoma, reticulum cell sarcoma-microglioma
Microgliomatosis, 215, **218, 222–224** (see also Sarcoma, reticulum cell sarcoma-microglioma)
astrocytic reaction, 224
leptomeningeal invasion, **223, 224**
Midbrain, see under Cranial region
Miller, A. A., 157, 216, 220, 234
Miquel, J., 367, 370
Mixed tumor cell populations, 8–9
glioblastoma and fibrosarcoma, 74–78, **74–78**
oligodendroglioma, 85, **96–97**
and astrocytoma, 93, 97, **99**
pineal and suprasellar germinoma and teratoma, 270, **272, 273**
sarcoma and glioma, 198
Monstrocellular sarcoma, see under Sarcoma
Moertel, C. G., 11, 16
Moore, E. W., 233, 234
Moossy, J., 227, 234
Morello, G., 236, 240
Morris, A. A., 367, 370
Moyes, P. D., 207, 214, 303, 308
Mucus-secreting adenomas, papillary and acinar, 259, **260, 267**
Müller, R., 285, 288
Mundinger, F., 83, 84
Murray, M. R., 210, 214
Myelitis, subacute necrotic, 255
Myelomalacia, angiodysgenetic, **253**, 255
Myoblastoma, 299, 300
Myxochondrosarcoma, direct extension, 318
Myxopapillary ependymoma, see under Ependymoma
Myxosarcoma
direct extension, 318
meninges, 200

Nager, G. T., 72, 84, 173, 190
Napolitano, L., 184, 190
Neoplasms, nonneurogenic, 285–295 (see also specific types)
Nerve root tumors, 205–214 (see also nerve root entries under Cranial region and under Spinal canal)
Nerves, acoustic and optic, see under Cranial region
Netsky, M. G., 349, 350, 360
Neurilemoma, 206
Neurinoma, 206
Neuroastrocytoma, 158
Neuroblastoma, 154–157, **155, 156**
differential diagnosis, 157
medulloblastoma, 152
oligodendroglioma, 157
pineocytoma, 281
sarcoma, 157, 203
differentiating cerebral (ganglioneuroblastoma), 156, **156, 157**
growth and spread, 156–157

peripheral, metastasis to central nervous system, 332
rosettes, **155**
transitional forms, ganglioneuroma and ganglioglioma, 161
Neurocutaneous disease, 300
Neurocutaneous melanosis, see under Melanosis
Neuroectodermal tumor of infancy
melanotic, 287, 297–298, **297**
pigmented, 141, **141**
Neuroepithelial cysts, see under Cyst
Neurofibroma, 213–214, **213**
acoustic, 206
association, von Recklinghausen's neurofibromatosis, 213–214
differential diagnosis, schwannoma, 213
Neurofibromatosis, von Recklinghausen's, 302–304
association
gliomatosis cerebri, 42
neurofibroma, 213–214
central form, **303**, **308**
arteriovenous malformation, leptomeninges, **307**
association
hamartomas, 303–308
meningioma, 172, **253**, 303, 305–306
pilocytic astrocytoma, 21, 303
schwannoma, 207, 209
spinal ependymoma, 108, **112**, **113**, 303, **305**, **306**
tumors, 21, 303
ependymal cells, 305, **305**, **306**
glial malformations, **303**, **304**, 304–305
intramedullary schwannosis, 306, **307**
multiple schwannomas, 206–207, 303
forms, 302
neoplastic gliogenous transformation, 4
peripheral form, 302
central lesions, **304**, **305**
Neurogenic tumors, central, 7–17 (see also specific types)
classification, 7–8
general biologic characteristics, 9–15
mixed tumor cell population, 8–9
Neuroglia, see under Cranial region and under Spinal canal
Neurohypophysis, see under Cranial region
Neuroma, acoustic, 206
Neuronal cell tumors and primitive bipotential precursors, 127–167
Neustein, H. B., 298
Nibbelink, D. W., 236, 240
Nicol, A. A. M., 236, 240
Nishiyama, R. H., 276, 284
Noetzli, M., 360
Nonneurogenic neoplasms, 285–295
Norman, R. M., 302
Northfield, D. W. C., 298, 299

Oat cell carcinoma, see under Carcinoma
Oberman, H. A., 149, 153
O'Connell, J. E. A., 201, 204, 287, 288
Oligodendroblastoma, 85
Oligodendrocytoma, 85
Oligodendroglioma, 85–104, **87–94**, **103**
appearance
gross, 86
microscopic, 86–96
calcifications, 86, **86**, 93, **95**
clinical data, 85–86
definition and cytogenesis, 85
differential diagnosis, 101
astrocytoma, 101
capillary hemangioblastoma, 239
endotheliomatous meningioma, 101
glioblastoma, 101
hemangioblastoma, 101
medulloblastoma, 101, 140, **140**, 152
meningioma, 101, 189
metastatic oat cell carcinoma, 101, 326
neuroblastoma, 157
pineocytoma, 101, 281
pituitary adenoma, 101, 313, **314**
reticulum cell sarcoma-microglioma, 101, 225
giant cells, **95**
growth and spread, 99, **100**
hyaline droplets and granular bodies, **93**
incidence, 85
isomorphous, 98
malignant changes, 97–99
metastasis, 13, 99–100
mixed cell population, 85
mixed forms, 96–97
astrocytoma, **99**
mucinous degeneration, 87, **89**
palisading pattern, **91**
perinuclear halo, 87, **87–90**
perivascular arrangement, **92**
polymorphous, 95, **95**, 98
prognosis, 100–101
signet ring cells, **93**
sites, 86
smear, **103**

stromal and vascular elements, 95, **96**
treatment, 100
vascular endothelial proliferation, 95–96, **97**
malignant, 96, **98**
Olive, I., 206, 214
Olivecrona, H., 212, 214, 236, 239, 240
Oppenheimer, D. R., 141, 153, 164, 166, 167, 350, 360
Optic nerve, see under Cranial region
Osteochondroma, direct extension, 318
Osteoma, ivory, 318
Osteosarcoma, direct extension, 318
Ostertag, B., 216, 234
Overton, M. C., 294
Owens, G., 82, 84

Pachymeningitis interna hemorrhagica, 320
Papillary adenocarcinoma, meningioma, adenoma, see under the nouns
Papilloma
choroid plexus, 257–262, **259**
appearance, gross and microscopic, 258
definition and histogenesis, 257
differential diagnosis, 261–262
degenerative changes in normal condition, 261
ependymoma, 125–126, 261
medulloepithelioma, 129
metastatic carcinoma, 326
growth and spread, 261
hydrocephalus, 257, **258**, 342
incidence, 257
lateral ventricle, 257, **258**
malignant changes (carcinoma of choroid plexus), 260–261, **260**, **261**, **267**
metastasis, 261
natural history and clinical effects, 257
pontocerebellar angle, 257, **258**
sites, 257–258
treatment, 261
variant: papillary and acinar mucus-secreting adenomas, 259, **260**, **267**
choroideum, 257
Pappenheim, E., 309, 311
Paraganglioma, 314
Paraphyseal cysts, 263 (see also under Cyst)
Paraphysis, see under Cranial region
Parasagittal region, see under Cranial region
Parenchyma, see under Cranial region
Patterson, R. H., 123, 126
Pearly tumor, 288, **290**, 291
Pearse, A. G. E., 366, 370
Peison, B., 216, 234
Pencil glioma, 26
Penfield, W., 245, 256, 363
Pennybacker, J., 239, 240, 350, 359, 360
Periadventitial sarcoma, 215
Periosteum, see under Cranial region
Perithelial sarcoma, 215
Perivascular sarcoma, 215
Peters, A., 19, 50
Peyton, W. T., 290–292
Phacomatoses associated with tumors, 300–311
Pheochromocytoma, association
capillary hemangioblastoma, 236
peripheral neurofibromatosis, 308
Pierce, G. B., Jr., 275, 284
Pigmented epulis, 297 (see also under Epulis)
Pigmented neuroectodermal tumor of infancy, 141
Pigmented papillary medulloblastoma, see under Medulloblastoma
Pilocytic or piloid astrocytoma, see under Astrocytoma
Pineal region, see under Cranial region
Pinealocytoma, 279
Pinealoma, 269, 278
ectopic, 269, 270
Pineda, A., 213, 214
Pineoblastoma, 278, 281, **281**
differential diagnosis, 281
medulloblastoma, 152, 281
Pineocytoma, 278–281, **279**, **280**
differential diagnosis, 280–281
astroblastoma, 281
neuroblastoma with rosette formation, 281
oligodendroglioma, 101, 281
Pituicytoma, 300
Pituitary adenoma, see under Adenoma
Pituitary gland, see under Cranial region
Plasmacytoma
primary involvement, nervous system, 227
secondary involvement, nervous system, 232
Plastic ependymoma, see under Ependymoma
Pleomorphic cell sarcoma, see under Sarcoma
Plexus, choroid, see under Cranial region
Poirier, J., 206, 211, 213, 214
Polak, M., 370
Polar spongioblastoma, see under Spongioblastoma
Polymorphic cell sarcoma, see under Sarcoma
Polymorphous oligodendroglioma, see under Oligodendroglioma
Pons, see under Cranial region
Pontocerebellar angle, see under Cranial region

Pool, J. L., 45, 46, 50, 82, 84, 235, 240
Popoff, N., 6, 16, 296, 297
Poppen, J. L., 316, 318
Poser, C. M., 11, 16, 21, 50, 108, 126, 236, 240, 306, 308
Progonoma, melanotic, 141, 297
Progressive multifocal leucoencephalopathy, 4
Protoplasmic astrocytoma, see under Astrocytoma
Psammomatous meningioma, see under Meningioma, types
Pubertas praecox, association, hypothalamic ganglionic hamartoma, 298, **298**
Purkinjeoma, 164

Raaf, J., 4, 16, 131, 153
Racemose varices, 254
Radiation changes, 349–360
  acellular fibrosis, 355
  coagulative necrosis, 352
  cytologic characteristics, 350
  demyelination, 352
  experimental, 5, 349
  necrosis, 349 (see also Radionecrosis, brain)
  neoplastic transformation, 360
  neuroglia, 354
  pathogenesis, 358–360
  vascular, exudative, and proliferative, 350, 353–354, **357**, 358–360
Radionecrosis, brain, 350–360, **351–357**
  appearance
    gross, 351
    microscopic, 342–358
  effects
    acellular fibrosis, 355
    cerebellar cortex, 355–358, **358**
    coagulative necrosis, 352
    demyelination, 352
    early delayed, 350–351
    late delayed, 351
    neuroglia, 354
    vascular changes, 353–354, **357**
  neoplastic transformation, 360
  pathogenesis, 358–360
  pure, 351
Rahman, A. N., 367
Raimondi, A. J., 33, 50, 64, 84, 93, 104, 105, 126
Ramsey, H. J., 211, 214, 235, 240, 275, 284
Raney, R. B., 236, 240
Raskind, R., 200, 204
Rathke pouch tumor, 292
Ray, B. S., 257, 265
Reactive gliosis, see Gliosis, reactive
Reese, A. B., 303, 308
Renal cell carcinoma, see under Carcinoma
Rendu-Osler-Weber disease, association, capillary telangiectases, 241
Reticuloendothelial sarcoma, 215
Reticuloendotheliosis, malignant, 215
Reticulohistocytic encephalitis, 215
Reticulosis, malignant, 215
Reticulum cell sarcoma-microglioma, see under Sarcoma
Retinal anlage tumor, 141, 297, **297**
Rhabdomyosarcoma
  direct extension, 318
  meninges, 201 (see also Sarcoma, embryonal)
  teratomatous nature and alternative explanation, 201, 287
Rhaney, K., 287, 288
Rich, J. R., 370
Richards, P., 319, 332
Riggs, H. E., 212, 214
Ringertz, N., 131, 140, 153
Rio-Hortega, P. del, 277, 278, 280, 284
Roberts, M., 100, 104
Robertson, D. M., 63, 84, 176, 190
Rochat, G. F., 236, 240
Rodriguez, H. A., 303, 306, 308
Rosman, N. P., 308, 309
Ross, A. T., 301, 302
Rubé, J., 227, 234
Rubin, P., 275, 284
Rubin, R., 6, 16
Rubinstein, L. J., 9, 12, 13, 16, 53, 55, 72, 74, 79, 84, 122, 124, 126, 140, 141, 143, 149, 153, 190, 192, 193, 198, 204, 220, 234, 283, 284, 303, 308, 309, 339, 348
Russell, D. S., 2, 5, 8, 9, 13, 17, 34, 42, 50, 53, 55, 85, 105, 126, 127, 129, 159, 161, 167, 182, 187, 190, 215–217, 229, 234, 235, 240, 269, 270, 284, 287, 288, 303, 309, 319, 320, 332, 342, 348, 362, 367, 370

Sacral region, see under Spinal canal
Salm, R., 311
Samuelsson, S-M., 217, 234
Sandbank, U., 4, 17
Sanerkin, N. G., 72, 85
Saran, N., 303, 309
Sarcoma, 190–204 (see also specific forms)
  adventitial, 215
  appearance, gross and microscopic, 192
  clinical data, 192
  circumscribed arachnoidal cerebellar, 203

classification, 190–191
controversial entities, 203
cytogenesis, 190–191
definition, 190
differential diagnosis, 203
astrocytoma, 194, 203
ependymoma, 203
glioblastoma multiforme, 83–84, 193, 203
medulloblastoma, 152, 203
neuroblastoma, 157, 203
embryonal, 201, **201**, **202**
metastasis to central nervous system, 332
fibrosarcoma, 192–193, **192–193** (see also Fibrosarcoma)
growth and spread, 195
incidence, 191
malignant gliomatous reaction, 198
secondary to invasive sarcoma, 198, 199
meninges, **197**
metastasis, 201–202
mixed, 9
glioma, 198
monstrocellular, 72, **73**, 74, 83–84, 203
pathogenetic factors, 191
radiation, 5, 191
periadventitial, 215
perithelial, 215
perivascular, 215
polymorphic cell, 194, **195**
differential diagnosis, reticulum cell sarcoma-microglioma, 225
vermis, metastasis, 202
prognosis, 202–203
reticuloendothelial, 215
reticulum cell, 215
secondary lymphomatous proliferations, 228–229
reticulum cell sarcoma-microglioma, 215–227, **218**, **220–222**
appearance
gross, 217–219
microscopic, 219–222
associated conditions, 217
dysglobulinemia, 217
Wiskott-Aldrich syndrome, 217, **219**
corpus callosum, **218**, **221**, **223**
definition and cytogenesis, 215–216
differential diagnosis, 225
oligodendroglioma, 101, 225
pineal or suprasellar germinoma, 225, 275
polymorphic cell sarcoma, 225
growth and spread, 223
incidence, 217
multicentricity, 217
natural history, 216–217
sites, 217
treatment, 223
variants, 225–227
visceral involvement, 216–217
sites, 192
spindle cell, 193–194, **194**
adjacent, malignant glioma, **365**
leptomeninges, **194**
treatment, 202
variants, 200–202
Sarcomatosis, primary, meninges, 200
Saunders, R. L., 290, 292
Scharenberg, K., 363, 370
Scheinberg, L. C., 15, 17
Scherer, H. J., 11, 12, 17, 28, 42, 50, 55, 68, 71, 85, 99, 104, 130, 138, 142, 153, 216, 234
Schermer, K. L., 315
Schilder's disease, differential diagnosis, gemistocytic astrocytoma, 47
Schisano, G., 206, 214
Schlote, W., 36, 50
Schmidt, E., 298, 299
Schneck, S. A., 217, 234
Scholz, D. A., 314
Schulz, M. D., 45, 50, 82, 85, 124, 126, 151, 153, 239, 240, 275, 284, 349, 360
Schwannoma, 206–213
acoustic, 207, **207–209**, **211**
ancient, 211
appearance
gross, 207–209
microscopic, 209–212
Antoni A type tissue, 209, **209**
Antoni B type tissue, 210, **211**
associated lesions, 207
central form, von Recklinghausen's neurofibromatosis, 207, 209
cauda equina, **210**
central, 212
clinical data, 206
definition, 206
differential diagnosis, 212–213
astrocytoma, 49, **211**, 212–213
meningioma, 188–189, 212
metastatic melanoma, 328, **331**
neurofibroma, 213

incidence, 206
intramedullary, 212
multiplicity, 207
in von Recklinghausen's neurofibromatosis, central form, 206–207, 303
sites, 206
spinal, **208, 210, 211**
treatment and prognosis, 212
variant: intramedullary, 212
Schwannosis, intramedullary, in central form, von Recklinghausen's neurofibromatosis, 306, **307**
Sclerosis
multiple, association, malignant gliomas and gemistocytic astrocytoma, 5
tuberous, 301–302, **301**
association
gliomatosis cerebri, 42
subependymal giant cell astrocytoma, 21, 40, 301
neoplastic gliogenous transformation, 4
subependymal "candle gutterings", 41–42, 301
Scott, M., 212, 214
Secondary tumors, 313–332 (see also specific types)
direct extension, 313–318
hematogenous spread, 319–332
Shabo, A. L., 184, 190
Shaw, R. K., 232, 234
Shein, H. M., 6, 17
Sheline, G. E., 100, 104
Shenkin, H. A., 100, 104
Shivas, A. A., 14, 17
Shuangshoti, S., 201, 204, 262, 263, 265, 287, 288
Siegel, G. J., 173, 190
Silver, M. L., 237, 240
Simpson, D., 188, 190
Simson, L. R., 269, 284
Sinus tumor, endodermal, 276
Siqueira, E. B., 113, 126
Skinner, H. A., 206, 214
Skull, see under Cranial region
Slaughter, J. C., 309, 311
Slooff, J. L., 2, 3, 17, 46, 50, 56, 85, 108, 124, 126, 206, 214
Smith, D. R., 13, 17, 79, 82, 85
Smith, J. F., 257, 265
Smith, K. R., Jr., 296, 297
Smith, W. T., 278, 283, 284
Smyth, G. E., 346, 348
Snell, K. C., 5, 17
Soas, J. M., 275, 284, 285, 288
Sohn, D., 343, 348
Solitare, G. B., 4, 17
Solomon, A., 21, 50
Spataro, J., 100, 104
Spinal canal
associated tumors and hamartomas, central form of von Recklinghausen's neurofibromatosis
ectopic ependymal cells, 305, **305, 306**
glia, 304, **305–307**
intramedullary schwannosis, 306, **307**
microscopic ectopic ependymoma, **306**
astrocytoma, 26
cauda equina
ependymoma, extraneural metastases, 123, **123, 124**
infiltration, malignant lymphoma, **229–231**
melanoma metastatic to, 328, **329**
schwannoma, **210**
dermoid cyst, 289, **289**
traumatic origin, repeated lumbar punctures, 288–289
dura
mesenchymal chondrosarcoma, 200, **200**
secondary involvement, Hodgkin's disease, 232
ectopic glioma, 296
sacral region, 296, **296, 297**
enterogenous cyst, **267**, 287–288
epidural space, primary meningeal lymphosarcoma, 227
filum terminale
myxopapillary ependymoma, 118–119, **119**
normal microscopic appearance, **119**
incidence, tumor types, 1–3
leptomeninges, see Cranial region, meninges
lipoma, 295
medulla, see Cranial region, medulla
meninges, see Cranial region, meninges
meningioma, 172
metastasis to
carcinoma, 319–327
diffuse infiltration, nerve roots, **326, 327**
melanoma, 328–332
amelanotic, infiltrating nerve root, **331**
spinal cord and cauda equina, **329**
nerve root infiltration
metastatic amelanotic melanoma, 331
metastatic carcinoma, 326, 327
nerve root tumors, 205–214
central form, von Recklinghausen's neurofibromatosis, 302–308
histogenesis and nomenclature, 205–206

meningeal carcinomatosis, 325, **326**, **327**
metastatic amelanotic melanoma, **331**
schwannosis, 306, **307**, **308**
neuroglia, radiation changes, 354
sacral region, ectopic glioma, 296, **296**, **297**
schwannoma, 206–212, **208**, **210**, **211**
spinal cord
astroblastoma, 51
astrocytoma, 26, 38, 56
prognosis, 46
capillary hemangioblastoma, 236, **237**, **243**
capillary telangiectases, **243**
cavernous angioma, 245
central neurofibromatosis
ectopic ependymal cells, **305**
hamartomas, 303–308
microscopic ectopic ependymoma, **306**
tumors, 303
compression, plasmacytoma, 232
effects, intraspinal neoplasms, 348
ependymoma, 108, 110
malignant, **121**
prognosis, 124
ganglioglioma and ganglioneuroma, 151
glioblastoma multiforme, spread through cerebrospinal fluid pathways, 78–79, **78**
meningeal meningiomatosis, 200
metastases from malignant melanoma, **329**
parenchyma, schwannosis, 306
venous malformations, **253**, 254, **254**
angiodysgenetic myelomalacia, 255
teratoma, 285
Virchow-Robin spaces, invasion
all gliomas, except ependymomas, 12
diffuse astrocytoma, 43, **44**
hamartomas in central neurofibromatosis, 304, **305**
reticulum cell sarcoma-microglioma, 219, 220, **222**
Spindle cell sarcoma, see under Sarcoma
Spongioblastoma, 19
in central form, von Recklinghausen's neurofibromatosis, 303
multiforme, 55
polar, 19, 53–55, **54**
definition and cytogenesis, 53
differential diagnosis, 55
microscopic appearance, 53
resemblance, medulloblastoma, 136–137
term misapplied, 34, 37, 38, 53
polare, 53
Stains, see under Diagnostic aids
Stern, W. E., 333, 348
Stevenson, L., 130, 131, 153
Stowell, R. E., 276, 284
Stroobandt, G., 6, 17
Sturge-Weber disease, **253**, 255–256, **256**, 309
associated conditions, 256
"railroad track" calcifications, 255, **256**
Subacute necrotic myelitis, 255
Subarachnoid space, see under Cranial region
Subependymal forms of astrocytoma, see under Astrocytoma
Subependymoma, **103**, 105, 116–118, **117**, **118**
blepharoplasts, 118, **118**
multiple, **116**, **117**
Suprasellar epidermoid cyst, see under Cyst
Suprasellar region, see under Cranial region
Suzuki, H., 173, 190
Sweet, W. H., 285, 288
Sympathicoblastoma, 154
differential diagnosis, ependymoma, 125
metastasis to cranial periosteum, 332
Syncytial meningioma, see under Meningioma, types
Syringomyelia, association
astrocytoma, 21
capillary hemangioblastoma, 236, **237**
central form, von Recklinghausen's neurofibromatosis, 306
intramedullary spinal cord tumors, 4
spinal ependymoma, 108
Szepsenwol, J., 5, 17

Taniguchi, R., 295
Tansley, K., 349, 350, 360
Tarlov, I. M., 192, 201, 204
Taylor, P. E., 304, 309
Teilmann, K., 241, 256
Telangiectases
capillary, 241–244, **243**
association, Rendu-Osler-Weber disease, 241
multiple
differentiation, cavernous angiomas, 241
medulla, **244**
Teratocarcinoma, 276
Teratoid tumors, 286–288 (see also Teratoma)
malformative origin, 4
Teratoma, 285–288
appearance, gross and microscopic, 286
atypical, 287
atypical pineal, 269
differential diagnosis, medulloepithelioma, 129

fourth ventricle, 286–287, **286, 287**
incidence, sites, associated conditions, 285
intracerebral, **285**
malformative origin, 4
malignancy, 286
pineal, differential diagnosis, medulloepithelioma, 129
pineal and suprasellar, **267**, 275–276
association, germinoma, 270, **272, 273**
variants, 286–288
Teratomatous cyst of vertebral canal, 287
Tetralogy, Fallot's, association, arteriovenous malformations, 274, 250, **251**
Tola, J. S., 132, 153
Tompkins, V. N., 275, 284
Tonning, H. O., 236, 241
Touraine, A., 309, 311
Transitional meningioma, see under Meningioma, types
Transplantation, kidney, association, reticuloendothelial neoplasms, 217
Trauma, 5
meningioma, 172
Treip, C. S., 127, 129
Tuberculum sellae, see Cranial region
Tuberous sclerosis, see under Sclerosis
Tumors, general
associated dysgenetic syndromes, 300–311
classification, 7–8
diagnostic aids, 361–370
experimental, 5–6
general biologic characteristics, 9–15
incidence, 1–3
pathogenesis, 3–5
rosettes, **125**
secondary, 313–332
tissue culture, 9
Turnbull, I. M., 184, 190
Tytus, J. S., 288, 289, 292

Van Epps, R. R., 129
Van Gilder, J. C., 5, 17, 289, 292
Vandenberg, H. J., Jr., 318
Varix of vein of Galen, 250, **251**
Vascular endothelial proliferation, see under Cranial region
Vascular lumen, see under Cranial region
Vaughn, J. E., 140, 153
Vein of Galen, see under Cranial region
Venous malformations, angioma, see under the nouns
Ventricle, see under Cranial region
Villi, arachnoid, see under Cranial region
Virchow-Robin spaces, see under Spinal canal
Virus agents, 4–5
Voigt, W. H., 140, 153
von Hippel-Lindau disease, 309
association, capillary hemangioblastoma, 235–236, 239, 240
incomplete forms, 236
von Recklinghausen's disease, see Neurofibromatosis, von Recklinghausen's
Vraa-Jensen, G., 261, 265

Waggener, J. D., 205, 206, 211, 213
Waldmann, T. A., 236, 241
Walsh, J., 172, 190
Walton, K., 275, 284
Waltz, T. A., 191, 204, 360
Weir, B., 100, 104
Weiss, L., 123, 126
White matter, see under Cranial region
Wilkins, R. H., 370
Willis, R. A., 10, 11, 17, 42, 50, 138, 140, 153, 200, 201, 204, 288
Wilson, C. B., 83, 85, 151, 153
Wiskott-Aldrich syndrome, association, reticulum cell sarcoma-microglioma, 217, **219**
Wohlwill, F. J., 256
Wolf, A., 318
Wolman, L., 37, 50, 298, 299
Wood, M. W., 169, 190
Worster-Drought, C., 305, 309
Wright, J. H., 126, 153
Wyburn-Mason, R., 236, 241, 250, 254, 255

Xanthogranuloma, choroid plexus, 262–263, **262, 263**
Xanthoma, choroid plexus, 262
Xanthosis, 262

Zeitlin, H., 276, 278, 283, 284
Zeman, W., 359, 360
Zettner, A., 295
Zimmerman, H. M., 5, 17
Zülch, K. J., 2, 17, 34, 37, 50, 72, 74, 83, 85, 95, 104, 105, 126, 203, 204
Zu Rhein, G. M., 4, 17

PROFESSIONAL NOTES AND FINDINGS

PROFESSIONAL NOTES AND FINDINGS

DATE DUE

NIH LIBRARY JUN 5 1975

NOV 25 1976

SEP 14 1982

GAYLORD PRINTED IN U.S.A.

LIBRARY
NIH
Amazing Research.
Amazing Help.

http://nihlibrary.nih.gov

10 Center Drive
Bethesda, MD 20892-1150
301-496-1080

NIH LIBRARY
4 0087 8660

NIH LIBRARY
3 1496 00199 9591

MAR 17 1987
NOV 3 1987
JAN 18 1988
DEC 8 1988
MAR 21 1991
JUL 11 1994
DEC 14
APR 23 2003